



## Case report

# Combination of bronchoscopic cryoextraction and argon plasma coagulation in treatment of total central airway obstruction caused by giant blood clot formation in massive airway bleeding



Eric Daniel Tenda<sup>a,\*</sup>, Abraham Yakub<sup>a</sup>, Ceva Wicaksono Pitoyo<sup>a</sup>, Fauziah Fardizza<sup>b</sup>

<sup>a</sup> Division of Respirology and Critical Care, Department of Internal Medicine, Dr. Cipto Mangunkusumo Hospital, Faculty of Medicine Universitas Indonesia, Jakarta, Indonesia

<sup>b</sup> Department of Otorhinolaryngology, Head and Neck Surgery, Dr. Cipto Mangunkusumo Hospital, Faculty of Medicine Universitas Indonesia, Jakarta, Indonesia

## ARTICLE INFO

## Article history:

Received 20 May 2016

Received in revised form

6 June 2016

Accepted 10 June 2016

## Keywords:

Argon plasma coagulation

Blood clot

Central airway obstruction

Cryoextraction

## ABSTRACT

Life threatening event due to central airway obstruction caused by very large blood clot formation with profuse on going bleeding its very challenging to manage. Interventional pulmonologist must aware about this situation which can lead to respiratory failure. There are several choices to treat this unlikely situation, in example flexible bronchoscopy with forceps, bronchial lavage, and suction. We present a case with post-surgical tracheostomy bleeding which caused a giant blood clot formation in a disseminated intravascular coagulation due to severe sepsis in end stage renal disease patient, successfully managed with cryoextraction and argon plasma coagulation. Combinations of two endobronchial approaches can give a quick, safe and cost effective lifesaving treatment.

© 2016 The Authors. Published by Elsevier Ltd. This is an open access article under the CC BY-NC-ND license (<http://creativecommons.org/licenses/by-nc-nd/4.0/>).

## 1. Introduction

Central airway obstruction is a life threatening situation which defined as an obstruction of central airways consists of trachea and mainstem bronchi [1]. Etiologies of central airway obstruction can be categorized either as malignant processes or non-malignant processes such as blood clots [1]. Blood clots might be formed from due to conditions like tuberculosis, lung malignancy, and medical procedures such as thrombus formation following tracheostomy [2,3].

Interventional pulmonology approaches offer minimal invasive methods of managing total central airway obstruction. We report the successful removal of total central airway obstruction due to a giant blood clot resulted from massive airway hemorrhage from tracheostomy tube placement. In this case, the blood clot was removed by using cryoextraction while the hemorrhage was controlled by using argon plasma coagulation.

### 1.1. Case report

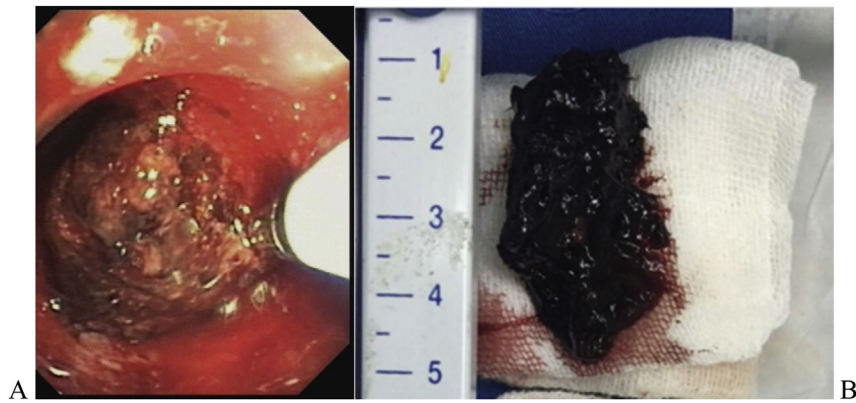
A 68-year-old man was referred to Intensive Care Unit of Dr. Cipto Mangunkusumo National General Hospital. Patient was diagnosed as septic shock due to hospital acquired pneumonia with multiple organ dysfunction syndrome. The kidney function was deteriorated with eGFR 9.8 ml/min/1.73 m<sup>2</sup>, blood ureum 221 mg/dl, and blood creatinine 5.6 mg/dl. The patient was put into regular hemodialysis.

Tracheostomy tube placement was indicated due to prolonged endotracheal tube ventilation. Following that, massive bleeding occurred around the tube stoma with suspicion of arterial bleeding. Oxygen saturation was found to be 62%. Moreover, disseminated intravascular coagulation (DIC) was observed marked by elevated d-dimer (3500 mcg/L), thrombocytopenia (76,000/ $\mu$ L), and prolonged prothrombin time (20.8 s).

Flexible bronchoscopy examination revealed presence of blood clots at larynx and proximal trachea which can be extracted by using biopsy forceps. Forceps extraction was unable to evacuate blood clot at distal trachea. This was due to the size of the blood clot was too large and attached forcefully to the posterior wall of the

\* Corresponding author.

E-mail address: [ericdanieltendaicl@gmail.com](mailto:ericdanieltendaicl@gmail.com) (E.D. Tenda).



**Fig. 1.** (A) Flexible bronchoscopy revealed obstruction due to blood clot at distal trachea, cryoextraction was performed. (B) Actual size of obstructed blood clot which was successfully removed.

distal trachea. Therefore, cryoextraction was performed to remove the blood clot. The cryoprobe was inserted through the clot for 15 seconds to deliver a frost effect (see Fig. 1A). A 4 cm length and 1.5 cm thick blood clot was successfully extracted (see Fig. 1B).

Bleeding was observed after removal of the blood clot hence argon plasma coagulation (APC) was conducted (see Fig. 2A). The ventilator setting of fraction inspired oxygen ( $\text{FiO}_2$ ) was set to 40% during the procedure to prevent air flame in the airway. Multiple APC was conducted at the side of carina, anterior, and right lateral wall of distal trachea. Bleeding was fully controlled immediately. At the end of procedures, oxygen saturation increased to 98%. Reevaluation bronchoscopy was conducted two days later revealed no new blood clots (see Fig. 2B). Patient was discharged two months later and is still in regular control at the outpatient clinic Dr. Cipto Mangunkusumo General Hospital for re-evaluation.

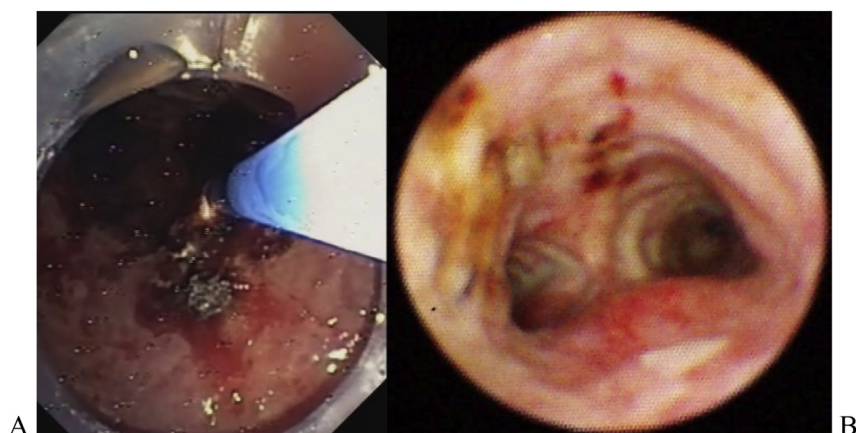
## 2. Discussion

Central airway obstruction might occur due to various etiologies which needs immediate management due to its high mortality [1]. Airway blood clot might be formed due to medical procedures such as tracheostomy tube placement [2]. Cases involving this kind of obstruction were rarely reported but it had been shown to be potentially fatal [3]. Attempts to remove airway blood clot by flexible bronchoscopy can be performed through bronchial lavage, suctioning, and forceps extraction initially [2].

In our case, the blood clot at distal trachea could not be evacuated by forceps extraction hence another approach is needed. Therefore, we decided to perform cryoextraction to evacuate the blood clot. Previously, cryoextraction had been reported to be safely performed at the bedside in intensive care unit [4]. In our case, we insert the cryoprobe tip for 15 seconds activation due to the large size of the clot. The central airway was successfully re-canalized through this approach.

In order to stop hemorrhage from former blood clots site, we decided to perform argon plasma coagulation (APC). In airway hemorrhage, bleeding foci are a good conductor for electrical current resulted from APC [5]. After bleeding foci has been successfully desiccated, electrical current will not penetrate deeper since those areas have been less electrically conductive [5]. Therefore, this method is more preferable for this case. Furthermore, APC was able to provide immediate control of airway hemorrhage [5]. In our case, hemorrhagic foci in carina and distal trachea were successfully controlled by APC immediately after its activation. Moreover, APC was able to prevent new blood clot formation as shown by reevaluation bronchoscopy two days later.

To conclude, combined bronchoscopy cryoextraction and APC technique proved to be a lifesaving and rapid method in managing endoluminal total central airway obstruction due to iatrogenic conditions, such as in this case it was caused by a blood clot despite the presence of comorbid conditions (DIC and end stage renal disease). Furthermore, a multidisciplinary team consisting of, but



**Fig. 2.** (A) Argon Plasma Coagulation of Distal Tracheal Wall. Bleeding was successfully stopped immediately following APC procedure. (B) Follow up bronchoscopy revealed no new blood clot formation in distal trachea.

not limited to, an interventional pulmonologist and otorhinolaryngologist is crucial in managing this life threatening situation.

#### **Conflict of interest**

There is no conflict of interest.

#### **Funding statement**

No funding was involved for the work of this paper.

#### **References**

- [1] A. Ernst, D. Feller-Kopman, H.D. Becker, A.C. Mehta, Central airway obstruction, *Am. J. Respir. Crit. Care Med.* 169 (2004) 1278–1297.
- [2] K.L. Arney, M.A. Judson, S.A. Sahn, Airway obstruction arising from blood clot\*: three reports and a review of the literature, *Chest* 115 (1) (1999) 293–300.
- [3] S.M. Underwood, R.J. Summerfield, Obstruction of tracheostomy by thrombus, *Crit. Care Med.* 14 (9) (1986) 834.
- [4] H. Lee, C.S. Leem, J.H. Lee, C.-T. Lee, Y.-J. Cho, Successful removal of endobronchial blood clots using bronchoscopic cryotherapy at bedside in the intensive care unit, *Tuberc. Respir. Dis.* 77 (2014) 193–196.
- [5] L. Sakr, H. Dutau, Massive hemoptysis: an update on the role of bronchoscopy in diagnosis and management, *Respiratory* 80 (2010) 38–58.