

Short report

Familial extrapyramidal disease with peripheral neuropathy

E BYRNE, PK THOMAS, KJ ZILKHA

From the Institute of Neurology, Queen Square, and the Royal Free Hospital School of Medicine, London

SUMMARY A family is presented in which 10 members over three generations developed a Parkinsonian syndrome. Two siblings had additional clinical and electrophysiological evidence of an associated peripheral neuropathy and sural nerve biopsy in one case revealed axonal loss. This is the third family reported in the literature in which an extrapyramidal syndrome is associated with neuropathy, but differs from earlier reports in that neuropathic involvement was due to axonal degeneration rather than segmental demyelination.

Parkinsonian features as part of a familial disorder may occur in isolation^{1,2} or as part of a more extensive multisystem disease, such as olivopontocerebellar atrophy.³⁻⁵ The concomitant development of familial peripheral neuropathy with an extrapyramidal syndrome reported in this paper is more unusual.

Case reports

The index case (II 7) supplied the family history shown in the figure. Ten cases over three generations developed an extrapyramidal syndrome. I 1 and I 5 developed severe tremor of the upper limbs in the fifth decade, and later a slow shuffling gait; they were unable to walk without assistance for many years before death in the seventh decade. Case II 1 developed a resting tremor and shuffling gait in his forties and died as a result of a complication of stereotactic thalamotomy. The earlier cases were resident in Guyana and cases II 8, II 9 and II 10 live in that country. Case II 11 emigrated from Guyana to Canada before the onset of symptoms. Cases II 3 and II 7 emigrated to England before becoming symptomatic and form the basis of this report.

Case 1 II 7 emigrated to England in 1962 aged 38 years and one year later developed resting tremor of the left leg, worse with stress and abolished by voluntary movement, followed by increasing slowness in fine hand movements

Address for reprint requests: Dr KJ Zilkha, The National Hospital, Queen Square, London WC1N 3BG, UK.

Received 25 April 1981 and in revised form 10 November 1981.

Accepted 9 December 1981.

and unsteadiness of gait. On examination aged 44 years, she had resting tremor of all limbs, generalised bradykinesia and cogwheel rigidity, impaired postural reflexes and ataxia of gait. No weakness or wasting was seen but knee and ankle jerks were absent. Over the next 10 years, her gait deteriorated further and when reassessed aged 56 she could not walk without assistance. Re-examination revealed that the extrapyramidal signs had progressed, with masklike facies, severe bradykinesia and plastic rigidity in all limbs. Mild arm ataxia and moderate ataxia of lower limbs and gait were evident. Although muscle bulk in the arms was well preserved, bilateral wasting of anterior tibial muscles and extensor digitorum brevis was seen without fasciculation. Weakness of intrinsic hand muscles and all movements at the ankles was present. Vibration sense was lost at ankle level but other sensory modalities were intact. The peripheral nerves were not thickened. Investigation revealed a normal erythrocyte sedimentation rate, blood picture, blood sugar and creatinine levels, liver function profile and immuno-

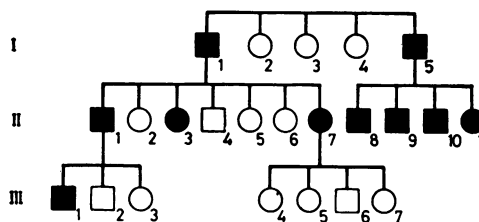


Figure Pedigree showing individuals affected by an extrapyramidal syndrome (filled symbols) over three generations.

globulin electrophoresis. The administration of amantadine and levodopa/carbidopa preparations was unbeneficial.

Case 2 II 3 developed a resting tremor in the left leg aged 46 years, which spread to the right leg three years later. On examination aged 49 years, she was found to have prominent blepharospasm and a coarse rhythmic resting tremor involving both lower limbs. No tremor was evident in the arms and muscle tone and speed of fine movements were normal. Over the next 10 years the tremor spread to the upper limbs and when re-examined aged 62, she had evidence of a severe resting tremor in all limbs. No other extrapyramidal signs were noted. When reassessed aged 65, she complained of numbness in both feet and on examination the knee and ankle jerks were absent. Power was well preserved. Sensory examination showed absent vibration sense to the knees; other modalities were preserved. Investigation revealed a normal blood picture, serum vitamin B₁₂ and blood sugar levels.

Nerve conduction studies

Conduction studies were carried out in Case II 7 at ages 45 and 56. In the initial study, sampling of left abductor pollicis brevis, abductor digiti minimi, tibialis anterior and extensor digitorum brevis revealed no spontaneous or excess insertion activity; on volition the motor unit recruitment pattern was moderately reduced in all muscles, with large polyphasic units up to 7 mV in amplitude in abductor pollicis brevis and 11 mV in extensor digitorum brevis, firing at high rates. Motor conduction velocity was 57 m/s in the left median and 52 m/s in the left peroneal nerve. The left peroneal nerve action potential at the head of the fibula with stimulation at the ankle was absent. Sensory action potentials recorded percutaneously at the wrist with stimulation of the index and fifth fingers respectively were of reduced amplitude but normal latency to peak (median 6 μ V, 3.3 ms; ulnar 5 μ V, 2.9 ms). The sural sensory action potential was absent. Repeat studies at age 56 were limited to the forearm. Ulnar motor conduction velocity was 36 m/s, median sensory action potential peak latency 4 ms, amplitude 2 μ V and ulnar sensory action potential peak latency 3.7 ms, amplitude 3 μ V.

In Case II 3, muscle sampling was not undertaken. Motor conduction velocity in the right ulnar nerve was 48 m/s and in the right peroneal nerve 34 m/s. The right median sensory action potential was broad and dispersed (latency 3.1 ms to onset, amplitude 2 μ V) and the right ulnar and sural potentials were absent.

Sural nerve biopsy

A right sural nerve biopsy (whole nerve) was performed in Case II 7 at age 56 years. The specimen consisted of seven fascicles. The total number of myelinated fibres was reduced at 1,942. The normal range for this nerve given by Behse and Buchthal⁶ is 5,200-9,500. The number of large fibres present was severely reduced, the total exceeding 7 μ m in diameter being only 29. The normal range for fibres of this calibre given by Behse and Buchthal is 1,650-3,300. Clusters of three or more fibres

of small diameter, indicative of regeneration after previous axonal degeneration, were numerous. Their frequency undoubtedly contributed to the maintenance of myelinated fibre density. No active fibre degeneration was seen and no concentric hypertrophic appearances (onion bulbs) were present. Teased fibre preparations showed that approximately 15% of the fibres displayed segmental demyelination and remyelination. This is probably not excessive for the patient's age. Arnold and Harriman⁷ found an incidence of segmental demyelination and remyelination of about 12% for subjects aged 40-59 in a control series. The density of unmyelinated axons was normal (54,760/mm²).

Discussion

Extrapyramidal signs dominated the clinical picture in both cases examined and preceded other signs by some years. The clinical impression of neuropathy with distal weakness, amyotrophy and areflexia in one case and stocking hypaesthesia with absent lower limb reflexes in the second case, was supported by nerve conduction studies in both and sural nerve biopsy in one, the findings indicating an axonal degeneration rather than segmental demyelination. The family history suggested that the disorder is transmitted as an autosomal dominant trait with high penetrance.

An association between post-encephalitic Parkinsonism and spinal muscular atrophy is well recognised,⁹ and sporadic¹⁰⁻¹³ and familial cases¹⁴ that appear to lack an encephalitic aetiology are also recognised. The difficulties in determining whether a disorder gives rise to anterior horn cell loss (neuropathy), a selective distal degeneration of axons (distal axonopathy) or a primary demyelinating process in the peripheral nerves are considerable, unless the peripheral nervous system is examined at several levels. As a consequence the neuropathological basis of the amyotrophy in reported cases is not always clear. Biemond and Sinnege¹⁵ described three patients in one family with prominent extrapyramidal signs and ataxia, areflexia and amyotrophy of variable severity, in one of whom *slight* degeneration of anterior horn cells was seen at necropsy. The motor roots and peripheral nerves were not examined and the authors acknowledged that a peripheral neuropathy had not been excluded. Biemond and Beck¹⁶ reported three first degree relatives affected by a progressive disorder with peripheral, pyramidal and extrapyramidal components. Necropsy studies in one case that had distal amyotrophy with areflexia, distal sensory loss and extrapyramidal signs, revealed severe demyelination in cervical and lumbar motor roots and marked axonal loss with demyelination in one motor nerve examined. As other nerves were not examined and

teased fibre studies were not performed, the basis of the amyotrophy is again open to question. Zeigler *et al*¹⁷ reported a large family with a pleomorphic neurological illness encompassing cerebellar ataxia, rigidity, bradykinesia, spasticity, fasciculation and amyotrophy in varying combinations. One case (IV 9) had a severe sensorimotor neuropathy with extrapyramidal signs. Sural nerve biopsy in this patient and two others revealed segmental demyelination and nerve conduction studies showed moderately slow motor conduction velocities.

The findings in the family reported here confirm a rare association between peripheral neuropathy and a multisystem disorder with prominent extrapyramidal involvement. Sural nerve biopsy demonstrated axonal loss rather than a demyelinating neuropathy. Review of the literature suggests that the basis of the amyotrophy in similar cases in the earlier literature is often unclear, although one family with prominent segmental demyelination has been documented.

We thank Professor J Marshall for allowing us to publish Case III 3 and for helpful comments on the manuscript; Miss J Workman for technical assistance; and the Friedreich's Ataxia Group for financial support.

References

- ¹ Allan W. The inheritance of the shaking palsy. *Arch Int Med* 1937;**60**:424-7.
- ² Spellman GC. Report of familial cases of Parkinson's syndrome. Evidence of a dominant trait in a patient's family. *JAMA* 1962;**179**:372-4.
- ³ Critchley M, Greenfield JG. Olivopontocerebellar atrophy. *Brain* 1948;**71**:343-63.
- ⁴ Aring CD. Degeneration of the basal ganglion associated with olivopontocerebellar atrophy. *J Nerv Ment Dis* 1940;**92**:448-70.
- ⁵ Konigsmark BW, Weiner LP. The olivopontocerebellar atrophies: a review. *Medicine* 1970;**49**:227-41.
- ⁶ Behse F, Buchthal F. Sensory action potentials and biopsy of the sural nerve in neuropathy. *Brain* 1978;**101**:473-93.
- ⁷ Arnold N, Harriman DGF. The incidence of abnormality in control human peripheral nerve studied by single axon dissection. *J Neurol Neurosurg Psychiatry* 1970;**33**:55-61.
- ⁸ Zilkha KJ. Discussion on motor neurone disease. *Proc R Soc Med* 1962;**55**:1028-9.
- ⁹ Greenfield JG, Matthews WB. Post-encephalitic Parkinsonism with amyotrophy. *J Neurol Neurosurg Psychiatry* 1954;**17**:50-6.
- ¹⁰ Brait K, Fahn S, Schwartz GA. Sporadic and familial Parkinsonism and motor neurone disease. *Neurology (Minneapolis)* 1973;**23**:990-1002.
- ¹¹ Yealland L. Progressive muscular atrophy associated with paralysis agitans. *Proc R Soc Med* 1937;**31**:211-2.
- ¹² Cordier J. Syndrome Parkinsonien avec des amyotrophies rappelant la sclérose latérale amyotrophique et d'origine post-traumatique. *Acta Neurol Belg* 1951;**51**:194-205.
- ¹³ Bonduelle P, Bouygues P, Delahousse J, Favaret C. Evolution simultanée chez un même malade d'une maladie de Parkinson et d'une sclérose latérale amyotrophique. *Rev Neurol (Paris)* 1959;**101**:63-6.
- ¹⁴ Van Bogaert L, Radermecker MA. Sclérose latérale amyotrophique typiques et paralysies agitanes héréditaires dans une même famille avec une forme de passage possible entre les deux affections. *Meschr Psychiat Neurol* 1954;**127**:185-203.
- ¹⁵ Biemond A, Sinnege JLM. Tabes of Friedreich with degeneration of the substantia nigra, a special type of hereditary Parkinsonism. *Confina Neurologica* 1955;**15**:129-42.
- ¹⁶ Biemond A, Beck W. Neural muscular atrophy with degeneration of the substantia nigra. *Confina Neurologica* 1955;**15**:142-53.
- ¹⁷ Ziegler DK, Schimke RN, Kepes JJ, Rose DL, Klinkerfuss G. Late onset ataxia, rigidity and peripheral neuropathy. A familial syndrome with variable response to L-dopa. *Arch Neurol* 1972;**27**:52-65.