

LETTER TO THE EDITOR

Clinical response to everolimus in a patient with Hodgkin's lymphoma harboring a *TSC2* mutation

Blood Cancer Journal (2016) 6, e420; doi:10.1038/bcj.2016.25; published online 13 May 2016

Hodgkin's lymphoma (HL) is a lymphoid malignancy that has a high cure rate with modern chemoradiation regimens.¹ However, about 10–20% of patients with advanced stage HL develop relapsed or progressive disease,¹ with 5% of patients presenting with primary progressive HL that has a 5-year overall survival of only 26%.² It is of paramount importance to develop novel treatments for this population of patients. Recently, several novel drugs were found to be active in refractory and/or relapsed HL, including the anti-CD30 monoclonal antibody brentuximab vedotin,³ the anti-PD1 monoclonal antibody nivolumab⁴ and the mTOR inhibitor everolimus.⁵ In a phase II clinical trial, everolimus

was shown to induce responses in 47% of patients with relapsed HL, including one patient who achieved clinical complete remission (CR).⁶ However, the lack of biomarkers for response are one of the many challenges that preclude a more widespread use of this drug in the therapy of HL. The advent of next-generation sequencing may help to determine molecular biomarkers associated with response to a specific drug, particularly when patients with an exceptional response are evaluated.⁷

We herein report the case of a female patient with primary refractory HL that achieved a near CR with single-agent everolimus. Genomic analysis of the tumor at the time of progression to the last therapy demonstrated damaging mutations of the *TSC2* gene that may lead to increased mTOR pathway activation.

A 31-year-old female patient was diagnosed with stage IVB nodular sclerosis HL in July 2012. She had primary refractory

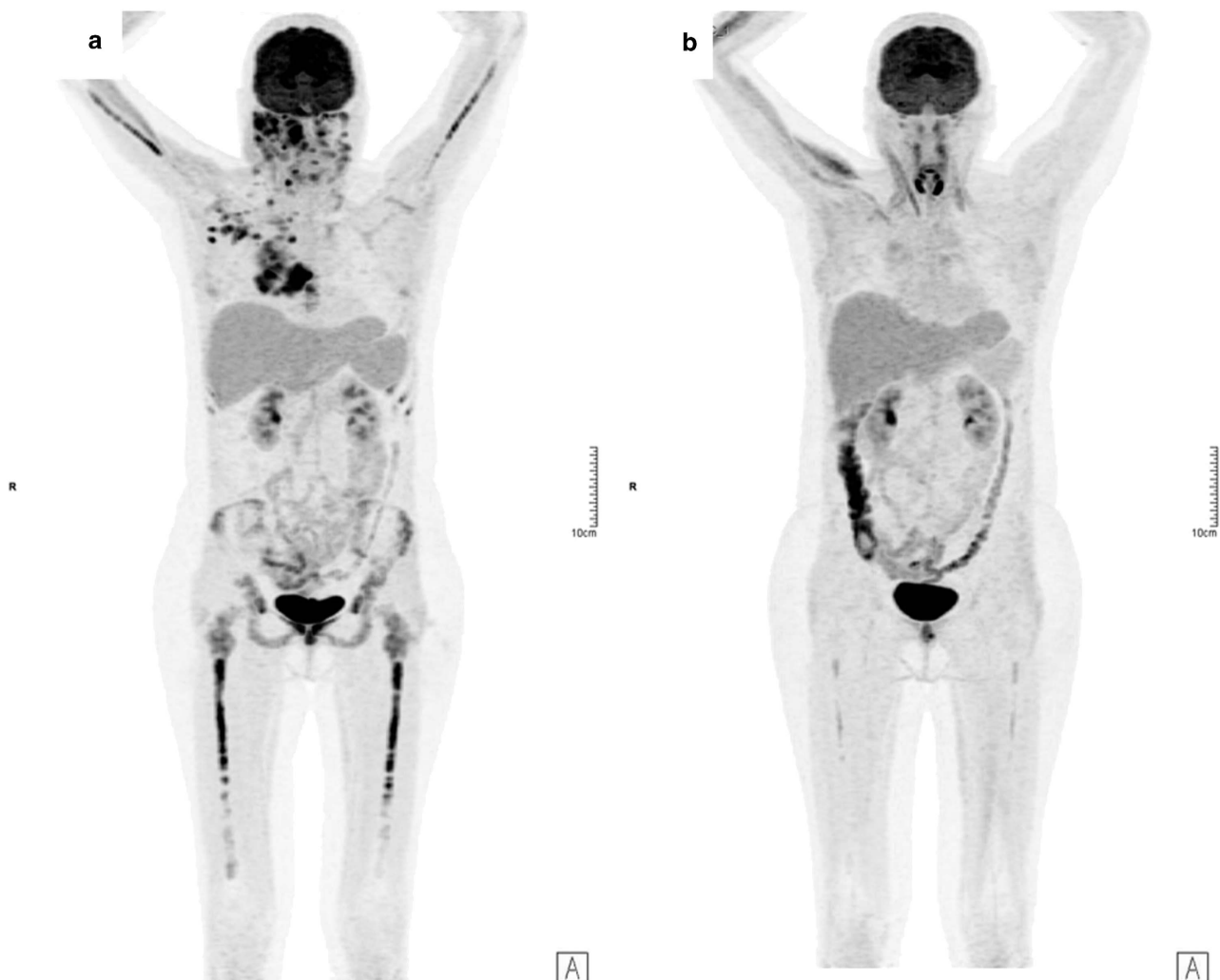


Figure 1. (a) Positron emission tomography-computed tomography (PET-CT) prior to start of everolimus therapy. (b) PET-CT after 2 months of therapy with single-agent everolimus.

disease and did not respond to ABVD and several different salvage chemotherapeutic regimens, including ICE, GNP, DHAP, BEACOPP, IVAC and bendamustine. She never underwent autologous peripheral blood stem cell transplantation due to lack of chemosensitive disease. She was treated with brentuximab vedotin, but had disease progression after six cycles, presenting with lung and pleural involvement and compression of spinal roots (Figure 1a). Patient was then started on therapy with off-label everolimus, based on the results of the aforementioned clinical trial, as she was considered to be refractory to chemotherapy.⁵ After 2 months of therapy with single-agent everolimus (10 mg orally once daily), a new positron emission tomography-computed tomography scan showed that the patient had achieved a near CR (Figure 1b) with disappearance of most sites of disease and >90% reduction in the remaining sites. As she had no HLA-matched donors, she underwent haploidentical allogeneic stem cell transplantation 1 month after achieving a response to everolimus. Unfortunately, she passed away due to transplant-related complications (cytomegalovirus pneumonia) on day +68.

Because of this patient-significant response to everolimus, an inhibitor of the PI3K-Akt-mTOR pathway, we hypothesized that this patient's tumor might harbor mutations associated with increased activity of this pathway. We sent the formalin-fixed paraffin-embedded block of a lymph node biopsy done at the time of disease progression on brentuximab to be analyzed by means of a comprehensive targeted next-generation-sequencing-based genomic profiling (FoundationOne Heme, Cambridge, MA, USA) using DNA and RNA in a CLIA certified laboratory (Foundation Medicine). This method consists of the analysis of the entire coding sequence of 405 cancer-related genes, 31 selected introns frequently involved in rearrangements and RNA sequencing of 265 genes commonly fused in cancer, to a median coverage of >500x and >20 000 000 reads. No microdissection of Reed–Sternberg cells was performed. No germline DNA was available for sequencing. The results revealed 21 genomic abnormalities, including a missense mutation on gene *TSC2*. The V1711M mutation on *TSC2* is a conservative missense mutation localized on the Rap-GAP domain of the tuberlin protein. The sorts intolerant from tolerant score (*in silico* tool that predicts whether changes in amino acids in protein sequences are deleterious) was 0.02, suggesting that this mutation is damaging. Furthermore, this mutation has been previously reported in a patient with squamous cell skin carcinoma of the face.⁸ Besides the *TSC2* mutation, several other oncogenic variants were detected (Table 1).

Inactivating mutations on *TSC2* and *TSC1* have been described in tuberous sclerosis,^{6,9} and the *TSC1*–*TSC2* complex is a critical negative regulator of mTOR complex 1 (mTORC1).¹⁰ Within the *TSC1*–*TSC2* complex, *TSC1* stabilizes *TSC2*, whereas *TSC2* acts as a GTPase-activating protein (GAP) for the small GTPase Rheb (Ras homolog enriched in brain).^{11,12} When active, the *TSC1*–*TSC2* complex inhibits mTORC1 by stimulating the conversion of Rheb-GTP to Rheb-GDP.^{11,12} Therefore, the ability of a variety of upstream pathways to affect mTORC1 activity is dependent on modifications that functionally inhibit or activate the *TSC1*–*TSC2* complex. The GAP domain, where the V1711M mutation is located, is crucial for *TSC2* function,⁹ and loss of *TSC2* activity may lead to mTORC1 pathway activation.^{11,12}

It has been suggested that *TSC1*/*TSC2* inactivation predicts for responses to mTOR inhibitors. Indeed, *TSC1* mutations have been found in 8% of bladder malignant tumors, and are correlated with sensitivity to everolimus.¹³ In another report, a nonsense mutation in *TSC2* (Q1178*) was described in a patient with anaplastic thyroid cancer who had an impressive response to everolimus.¹⁴ Activation of the mTOR pathway is found in the majority of cases of HL and HL cell lines,¹⁵ but the mechanisms that lead to this increased activity are currently unknown.⁵

We herein describe the first case of *TSC2* mutation in a patient with advanced HL who had an impressive clinical response to

Table 1. Oncogenic genomic alterations found

Known drivers and potential driver mutations		
Gene	AA change	VAF (%) or fold amplification
<i>TSC2</i>	p.V1711M	50
<i>DNMT3A</i>	p.P896L	11
<i>PTCH1</i>	p.G288D	12
<i>ATR</i>	p.W2104*	7
<i>BRCA2</i>	p.R2842C	42
<i>B2M</i>	p.M11	13
<i>B2M</i>	p.M1K	26
<i>MSH6</i>	p.T1219I	9
<i>TP53</i>	p.K291N	19
<i>TP53</i>	p.R248Q	21
<i>ASXL1</i>	p.Q1517*	9
<i>XPO1</i>	p.E571K	32
<i>AXIN1</i>	p.P24S	9
<i>FBXO11</i>	p.R640fs*5	9
<i>CD36</i>	p.Y325*	51
<i>CDC73</i>	Splice site (c.370+1G>A)	10
<i>JAK2</i>	Amplification	11x
<i>CD274</i>	Amplification	11x
<i>PDCD1LG2</i>	Amplification	11x
<i>CCND3</i>	Amplification	22x
<i>KDM4C</i>	Amplification	11x

Abbreviations: AA, amino acid; VAF, variant allele fraction.

everolimus. One limitation of this report is that no functional studies were done to confirm the oncogenic role of this particular *TSC2* mutation in HL. However, we do believe that the response to everolimus seen in this case suggests that mutations of *TSC2* and other genes of the mTOR pathway should be further investigated in patients with HL.

CONFLICT OF INTEREST

PVC, SA and JSR are employees of Foundation Medicine Inc.

GF Perini¹, PV Campregher^{1,2}, JS Ross^{2,3}, S Ali², N Hamerschlak¹ and FPS Santos¹

¹Centro de Oncologia e Hematologia Familia Dayan Daycova, Hospital Israelita Albert Einstein, São Paulo, Brazil;

²Foundation Medicine Inc, Cambridge, MA, USA and

³Department of Pathology and Laboratory Medicine, Albany Medical Center, Albany, NY, USA

E-mail: santos.fabio2@einstein.br or fabiopss@gmail.com

REFERENCES

- Connors JM. I. Hodgkin lymphoma: special challenges and solutions. *Hematol Oncol* 2015; **33**(Suppl 1): 21–24.
- Josting A, Rueffer U, Franklin J, Sieber M, Diehl V, Engert A. Prognostic factors and treatment outcome in primary progressive Hodgkin lymphoma: a report from the German Hodgkin Lymphoma Study Group. *Blood* 2000; **96**: 1280–1286.
- Younes A, Bartlett NL, Leonard JP, Kennedy DA, Lynch CM, Sievers EL *et al*. Brentuximab vedotin (SGN-35) for relapsed CD30-positive lymphomas. *N Engl J Med* 2010; **363**: 1812–1821.
- Ansell SM, Lesokhin AM, Borrello I, Halwani A, Scott EC, Gutierrez M *et al*. PD-1 blockade with nivolumab in relapsed or refractory Hodgkin's lymphoma. *N Engl J Med* 2015; **372**: 311–319.
- Johnston PB, Inwards DJ, Colgan JP, Laplant BR, Kabat BF, Habermann TM *et al*. A phase II trial of the oral mTOR inhibitor everolimus in relapsed Hodgkin lymphoma. *Am J Hematol* 2010; **85**: 320–324.
- European Chromosome 16 Tuberous Sclerosis C. Identification and characterization of the tuberous sclerosis gene on chromosome 16. *Cell* 1993; **75**: 1305–1315.
- Marx V. Cancer: a most exceptional response. *Nature* 2015; **520**: 389–393.
- Durinck S, Ho C, Wang NJ, Liao W, Jakkula LR, Collisson EA *et al*. Temporal dissection of tumorigenesis in primary cancers. *Cancer Discov* 2011; **1**: 137–143.

- 9 Niida Y, Lawrence-Smith N, Banwell A, Hammer E, Lewis J, Beauchamp RL *et al*. Analysis of both TSC1 and TSC2 for germline mutations in 126 unrelated patients with tuberous sclerosis. *Hum Mutat* 1999; **14**: 412–422.
- 10 Tee AR, Fingar DC, Manning BD, Kwiatkowski DJ, Cantley LC, Blenis J. Tuberous sclerosis complex-1 and -2 gene products function together to inhibit mammalian target of rapamycin (mTOR)-mediated downstream signaling. *Proc Natl Acad Sci USA*. 2002; **99**: 13571–13576.
- 11 Tee AR, Manning BD, Roux PP, Cantley LC, Blenis J. Tuberous sclerosis complex gene products, tuberlin and hamartin, control mTOR signaling by acting as a GTPase-activating protein complex toward Rheb. *Curr Biol* 2003; **13**: 1259–1268.
- 12 Inoki K, Li Y, Xu T, Guan KL. Rheb GTPase is a direct target of TSC2 GAP activity and regulates mTOR signaling. *Genes Dev* 2003; **17**: 1829–1834.
- 13 Iyer G, Hanrahan AJ, Milowsky MI, Al-Ahmadie H, Scott SN, Janakiraman M *et al*. Genome sequencing identifies a basis for everolimus sensitivity. *Science* 2012; **338**: 221.
- 14 Wagle N, Grabiner BC, Van Allen EM, Amin-Mansour A, Taylor-Weiner A, Rosenberg M *et al*. Response and acquired resistance to everolimus in anaplastic thyroid cancer. *N Engl J Med* 2014; **371**: 1426–1433.
- 15 Mark A, Hajdu M, Varadi Z, Sticz TB, Nagy N, Csomor J *et al*. Characteristic mTOR activity in Hodgkin-lymphomas offers a potential therapeutic target in high risk disease—a combined tissue microarray, *in vitro* and *in vivo* study. *BMC Cancer* 2013; **13**: 250.



This work is licensed under a Creative Commons Attribution-NonCommercial-ShareAlike 4.0 International License. The images or other third party material in this article are included in the article's Creative Commons license, unless indicated otherwise in the credit line; if the material is not included under the Creative Commons license, users will need to obtain permission from the license holder to reproduce the material. To view a copy of this license, visit <http://creativecommons.org/licenses/by-nc-sa/4.0/>