

# THE AORTIC LESION OF ANKYLOSING SPONDYLITIS

BY

B. M. ANSELL, E. G. L. BYWATERS, AND I. DONIACH

*From the Postgraduate Medical School of London and Canadian Red Cross Memorial Hospital, Taplow*

Received January 20, 1958

The occurrence of heart disease in rheumatoid arthritis and ankylosing spondylitis has been known for a considerable time, but its exact incidence and status has been the subject of much controversy, further confused by the North American inclusion of both diseases under one heading. In a survey of the subject in 1950, Bywaters distinguished three combinations: patients with rheumatoid arthritis and specific (rheumatoid) valve lesions; patients with both rheumatoid arthritis and, as a coincidence, rheumatic heart disease; and finally, patients with Jaccoud's syndrome (rheumatic heart disease and chronic post-rheumatic joint deformities). These three possibilities were also discussed by Thomas (1955) in relation to ankylosing spondylitis, and it was concluded that some of these patients were of the Jaccoud type. In his series of 12 cases with spondylitis and valvular disease, only two showed lone aortic disease, both with a previous history of rheumatic fever and thought to be rheumatic in origin; the remaining 10 presented mitral lesions predominantly. Only four cases of ankylosing spondylitis with necropsy were tabulated by Bywaters in 1950; one of them had mitral fibrosis without stenosis or regurgitation, and another calcified aortic valves. A larger series of cases has since been studied clinically (Wilkinson and Bywaters, 1958) and two patients have been found up to the present time presenting the aortic lesion described in "rheumatoid arthritis" (ankylosing spondylitis) by Bauer *et al.*, 1951. As these appear to be the first described in this country, a detailed account, including necropsy data on one, is thought to be of interest.

## CASE REPORTS

*Case 1.* A man, when aged 22 in 1944, developed pain and swelling of both feet. A diagnosis of rheumatoid arthritis was made and he was discharged from the Army, walking with the aid of sticks. His ankles and feet improved, but this was followed by pain and stiffness in the knees. At the end of a year he was symptom free and working full time as a lorry driver.

In 1947 he developed a right iritis. About 1949 he first noticed stiffness and aching in the lumbar and thoracic spine and when seen at Hammersmith Hospital was found to have a rigid spine with a chest expansion of 2 cm. At that time the E.S.R. was 74 mm./hr. Westergren, and the hæmoglobin 65 per cent. Narrowing of the sacroiliac joints and some marginal lipping of both hip joints were seen on X-ray films. He was treated by radiotherapy with good symptomatic effect.

He had further courses of radiotherapy in 1950 and twice in 1952. In 1951 the right iritis recurred, and despite local therapy he was left with severely impaired vision. At this time the spine was completely fixed. Despite an E.S.R. between 75 and 125 mm./hr. and mild anæmia, he was well enough to continue work as a lorry driver until early in 1954, when iritis appeared in the left eye; it was again treated locally, and caused further deterioration in vision. He had developed increasing flexion deformity of the right hip, and in October 1954, on entry into Hammersmith Hospital, in addition to the completely rigid spine he showed an attitude of general flexion, with limitation of both shoulder and hip joints and both knees. The chest expansion was now half an inch. The cardiovascular system was normal clinically, apart from a soft systolic murmur at the apex; blood pressure 135/70. There was slight œdema of the dorsum of both feet. There was bilateral and extensive old iritis but no evidence of active inflammation. Investigations revealed

E.S.R. (Westergren) 97 mm./hr., D.A.T. 1 : 4 (negative), mild hypochromic anæmia, and marrow compatible with iron deficiency anæmia; occult blood was positive on two occasions, but a barium meal was normal as was a fractional test meal. Rectal examination was negative. He was treated by oral iron with moderate response.

He became increasingly disabled because of severe hip involvement, and was admitted to Manor House Hospital in November 1955, where he remained until the beginning of October 1956, being treated with radiotherapy and prednisolone. At this time the heart was reported as normal. By the time he was discharged, now off hormone, he was able to walk without assistance, but rapidly relapsed so that by the time of re-admission here in November 1956 he was unable to do anything for himself, and was in severe pain. The lumbar and thoracic spine was rigid and flexed and there was slight movement in the cervical region only. Both shoulders were painful and limited and the hips fixed at about 90° flexion deformity. X-ray showed gross changes in spine, sacroiliac joints, and hips, typical of ankylosing spondylitis.

By now the pulse was of water hammer character and the blood pressure was 140/70. The apex beat was displaced to the left and of left ventricular type and there was a triple rhythm with an ejection murmur at the apex; also a loud aortic diastolic murmur (Fig. 1). Investigations: E.S.R. 85 mm./hr., D.A.T. 1 : 1; hæmoglobin 65 per cent; iron deficiency anæmia; barium meal negative; Wassermann and Kahn, treponema pallida immobilization test and Price precipitation reaction (kindly done for us at the V.D. Reference Laboratory) were all negative, as all our own tests had been. A chest X-ray showed no abnormality. The cardiogram showed partial right bundle-branch block with P-R interval 0.24 seconds.

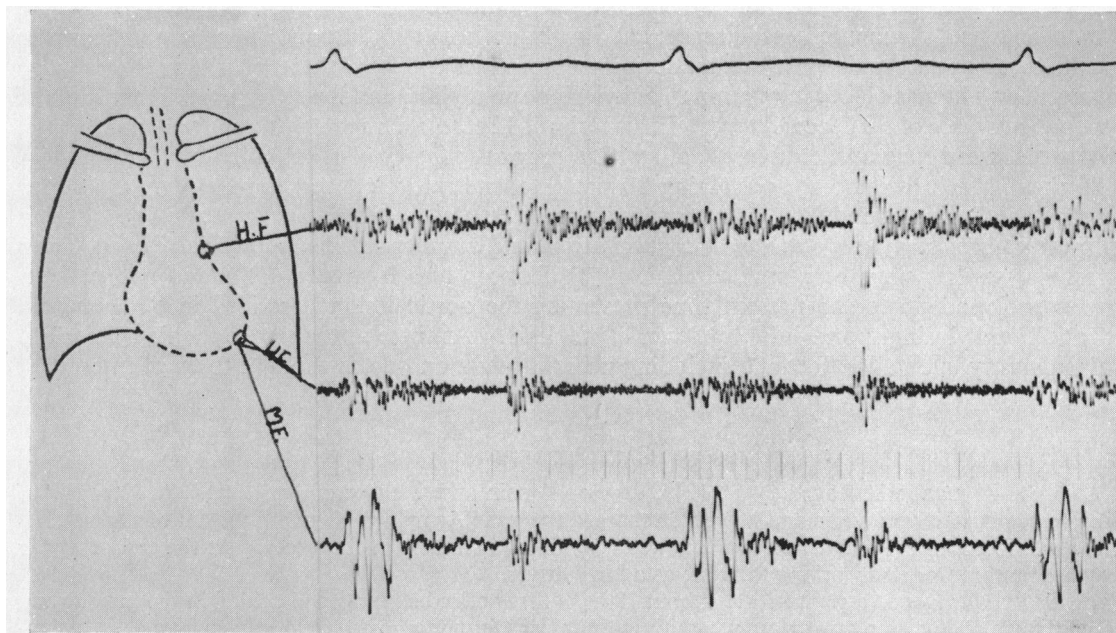


FIG. 1.—Case 1. Phonocardiogram, showing aortic diastolic murmur in a man aged 36 who had ankylosing spondylitis for 13 years.

The patient was given 15 mg. prednisolone daily, which was temporarily increased to 30 mg. a day together with dispirin and intensive physiotherapy. On this treatment he slowly improved so that it became possible for him to live at home and to get about well on elbow crutches. The eyes have improved only slightly and the cardiovascular system is clinically unchanged, but he has had several attacks of palpitation lasting about ten minutes, which are thought to have been paroxysmal tachycardia. There has been no evidence of cardiac failure.

*Case 2.* A man, aged 27, was first seen in 1949, complaining of pain in the right sacro-iliac region which had appeared every 10 to 14 days, persisting for two to three days over the last six months. He was febrile (temperature up to 103 °F.) and showed acute tenderness over the right sacro-iliac joint and right great

trochanter, but no other abnormal physical findings, the blood pressure being 130/84. Investigations showed an E.S.R. 122 mm./hr. (Westergren) and haziness in the right sacro-iliac joint on X-ray. The most likely diagnosis was thought to be tuberculous sacro-ileitis, but this could not be substantiated, the Mantoux being negative 1/100 and no abnormality seen on the chest X-ray. Over the next weeks he ran a persistently high E.S.R., and lost weight. Ten weeks after admission he developed pain and swelling of the right knee, and later of the right ankle and foot. At this time blood Wassermann and Kahn and gonococcal fixation tests were negative; aspiration of the synovial fluid showed low viscosity, 5.5 g. of protein per 100 ml.; white cell count 4400/cu. mm. with 98 per cent lymphocytes. Biopsy of the synovial membrane was compatible with, but not typical of, rheumatoid arthritis. At this time it was thought that the most likely diagnosis was an unusual form of rheumatoid arthritis, but the possibility of Reiter's syndrome had to be borne in mind. The patient continued to have pain and swelling of other peripheral joints (left knee, left ankle, and several toe joints), but steadily improved on salicylates, so that about six months from the time of admission he was completely well again and symptom free.

He then went to India, where from 1950 to 1953 he was quite well, working as a supervisor in the well-digging industry. In 1952 he developed a urethral sore, which was treated by a short course of penicillin injections. Shortly after his return in 1953 he was seen at Hammersmith Hospital when he appeared to be quite well and had had no further symptoms. No X-ray or blood examinations were made. In 1954 he developed left iritis. This was treated by local cortisone, and improved after two weeks only, to recur and require further treatment over a period of one year without any real recovery of sight in that eye.

The patient was seen again in November 1955. In the preceding four months he had become increasingly tired, and had severe exertional dyspnoea, with recurrent chest pain on exertion, and frequent nose bleeds. At this time he showed a jugular venous pressure of 3 cm. above the sternal angle, a collapsing pulse, blood pressure of 130/55, an apex beat displaced to the left, a triple rhythm, and a loud aortic diastolic murmur. The only other positive finding at this time was the old left iritis. There was no apparent peripheral joint abnormality and minimal limitation of back movement. He was advised admission to hospital but this he refused. However, he had to be admitted in February 1956 because the angina had become very much worse. There was no change in the physical signs recorded in the out-patient notes.

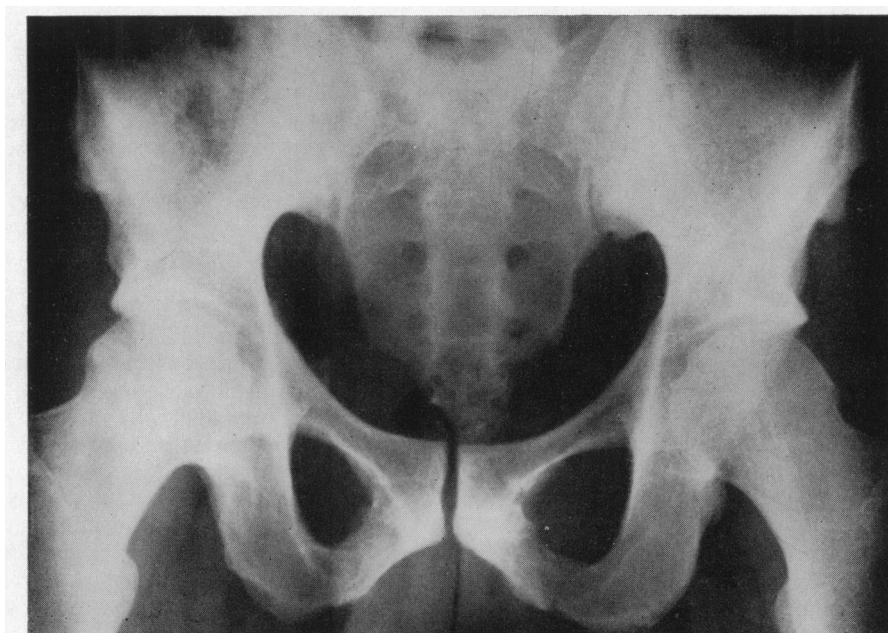


FIG. 2.—Case 2. Pelvis, showing obliterated sacro-iliac joint on one side with early erosions and subarticular sclerosis on the other. Note also hypertrophic bony outgrowths on ilium and ischiopubic rami.

The chest expansion was now 2 cm., having been 11 cm. in 1949. Investigations: E.S.R. 60 mm./hr. Westergren; total protein 7.8 g. albumin 3.4 g. globulin 4.4 g. each per 100 ml.; colloidal gold negative; zinc sulphate 5; D.A.T. 1:4; Wassermann and Kahn, Price precipitation and *Treponema* immobilization tests all negative. X-ray of the chest showed rounding of the left ventricular border with prominence of the left aortic knuckle. The

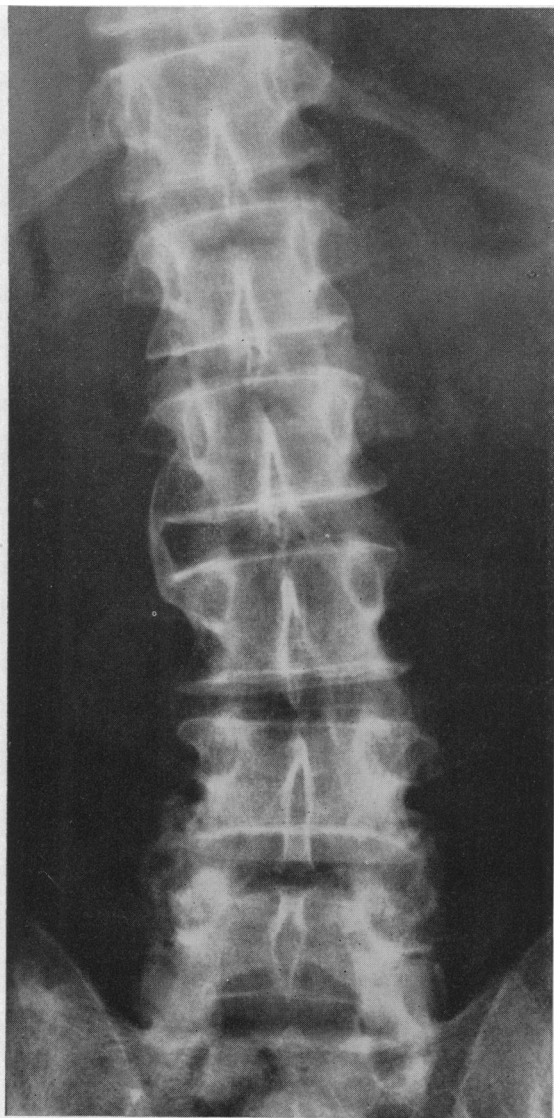


FIG. 3.—Case 2. X-ray of spine (Feb. 1956), showing bridging L.2, 3 and early bridging T.12, L.1, L.2. Some sclerosis of apophyseal joints.

joint X-rays showed complete obliteration of the right sacro-iliac joint, some bony sub-articular sclerosis in the region of the left, complete bridging between the second and third lumbar vertebra and early bridging elsewhere in the lumbar spine. The ischial and pubic rami showed characteristic bony excrescences (Fig. 2 and 3). There was an erosion of the terminal joint of the right big toe. In the electrocardiogram the P-R interval was 0.22 to 0.26 seconds with some depression of the S-T interval and marked changes of the T wave. This was thought to indicate a large left ventricle with probably some ischaemic changes or digitalis effect. He was treated with digitalis and bed rest and trinitrini with good effect.

He was re-admitted twice more in 1956 for heart failure, with nocturnal and exertional dyspnoea and angina. The blood pressure rose gradually to 230/70; the liver became palpable and crepitations were heard at the bases. The heart became greatly enlarged. Treatment was continued with digitalis and neomercazole, until the recurrence of iritis in 1957, not responding to local hormone, necessitated the addition of prednisolone. This had to be discontinued after two weeks because of his psychotic behaviour. The jugular venous pressure rose, and peripheral oedema appeared, unresponsive to treatment; he died in April 1957 after the development of what was thought to be pulmonary infarction.

Post-mortem examination (Dr. Doniach) showed evidence of long-standing congestive heart failure with terminal pulmonary infarction. No other visceral changes except those in the heart were seen.

The heart weighed 515 g. and was dilated and hypertrophied, especially the left ventricle. The mitral valve showed congenital duplication of the posterior cusp but no other abnormality. The aortic cusps were thickened and the free margins rolled. The commissures were thickened, leading to regurgitation but not inter-adherent (Fig. 4). The other valves were healthy and the coronary arteries showed no atheroma although there was slight hyaline thickening of the first few proximal

centimetres. The aorta showed patchy hyaline thickening (Fig. 5), down to below the renal arteries, especially round the orifices of branches, longitudinal wrinkling, and a few spider scars, closely resembling the changes of syphilis (although in the latter disease these changes seldom spread below the diaphragm).

Microscopically, infarction of the lungs was confirmed and there was congestive centrilobular necrosis in the liver. The eye showed chronic inflammatory iritis and cyclitis. The prostate showed no abnormality apart from some thrombus in the periprostatic veins. Examination of the knee, finger joints, sacro-iliac

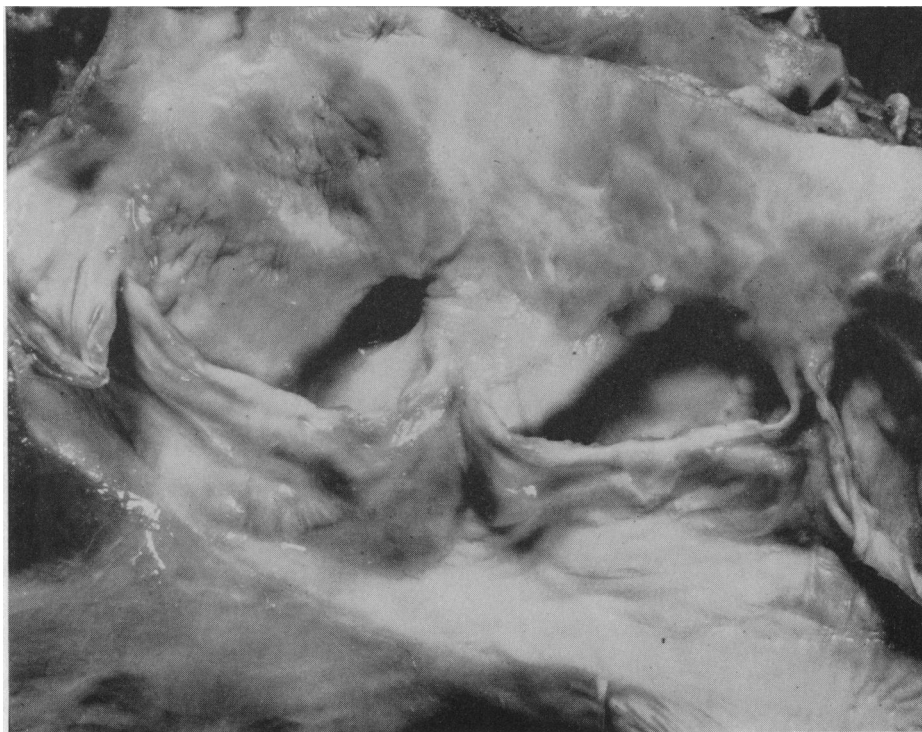


FIG. 4.—Aortic valve, showing thickening of the cusps, rolled free margins, thickening and separation of the commissures. The intima of the sinuses of Valsalva and ascending aorta is irregularly thickened and wrinkled. Case 2.

and apophyseal joints showed no present active inflammatory disease, although in the knee there was evidence of previous disease. The sacro-iliac joint and apophyseal joints also showed scarring with loss of cartilage and replacement by fibrotic connective tissue which also penetrated the sub-chondral bone in places. This tissue was quite distinct from the normal fibrous tissue bridging the upper part of the joint between the two bones.

The heart showed no Aschoff nodes or evidence of previous inflammatory disease in the neighbourhood of the mitral valve. The aortic valve (Fig. 6) showed collagenous thickening of the cusps from the free margin to the base. There were abnormal vessels in the cusp itself and in the epicardium surrounding the root of the aorta. The latter vessels showed gross thickening of the intima by the new formation of longitudinal muscle and elastic tissue internal to the internal elastic lamina, resulting in a very small lumen (Fig. 7 and 8). The aorta showed hyaline thickening of the intima and collagenous thickening of the adventitia with some cuffing of the vasa vasorum by lymphocytes. Some also showed intimal endarteritis. The media showed severe and widespread damage by both diffuse and focal collagenous replacement of muscle and elastic tissue usually surrounding small vessels (Fig. 9 and 10); in places, nuclei were absent. This change extended down to the mid-abdominal aorta (see Fig. 5.)

#### DISCUSSION

It is clear that both these patients developed the lesion that was described briefly by Bauer and his colleagues in 1951, and more fully by Clark *et al.* (1957). As Bauer claims, on more general grounds, this is not syphilis, since the *Treponema* immobilization test was negative in both instances (Zellmann, 1954). Bennett (1951) in discussion of Bauer's 1951 abstract cites a case of juvenile rheumatoid arthritis, commencing at the age of 3 and showing at the age of 8 at necropsy severe

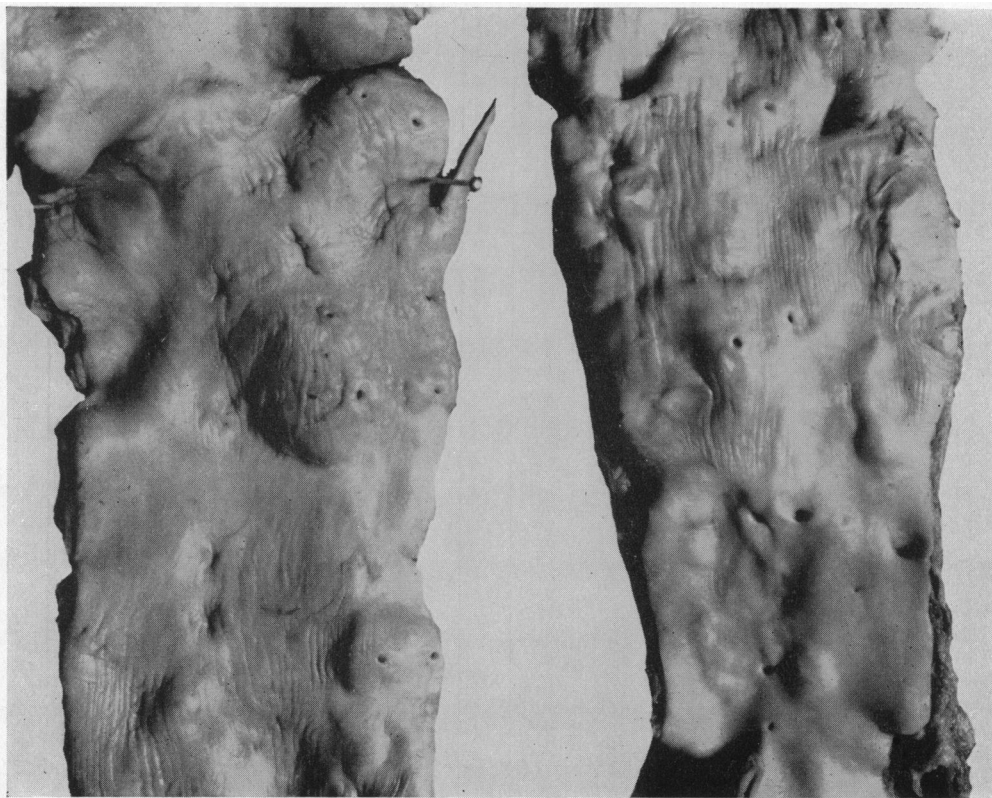


FIG. 5.—Thoracic aorta on the left, abdominal on the right, showing longitudinal wrinkling, scattered intimal plaques and occasional irregular intimal scars. These changes stop sharply a few cm. above the bifurcation. Case 2.

aortitis with aneurysm formation; the cusps were thickened and the proximal 3 cm. of aorta showed lesions “difficult if not impossible to distinguish from an actual syphilitic aortitis.” In this, as in Bauer’s cases and ours, the serological reactions were negative. We have also seen the development in juvenile rheumatoid arthritis (Still’s disease) of basal diastolic murmurs and aortic regurgitation. At this age, sacro-iliac disease is difficult to diagnose radiologically or by other means. Three of the six cases described by Schilder *et al.* (1956) had symptoms in childhood at 3, 11, and 12 years of age, before developing spondylitis as young men and aortic lesions some years later.

It is of some interest that this complication developed in the two present cases at 7 and 12 years from the apparent onset. This compares with a duration of from 9 to 29 years in the Washington series. Both our patients showed a prolonged P-R interval and this has been present in five out of six of the Washington series and in six of the Boston series.

The incidence of this complication seems to be low. Thus, in a study of 530 patients at a spondylitis clinic, Sharp (1957) mentions patients with rheumatic heart disease and patients with Jaccoud’s syndrome affecting the spine, but does not mention this aortic lesion. We ourselves in a follow-up and survey of 222 patients with ankylosing spondylitis (Wilkinson and Bywaters, *in press*) found only these two patients with lone aortitis, and two with rheumatic heart disease (mitral involvement) on clinical examination. This was with a mean follow-up period of 4.6 years and a mean duration of disease of about 12 years for the group as a whole. However, had we done the survey two years earlier we should have picked up neither of these two cases. This incidence is comparable to the figure given by Bernstein and Broch (1949): in 292 cases they found three with

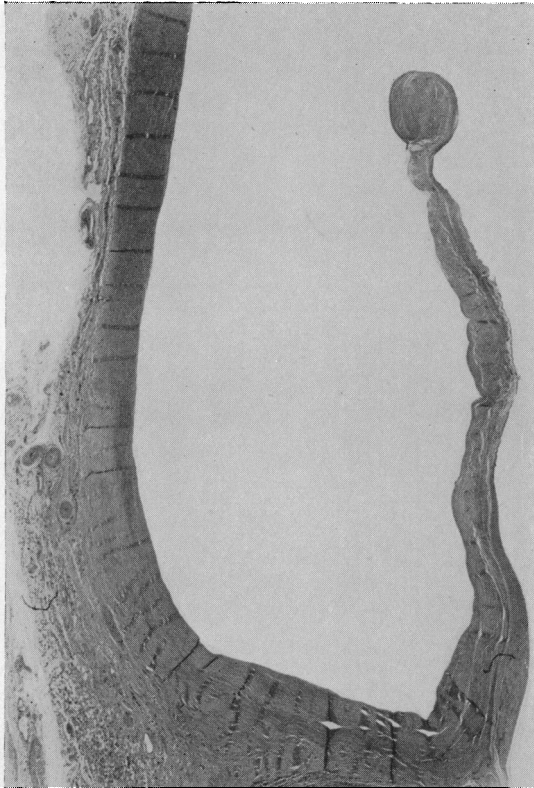


FIG. 6.—Section of aortic valve, showing gross collagenous thickening of the cusp and ring. H. & E.  $\times 8$ .

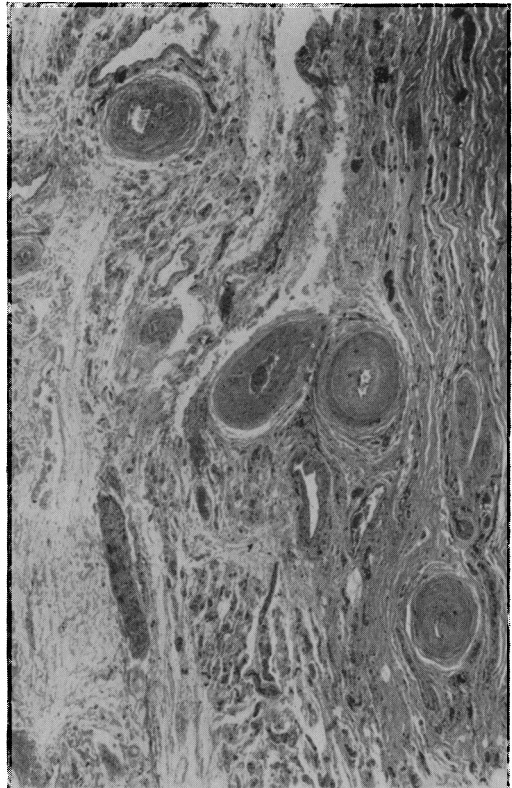


FIG. 7.—Epicardium over root of aorta. The vasa vasorum of the adventitia of the root of the aorta show striking intimal thickening. H. & E.  $\times 57$ .

aortic regurgitation alone. Three more also had aortic stenosis and four had mitral stenosis (two with aortic regurgitation). There seems to be no reason why the large anterior leaf of the mitral valve should not be involved in contiguity as it sometimes is in syphilis, and indeed MacMahon *et al.* (1955) have described such a case. It should not however give rise to mitral stenosis, nor to much in the way of regurgitation.

The significance of this lesion is uncertain: it does not seem likely that patients with ankylosing spondylitis fail to develop a positive Wassermann and Kahn or *Treponema pallida* immobilization after infection with *T. pallida*, since when syphilis was more common, many such patients gave positive reactions. Thus Fletcher (1947) found positive tests in four of seventy patients. We do not think that our patients had Reiter's disease. Moreover, there is no relation to post-irradiation fibrosis, as our second case had no radiotherapy. Aortic scarring and vessel changes have been described in rheumatic heart disease (Shaw, 1929), but there was neither clinical nor pathological evidence for this. The lesion appears to be quite different from the aortic or mitral valve deformities associated with rheumatoid granulomata.

We must, therefore, agree with Bauer and his colleagues that this is a specific lesion and related in some way to the connective tissue changes that affect the central and peripheral joints in ankylosing spondylitis. It is well known that the aorta is rich in chondroitin sulphate, elastin, and collagen fibres, as are joint tissues, but we are not yet able to point to the component or components involved nor to the manner of its involvement. By analogy with the histological change of syphilitic aortitis, the localization of lesions may be related to the vascular supply.

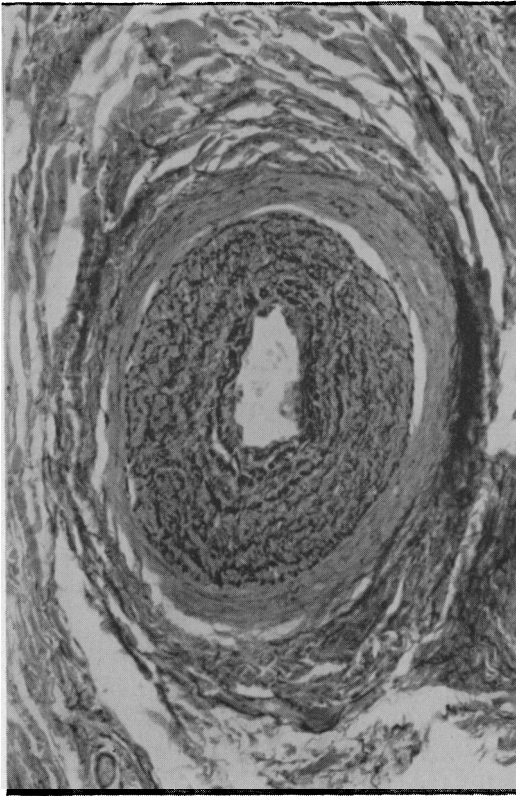


FIG. 8.—Section of artery from adventitia of root of aorta, showing irregular musculo-elastic fibre formation within the intima. Weigert's elastic and Van Gieson  $\times 185$ .

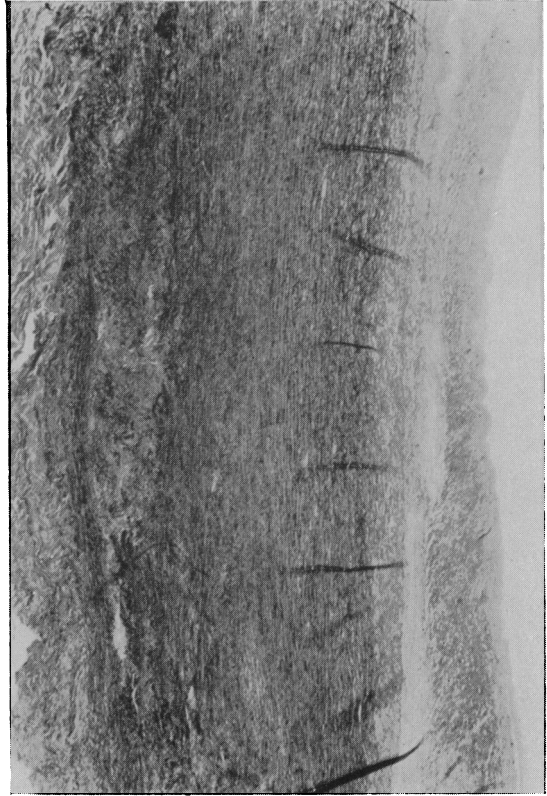


FIG. 9.—Aorta of which the adventitia (to left) and intima (to right) of the aorta are thickened; the elastic fibres of the media are interrupted by fibrous scar tissue in an irregularly shaped focus near the adventitia. Verhoeff's elastic  $\times 57$ .

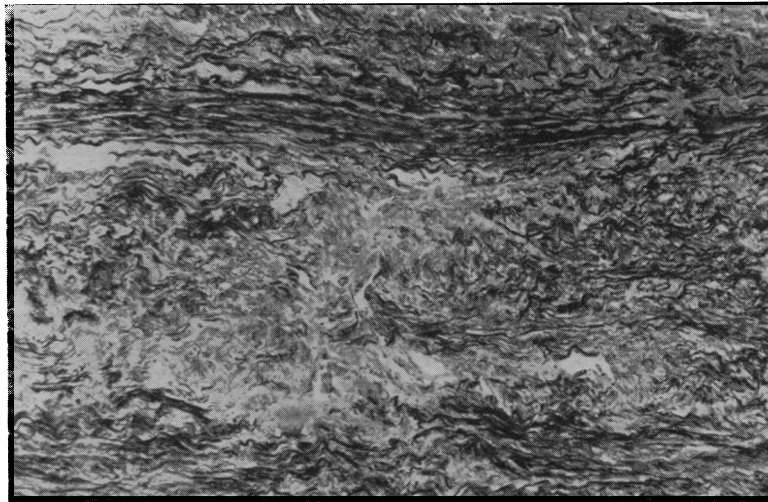


FIG. 10.—High power of Fig. 9, showing medial scar, due to focal interruption of the elastica by collagen. Verhoeff's elastic  $\times 95$ .



## SUMMARY

Two patients with lone aortic disease, a prolonged P-R interval, and ankylosing spondylitis are described. One had congestive failure, from which he died, and histological study showed fibrotic lesions in the aortic valve cusps and in the aorta, similar to those described by Bauer and his colleagues. In both, the Wassermann, Kahn, *Treponema* immobilization and Price precipitation tests were negative. These two were the only cases found in a survey of 222 patients followed up for a mean period of 4-6 years.

We are grateful to Dr. Cope and other colleagues at the Postgraduate Medical School for some of the data on these patients, and to the Venereal Disease Reference Laboratory, Director, Dr. I. N. Orpwood-Price, for the specific tests.

## REFERENCES

- Bauer, W., Clark, W. S., and Kulka, J. P. (1951). *Ann. rheum. Dis.*, **10**, 470.  
Bennett, G. A. (1951). In discussion on Bauer, W., Clark, W. S., and Kulka, J. P. (1951).  
Bernstein, L., and Broch, O. J. (1949). *Acta. med. Scand.*, **135**, 185.  
Bywaters, E. G. L. (1950). *Brit. Heart J.*, **12**, 101.  
Clark, W., Kulka, J. P., and Bauer, W. (1957). *Amer. J. Med.*, **22**, 560.  
Fletcher, E. (1947). *Medical Disorders of the Locomotive System*. Edinburgh.  
MacMahon, H. E., Magendantz, H., Brugsch, H. G., and Patterson, J. F. (1955). *Bull. Tufts New Engl. Med. Center*, **1**, 50.  
Schilder, D. G., Harvey, W. P., and Hufnagel, C. A. (1956). *New Engl. J. Med.*, **255**, 11.  
Sharp, J. (1957). *Brit. med. J.*, **1**, 975.  
Shaw, A. F. B. (1929). *Arch. Dis. Child.*, **4**, 155.  
Thomas, A. E. (1955). *Ann. rheum. Dis.*, **14**, 259.  
Wilkinson, M., and Bywaters, E. G. L. (1958). In press.  
Zellmann, H. E. (1954). *Amer. J. Syph.*, **38**, 506.