

Meningioma after contralateral hemispherectomy for malignant glioma: case report

P. J. E. WILSON AND D. J. B. ASHLEY

*From the Departments of Surgical Neurology and Pathology,
Morriston Hospital, Swansea*

SYNOPSIS A patient is described who successfully underwent cerebral hemispherectomy for malignant glioma and whose death nine months later, wrongly ascribed to recurrent malignancy, was in fact due to a subsequently-developing benign meningioma in the remaining hemisphere. The possible advantages of a modification of standard hemispherectomy technique are also discussed.

Although the occasional concomitance of intracranial glioma with meningioma is well known, the following case is reported in detail because of unusual features in the diagnosis and management.

CASE REPORT

Mr D.B. (MH 31189/70) a married, right-handed shipping-clerk aged 33 years, was first referred to Dr

(Accepted 24 December 1974.)

B. M. Phillips, consultant neurologist, with a history of epilepsy for the preceding 11 days.

The patient had been perfectly well until the night of 10 February 1970 when he suffered a nocturnal tonic seizure, witnessed by his wife, but for which he himself was amnesic. A week later, while walking in the street, he had sudden pain in the left foot spreading to involve the entire left side of the body; he fell to the ground, but did not convulse or lose consciousness, and was not incontinent. A similar attack occurred on the day of referral, 21 February 1970.

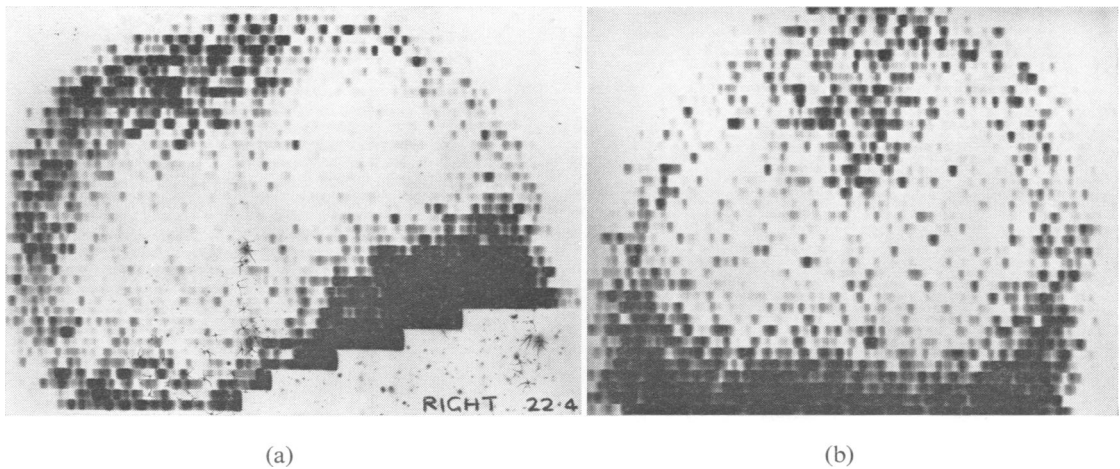


FIG. 1 Rectilinear brain scan on 22 April 1970, one month before right hemispherectomy. (a) Right lateral view, showing a diffuse area of increased isotope uptake in the parietal region. (b) Anteroposterior view, showing that the increased isotope uptake is parasagittal and right-sided.

Physical examination, skull radiographs, and EEG were all entirely normal.

During March 1970 he began to have increasingly frequent and severe headaches, and experienced several brief episodes of painful stiffness and paraesthesiae in the left foot, sometimes also affecting the left hand, and accompanied by an insidious left hemiparesis.

On readmission to hospital on 16 April 1970 (again under the care of Dr B. M. Phillips), he was alert, of normal intelligence, with no papilloedema or meningism, but had dense flaccid left hemiparesis and left-sided sensory impairment. An EEG now recorded persistent low-amplitude activity in the theta and delta ranges from the right parietal leads. Right carotid angiography by Dr A. M. Jones on 20 April 1970 showed deviation of the pericallosal arteries 6 mm to the left of the midline, but gave no definite localizing information. Brain scan on 22 April 1970, using ^{99m}Tc , showed a poorly-defined zone of increased uptake in the right parietal parasagittal region (Fig. 1). On 28 April 1970, lumbar puncture yielded xanthochromic CSF containing protein 65 mg/dl but only 4 red cells and 3 white cells per mm^3 . He thereafter became insidiously more inattentive and inert, and showed neck rigidity, but his headaches and hemiparesis were unchanged. On 9 May 1970, carotid angiography was repeated, showing that the pericallosal shift had increased to

14 mm, but again no abnormalities of localizing value were demonstrated.

On 12 May 1970 he became frankly stuporose and acute bilateral papilloedema was observed. Dexamethasone 5 mg intramuscularly every six hours restored almost full alertness, and he was then referred to one of us (P.J.E.W.) on 13 May 1970. The same day, cerebral biopsy via a right parietal burr-hole yielded necrotic fragments of astrocytic glioma, grade II–III. On 14 May 1970, despite continued high doses of corticosteroids, he relapsed into stupor. Accordingly, emergency right lateral craniotomy was performed. The brain was extremely tense, and the pre-central parasagittal convolutions were partly replaced by soft pinkish tumour. All visible tumour tissue was excised. The resulting brain cavity exposed the full depth of the falx and measured roughly $7 \times 4 \times 4$ cm. The surrounding brain was quite slack, but biopsy showed that tumour extended into it beyond the anterior limit of the resection. The exposed falx looked normal.

The patient recovered promptly to a state of full alertness. His hemiplegia showed no change. Because the criteria for radical surgery seemed to be satisfied (*vide infra*), the question of cerebral hemispherectomy was discussed with both the patient and his relatives, who agreed to the procedure and all its implications.

On 22 May 1970, the right cerebral hemisphere was removed in one block. The line of section was

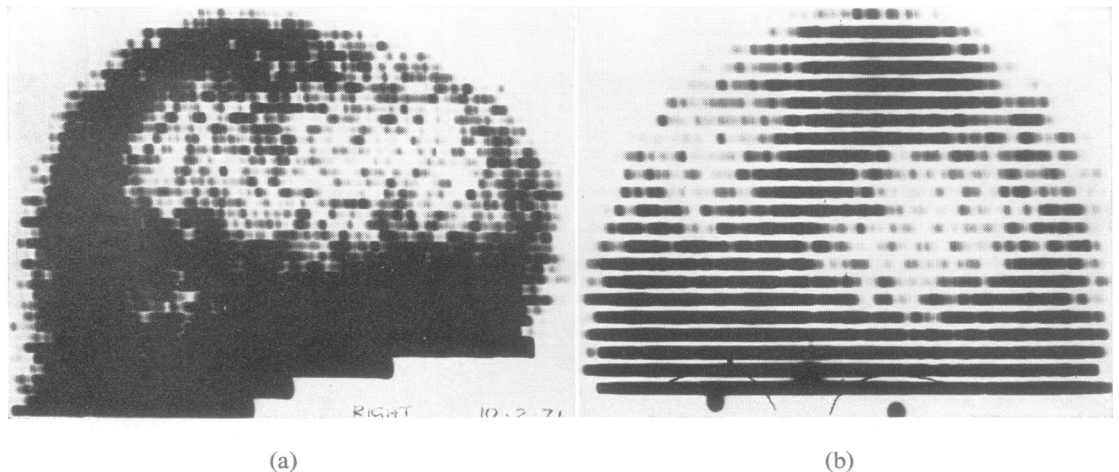


FIG. 2 Rectilinear brain scan on 10 February 1971, nine months after right hemispherectomy. (a) Right lateral view, showing an area of abnormal isotope uptake of similar position, pattern, and density to that on the pre-operative scan. (b) Anteroposterior view, showing a general increase of isotope uptake in the right hemicranium and a dense circumscribed uptake in the left parasagittal region. This appearance is, in retrospect, consistent with meningioma.

extrathalamocaudate, mesial temporal structures being left undisturbed. The ipsilateral choroid plexus was coagulated. The septum pellucidum was not fenestrated. The calvarial dura mater was folded into the right hemicranial cavity and sutured to the free edge of the falx and tentorium so as to obliterate the potential subdural space and 'screen' the third ventricle. (These important departures from standard hemispherectomy technique will be discussed below). Detailed examination of the resected hemisphere was somewhat hampered by the effects of operative venous infarction but showed that the remaining tumour was everywhere contained within a generous margin of normal brain.

The patient's postoperative recovery was rapid and smooth. He sat out of bed on the third day and was able to walk with help on the tenth day. Slight

euphoria, fatuity, and social disinhibition were noted at times. Psychometric assessment on 29 June 1970 gave him verbal-scale IQ 126, performance-scale IQ 61 (WAIS). On 14 August 1970 he was allowed home. He was able to walk with the aid of a stick and a toe-raising device, but had virtually total spastic monoplegia and sensory loss in the left arm. There was a complete left homonymous hemianopia.

Intensive physical and occupational rehabilitation enabled him to return to part-time work in his previous job at the shipping agency, to which he would travel by public transport. His fatuity resolved, but his family commented that he was more irritable, more self-centred, and less judicious than before.

He progressed well until January 1971, when he noticed increasing difficulty in walking due to stiff-

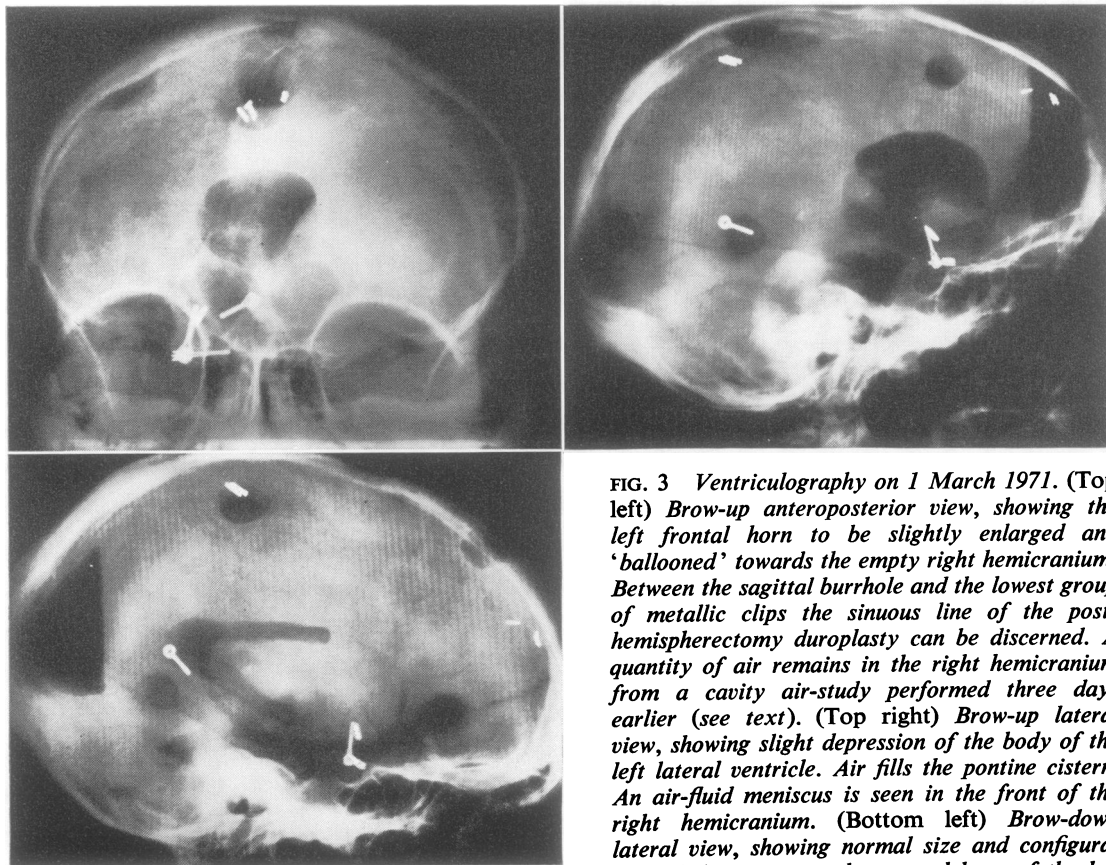


FIG. 3 *Ventriculography on 1 March 1971. (Top left) Brow-up anteroposterior view, showing the left frontal horn to be slightly enlarged and 'ballooned' towards the empty right hemicranium. Between the sagittal burrhole and the lowest group of metallic clips the sinuous line of the post-hemispherectomy duroplasty can be discerned. A quantity of air remains in the right hemicranium from a cavity air-study performed three days earlier (see text). (Top right) Brow-up lateral view, showing slight depression of the body of the left lateral ventricle. Air fills the pontine cistern. An air-fluid meniscus is seen in the front of the right hemicranium. (Bottom left) Brow-down lateral view, showing normal size and configuration of the trigone and temporal horn of the left*

lateral ventricle. The fourth ventricle has filled with air spontaneously, and is also normal in size, shape, and position. The right hemicranial air-fluid meniscus has moved freely to the back of the head.

ness and dragging of the 'good' right leg. When re-admitted to hospital on 6 February 1971, he was alert and rational, not dysphasic, and had normal optic fundi. The postoperative left hemiplegia was unchanged, but there was global spastic monoparesis of the right leg, sensation in that limb being normal. An EEG showed low-voltage activity over the right hemicranium, presumably transmitted from the left, and a non-focal increase of slower frequencies over the left hemicranium. Repeat brain scan on 10 February 1971 showed a dense but ill-defined area of increased uptake in the *left* central parasagittal region, almost a mirror-image of the preoperative scan (Fig. 2). Left carotid angiography showed bowing of the pericallosal artery 21 mm to the right of the midline, but no area of pathological circulation or other vascular displacements could be seen. On 26 February 1971 the right hemicranial cavity was punctured and clear watery yellow fluid at normal pressure was obtained (protein 7.2 g/dl, RBC nil, WBC 32 per mm³, mostly lymphocytes). Filtered air (30 ml) was injected into the cavity but none of this could be induced to enter the remaining ventricles. On 1 March 1971, via a left coronal burr-hole, pneumoventriculography was performed. The left lateral ventricle contained clear colourless CSF. There was a smooth depression and narrowing of the body of the ventricle, suggesting the presence of a parasagittal mass (Fig. 3). It was felt unlikely that the mass could be anything other than a glioma recrudescence across the corpus callosum, and a cannula biopsy on 8 March 1971 appeared to confirm this view: material from the left hemisphere was reported by one of us (D.J.B.A.) as follows: 'There

is extensive gliosis. There is one small area in which there is protoplasmic astrocytoma'.

Further surgery seemed unwarrantable in the circumstances. Radiotherapy was considered but rejected. The patient showed a gradual decline into coma and double hemiplegia, punctuated by several grand mal seizures. He died on 30 May 1971.

Necropsy was performed by one of us (D.J.B.A.) two days after death.

The right cerebral hemisphere had been removed surgically and the dura mater of the vault had been folded medially and sutured to the dura mater of the tentorium, and falx. Clear yellowish fluid occupied the space between the dura mater and the inner table of the skull, and the transposed dura mater was adherent to the remaining brain. The left cerebral ventricle was compressed, and there were a few minute granulations in its ependymal lining.

A firm rounded tumour roughly 3 cm in diameter was embedded in the medial surface of the left parietal parasagittal cortex, and had its origin from the adjacent falx (Fig. 4). Histological examination showed this tumour to be a fibrous meningioma of typical and benign appearance. Multiple sections of the brain substance showed gliosis round the meningioma. (It is probably from this zone that the misleading biopsy was taken). No gross or microscopic evidence of persistent glioma was found in the remainder of the brain. Sections of the wall of the ventricle showed no ependymitis.

There was no noteworthy arachnoiditis and no macroscopic staining of the surface of the brain by iron-containing pigments.

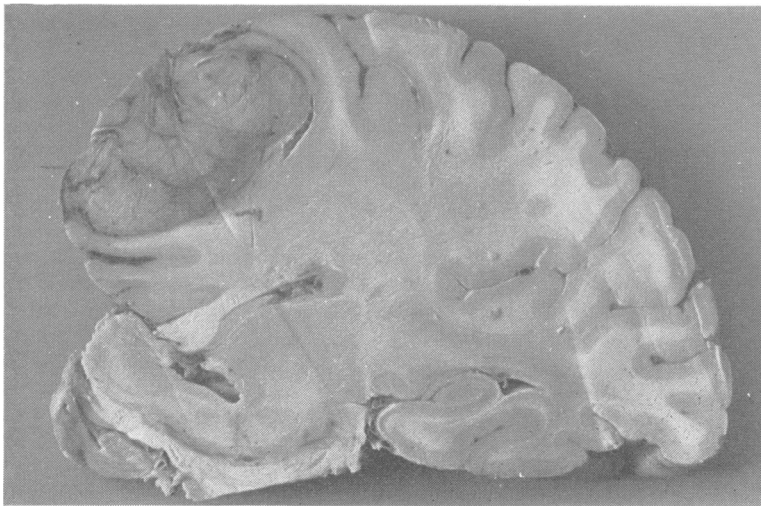


FIG. 4 *Coronal section of the left cerebral hemisphere, upper mid-brain and right basal ganglia. The left hemisphere is swollen. An ovoid extrinsic tumour with a whorled cut surface has invaginated the parasagittal and parafalcine cortex. The left lateral ventricle is of normal cross-section,[†] but the third ventricle is slightly dilated. A shrunken remnant of the right hippocampus can be seen. (The specimen has become somewhat distorted during fixation.)*

DISCUSSION

This patient had two intracranial tumours, of different types, separated both spatially and anatomically. That on the right side, treated by radical surgery, was an intrinsic astrocytoma of fibrillary and protoplasmic type, parts of it being Kernohan's grade II (relatively benign) whereas other areas were grade III (somewhat more malignant). The tumour on the left side was a typical benign fibrous meningioma.

Madonick *et al.* (1961) found that meningioma and glioma was the commonest combination of multiple diverse primary intracranial tumours.

Russell and Rubinstein (1971) record five instances of this association which they had themselves observed. O'Connell (1961) reported four patients who had meningiomas in conjunction with other central nervous system tumours: in one case, cranial and spinal meningiomas; in one case, meningioma and chromophobe pituitary adenoma; in one case, meningioma and acoustic neuroma; and in one case, meningioma and astrocytic glioma. A recent monograph based on McKissock's personal series of 916 parasagittal and falx meningiomas includes one instance (case 130) of astrocytic glioma of the cerebellum in association with a parietal parasagittal meningioma (Gautier-Smith, 1970). If we exclude the various phakomatoses—notably, von Recklinghausen's disease—such combinations of different types of primary intracranial tumour are probably more common than is actually recorded in the literature; one of us (D.J.B.A.), with a much smaller personal experience than Russell and Rubinstein, has encountered four cases, three of concomitant meningioma and glioma, and one of concomitant meningioma and acoustic neuroma.

In most instances, the two tumours have been spatially or anatomically separated. It is thus difficult to conceive of a common local oncogenic stimulus. One could postulate loosely that the presence of one intracranial tumour may in some way alter the environment of other parts of the brain and thereby lead possibly to a situation in which cells are more easily stimulated into new growth. Our patient did not receive radiotherapy, but had he done so it would have been necessary to consider whether ionizing

radiations may have induced a neoplastic propensity in mesodermal tissues. Norwood *et al.* (1974) describe two examples of benign convexity meningioma presenting 25 and 15½ years after irradiation for optic nerve glioma and hind-brain glioma respectively. Munk and his colleagues (1969) reported one presumed and four proved examples of meningioma occurring in patients whose skulls had been irradiated for ringworm. McKissock's case, already mentioned, had had radiotherapy for his cerebellar astrocytoma 15 years before the onset of symptoms attributable to his meningioma (Gautier-Smith, 1970). Examples of *glioma* after radiotherapy seem to be very rare. Butler and Netsky (1973) averred that none had yet been documented in man. However, one such case is described by Jones (1960), without comment as to any possible link between irradiation and oncogenesis. This was a patient who had a lesion-dose of 4 000 *r* to an inoperable angio-blastic meningioma of the left frontal region, and died 10 years later from an astrocytoma of the opposite hemisphere, the original meningioma having regressed and become psammomatous.

The ideal treatment for malignant cerebral glioma is total surgical extirpation with a wide margin of uninvolved but dispensable brain-tissue. In practice, it is rare for this ideal to be approached except at the risk of crippling neurological sequelae. Even more rarely can the neurosurgeon feel justified in offering his patient a reasonable guarantee of cure at the bitter price of deliberately incurring an irrevocable neurological deficit.

However, since Dandy's first reports nearly half a century ago, cerebral hemispherectomy (the ultimate weapon of radical brain surgery), has from time to time been employed, with a proportion of good long-term results (Dandy, 1928; Bell and Karnosh, 1949; Gardner, 1954; Gardner *et al.*, 1955).

The indications for this severe procedure in the treatment of glioma are not absolute, but many surgeons would accept the following: the tumour should be proven low-grade glioma superficially-placed in the Rolandic area of the non-dominant hemisphere in a young patient of good intelligence and pre-morbid personality, who has a stable domestic background, an

adaptable occupation, can rely upon full resources for physical and mental rehabilitation, and who already has an established and irreversible hemiplegia.

The initial result in our patient was encouraging. Despite a severe fall-off in performance scale sub-tests he was able to return to paid clerical work, and achieved a near-normal measure of personal independence. The less tangible psychological legacies of hemispherectomy, stressed by Gardner *et al.* (1955) were present, but not to a distressing or disabling degree.

When, some eight months after hemispherectomy and despite the histological evidence of complete removal of tumour, the patient developed progressive symptoms and signs implicating the remaining hemisphere, it seemed that the most likely explanation was a recrudescence of the original glioma via the corpus callosum into the contralateral Rolandic area. Investigations were all in ostensible support of this assumption, and the possibility of an independent benign lesion was not seriously considered, especially after biopsy was construed as positive for glioma. In retrospect, the biopsy cannula had merely skirted the meningioma but not sampled it.

The postmortem appearances make it clear that, had the meningioma been successfully biopsied, its total removal would have presented less technical difficulty than usual, by a transfalcal approach through the empty right hemisphericum. The clinical outcome should then have been a happier one. The commonest cause of morbidity and later mortality after hemispherectomy (for whatever indication) is chronic subdural haemorrhage into the hemisphericum, resulting in granular ependymitis, obstructive or communicating hydrocephalus, and—in a few cases—subpial haemosiderosis of the brain and spinal cord (Griffith, 1967; Falconer and Wilson, 1969; Wilson, 1970). Many early descriptions of this sequence of events were published in great detail before their pragmatic implications were realized. Not only is this syndrome of delayed intracranial haemorrhage treatable, it should be largely or entirely preventable. In the case now reported, a deliberate modification of the standard hemispherectomy technique was employed. It has been customary, after removal of

the hemisphere, to fenestrate the septum pellucidum and to coagulate and excise the remaining choroid plexus, with the idea of preventing brain-stem shift in the immediate post-surgical phase (Cabieses *et al.*, 1957) and of minimizing the development of hydrocephalus in the later convalescent period (McKissock, 1953). This step in the technique may do more harm than good, because it enables the large, potentially blood-filled subdural cavity to drain unimpeded into the ventricular and subarachnoid CSF pathways. The basic dangers of such a 'sump' effect have long been recognized in other surgical contexts (Finlayson and Penfield, 1941), and the term 'acute postoperative aseptic leptomeningitis' was coined to describe the stormy course that often follows such a situation. The modification used in the present case was to screen the ventricular system from the operative cavity by folding the vault dura mater down into it and suturing it firmly to the falx, tentorium, and basal dura mater. The patient's surgical convalescence was very smooth, without pyrexia, meningism, or headache. Although (extradural) cavity puncture eight months after operation yielded yellow and highly proteinaceous fluid, the ventricular CSF at that time was in striking contrast, being clear and colourless, with a protein level of only 80 mg/dl, WBC 1 per mm³, RBC 1 600 per mm³ (the latter probably of traumatic origin). No neuropathological evidence of significant ependymitis or arachnoiditis was found when the brain was examined after fixation.

We feel that our failure to suspect a benign nature in the second tumour, compounded by misinterpretation of the biopsy from brain tissue close to the meningioma, determined the fatal outcome. It is worth keeping in mind the possibility of a second and different tumour when a patient with a known intracranial neoplasm develops symptoms indicative of recurrence, especially if these symptoms suggest an unusual mode of recrudescence or spread.

REFERENCES

- Bell, E., Jr, and Karnosh, L. J. (1949). Cerebral hemispherectomy. Report of a case ten years after operation. *Journal of Neurosurgery*, 6, 285–293.
- Butler, A. B., and Netsky, M. G. (1973). Classification and biology of brain tumors. In *Neurological Surgery*, vol. 3,

- pp. 1297-1339. Edited by J. R. Youmans. Saunders: Philadelphia.
- Cabieses, F., Jeri, R., and Landa, R. (1957). Fatal brain-stem shift following hemispherectomy. *Journal of Neurosurgery*, **14**, 74-91.
- Dandy, W. E. (1928). Removal of right cerebral hemisphere for certain tumors with hemiplegia. Preliminary report. *Journal of the American Medical Association*, **90**, 823-825.
- Falconer, M. A., and Wilson, P. J. E. (1969). Complications related to delayed hemorrhage after hemispherectomy. *Journal of Neurosurgery*, **30**, 413-426.
- Finlayson, A. I., and Penfield, W. (1941). Acute postoperative aseptic leptomeningitis. Review of cases and discussion of pathogenesis. *Archives of Neurology and Psychiatry (Chic.)*, **46**, 250-276.
- Gardner, W. J. (1954). Removal of cerebral hemisphere for glioma. *Proceedings, 5th International Congress of Neurologists, Lisbon, 1953*, vol. 4, pp. 307-313. Lisbon.
- Gardner, W. J., Karnosh, L. J., McClure, C. C., Jr, and Gardner, A. K. (1955). Residual function following hemispherectomy for tumour and for infantile hemiplegia. *Brain*, **78**, 487-502.
- Gautier-Smith, P. C. (1970). *Parasagittal and Falx Meningiomas*. Butterworths: London.
- Griffith, H. B. (1967). Cerebral hemispherectomy for infantile hemiplegia in the light of the late results. *Annals of Royal College of Surgeons of England*, **41**, 183-201.
- Jones, A. (1960). Supervoltage x-ray therapy of intracranial tumours. *Annals of Royal College of Surgeons of England*, **27**, 310-354.
- McKissock, W. (1953). Infantile hemiplegia. *Proceedings of the Royal Society of Medicine*, **46**, 431-434.
- Madonick, M. J., Shapiro, J. H., and Torack, R. M. (1961). Multiple diverse primary brain tumors: report of a case and review of literature. *Neurology (Minneap.)*, **11**, 430-436.
- Munk, J., Peyser, E., and Gruskiewicz, J. (1969). Radiation induced intracranial meningiomas. *Clinical Radiology*, **20**, 90-94.
- Norwood, C. W., Kelly, D. L., Jr, Davis, C. H., Jr, and Alexander, E., Jr (1974). Irradiation-induced mesodermal tumors of the central nervous system: report of two meningiomas following x-ray treatment for gliomas. *Surgical Neurology*, **2**, 161-164.
- O'Connell, J. E. A. (1961). Intracranial meningiomata associated with other tumours involving the central nervous system. *British Journal of Surgery*, **48**, 373-383.
- Russell, D. S., and Rubinstein, L. J. (1971). *Pathology of Tumours of the Nervous System*, 3rd edn. Arnold: London.
- Wilson, P. J. E. (1970). Cerebral hemispherectomy for infantile hemiplegia. A report of 50 cases. *Brain*, **93**, 147-180.