

# Scapulo-peroneal atrophy with sensory involvement: Dauidenkow's syndrome

M. S. SCHWARTZ AND M. SWASH

*From the Section of Neurological Sciences, The London Hospital, London*

**SYNOPSIS** A patient with scapulo-peroneal atrophy of neurogenic type, in whom there was also distal sensory impairment, has been studied with conventional EMG, single fibre EMG, and muscle biopsy. This disorder, described by Dauidenkow, may be a distinct entity.

In 1939 Dauidenkow described 13 patients, all but one familial, in whom weakness of scapulo-peroneal distribution, often also affecting the face, was associated with distal sensory loss in the limbs and, usually, with pes cavus. None of the subsequent reports of patients with scapulo-peroneal weakness has included cases with distal sensory loss (*cf.* Thomas *et al.*, 1972) and these reports have generally been concerned with the establishment of myopathic and neurogenic forms of the 'scapulo-peroneal syndrome' (Kaeser, 1965; Ricker and Mertens, 1968; Ricker *et al.*, 1968; Meadows and Marsden, 1969; Feigenbaum and Munsat, 1970). Wilson (1940) suggested that Dauidenkow's patients were suffering from an unusual form of Charcot-Marie-Tooth disease, but Ricker and Mertens (1968) have recently refuted this suggestion.

We have studied a patient similar in most respects to Dauidenkow's (1939) cases. In this report we shall describe our clinical, histological, and electrophysiological findings, including single fibre electromyography, and shall suggest that Dauidenkow's syndrome, although rare, may be a distinct and recognizable disorder.

## CASE REPORT

A 27 year old Sudanese Arab student presented complaining of increasing weakness. He had first become aware of weakness about 14 years previously and had noticed a gradual deterioration since then. He had particularly noticed that he tended to trip easily, that his arms were weak, and, more recently,

that he could no longer easily rise from a low chair without using his arms. During the last three years he had also become aware of weakness of grip and of numbness of his fingers and feet, so that he had difficulty in recognizing objects by palpation, and could not feel his shoes. There was no family history of neuromuscular disease.

On examination he was a tall thin man. There was weakness and atrophy in a proximal distribution in the upper limbs, and in a distal distribution in the legs, although the neck muscles, deltoids, and extensor digitorum brevis muscles were virtually uninvolved. The triceps, biceps brachii, periscapular muscles, peronei, and tibialis anterior were particularly severely affected. There was only mild weakness of quadriceps femoris, of hip flexion and extension, and of the forearm and intrinsic hand muscles. There was mild bilateral facial weakness but the other cranial musculature was normal. Fasciculation was not observed. Perception of light touch, position sense, vibration sense, and of pin-prick and temperature was impaired in a symmetrical glove and stocking distribution. All the tendon reflexes were absent but the pupils were normal. The peripheral nerves were not thickened. The general examination was normal.

Routine biochemical, haematological, and radiographic investigations were normal. There was no glycosuria and the ESR was normal. The lumbar CSF was clear and colourless and contained 0.70 g/l protein, and one lymphocyte  $\text{mm}^{-3}$ . The creatine phosphokinase was 244, 315, and 248 IU/l on three occasions (normal: less than 100 IU/l). The electrocardiogram was normal. Electromyography and muscle biopsy were performed.

**ELECTROPHYSIOLOGICAL STUDIES** *Methods* Routine EMG and nerve conduction velocity studies were

made with a DISA 14A21 two channel EMG apparatus, using DISA concentric needle electrodes. Single fibre EMG (SFEMG) was performed (Ekstedt, 1964; Ekstedt and Stålberg, 1973) using the same apparatus modified by increasing the low frequency filter range of one of the amplifiers from 50 Hz to 500 Hz. SFEMG potentials were displayed either on the oscilloscope of the DISA EMG apparatus or on a separate Telequipment DM64 oscilloscope. A DISA SFEMG electrode with two leading-off surfaces was used. The fibre density, defined as the mean number of muscle fibres belonging to a single motor unit recorded within the uptake area of the electrode during 20 electrode placements (Stålberg and Thiele, submitted for publication), and the neuromuscular jitter (Stålberg *et al.*, 1971) were particularly studied.

**Results** Motor and sensory nerve conduction velocities were:

	m/s	Distal latency (ms)
R peroneal nerve	41	7.2
R median nerve	40	5.2
R ulnar nerve	52	5.3

Sensory conduction velocity in the right sural nerve was 35 m/s and the median sensory latency was 4.9 ms.

Concentric needle EMG studies of the right and left biceps brachii, triceps, quadriceps femoris, tibialis anterior, peronei, abductor pollicis brevis, and first dorsal interosseous muscles were performed. In all these muscles there was increased insertional activity. There were prominent pseudomyotonic discharges in the biceps brachii and tibialis muscles. Fibrillation potentials and positive sharp

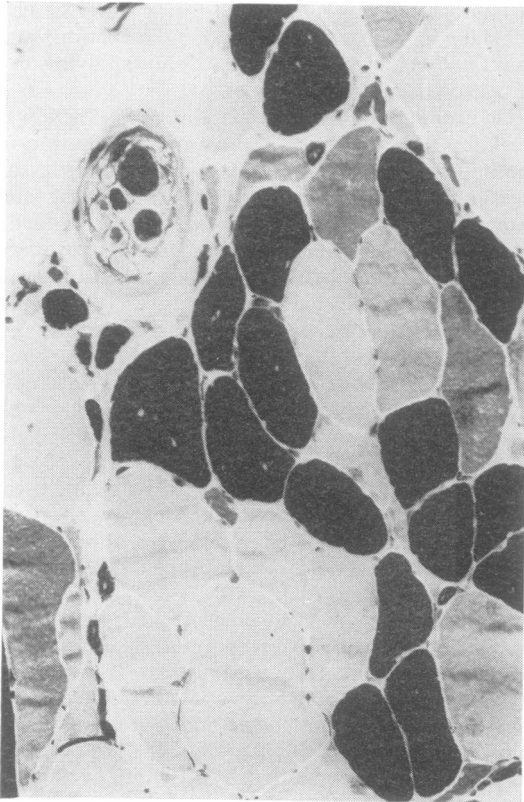


FIG. 1 *Fibre type grouping. There are groups of light and dark-staining fibres. The muscle spindle contains two large fibres and four smaller ones of varying histochemical type. ATPase (pH 4.3),  $\times 180$ .*

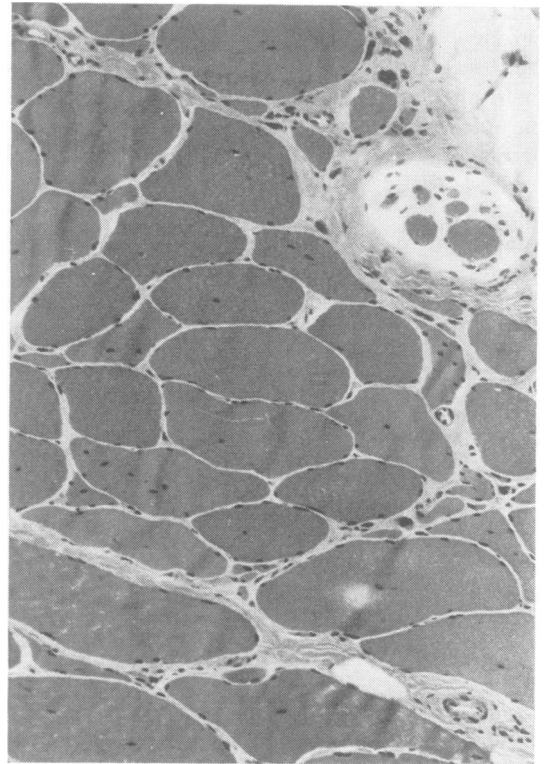


FIG. 2 *(Consecutive section to Fig. 1 rotated 90°.) Variability in fibre size with central nucleation. There are several groups of small, thin, pointed fibres. The periaxial space of the muscle spindle contains excess collagen, its capsule is thickened and the smaller (presumed nuclear chain fibres) are thinner than normal. Gomori trichrome,  $\times 180$ .*

waves were recorded in the biceps brachii, triceps, and tibialis anterior muscles bilaterally. On volition in the biceps, triceps, tibialis anterior, and quadriceps there were increased numbers of polyphasic motor unit potentials of normal or increased amplitude (maximum 9 mV) and increased duration. The interference pattern was moderately reduced in these muscles. These findings were consistent with a neurogenic disorder.

SFEMG showed increased fibre density in the biceps brachii (2.7) and tibialis anterior (3.5) muscles: normal <2.0. The complex single fibre action potentials in both muscles were relatively stable, without evidence of neuromuscular block. The jitter was not measured electronically but superimposition measurements showed some action potentials with increased jitter. The most complex motor unit potentials were found in tibialis anterior. These consisted of up to seven separate action potentials each representing a single fibre from the same motor unit, within the uptake area of the recording electrode: normal less than four (Stålberg *et al.*, 1975a). The duration of the longest such complex unit potential was 18 ms, which was slightly greater than normal (Stålberg *et al.*, 1975b).

**MUSCLE BIOPSY** The right biceps brachii muscle was biopsied, and the specimen was examined using conventional histological, enzyme histochemical, and electron microscopic techniques.

In the sections of the frozen material the fibre diameter varied from 4 to 160  $\mu\text{m}$ . Many of the smallest fibres were narrow and pointed. These fibres, which stained darkly for NADH tetrazolium reductase, were often arranged in small groups, consisting of three to seven fibres of identical histochemical type. In the sections stained for ATPase (pH 4.3) there were prominent groups of up to 20 fibres of uniform histochemical type, without fibre type preponderance (Fig. 1). Groups of pyknotic nuclear clumps marked the site of the smallest atrophic fibres. Central nuclei were found in 34% of fibres in the biopsy specimen (Fig. 2) and both histochemical fibre types, of all diameters, were affected. Some fibres contained sudanophilic lipid droplets and there were a few fibres in which the myofibrillar pattern appeared normal. With the electron microscope other, less severe, changes such as wide separation of myofibrils and focal degeneration of several sarcomeres of a single myofibril were found, but these ultrastructural changes were non-specific.

One muscle spindle, sectioned through one of its poles, was seen (Figs 1 and 2). There was an increased amount of collagen in the periaxial space and the intrafusal muscle fibres were smaller than normal. These appearances were considered con-

sistent with motor denervation (Swash and Fox, 1974).

#### DISCUSSION

It is clear from previous reports that weakness in a scapulo-peroneal distribution may occur in a number of different disorders (Ricker and Mertens, 1968). The familial form of scapulo-peroneal atrophy may be of neurogenic or myopathic type (Kaeser, 1965; Thomas *et al.*, 1972), but sporadic cases are more likely to be neurogenic (Ricker *et al.*, 1968; Feigenbaum and Munsat, 1970).

In emphasizing the various causes of weakness in a scapulo-peroneal distribution, Ricker and Mertens (1968) pointed out that 13 of their 30 cases of facioscapulo-humeral muscular dystrophy and 12 of their 47 cases of myotonic dystrophy had weakness in this distribution at some time in their illness. In our patient, these disorders could be excluded because the disorder was sporadic, both the EMG and histological evidence suggested a neurogenic cause, there was a marked distal sensory disturbance, and, in addition, the usual clinical features of myotonic dystrophy were absent.

Some of the clinical features in our patient, especially the distal sensory disturbance in the limbs and the distal weakness in the legs, were consistent with a diagnosis of Charcot-Marie-Tooth disease. However, Ricker and Mertens (1968) found that none of 63 patients with Charcot-Marie-Tooth disease had weakness in a scapulo-peroneal distribution, and Davidenkow (1939), in his description of scapulo-peroneal syndrome with distal sensory disturbance, stated that this disorder and Charcot-Marie-Tooth disease never occurred in the same family.

The clinical features in our patient were very similar to those reviewed by Davidenkow (1939), although the disorder occurred sporadically in only one of his patients, and pes cavus was absent in our case. Another minor difference is that in Davidenkow's patients the disease began after the age of 20 years but in our patient it began in childhood. Davidenkow (1939) noticed that the extensor digitorum brevis muscles were spared and this was so, also, in our patient. This is not a helpful point in diagnosis, however, since Thomas *et al.* (1972) observed the same

phenomenon in their cases of X-linked scapulo-peroneal weakness due to a myopathy. However, in the neurogenic form of scapulo-peroneal atrophy weakness is usually first noticed in the legs, in contrast with the myopathic form in which it begins in the shoulder girdle (Ricker and Mertens, 1968).

The distal sensory symptoms and signs in our patient were accompanied by slowed median and sural sensory nerve conduction velocities. The distal motor latencies were also increased and there was slowing of motor conduction velocity in the median nerve. There have been other reports of patients with scapulo-peroneal atrophy in whom there was slight slowing of motor nerve conduction velocity (Emery *et al.*, 1968; Feigenbaum and Munsat, 1970) but in these cases the distal latencies were normal and there were no sensory symptoms or signs. Pseudomyotonic discharges have not been reported previously in scapulo-peroneal atrophy, but this electromyographic abnormality can be found in longstanding denervation of any cause (Emeryk *et al.*, 1974). The SFEMG findings of increased muscle fibre density, unusually complex motor unit potentials and only slightly increased neuromuscular jitter indicate a chronic neurogenic disorder, with adequate functional collateral sprouting, in which little recent reinnervation has taken place (Stålberg *et al.*, 1975b). The muscle biopsy specimen showed grouped denervation atrophy with pyknotic nuclear clumps. Secondary myopathic changes were also present and these probably accounted for the moderate increase in the blood creatine phosphokinase levels. The degree of central nucleation was unusual, but this was not considered a specific finding.

The clinical, electromyographic, and histological evidence in our case is all consistent with a neurogenic disorder. An axonal degeneration secondary to disease both of anterior horn cells and of cells in the posterior root ganglia might explain the motor and sensory abnormalities, the absence of the tendon reflexes, and the slight increase in CSF protein, but it is difficult to account for the proximal distribution of neurogenic atrophy in the arms and the distal weakness in the legs on the basis either of a 'dying back' or a 'longest fibre' disorder. Recently, moreover, Jędrzejowska *et al.* (1974) have found histo-

logical abnormalities in the sural nerves of patients with the distal form of progressive muscular atrophy, in one of whom there was scapulo-peroneal involvement. Davidenkow (1939) did not examine the CSF in his patients.

Kaeser (1965), in his review of the scapulo-peroneal syndrome, found reports of 27 cases of Davidenkow's syndrome, including the 13 reviewed by Davidenkow (1939) himself. Twenty-six of these occurred in five families and one was sporadic. Wilson (1940) mentions patients with Charcot-Marie-Tooth disease in whom proximal weakness had been observed and, in view of Ricker and Mertens' (1968) observations it may be that these were really examples of Davidenkow's syndrome. Our case, with the electrophysiological and histological findings, provides some support for the concept that Davidenkow's syndrome of neurogenic scapulo-peroneal weakness associated with distal sensory impairment, may be a distinct disorder.

We thank the DISA Co. Ltd. for the loan of a prototype SFEMG electrode; and Professor P. K. Thomas, who brought Davidenkow's work to our notice, in a paper read to the Association of British Neurologists.

#### REFERENCES

- Davidenkow, S. (1939). Scapulo-peroneal amyotrophy. *Archives of Neurology and Psychiatry (Chic.)*, **41**, 694-701.
- Ekstedt, J. (1964). Human single muscle fiber action potentials. *Acta Physiologica Scandinavica*, **61**, suppl. 226, 1-96.
- Ekstedt, J., and Stålberg, E. (1973). Single fibre electromyography for the study of the microphysiology of human muscle. In *New Developments in Electromyography and Clinical Neurophysiology*, vol. 1, pp. 89-112. Edited by J. E. Desmedt. Karger: Basel.
- Emery, E. S., Fenichel, C. M., and Eng, G. (1968). A spinal muscular atrophy with scapulo-peroneal distribution. *Archives of Neurology (Chic.)*, **18**, 129-133.
- Emeryk, B., Hausmanova-Petrusewicz, I., and Nowak, T. (1974). Spontaneous volleys of bizarre high frequency potentials (bhfp) in neuromuscular diseases. Part 1: Occurrence of spontaneous volleys of bhfp in neuromuscular diseases. *Electromyography and Clinical Neurophysiology*, **14**, 303-312.
- Feigenbaum, A., and Munsat, T. L. (1970). A neuromuscular syndrome of scapulo-peroneal distribution. *Bulletin of the Los Angeles Neurological Society*, **35**, 47-57.
- Jędrzejowska, H., Lambert, E. H., and Dyck, P. J. (1974). The nature of the myelinated fiber degeneration in the distal form of progressive muscular atrophy. In *IIIrd International Congress on Muscle Diseases, Newcastle upon Tyne. Excerpta Medica International Congress Series*, no. 334, pp. 32-33. Excerpta Medica: Amsterdam.

- Kaesler, H. E. (1965). Scapulo-peroneal muscular atrophy. *Brain*, **88**, 407-418.
- Meadows, J., and Marsden, C. D. (1969). Scapulo-peroneal amyotrophy. *Archives of Neurology (Chic.)*, **20**, 9-12.
- Ricker, K., and Mertens, H. G. (1968). The differential diagnosis of the myogenic-(facio)-scapulo-peroneal syndrome. *European Neurology*, **1**, 275-307.
- Ricker, K., Mertens, H. G., and Schimrich, K. (1968). The neurogenic scapulo-peroneal syndrome. *European Neurology*, **1**, 257-274.
- Stålberg, E., Ekstedt, J., and Broman, A. (1971). The electromyographic jitter in normal human muscles. *Electromyography and Clinical Neurophysiology*, **31**, 429-438.
- Stålberg, E., Schwartz, M. S., Thiele, B., and Schiller, H. H. (1975a). The normal motor unit in man—a single fibre EMG multielectrode investigation. *Journal of the Neurological Sciences*. (In press.)
- Stålberg, E., Schwartz, M. S., and Trontelj, J. V. (1975b). Single fibre electromyography in disorders affecting the anterior horn cell. *Journal of the Neurological Sciences*, **24**, 403-415.
- Swash, M., and Fox, K. P. (1974). The pathology of the human muscle spindle: effect of denervation. *Journal of the Neurological Sciences*, **22**, 1-24.
- Thomas, P. K., Calne, D. B., and Elliott, C. F. (1972). X-linked scapuloperoneal syndrome. *Journal of Neurology, Neurosurgery, and Psychiatry*, **35**, 208-215.
- Wilson, S. A. K. (1940). *Neurology*, vol. 2, p. 1003. Edited by A. Ninian Bruce. Arnold: London.

## ADDENDUM

Since this communication went to press Kazakov *et al.* (1975) have followed up one of the families reported by Davidenkow (1939), and have suggested that this family's neuromuscular disorder was myopathic rather than neurogenic. However, needle EMG and sensory conduction velocities were not studied and muscle biopsy was not performed.

## REFERENCE

- Kazakov, V. M., Bogorodinsky, D. K., and Skorometz, A. (1975). Myogenic scapuloperoneal syndrome—muscular dystrophy in the K kindred. *European Neurology*, **13**, 350-359.