

REVIEW

**Bone and soft tissue sarcomas during pregnancy: A narrative review of the literature**  CrossMark

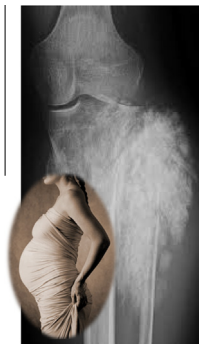**George Zarkavelis<sup>a</sup>, Dimitrios Petrakis<sup>a</sup>, George Fotopoulos<sup>b</sup>, Sotirios Mitrou<sup>c</sup>,  
Nicholas Pavlidis<sup>a,\*</sup>**

<sup>a</sup> Department of Medical Oncology, Ioannina University Hospital, 45110 Ioannina, Greece

<sup>b</sup> Department of Medicine, Sotiria General Hospital, Athens University, Athens, Greece

<sup>c</sup> REA Maternity Hospital, A. Sygrou Avenue, 383, P. Faliro, Athens, Greece

GRAPHICAL ABSTRACT



ARTICLE INFO

*Article history:*

Received 1 October 2015

Received in revised form 12 January 2016

ABSTRACT

Bone or soft tissue sarcomas are rarely diagnosed during pregnancy. Until today 137 well documented cases have been reported in the English literature between 1963 and 2014. Thirty-eight pregnant mothers were diagnosed with osteosarcoma, Ewing's sarcoma or chondrosarcoma,

\* Corresponding author. Tel./fax: +30 26510 99394.

E-mail address: [npavlid@uoi.gr](mailto:npavlid@uoi.gr) (N. Pavlidis).

Peer review under responsibility of Cairo University.



Production and hosting by Elsevier

<http://dx.doi.org/10.1016/j.jare.2016.01.003>

2090-1232 © 2016 Production and hosting by Elsevier B.V. on behalf of Cairo University.

This is an open access article under the CC BY-NC-ND license (<http://creativecommons.org/licenses/by-nc-nd/4.0/>).

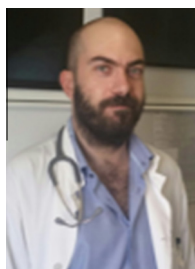
Accepted 13 January 2016  
Available online 2 February 2016

**Keywords:**

Cancer  
Pregnancy  
Bone sarcomas  
Soft tissue sarcomas

whereas 95 other cases of soft tissue sarcomas of various types have been documented. We present the clinical picture and therapeutic management of this coexistence.

© 2016 Production and hosting by Elsevier B.V. on behalf of Cairo University. This is an open access article under the CC BY-NC-ND license (<http://creativecommons.org/licenses/by-nc-nd/4.0/>).



**George Zarkavelis, MD**, is a fellow in Medical Oncology, Department of Medical Oncology, Ioannina University Hospital, Greece.



**Nicholas Pavlidis, MD, PhD, FRCP Edin**, is a Professor and Head of the Department of Medical Oncology, Ioannina University Hospital, Greece, and Member of Scientific Committee and Coordinator of Master classes of European School of Oncology; Member of Scientific Committee of ESMO/ASCO Global Curriculum; and Editor in Chief, Cancer Treatment Reviews.



**Dimitrios Petrakis, MD, PhD**, works as a Senior Oncologist, Department of Medical Oncology, Ioannina University Hospital, Greece



**George Fotopoulos, MD**, works as a Senior Oncologist, Department of Medicine, Sotiria Hospital, University of Athens, Greece.



**Sotirios Mitrou, MD**, works as a Senior obstetrician and gynecologist, REA Maternal Hospital, Athens, Greece

## Introduction

### *Cancer and pregnancy*

Cancer diagnosis during pregnancy is a rare coexistence in a ratio of one case per 1000 deliveries. However, there is an increasing trend due to delaying pregnancy in western societies into the later reproductive years [1].

The most common gestational cancers are those appearing during the reproductive period of a woman. Breast cancer and cervical cancers are the most frequently diagnosed malignancies followed by hematological tumors and melanoma [1].

Diagnostic and staging workup should be very carefully performed due to maternal and fetal radiation exposure. Recommendation of imaging studies should always follow the established guidelines [2].

Systemic chemotherapy should be avoided during the first trimester of pregnancy due to lethal, teratogenic or developmental malformation effects. However, during the second and third trimesters certain chemotherapeutic drugs can be administered. Hormonal and/or targeted treatments should not be advised. In addition, radiotherapy cannot be applied to the mother's trunk due to the lethal effects on the fetus [3,4].

Metastatic transmission to the products of conception happens rarely and the most frequent malignancies that invade placenta and fetus are melanoma (30%), cancer of unknown primary site (22.5%), hematological malignancies (15%), breast cancer (14%) and lung cancer (13%) [5].

### *Bone and soft tissue sarcomas [6]*

Malignant bone tumors are rare, accounting for only 0.2% of all malignancies. Among them the most frequent are osteosarcoma, Ewing's sarcoma and chondrosarcoma. Less frequent sarcomas are the malignant fibrous histiocytoma, chordoma, and very rarely liposarcoma, angiosarcoma, and hemangiopericytoma.

*Bone osteosarcoma*

It is the commonest primary bone tumor and occurs predominantly in adolescence with a peak incidence at the age of 15–19 years. Osteosarcoma most commonly involves long bones (mainly the tibia close to knee joint) and more rarely the axial skeleton. It presents with localized bone pain characteristically during the night or at rest. Limb-sparing surgery with extending endoprostheses is the treatment of choice. Adjuvant chemotherapy improves overall survival. In certain cases neoadjuvant chemotherapy can be used.

*Ewing's sarcoma*

It is part of the Ewing's sarcoma family including also the primitive neuroendocrine tumor and Askin's tumor. The median age is 14 years and tumor affects long bones or axial skeleton. Presenting symptoms are local pain, (deteriorating at night) as well as fever or weight loss. Systemic chemotherapy (neoadjuvant or adjuvant) is usually followed by local radiotherapy. In certain cases, surgery can be recommended following induction chemotherapy.

*Chondrosarcoma*

It is more commonly diagnosed over the age of 40. Most frequently it affects the pelvis, axial skeleton and proximal limbs. Histologic grading is important ranging from grade 1 to 3. The primary modality of therapy is surgery. Five-year survival is >90% and 25% for grade 1 and 3, respectively.

*Soft tissue sarcomas**Leiomyosarcoma*

The most common site of leiomyosarcomas is the retroperitoneum (50%), followed by abdominal viscera, uterus or extremities. Retroperitoneal leiomyosarcomas usually present with vague abdominal discomfort, abdominal mass or weight loss, while peripherally located primaries present with a painless enlarging mass. Surgery remains the dominant treatment. Chemotherapy has poor results in metastatic disease.

*Liposarcoma*

It affects adults between 40 and 60. It involves most commonly the thigh followed by abdominal cavity. Histologically, there are four types: well-differentiated, myxoid, pleomorphic and dedifferentiated liposarcoma. Prognosis is dependent on histologic type and site of disease.

*Rhabdomyosarcoma*

They arise from skeletal muscle cells. The most common locations are in the head and neck (40%), the genitourinary tract (25%) and the extremities (20%). The symptoms are associated with the tumor location. There are two main histologic types: the embryonic and the alveolar type.

*GIST (Gastrointestinal stromal tumors)*

GISTs are soft tissue mesenchymal tumors occurring in the gastrointestinal tract, originating in the interstitial cells of

Cajal. The annual incidence in UK ranges from 1.32 to 1.50 per 100,000 population which is equivalent to 800–900 new cases per year. The stomach (60%) and small intestine (30%) are the most common primary sites followed by duodenum (5%) and colorectum (5%). The most common symptoms are vague, nonspecific abdominal pain and discomfort. Rarely GI obstruction or bleeding could be seen.

Surgery is the primary treatment, whereas targeted therapy with tyrosine kinase inhibitors (imatinib, sunitinib or regorafenib) produced excellent results in both adjuvant and metastatic settings.

*Synovial sarcoma*

It can occur at any age but it is more common among teenagers and young adults. Most commonly it is located in the legs or arms. It is usually diagnosed as a slowly growing painless mass. Surgery followed by radiotherapy is the recommended treatment. Chemotherapy is advised in patients with metastatic disease.

*Kaposi's sarcoma*

Is a sarcoma caused by human herpesvirus 8. It is classified into four different forms: the classic, the endemic, the immunosuppression – associated and AIDS-associated Kaposi sarcomas. It involves the skin, mouth, GI tract and respiratory tract. In general, surgery is not recommended.

*Angiosarcoma*

It most commonly occurs in the skin, breast, liver, spleen and deep tissue. It can present as a skin lesion or a painless soft lump. Surgery is the primary therapeutic choice.

*Endometrial stromal sarcoma (EDS)*

EDSs are very rare malignant tumors that make up approximately 10% of uterine sarcomas but only around 0.2% of all uterine sarcomas. They can present by abnormal bleeding or spotting, vaginal discharge, pelvic pain or mass. Histologically, EDSs are divided into the following: (a) endometrial stromal nodule, (b) low-grade endometrial stromal sarcoma and (c) undifferentiated stromal sarcoma. Surgery with adjuvant radiotherapy is the recommended treatment. Five-year survival for early stage I is 54–100%, for stage II (30%) and for stage III–IV only 11%.

**Literature search***Bone sarcomas (Table 1)**Osteosarcoma*

In total 24 cases of various subtypes of gestational osteosarcomas have been reported since 1977. Osteoblastic, fibroblastic, chondroblastic, paraostal or high-grade osteosarcomas have been documented. The most common primary bone sites were thigh, pelvis and back, whereas the most frequent presenting symptoms were pain, detection of a mass or pathological fracture. Most patients were treated surgically either during

**Table 1** Bone sarcomas during pregnancy.

Histology	No of cases	% (all sarcomas) <sup>a</sup>	Period
Osteosarcoma [7–12]	24	17	1977–2012
Ewing's sarcoma [10,13–18]	19	14	1963–2012
Chondrosarcoma [9,10,19,20]	10	7	1989–2015

<sup>a</sup> Out of a total of 137 sarcomas reported.

**Table 2** Soft tissue sarcomas during pregnancy.

Histology	No of cases	% (all sarcomas) <sup>a</sup>	Period
Leiomyosarcoma [9,21–34]	17	12	1969–2010
Liposarcoma [10,29,35–43]	17	12	1993–2014
Rhabdomyosarcoma [10,44–56]	14	10	1969–2014
GIST (57–65) <sup>b</sup>	9	7	1996–2014
Synovial sarcoma [29,66–72]	9	7	2007–2014
Kaposi's sarcoma [73–80]	8	6	1971–2012
Angiosarcoma [9,81–83]	5	4	2004–2013
Endometrial stromal sarcoma [84–88]	5	4	2002–2014

<sup>a</sup> Out of a total of 137 sarcomas reported.

<sup>b</sup> Gastrointestinal stromal tumors.

pregnancy or postpartum and some patients received chemotherapy in an adjuvant setting during the postpartum period. Survival outcomes are similar to their nonpregnant counterparts [7–12].

#### *Ewing's sarcoma*

Since 1963 19 cases of gestational Ewing's sarcomas have been published in the English literature, including three cases of extra-skeletal Ewing's sarcoma. Almost all cases were diagnosed during pregnancy. Most cases were treated during pregnancy with chemotherapy, radiotherapy to the extremity and/or surgery and resulted in a favorable outcome for both mother and newborn. Only two patients underwent termination of pregnancy [10,13–18].

#### *Chondrosarcoma*

Only 10 cases of gestational chondrosarcomas appeared in the literature during the last 25 years. Primary tumors were located on iliac, innominate, tibial head and maxillary bones. One case was diagnosed as extraskeletal myxoid chondrosarcoma. Surgical intervention during pregnancy is not always feasible [9,10,19,20].

#### *Soft tissue sarcomas (Table 2)*

##### *Leiomyosarcoma*

Gestational leiomyosarcoma constitutes 12% of all sarcomas diagnosed during pregnancy. Since 1969, 17 cases have appeared in the literature. Among the reported cases most of them arise in the uterus followed by vulva, jejunum and retroperitoneal area. Histopathologically, typical leiomyosarcomas (mostly high grade), or epithelioid or myxoid type was diagnosed. Uterine leiomyosarcomas are generally considered to be more aggressive than other types of uterine tumors [9,21–34].

##### *Liposarcoma*

During the last two decades 17 cases of liposarcomas during pregnancy (12%) have been published. Almost all of them were located in the retroperitoneal area mostly with myxoid histology. Surgical manipulation is not feasible in all patients. About 50% of patients died early after diagnosis, while newborns remained well and healthy wherever deliveries were achievable [10,29,35–43].

##### *Rhabdomyosarcoma*

Fourteen cases of gestational rhabdomyosarcoma (10%) have been described during the last 45 years. Most common primary sites were orbit or vagina followed by maxillary sinus, nasal septum, perineum, bladder, breast or retroperitoneum. Apart from typical rhabdomyosarcomas some patients were diagnosed with embryonal, botryoid, spindle-cell or alveolar subtype of rhabdomyosarcomas. In one case invasion of the placenta was found [10,44–56].

##### *Gastrointestinal stromal sarcoma (GIST)*

Since the term of GIST was given in 1983, 9 pregnant mothers with gestational GIST have been documented. Signs and symptoms are usually non-specific unless they occur as a result of the "mass effect" of the tumor itself. CT scans are not recommended, however they can be replaced by abdominal ultrasound or even MRI. The optimal timing of surgery it is not well defined leaving the decision to the multidisciplinary team setting although it is considered safe in pregnancy. Imatinib treatment during pregnancy or breast feeding is contraindicated since spontaneous miscarriages and birth defects have been reported. Prognosis of women with gestational GIST remains favorable [57–65].

##### *Synovial sarcomas*

Gestational synovial sarcomas are rare sarcomas. Since 2007 only 9 cases (7%) of synovial sarcomas during pregnancy were

found. Three were primary pulmonary sarcomas, two head and neck sarcomas, one leg, one pelvis, one abdominal wall and one renal synovial sarcoma. Signs and symptoms included local slowly growing swelling for superficial tumors or symptoms related to the primary sites i.e. dyspnea, hematuria. Most women died of advanced disease [29,66–72].

#### *Kaposi's sarcoma*

Eight cases (6%) of Kaposi's sarcomas were found in the literature during the last 40 years. Five cases were diagnosed as AIDS-associated Kaposi's sarcomas following maternal infection with human immunodeficiency virus [73–80].

#### *Angiosarcoma*

Only 5 gestational angiosarcomas were reported in the English literature. Two were located to the breast and one to the skull. No data are available for the other two patients [9,81–83].

#### *Endometrial stromal sarcoma*

Five cases (4%) have been reported between 2002 and 2014. Most of them represent low-grade stromal sarcomas [85–89].

### Conclusions

In conclusion, diagnosis of bone and soft-tissue sarcomas in young pregnant women is rare. However, almost all types of sarcomas have been reported to coexist with pregnancy. In localized disease the goal is to treat primarily the mother and simultaneously to try to protect and safe the life of the fetus depending on the period of gestation. In metastatic disease the prognosis of the mothers is still poor in majority of the cases.

### Conflict of Interest

*The authors have declared no conflict of interest.*

### Compliance with Ethics Requirements

*This article does not contain any studies with human or animal subjects.*

### References

- [1] Pentheroudakis G, Pavlidis N. Cancer and pregnancy: poena magna, not anymore. *Eur J Cancer* 2006;42(2):126–40.
- [2] Orecchia R, Lucignani G, Tosi G. Prenatal irradiation and pregnancy: the effects of diagnostic imaging and radiation therapy. *Recent Results Cancer Res* 2008;178:3–20.
- [3] Azim Jr HA, Pavlidis N, Peccatori FA. Treatment of the pregnant mother with cancer: a systematic review on the use of cytotoxic, endocrine, targeted agents and immunotherapy during pregnancy. Part II: hematological tumors. *Cancer Treat Rev* 2010;36(2):110–21.
- [4] Azim Jr HA, Peccatori FA, Pavlidis N. Treatment of the pregnant mother with cancer: a systematic review on the use of cytotoxic, endocrine, targeted agents and immunotherapy during pregnancy. Part I: solid tumors. *Cancer Treat Rev* 2010;36(2):101–9.
- [5] Pavlidis N, Pentheroudakis G. Metastatic involvement of placenta and foetus in pregnant women with cancer. *Recent Results Cancer Res* 2008;178:183–94.
- [6] Ajithkumar T. *Oxford desk reference oncology*. Oxford: University Press; 2011, p. 406-432.
- [7] Pratt CB, Rivera G, Shanks E. Osteosarcoma during pregnancy. *Obstet Gynecol* 1977;50(1 Suppl):24s–6s.
- [8] Merimsky O, Inbar M, Issakov J, Kollender Y, Flusser G, Meller I, et al. Gestation-related malignant musculoskeletal tumors. *Isr Med Assoc J* 2003;5(4):264–7.
- [9] Maxwell C, Barzilay B, Shah V, Wunder JS, Bell R, Farine D. Maternal and neonatal outcomes in pregnancies complicated by bone and soft-tissue tumors. *Obstet Gynecol* 2004;104(2):344–8.
- [10] Al-Jubran A, Salam MA, El-Weshi A, Memon M, Ezzat A, Maghfoor I. Bone and soft tissue sarcomas during pregnancy. *J Clin Oncol* 2005 ASCO, Annual Meet Proceed 2005;23(16S (June 1 Suppl)):9077.
- [11] Kanazawa I, Yamauchi M, Yano S, Imanishi Y, Kitazawa R, Nariai Y, et al. Osteosarcoma in a pregnant patient with McCune-Albright syndrome. *Bone* 2009;45(3):603–8.
- [12] Corrêa RR, Espindula AP, Machado JR, Paschoini MC, Pacheco Olegário JG, Rocha LP, et al. Osteosarcoma in a pregnant woman: case report. *Arch Gynecol Obstet* 2012;286(6):1601–2.
- [13] Lysyj A, Bergquist JR. Pregnancy complicated by sarcoma. Report of two cases. *Obstet Gynecol* 1963;21:506–9.
- [14] Verheeecke M, Salembier C, Vanderlinden S. Delayed diagnosis of an Ewing sarcoma of the knee during pregnancy. *Facts Views Vis Obgyn* 2013;5(2):133–8.
- [15] Chihara IG, Osada H, Iitsuka Y, Masuda K, Sekiya S. Pregnancy after limb-sparing hemipelvectomy for Ewing's sarcoma. A case report and review of the literature. *Gynecol Obstet Invest* 2003;56(4):218–20.
- [16] Merimsky O, Le Chevalier T, Missenard G, Lepechoux C, Cojean-Zelek I, Mesurole B, et al. Management of cancer in pregnancy: a case of Ewing's sarcoma of the pelvis in the third trimester. *Ann Oncol* 1999;10(3):345–50.
- [17] Nakajima W, Ishida A, Takahashi M, Hirayama M, Washino N, Ogawa M, et al. Good outcome for infant of mother treated with chemotherapy for Ewing sarcoma at 25–30 weeks' gestation. *J Pediatr Hematol Oncol* 2004;26(5):308–11.
- [18] Schur S, Wild J, Amann G, Köstler W, Langer M, Brodowicz T. Sarcoma of the Ewing family in pregnancy: a case report of intrauterine fetal death after induction of chemotherapy. *Case Rep Oncol* 2012;5(3):633–8.
- [19] Heetkamp A, Feijen HW, Papatsonis DN. Spontaneous delivery after hemipelvectomy because of chondrosarcoma: a case report and review of the literature. *Am J Perinatol* 2008;25(4):255–8.
- [20] Roessler PP, Schmitt J, Fuchs-Winkelmann S, Efe T. Chondrosarcoma of the tibial head during pregnancy: a challenging diagnosis. *BMJ Case Rep* 2014;2014:30.
- [21] Soto RE, Carvajal FC, Lopez VS. *Ginecol Obstet Mex* 1970;27(164):693–9.
- [22] Wolfe SA, Seckinger D. Sarcoma of the uterus associated with pregnancy. *Am J Obstet Gynecol* 1969;104(8):1215–6.
- [23] Calzada GJ. Leiomyosarcoma and pregnancy (report of a case). *Ginecol Obstet Mex* 1974;35(209):247–9.
- [24] King TM, Atienza MF, Burkman RT. The incidence of abdominal surgical procedures in a population undergoing abortion. *Am J Obstet Gynecol* 1980;137(5):530–3.
- [25] Kyodo Y, Inatomi K, Abe T. Sarcoma associated with pregnancy. *Am J Obstet Gynecol* 1989;161(1):94–6.
- [26] Kuller JA, Zucker PK, Peng TC. Vulvar leiomyosarcoma in pregnancy. *Am J Obstet Gynecol* 1990;162(1):164–6.
- [27] Bekkers RL, Massuger Lf, Berg PP, Haelst UG, Bulten J. Uterine malignant leiomyoblastoma (epithelioid leiomyosarcoma) during pregnancy. *Gynecol Oncol* 1999;72(3):433–6.

- [28] Younis JS, Okon E, Anteby SO. Uterine leiomyosarcoma in pregnancy. *Arch Gynecol Obstet* 1990;247(3):155–60.
- [29] Molho RB, Kollender Y, Issakov J, Bickels J, Flusser G, Azem F, et al. The complexity of management of pregnancy-associated malignant soft tissue and bone tumors. *Gynecol Obstet Invest* 2008;65(2):89–95.
- [30] Di Gilio AR, Cormio G, Resta L, Carriero C, Loizzi V, Parisi AM, et al. Rapid growth of myxoid leiomyosarcoma of the vulva during pregnancy: a case report. *Int J Gynecol Cancer* 2004;14(1):172–5.
- [31] Bodner-Adler B, Lozano P, Bodner K, Zeisler H. Primary uterine leiomyosarcoma and primary atypical meningioma diagnosed during pregnancy. *Anticancer Res* 2008;28(5B):3083–5.
- [32] Ulker V, Gungorduk K, Numanoglu C, Sahbaz A, Aslan O, Tekirdag AI, et al. Complete surgical resection of retroperitoneal leiomyosarcoma in pregnancy: a case report. *Arch Gynecol Obstet* 2008;277(4):353–6.
- [33] Lau TK, Wong WS. Uterine leiomyosarcoma associated with pregnancy: report of two cases. *Gynecol Oncol* 1994;53(2):245–7.
- [34] Church E, Dhanaliwala A, Sengupta S, Katakam N, Tomlinson AJ, Chia KV. An unusual case of vaginal leiomyosarcoma in pregnancy. *J Obstet Gynaecol* 2010;30(7):736–7.
- [35] De Jaco P, Giorgio M, Zantedeschi B, Mazzoleni G, Marabini A. A case of retroperitoneal liposarcoma in pregnancy. *Acta Obstet Gynecol Scand* 1993;72(2):122–4.
- [36] Matsuda S, Tanaka K, Harimaya K, Matsumoto Y, Sato H, Iwamoto Y. Treatment of myxoid liposarcoma in pregnancy. *Clin Orthop Relat Res* 2000(376):195–9.
- [37] Tebes S, Cardosi R, Hoffman M. Liposarcoma complicating pregnancy. *Gynecol Oncol* 2001;83(3):610–2.
- [38] Femenia F, Ruiz-Gimeno JI, Ferre MA, Barberá M. Liposarcoma removal under combined intradural–epidural anesthesia and sedation with propofol and remifentanyl in a pregnant patient. *Rev Esp Anesthesiol Reanim* 2007;54(7):448–50.
- [39] Jeng CJ, Tzen CY, Huang WC, Yang YC, Shen J, Tzeng CR. Recurrent retroperitoneal myxoid liposarcoma during pregnancy: a case report and literature review. *Int J Gynecol Cancer* 2005;15(6):1235–8.
- [40] Yamamoto T, Marui T, Akisue Hitora T, Kawamoto T, Nagira K, et al. Management of liposarcoma occurring in pregnant women. *Anticancer Res* 2003;23(1B):799–802.
- [41] Lopes RI, Machado M, Paz C, Santos AC, Rezende WW. Successful outcome of a surgically treated giant retroperitoneal liposarcoma during pregnancy. *Arch Gynecol Obstet* 2009;280(6):1067–9.
- [42] Duenas-Garcia OF, Diaz-Sotomayor M, Rico-Olvera H. Well differentiated giant retroperitoneal liposarcoma during the pregnancy. *Rev Esp Enferm Dig* 2011;103(12):657–8.
- [43] Oh SE, Kim HJ, Choi SJ, Oh SY, Roh CR, Kim JH. A case of huge retroperitoneal liposarcoma in pregnancy. *Obstet Gynecol Sci* 2014;57(3):236–9.
- [44] Olurin O. Orbital rhabdomyosarcoma in pregnancy. *Cancer* 1969;24(5):1013–6.
- [45] Wiernik-Strzeszynska E. Case of rhabdomyosarcoma of the maxillary sinus in advanced pregnancy. *Otolaryngol Pol* 1979;33(4):453–6.
- [46] Singhal S, Sharma S, De S, Kumar L, Chander S, Rath GK, et al. Adult embryonal rhabdomyosarcoma of the vagina complicating pregnancy: a case report and review of the literature. *Asia Oceania J Obstet Gynaecol* 1990;16(4):301–6.
- [47] Martin D, Winter SS, Gardner MO, Nicklaus P. Rhabdomyosarcoma treated with chemotherapy during the third trimester. *Obstet Gynecol* 1997;89(5 Pt 2):828–31.
- [48] O'Day MP, Nielsen P, Al-Bozom I, Wilkins IA. Orbital rhabdomyosarcoma metastatic to the placenta. *Am J Obstet Gynecol* 1994;171(5):1382–3.
- [49] Ariza M, Rafeae T, Adeeb N, Muhaizan WM, Isa MR. A successful pregnancy outcome in treated vulval rhabdomyosarcoma. *Med J Malaysia* 1999;54(3):371–3.
- [50] Yaren A, Guclu A, Sen N, Erdem E, Demirkan F. Breast metastasis in a pregnant woman with alveolar rhabdomyosarcoma of the upper extremity. *Eur J Obstet Gynecol Reprod Biol* 2008;140(1):131–3.
- [51] Meazza C, Casanova M, Zaffignani E, Clerici CA, Favini F, Vasquez R. An adolescent with rhabdomyosarcoma during pregnancy. *Tumori* 2008;94(3):431–3.
- [52] Esfahani SA, Montaser-Kouhsari L, Saeedi P, Sadeghi Z, Kajbafzadeh AM. An antenatally diagnosed rhabdomyosarcoma of the bladder treated without extensive surgery. *Nat Rev Urol* 2009;6(8):449–53.
- [53] Yu L, Yang SJ. Spindle cell rhabdomyosarcoma of the retroperitoneum: an unusual case developed in a pregnant woman but obscured by pregnancy. *Int J Clin Exp Pathol* 2014;7(8):4904–12.
- [54] Merced C, Rubio IT, Rodríguez J, Peg V, Xercavins J. Breast metastasis from rhabdomyosarcoma of the nasal septum in a pregnant adult woman. *Breast J* 2011;17(4):420–1.
- [55] Mhaskar R, Takkar D, Bijlani L, Mala G, Rath. Embryonal rhabdomyosarcoma of the vagina associated with pregnancy; a case report. *Eur J Obstet Gynecol Reprod Biol* 1989;30(1):95–8.
- [56] Siepermann M, Koscielniak E, Dantonello T, Klee D, Boos J, Krefeld B, et al. Oral low-dose chemotherapy: successful treatment of an alveolar rhabdomyosarcoma during pregnancy. *Pediatr Blood Cancer* 2012;58(1):104–6.
- [57] Valente PT, Fine BA, Parra C, Schroeder B. Gastric stromal tumor with peritoneal nodules in pregnancy: tumor spread or rare variant of diffuse leiomyomatosis. *Gynecol Oncol* 1996;63(3):392–7.
- [58] Lanzafame S, Minutolo V, Caltabiano R, Minutolo O, Marino B, Gagliano G, et al. About a case of GIST occurring during pregnancy with immunohistochemical expression of epidermal growth factor receptor and progesterone receptor. *Pathol Res Pract* 2006;202(2):119–23.
- [59] Scherjon S, Lam WF, Gelderblom H, Jansen FW. Gastrointestinal stromal tumor in pregnancy: a case report. *Case Rep Med* 2009;2009:456402.
- [60] Igras ET, Fosh BG, Neuhaus SJ. Maternal GIST in twin pregnancy: case report of a rare and complex management challenge. *Gynecol Oncol Case Rep* 2012;2(4):133–5.
- [61] Stubbs BM, Desai A, Singh S, Seddon B, Khan F. Gastrointestinal stromal tumour in pregnancy. *BMJ Case Rep* 2011;2011:20.
- [62] Gözükarı I, Dilek TU, Durukan H, Düşmez Apa D, Kabil Kucur S, Dilek S. Extragastrintestinal stromal tumor during pregnancy. *Case Rep Obstet Gynecol* 2012;2012:846747.
- [63] Varras M, Vlachakos N, Akrivis C, Vasilakaki T, Skafida E. Malignant gastrointestinal stromal tumor presenting with hemoperitoneum in puerperium: report of a case with review of the literature. *World J Surg Oncol* 2010;8:95.
- [64] Haloob N, Slessor AA, Haloob AR, Khan F, Bostanci G, Abdulla A. An elective combined caesarean section and small bowel GIST resection during the third trimester of pregnancy: report of a case. *Int J Surg Case Rep* 2013;4(1):121–4.
- [65] Goel N, Malik R, Rathi B, Bhaskaran S, Rajaram S, Mehta S, et al. Pregnancy with metastatic gastrointestinal stromal tumor (GIST) on imatinib chemotherapy: an oncologist's nightmare and obstetrician's dilemma. *J Gastrointest Cancer* 2013;44(1):115–7.
- [66] Orlandi E, Zonca G, Pignoli E, Stucchi C, Borroni M, Collini P, et al. Postoperative radiotherapy for synovial sarcoma of the

- head and neck during pregnancy: clinical and technical management and fetal dose estimates. *Tumori* 2007;93(1):45–52.
- [67] Esaka EJ, Celebrezze JU, Golde SH, Chiossi G, Thomas RL. Pulmonary synovial sarcoma presenting as a pneumothorax during pregnancy. *Obstet Gynecol* 2008;111(2 Pt 2):555–8.
- [68] Ortiz M, Giraldez LA, Riera-March A. Synovial sarcoma of the hypopharynx in pregnancy. *Bol Asoc Med P R* 2012;104(3):55–6.
- [69] Bunch K, Deering SH. Primary pulmonary synovial sarcoma in pregnancy. *Case Rep Obstet Gynecol* 2012;2012:326031.
- [70] Nebhnani D, Fernandes G, Menon S, Naik L. Primary renal synovial sarcoma presenting in the first trimester of pregnancy. *J Obstet Gynaecol India* 2014;64(Suppl 1):22–3.
- [71] Harris EM, Allan RW, Riggs Jr CE. Primary pulmonary synovial sarcoma during pregnancy: a diagnostic and therapeutic dilemma. *Case Rep Oncol* 2014;7(1):139–43.
- [72] Kanade US, Gadgil PA, Birare SD, Chaware SA, Kamra H. Abdominal wall synovial sarcoma during pregnancy – a case report. *Indian J Surg* 2013;75(Suppl 1):463–4.
- [73] Taylor JF, Templeton AC, Kylwazi S, Lubega A. Kaposi's sarcoma in pregnancy. Two case reports. *Br J Surg* 1971;58(8):577–9.
- [74] Rawlinson KF, Zubrow AB, Harris MA, Jackson UC, Chao S. Disseminated Kaposi's sarcoma in pregnancy: a manifestation of acquired immune deficiency syndrome. *Obstet Gynecol* 1984;63(3 Suppl):2S–6S.
- [75] Audouin AF, Lopes P, Lenne Y. Kaposi's sarcoma of the uterine cervix associated with atypical condyloma in a female patient with cardiac transplantation (during the post-partum period). *Arch Anat Cytol Pathol* 1988;36(5–6):226–8.
- [76] McCarty KA, Bungu Z. Kaposi's sarcoma in a two week old infant born to a mother with Kaposi's sarcoma/AIDS. *Cent Afr J Med* 1995;41(10):330–1.
- [77] Bryant AE, Genc M, Hurtado RM, Chen KT. Pulmonary Kaposi's sarcoma in pregnancy. *Am J Perinatol* 2004;21(6):355–63.
- [78] Sebitloane HM, Mosam A, Moodley J. Disseminated AIDS-associated Kaposi's sarcoma in pregnancy. *S Afr Med J* 2006;96(7):602–3.
- [79] Brunet-Possenti F, Pages C, Rouzier R, Dupin N, Bagot M, Lebbé C. Kaposi's sarcoma and pregnancy: case report and literature review. *Dermatology* 2013;226(4):311–4.
- [80] Adeyemo A, Wood C, Govind A. Kaposi's sarcoma in pregnancy after initiation of highly active antiretroviral therapy: a manifestation of immune reconstitution syndrome. *Int J STD AIDS* 2012;23(12):905–6.
- [81] Jha S, Chan KK, Poole CJ, Rollason TP. Pregnancy following recurrent angiosarcoma of the ovary – a case report and review of literature. *Gynecol Oncol* 2005;97(3):935–7.
- [82] Samadian M, Rakhshan M, Haddadian K, Rezaei O, Zamani SA, Khormaei F. Angiosarcoma of skull in a pregnant woman: case report and review of the literature. *Turk Neurosurg* 2012;22(1):113–5.
- [83] Wang J, Fisher C, Thway K. Angiosarcoma of the breast with solitary metastasis to the ovary during pregnancy: an uncommon pattern of metastatic disease. *Case Rep Oncol Med* 2013;2013:209610.
- [84] Leunen K, Amant F, Debiec-Rychter M, Croes R, Hagemeyer A, Schoenmakers EF, et al. Endometrial stromal sarcoma presenting as postpartum haemorrhage: report of a case with a sole t(10;17)(q22;p13) translocation. *Gynecol Oncol* 2003;91(1):265–71.
- [85] Woytoń J, Florjański J, Tomiałowicz M. Stromal sarcoma in pregnancy – a case report. *Ginekol Pol* 2002;73(4):400–3.
- [86] Jain PS, Jariwala MC. Successful pregnancy with endometrial stromal sarcoma (ESS). *J Obstet Gynaecol India* 2014;64(4):297–8.
- [87] Koskas M, Morice P, Yazbeck C, Duvillard P, Walker F, Madelenat P. Conservative management of low-grade endometrial stromal sarcoma followed by pregnancy and severe recurrence. *Anticancer Res* 2009;29(10):4147–50.
- [88] Amant F, Van Calsteren K, Debiec-Rychter M, Heyns L, De Beeck KO, Sagaert X, et al. High-grade endometrial stromal sarcoma presenting in a 28-year-old woman during pregnancy: a case report. *J Med Case Rep* 2010;4:243.