

Pronator syndrome: clinical and electrophysiological features in seven cases

HAROLD H. MORRIS AND BRUCE H. PETERS

From the Department of Neurology, University of Texas Medical Branch, Galveston, Texas, USA

SYNOPSIS The clinical and electrophysiological picture of seven patients with the pronator syndrome is contrasted with other causes of median nerve neuropathy. In general, these patients have tenderness over the pronator teres and weakness of flexor pollicis longus as well as abductor pollicis brevis. Conduction velocity of the median nerve in the proximal forearm is usually slow but the distal latency and sensory nerve action potential at the wrist are normal. Injection of corticosteroids into the pronator teres has produced relief of symptoms in a majority of patients.

In the majority of isolated median nerve dysfunctions the carpal tunnel syndrome is appropriately first suspected. The median nerve can also be entrapped in the forearm giving rise to a similar picture and an erroneous diagnosis.

The purpose of this report is to draw full attention to the pronator syndrome and to the features which allow it to be distinguished from median nerve entrapment at other sites.

Our material was gathered over eight years of consultative neurological practice. During this

period 101 cases of the carpal tunnel syndrome and the seven cases of the pronator syndrome reported here were identified. Median nerve conduction velocity determinations were made on all of these patients.

REPORT OF CASES

Table 1 provides clinical details of seven cases of the pronator syndrome and Table 2 shows results of electrophysiological studies. Two cases, described in detail below, exemplify the clinical features.

TABLE 1
CLINICAL FEATURES OF SEVEN PATIENTS WITH PRONATOR SYNDROME

Case	Age (yr)	Sex	Occupation	Symptoms			Signs			
				Numbness	Weakness	Forearm pain	Atrophy	Weakness	Sensory loss	Tender over pronator teres
1	28	M	Shoveller	+	—	—	—	Fpl, op	+	+
2	53	M	Woodworker	+	+	—	—	apb Fpl, op apb	—	+
3	61	M	Mechanic	—	+	+	Fdp	Fpl, fdp apb	+	+
4	27	M	Baseball pitcher	+	+	—	—	Fpl, op	+	+
5	44	M	Fiddler	+	—	+	—	Fpl, op apb	+	+
6	44	M	Mechanic	+	—	—	—	Fdp, fpl apb, op	+	+
7	70	M	Barber*	+	—	+	—	Fpl, fdp apb	+	+

Apb=abductor pollicis brevis, fdp=flexor digitorum profundus, fpl=flexor pollicis longus, op=opponens pollicis.

*Bilateral pronator syndrome.

TABLE 2
MEDIAN NERVE ELECTROPHYSIOLOGICAL FINDINGS IN PRONATOR SYNDROME

Case	Distal latency (ms)	Motor conduction elbow to wrist (m/s)	Motor conduction axilla to elbow (m/s)	Sensory latency (ms)
1	3.6	40.0	46.1	ND
2	3.3	40.0	67.0	ND
3	3.4	61.9	ND	ND
4	3.3	42.7	61.4	3.16
5	3.2	61.4	ND	2.70
6	2.9	42.0	59.0	2.6
7	3.8 R	38.0	60.0	ND
	3.5 L	42.0	ND	ND
Normal	≤ 4.5	≥ 45.0	≥ 45.0	≤ 3.2

R: right; L: left; ND: not done.

CASE 1 A 28 year old male noted numbness and tingling of his right thumb and fingers three weeks after starting an industrial job in which he cleaned sludge from magnesium cells by holding a long pole at the end of which was a bucket, emptied by recurrent forceful pronation of his right forearm. When seen two months after the onset of his symptoms there was slight weakness of the right flexor digitorum profundus and moderate weakness of the right flexor pollicis longus, opponens pollicis, and abductor pollicis brevis muscles. There was a slight decrease in pin and touch sensation in the median nerve distribution including the thenar eminence. Tenderness to palpation was present over the right pronator teres muscle. Distal motor latency of the right median nerve was normal at 3.6 ms. Motor nerve conduction velocity from axilla to wrist was 46.1 m/s (normal greater than 45 m/s) but in the segment distal to the pronator teres it was reduced to 40 m/s. Electromyography confirmed denervation of the right abductor pollicis brevis. The patient improved after infiltration of the right pronator region with corticosteroids and change in occupation.

CASE 2 A 49 year old college professor and avid weekend woodworker had noted intermittent burning and tingling paraesthesias of the right forearm, thumb and index finger usually after a weekend spent pursuing his hobby. Symptoms were especially severe after vigorously using a screwdriver or playing golf. The discomfort would subside in several days. Physical findings included tenderness and a Tinel's sign on palpating over the median nerve at the pronator teres. There was moderate weakness of the right abductor pollicis brevis muscle and slight weakness in the flexor digitorum profundus and flexor pollicis longus. Nerve conduction velocity studies showed a normal median nerve distal latency of 3.3 ms. The median nerve overall (motor fibres)

conducted at 67 m/s but slowed to 42 m/s in the segment between the elbow and mid-forearm. The patient was treated with steroid injections into the pronator region and advised against exercise requiring forceful pronation and finger flexion. Response to this therapy and advice was complete and the patient found he could resume his golfing without discomfort and actively pursue his hobby by using an electrically powered screwdriver.

DISCUSSION

Entrapment of the median nerve at the level of the pronator teres was first recognized by Seyffarth (1951), who in 1951 reported on 17 patients. No clinical series have since been reported in the English literature, although Kopell and Thompson (1958) and Esposito (1972) have refined the syndrome's clinical definition. All of our seven patients and the majority of those previously reported were males and experienced symptoms in their dominant arm. In all instances, the patient's work required considerable muscular activity of the forearm and hand, especially forceful pronation accompanying finger flexion. The most common presenting complaints were pain and tenderness of the proximal forearm and paraesthesias of the hand. Weakness of the hand was a less common complaint. Compared with the carpal tunnel syndrome, intense nocturnal paraesthetic discomfort was uncommon. All of our patients demonstrated definite weakness of the flexor pollicis longus and only one did not have weakness of abductor pollicis brevis. The flexor digitorum profundus and opponens pollicis muscles less often showed clinically demonstrable

weakness. It is noteworthy that the degree of weakness was often slight and would be missed if not specifically sought for in comparison with the contralateral muscle. Most of these patients are accustomed to manual labour and may have surprising strength even in involved muscles. Sensory impairment, also often subtle, was noted in six of the cases. Tenderness over the pronator muscle was an invariable finding and frequently was associated with a positive Tinel's sign over the median nerve at that point.

Electrophysiological studies were helpful; six of the seven patients had slowed motor nerve conduction in the forearm with a normal distal motor latency. In some cases motor nerve conduction measured from elbow to wrist fell within the normal range (greater than 45 m/s), but conduction of the elbow to mid-forearm segment was slowed. In several of the cases an initial impression of carpal tunnel syndrome had been made and a correct diagnosis was not recognized until the patient was examined again after electrodiagnostic testing.

In the differential diagnosis of median nerve dysfunction not due to acute severe trauma the carpal tunnel syndrome justly receives first thought. In this condition, the patient will experience pain and paraesthesias frequently more severe at night in the median innervated aspect of the hand. The painful paraesthetic feelings of the carpal tunnel syndrome may extend up the forearm—but, unlike the pronator syndrome, there will be no tenderness or Tinel's sign over the pronator teres muscle. In both carpal tunnel and pronator syndromes a Tinel's sign at the wrist may be encountered, although it is usually more prominent in the former. Although it is true that reduction of sensation in the pronator syndrome may extend over the thenar eminence and that this is not seen in carpal tunnel compression, this is not often a diagnostically useful clinical feature because of the subtleties and inconsistencies of sensory testing. More useful is careful scrutiny of the muscles. In the carpal tunnel syndrome the abductor pollicis brevis is most commonly the only clinically weak or atrophic muscle, whereas in addition to this muscle the flexor pollicis longus and flexor digitorum profundus will be at least modestly weak in the pronator syndrome. Electrophysiological tests are very useful. In our

experience, a normal motor and sensory distal latency of the median nerve in the face of a demonstrable clinical weakness is very unusual in the carpal tunnel syndrome but is a common finding of the pronator syndrome.

An identifiable supracondylar spur of the humerus is present in a small proportion of the normal human population and although it is usually clinically silent it may give rise to the humeral supracondylar spur syndrome. This can clinically mimic the pronator syndrome except that in it a spur can be appreciated about 5 cm above the medial epicondyle by palpation and/or radiography. Also, because the median nerve and the brachial artery course under a fibrous band (ligament of Struthers) connecting this spur with the medial epicondyle, the radial pulse will frequently disappear or diminish on fully extending and supinating the forearm.

The anterior interosseous nerve entrapment syndrome is unique in lacking sensory symptoms. This nerve is compressed in the proximal forearm near its branching point from the median nerve. The muscles usually supplied by this nerve are (with some variability that may add confusing elements to the diagnosis of any of these syndromes) the flexor pollicis longus, flexor digitorum profundus to the index finger, and the pronator quadratus muscle. A characteristic posture of the thumb and index finger is assumed when the patient pinches them vigorously together. The metacarpal phalangeal joint of the thumb and the proximal interphalangeal joint of the index finger are hyperflexed whereas the distal interphalangeal joints of each are hyperextended (Esposito, 1972).

The thoracic outlet syndrome should seldom present differential diagnostic difficulties. There is usually a sensory loss in a lower brachial plexus distribution, weakness of ulnar-innervated muscles, and tenderness and/or a bruit in the supraclavicular space. A unilateral radial pulse reduction on the Adson's, hyperabduction, or costoclavicular manoeuvre may be seen. A delay of median nerve distal latency or focal median nerve slowing of conduction distally is not found. Slowing of conduction along the ulnar nerve as measured by stimulation at the supraclavicular space, although infrequently found in our experience, is a helpful finding when present.

When an atraumatic median mononeuropathy

presents abruptly, tests for diabetes and collagen vascular diseases should be done.

Solnitzky (1960) reviewed the anatomy of the median nerve and found that in 85% of dissections the nerve pierced the two heads of the pronator teres muscle before passing deep to the tendinous arch of the flexor digitorum sublimis—the so-called 'sublimis bridge'. Occasionally, an anomalous fibrous band connects the pronator teres to the 'sublimis bridge' and may impinge on the median nerve at that point (Figure).

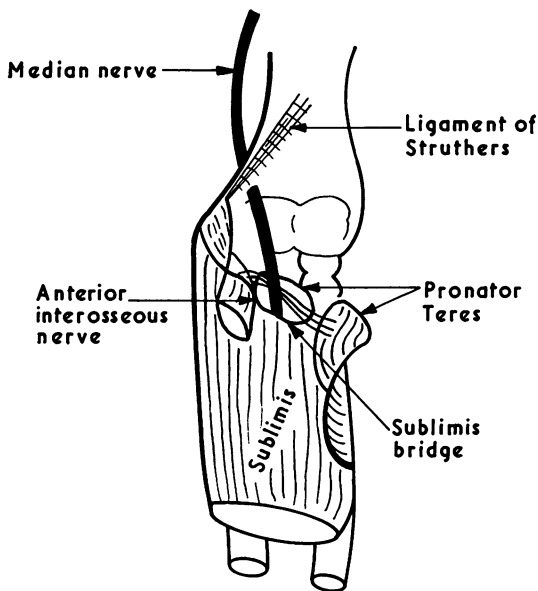


FIGURE Diagram of anatomical relations of left median nerve to structures in front of the elbow joint.

Near its passage through the pronator teres, the median nerve sends branches to the elbow joint, pronator teres, flexor carpi radialis, flexor pollicis longus, and flexor digitorum sublimis. It then gives rise to the anterior interosseous nerve which usually supplies the flexor pollicis longus, flexor digitorum profundus, and pronator quadratus. This nerve is on the anterior aspect of the interosseous membrane in the forearm. The main trunk of the median nerve courses in

the forearm deep to the flexor digitorum sublimis and at the wrist gives off a sensory branch to the thenar eminence which passes superficially to the flexor retinaculum and, hence, is not involved in the carpal tunnel syndrome. The nerve continues into the hand supplying the first two lumbricales and all the thenar muscles except the adductor pollicis.

RESULTS OF THERAPY Surgery has been considered to be the definitive treatment, but in our experience non-surgical measures are of value and should be tried in each case. Infiltration of the pronator teres muscle with corticosteroids should be done and repeated if the response is incomplete. When possible, the patient is advised to avoid vigorous supination-finger-flexion activities. Simple measures, such as utilizing a screwdriver attachment on a variable speed electric drill, may benefit a patient who must do carpentry or other work requiring use of the screwdriver. Five of our seven patients had been adequately relieved of their symptoms and able to maintain their employment after corticosteroid injections. In patients who are not adequately relieved by conservative measures or whose work results in repeated exacerbations of the pronator syndrome, exploration of the pronator region and surgical division of any constricting band or compressing lesion is suggested.

The authors are grateful to Mrs Betty Morris for the anatomical drawing.

REFERENCES

- Esposito, G. M. (1972). Peripheral entrapment neuropathies of upper extremity. *New York State Journal of Medicine*, **72**, 717-724.
- Kopell, H. P., and Thompson, W. A. I. (1958). Pronator syndrome: a confirmed case and its diagnosis. *New England Journal of Medicine*, **259**, 712-715.
- Seyffarth, H. (1951). Primary myoses in the m. pronator teres as cause of lesion of the n. medianus (the pronator syndrome). *Acta Psychiatrica et Neurologica Scandinavica, suppl.*, **74**, 251-254.
- Solnitzky, O. (1960). Pronator syndrome: compression neuropathy of the median nerve at the level of pronator teres muscle. *Georgetown Medical Bulletin*, **13**, 232-238.