

# Hypertrophy of the branchial muscles

## A case with unusual features

C. D. LAMBERT<sup>1</sup> AND J. R. B. YOUNG

*From the Middlesex Hospital, London*

**SYNOPSIS** A detailed morphological and histochemical description of pathological changes previously unreported in hypertrophy of the masseter muscle is presented. The patient differed from earlier cases in reacting adversely to anaesthetic agents.

Recently Mancall and colleagues (1974) described, for the first time in a neurological journal, a patient with hypertrophy of the muscles of mastication. Over 100 earlier cases were reviewed and the characteristic clinical features of the disorder documented. The paucity of available histopathological data was remarked upon but it was suggested that the disorder was a myopathy of benign character. This report describes a further example of the disorder in which two previously unreported features were observed: the patient reacted adversely to general anaesthetics on two occasions, and histochemical studies of an affected muscle showed gross predominance and hypertrophy of type I fibres.

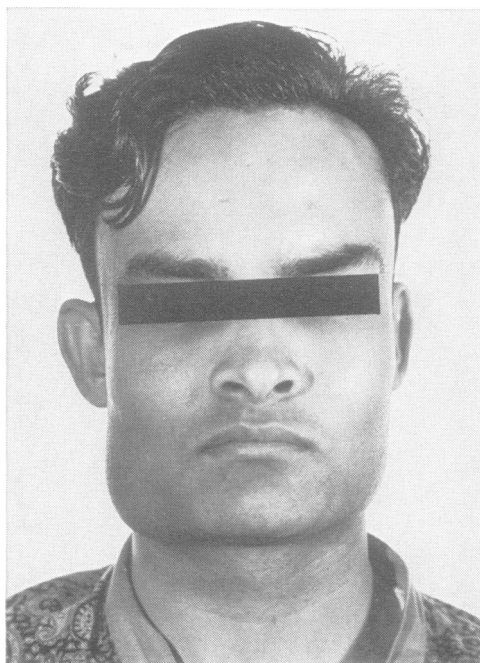
### CASE REPORT

In 1969 a 22 year old Anglo-Indian presented to a surgical clinic complaining of swelling of the angle of the jaw. This had first been noticed at the age of 10 years and had subsequently gradually increased in size; the swelling became slightly painful on hard chewing. The patient was otherwise well, was not receiving any medication, and had had no significant past illnesses. There was no family history of muscle disease or anaesthetic death.

On examination there was swelling at the angle of the mandible on the right side which was firm and contracted to a hard mass on clenching the teeth (Fig. 1). No abnormality was present intraorally or

on general examination. A diagnosis of masseteric hypertrophy was made. Admission to hospital for investigation, which included carotid angiography, was arranged.

The patient, weighing 56 kg, was premedicated with papaveretum 15 mg, and scopolamine 0.3 mg one



**FIG. 1** *Patient—presenting feature: swelling at the angle of the jaw.*

<sup>1</sup> Address for correspondence: Dr C. D. Lambert, Atkinson Morley's Hospital, Copse Hill, Wimbledon, London SW20 0NE.

(Accepted 30 March 1976.)

hour preoperatively. Anaesthesia was induced using methohexitone 70 mg followed by suxamethonium 50 mg. No fasciculations were observed but violent contraction of both forearms occurred, followed by relaxation. The jaws clenched tightly, and failed to relax after a second injection of 50 mg of suxamethonium. Considerable hand force was required to separate the jaws. A cuffed orotracheal tube was passed into the trachea and a sequence of nitrous oxide, oxygen, and halothane was used to maintain anaesthesia. Spontaneous respiration recurred within two minutes of intubation.

Carotid angiography was performed but because of masseteric spasm the vessels within this muscle did not fill; surrounding tissues showed a normal vascular pattern. Anaesthesia was maintained for 40 minutes; jaw spasm persisted for 90 minutes. A mild rise of body temperature to 37.6°C occurred three hours after induction of anaesthesia but recovery was otherwise uneventful.

A neurological opinion was then obtained. Asymmetrical hypertrophy of the masseter muscles and symmetrical hypertrophy of the temporalis muscles were found. The anterior fibres of the deltoid muscles were possibly hypertrophied but no other neurological abnormality was found. The serum creatine phosphokinase (CPK) was normal (67 IU/l). No abnormality was found in either the right masseter or deltoid muscles at electromyography. No myotonic

discharges were recorded.

Three months later the patient was reviewed by the dental surgeons because of progressive difficulty in opening his mouth and in chewing. It was felt that he required partial resection of his right masseter muscle and mandibular osteotomy. In view of the previous atypical response to suxamethonium this drug was omitted from the second anaesthetic and throughout the procedure the pulse, blood pressure, and arterial blood gases were closely monitored, as was body temperature through sensors applied to the skin and oesophageal wall. An abnormal response to the muscle relaxant was, however, again observed. After the injection of curare 45 mg the masseter muscles went into spasm while the other muscles became flaccid, making oral intubation of the trachea difficult, but ventilation was readily maintained *via* a face-mask. The procedure, lasting two hours, was otherwise uneventful. The drugs administered were: papaveretum 20 mg, scopolamine 0.4 mg (one hour preoperatively), thiopentone sodium 950 mg, nitrous oxide, and oxygen with atropine 1.2 mg and neostigmine 2.5 mg at the end of the anaesthetic. Spontaneous respiration returned rapidly and after an uneventful period of observation in the recovery room the patient was returned to the ward.

Five hours after the start of surgery a sudden temperature rise occurred (Fig. 2). The patient was stripped and cooled by means of a fan and cold

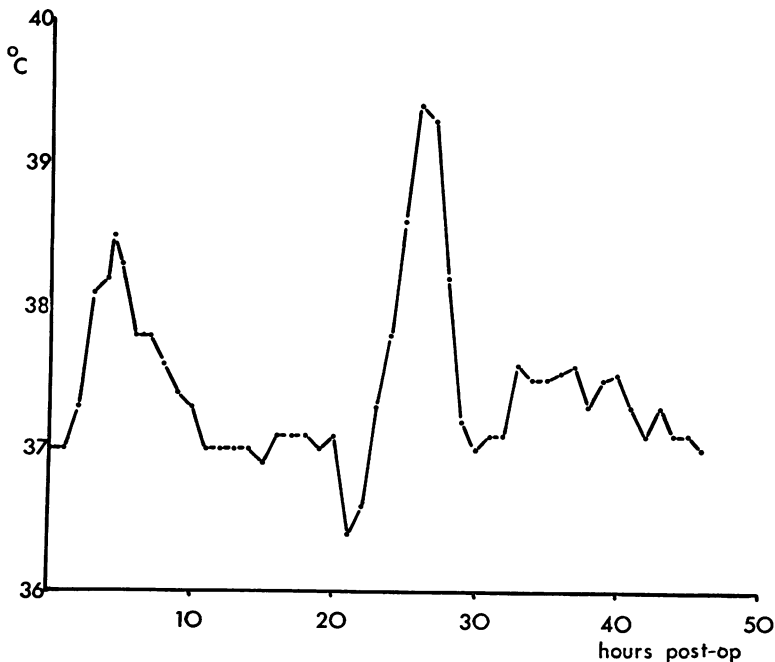


FIG. 2 Postoperative temperature chart.

sponging. Shivering was controlled by diazepam 10 mg intramuscularly initially with subsequent four-hourly increments to a total of 30 mg. The temperature settled to normal overnight and the patient was well until 24 hours after surgery when a second abrupt temperature rise occurred. The methods which had successfully controlled the first temperature spike were inadequate on the second occasion. The patient was therefore transferred to the theatre suite with a view to cooling him in the ice bath used for controlled hypothermia. Before this, chlorpromazine 25 mg and diazepam 5 mg were given intravenously and the temperature rise halted at 39.4°C. Further increments of chlorpromazine (total 137.5 mg) and diazepam (total 15 mg) were subsequently given. The temperature fell rapidly to a normal level and, apart from some minor elevations in the following days, recovery was uneventful.

The pyrexial episode was not associated with hyperkalaemia or metabolic acidosis. The serum CPK level was 63 IU/l preoperatively. This rose to a maximum of 870 IU/l on the fifth postoperative day and returned to normal on the ninth day.

Lincomycin was administered prophylactically after surgery but there was no evidence of infection either at the operation site or elsewhere; swab and blood cultures were negative.

**HISTOLOGY** The excised specimen of masseter muscle, containing approximately 2000 fibres, was examined using conventional morphological and histochemical techniques (Dubowitz and Brooke,

1973). In one small area gross myopathic changes, focal about a central point, were apparent (Fig. 3). Morphological abnormalities in the remainder of the specimen were inconspicuous. The connective tissue appeared normal; occasional internal nuclei and some necrotic fibres were seen (Fig. 4). Fibre diameters ranged from 5–100  $\mu\text{m}$ . Gross preponderance of type I fibres was evident with the routine ATPase reaction (Fig. 5). Less than 1% of fibres were type II. The type I fibres were hypertrophic (range 30–100  $\mu\text{m}$ ) with a mean fibre diameter of 57  $\mu\text{m}$  (normal 35  $\mu\text{m}$ ). The type II fibres were small, ranging from 5–35  $\mu\text{m}$  in diameter, but their mean diameter of 19  $\mu\text{m}$  did not differ from that of the normal male (18  $\mu\text{m}$ ) (Ringqvist, 1974). All fibres were uniform in appearance with the NADH-TR reaction, while minimal differences were apparent with the PAS and phosphorylase reactions.

#### DISCUSSION

The characteristic features of bilateral hypertrophy of the muscles of mastication were documented by Mancall and colleagues (1974): patients usually present to surgical clinics with swelling at the angle of the jaw. Examination shows enlargement of the muscles of mastication. The masseters are most conspicuously involved, often asymmetrically, but the pterygoid and temporalis muscles also hypertrophy. The course is one of slow progression; other muscles are not

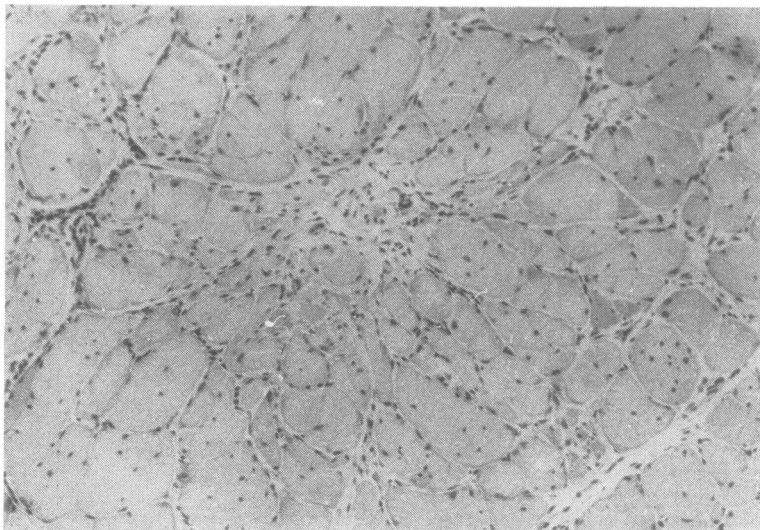
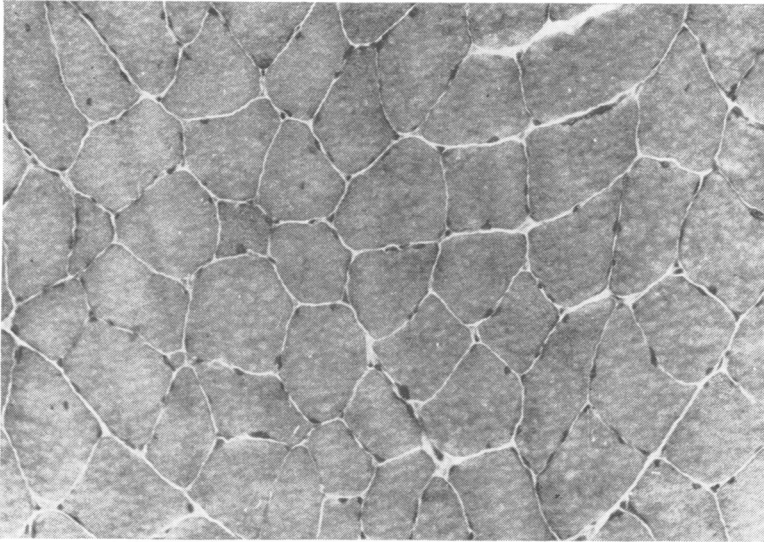
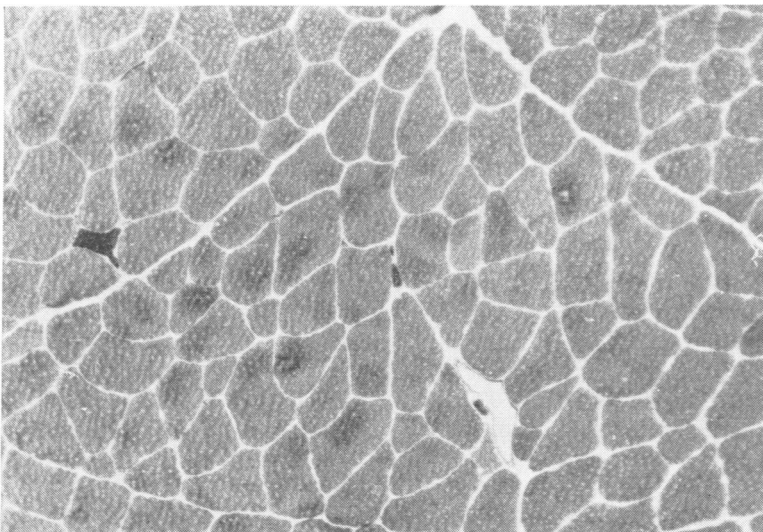


FIG. 3 *Masseter muscle. Localized area of gross myopathic change. H and E, original magnification  $\times 65$ .*



**FIG. 4** *Masseter muscle, showing relatively normal architecture. Modified Gomori trichrome, original magnification  $\times 105$ .*



**FIG. 5** *Masseter muscle. Gross preponderance of type I fibres. Routine ATPase reaction at pH 9.4, original magnification  $\times 65$ .*

affected. Reduction of muscle bulk may be undertaken for cosmetic reasons or because protrusion of the muscle mass into the oral cavity impairs chewing. The aetiology of the disorder is unknown. Few electromyographic studies have been undertaken and no significant abnormalities have been observed. These features were evident in the present case.

In their case, Mancall *et al.* (1974) observed myopathic changes in the masseter and temporalis muscles. Limb muscles were unaffected both clinically and histologically. These authors commented upon the paucity of histopathological reports but suggested that the disorder was myopathic and recommended that it should be called hypertrophic branchial myopathy. Our own study did not support the contention that the masseter muscle was diffusely affected by a myopathic process. Although increased variation in fibre size (10–100  $\mu\text{m}$ ) was apparent, morphological abnormalities were otherwise slight except in one area (Fig. 3). This localized abnormality was thought to be an artefact resulting from previous electromyographic sampling of the muscle (Engel, 1967; Paakkari and Mumenthaler, 1974).

The most striking abnormality present, demonstrable with the ATPase reaction, was gross predominance and hypertrophy of type I fibres. Less than 1% of the fibres were type II. The normal masseter muscle contains approximately 57% of type II fibres (Ringqvist, 1974). The significance of gross fibre type predominance, or uniformity of muscle histochemistry, is at present undetermined. Experimental studies—neonatal neurectomy (Karpati and Engel, 1967a), cross-innervation (Karpati and Engel, 1967b), and aeneal culture of muscle (Askansas *et al.*, 1972)—all indicate the importance of neural factors in the development and maintenance of the fibre populations defined by the ATPase reaction, as does type-grouping in human disease (Brooke and Engel, 1966). In contrast, histochemical uniformity is encountered clinically in disorders of unknown aetiology which are at present classed as myopathic (Gonatas *et al.*, 1965; Nienhuis *et al.*, 1967; Lambert, 1974).

Administration of a general anaesthetic to our patient produced two abnormal reactions. On the first occasion, suxamethonium produced muscle rigidity with masseteric spasm and, on the second

occasion, when this agent was omitted, masseteric spasm and a biphasic postoperative temperature rise occurred. No immediate explanation for the latter event was apparent. The combination of a rise in body temperature and muscle rigidity occurring with suxamethonium raises the possibility of incipient malignant hyperthermia (Relton *et al.*, 1973). In this disorder a rise in temperature may be delayed until the postoperative period (Ryan and Papper, 1970; Beldavs *et al.*, 1971), and rebound rises also occur (Ratzlaff and Jenkins, 1972). The association between malignant hyperthermia, musculoskeletal disorders, and abnormal muscle biopsies is well recognised (Britt and Kalow, 1970; Ellis, 1973).

No specific musculoskeletal abnormality has been consistently observed to predispose to malignant hyperthermia. Some reports comment upon muscle hypertrophy in susceptible subjects (Steers *et al.*, 1970; King *et al.*, 1972; Harriman *et al.*, 1973). The pathological changes observed in muscle biopsies are variable and non-specific (Harriman *et al.*, 1973; Isaacs *et al.*, 1973; Ellis *et al.*, 1975).

The underlying factor in malignant hyperthermia is an abnormal metabolic response of muscle, often genetically determined, to a pharmacological trigger. Identification of susceptibility to this disorder is currently based upon *in vitro* pharmacological studies of suspect muscle, a technique not described at the time our patient was seen (Kalow *et al.*, 1970; Ellis *et al.*, 1972; Moulds and Denborough, 1974). The resting serum creatine phosphokinase level is not a reliable screening procedure (Ellis *et al.*, 1975). The elevation of serum activity of this enzyme in our patient is of doubtful significance. Changes of similar magnitude, usually maximal at 24–48 hours, occur after uncomplicated anaesthesia (Tammisto and Airaksinen, 1966; Innes and Stromme, 1973), while in malignant hyperthermia rapid rises in serum levels of up to 55 000 IU/litre have been recorded (Ratzlaff and Jenkins, 1972). Our patient, although exhibiting two features which should alert the anaesthetist to the possible onset of a hyperthermic incident (Relton *et al.*, 1972), did not develop the cardio-respiratory and metabolic features characteristic of the fully developed syndrome (Ellis, 1973). Malignant hyperthermia has developed in

patients in whom similar abnormalities have occurred during a previous anaesthetic (Relton *et al.*, 1968); it is possible that herald or incomplete forms of the disorder may occur.

However, anaesthetic agents, particularly suxamethonium, may provoke a variety of reactions in normal and diseased muscle. Muscle pains (Wylie and Churchill Davidson, 1972), hyperkalaemia (Cooperman, 1970), rhabdomyolysis (Jensen *et al.*, 1968) and contracture in myotonic disorders (Thiel, 1967) have been reported. Careful evaluation of individual cases is therefore mandatory; the pathophysiology of the episodes described in our patient remains uncharacterized. The clinical and histochemical abnormalities observed, however, suggest that the hypertrophy of the muscles of mastication merits further attention for both practical and theoretical reasons.

The authors wish to thank Mr Cook and Dr P. LeQuesne for permission to study the case, and Dr I. Verner who was associated with J.R.B.Y. with the anaesthesia on the second occasion, and Miss R. J. Biles for secretarial assistance.

## REFERENCES

- Askansas, V., Shafiq, S. A., and Milhorat, A. T. (1972). Histo-chemistry of cultured aneural chick muscle. Morphological maturation without differentiation of fibre types. *Experimental Neurology*, **37**, 218-230.
- Beldavs, J., Small, V., Cooper, D. A., and Britt, B. A. (1971). Postoperative malignant hyperthermia: a case report. *Canadian Anaesthetists' Society Journal*, **18**, 202-211.
- Britt, B. A., and Kalow, W. (1970). Malignant hyperthermia: a statistical review. *Canadian Anaesthetists' Society Journal*, **17**, 293-315.
- Brooke, M. H., and Engel, W. K. (1966). The histologic diagnosis of neuromuscular diseases: a review of 79 biopsies. *Archives of Physical Medicine and Rehabilitation*, **47**, 99-121.
- Cooperman, L. E. (1970). Succinylcholine-induced hyperkalaemia in neuromuscular disease. *Journal of the American Medical Association*, **213**, 1867-1871.
- Dubowitz, V., and Brooke, M. H. (1973). *Muscle Biopsy: a Modern Approach*. Saunders: London.
- Ellis, F. R. (1973). Malignant hyperpyrexia. *Anaesthesia*, **28**, 245-252.
- Ellis, R. F., Clarke, I. M. C., Modgill, M., Currie, S., and Harriman, D. G. F., (1975). Evaluation of creatine phosphokinase in screening patients for malignant hyperpyrexia. *British Medical Journal*, **3**, 559-561.
- Ellis, F. R., Keaney, N. P., Harriman, D. G. F., Sumner, D. W., Kyei-Mensah, K., Tyrell, J. H., Hargreaves, J. B., Parikh, R. K., and Mulrooney, P. L. (1972). Screening for malignant hyperpyrexia. *British Medical Journal*, **3**, 559-561.
- Engel, W. K. (1967). Focal myopathic changes produced by electromyographic and hypodermic needles. *Archives of Neurology (Chic.)*, **16**, 509-511.
- Gonatas, N. K., Perez, M. C., Shy, G. M., and Evangelista, I. (1965). Central 'core' disease of skeletal muscle. *American Journal of Pathology*, **47**, 503-523.
- Harriman, D. G. F., Sumner, D. W., and Ellis, F. R. (1973). Malignant hyperpyrexia myopathy. *Quarterly Journal of Medicine*, **42**, 639-664.
- Innes, R. K. R., and Stromme, J. H. (1973). Rise in serum creatine phosphokinase associated with agents used in anaesthesia. *British Journal of Anaesthesia*, **45**, 185-190.
- Isaacs, H., Frere, G., and Mitchell, J. (1973). Histological, histochemical and ultramicroscopic findings in muscle biopsies from carriers of the trait for malignant hyperpyrexia. *British Journal of Anaesthesia*, **45**, 860-868.
- Jensen, K., Bennike, K. A., Hanel, H. K., and Olesen, H. (1968). Myoglobinuria following anaesthesia including suxamethonium. *British Journal of Anaesthesia*, **40**, 329-334.
- Kalow, W., Britt, B. A., Terreau, M. E., and Haist, C. (1970). Metabolic error of muscle metabolism after recovery from malignant hyperthermia. *Lancet*, **2**, 895-898.
- Karpati, G., and Engel, W. K. (1967a). Neuronal trophic function: a new aspect demonstrated histochemically in developing soleus muscle. *Archives of Neurology (Chic.)*, **17**, 542-545.
- Karpati, G., and Engel, W. K. (1967b). Transformation of the histochemical profile of skeletal muscle by 'foreign innervation'. *Nature (London)*, **215**, 1509-1510.
- King, J. O., Denborough, M. A., and Zapf, P. W. (1972). Inheritance of malignant hyperpyrexia. *Lancet*, **1**, 365-370.
- Lambert, C. D. (1974). Uniform muscle histochemistry: a clinical and biopsy study. *Transactions of the American Neurological Association*, **99**, 120-125.
- Mancall, E. L., Patel, A. N., and Hirschhorn, A. M. (1974). Hypertrophic branchial myopathy. Idiopathic enlargement of the masticatory muscles as a neglected myopathic disorder. *Neurology (Minneap.)*, **24**, 1166-1170.
- Moulds, R. F. W., and Denborough, M. A. (1974). Identification of susceptibility to malignant hyperpyrexia. *British Medical Journal*, **2**, 245-247.
- Nienhuis, A. W., Coleman, R. F., Brown, W. J., Munsat, T. L., and Pearson, C. M. (1967). Nemaline myopathy. A histopathologic and histochemical study. *American Journal of Clinical Pathology*, **48**, 1-13.

- Paakkari, I., and Mumenthaler, M. (1974). Needle myopathy—an experimental study. *Journal of Neurology*, **208**, 133–138.
- Ratzlaff, E. H., and Jenkins, L. C. (1972). Malignant hyperthermia: a case report of successful management. *Canadian Anaesthetists' Society Journal*, **19**, 549–556.
- Relton, J. E. S., Britt, B. A., and Steward, D. J., (1973). Malignant hyperpyrexia. *British Journal of Anaesthesia*, **45**, 269–275.
- Relton, J. E. S., Creighton, R. E., and Conn, A. W. (1968). Fulminant hyperpyrexia associated with anaesthesia. *Anaesthesia*, **23**, 253–258.
- Relton, J. E. S., Steward, D. J., Creighton, R. E., and Britt, B. A. (1972). Malignant hyperpyrexia: a therapeutic and investigative regimen. *Canadian Anaesthetists' Society Journal*, **19**, 200–202.
- Ringqvist, M., (1974). Size and distribution of histochemical fibre types in masseter muscle of adults with different states of occlusion. *Journal of the Neurological Sciences* **22**, 429–438.
- Ryan, J. F., and Papper, E. M. (1970). Malignant fever during and following anaesthesia. *Anaesthesiology*, **32**, 196–201.
- Steers, A. J. W., Tallack, J. A., and Thompson, D. E. A. (1970). Fulminating hyperpyrexia during anaesthesia in a member of a myopathic family. *British Medical Journal*, **2**, 341–434.
- Tammisto, T., and Airaksinen, M. (1966). Increase of creatine kinase activity in serum as a sign of muscular injury caused by intermittently administered suxamethonium during halothane anaesthesia. *British Journal of Anaesthesia*, **38**, 510–515.
- Thiel, R. E. (1967). The myotonic response to suxamethonium. *British Journal of Anaesthesia*, **39**, 815–820.
- Wylie, W. D., and Churchill Davidson (1972). *A Practice of Anaesthesia*, pp. 741–742. Lloyd-Luke: London.