

Computerized tomography in the diagnosis of cerebral atrophy

MARGARET A. ROBERTS, F. I. CAIRD, K. W. GROSSART,
AND J. L. STEVEN

*From the University Department of Geriatric Medicine, and Division of Neuroradiology,
Institute of Neurological Sciences, Southern General Hospital, Glasgow*

SYNOPSIS Computerized tomograms were studied of 67 adults whose lumbar pneumoencephalograms were normal or showed ventricular dilatation with or without widening of the sulci. The maximum ventricular area, measured from 80×80 matrix printouts, correlates well with measures of ventricular size on the pneumoencephalogram. An area of 10 cm^2 is suggested as the upper limit of normal. The correlation between measures of sulcal width on computerized tomography and pneumoencephalography is less precise, but normal sulci and gross degrees of cortical atrophy can be identified.

The diagnosis of cerebral atrophy may be made *in vivo* by pneumoencephalography, which can show the presence of symmetrical ventricular dilatation and widening of the cortical sulci. The advent of computerized tomography (Ambrose, 1973; Hounsfield, 1973) has made the same phenomena demonstrable by a technique which is non-invasive and therefore more widely applicable. Gawler *et al.* (1976) have found excellent general agreement between measurements of various ventricular dimensions on computerized tomography and pneumoencephalography, but less satisfactory correlation for sulcal widening. The present study was undertaken to investigate the criteria by which simple measurements of these two aspects of cerebral atrophy might be made by computerized tomography.

METHODS

Sixty-seven adult patients aged 18-64 years, in the Institute of Neurological Sciences, Glasgow, were studied. All had a lumbar pneumoencephalogram and a computerized tomogram performed on the same admission. The pneumoencephalogram showed normal or dilated ventricles, without distortion of

their anatomy, though the common minor degrees of asymmetry (see Bruijn, 1959) were included. Both investigations were technically adequate for the assessment of ventricular size in 60 cases, and of the sulci in 49.

VENTRICULAR SIZE This was assessed from the lumbar pneumoencephalogram by three methods, as follows:

1. The radiographs were independently assessed by two experienced neuroradiologists, and the size of the ventricles scored as normal (0), or slightly (1), moderately (2), or grossly dilated (3). The sum of the two scores was termed the 'ventricular score'.

2. The width in millimetres of the lateral recesses of the cellae mediae of the ventricles was measured in a brow-up postero-anterior view, and termed the 'ventricular span' (Bruijn, 1959; Burhenne and Davies, 1963; Engeset and Skraastad, 1964).

3. The maximum width of the third ventricle, the width of the lateral ventricles, and the height of the lateral ventricles were measured and 'combined ventricular atrophy' graded as absent, slight, moderate, or severe, as described by Nielsen *et al.* (1966a).

Ventricular size was measured from the computerized tomogram as follows: the 80×80 matrix printout of the tomographic cut showing the largest area of ventricle was taken, and the area representing ventricle and occupied by cells of the matrix with a density of nine units or less was measured by planimetry; each cell represented an area of 0.09 cm^2 . The total area in cm^2 was termed the 'maximum ventricular area'. Cells within this area which had a density

of greater than 10 units—for example, choroid plexus—were considered to be within the ventricles. Figure 1 shows three examples.

DEGREE OF DILATATION OF CORTICAL SULCI This was assessed from the pneumoencephalogram in two ways.

1. The two radiologists graded the sulci as normal (0), or as showing focal (1) or general (2) dilatation, and the two scores were summed to give the 'sulcal score'.

2. The scheme of Nielsen *et al.* (1966b) was used to

grade 'cortical atrophy' as absent, slight, moderate, and pronounced or severe.

The degree of sulcal widening was measured on the computerized tomogram from the 80×80 printout of a higher tomographic cut showing cortex, but no ventricle, in two ways: (1) by counting the total number of low-density cells (density nine units or less), and (2) by counting the apparent maximum width (in low density cells) of the widest sulcus, chosen from the corresponding Polaroid print; each cell represented a width of 3 mm. Figure 2 shows three examples.

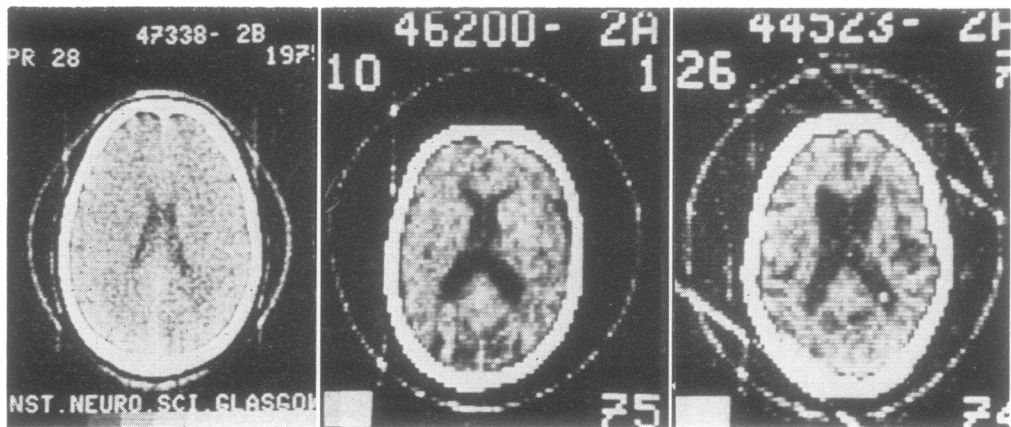


FIG. 1 Three maximum ventricular areas: left 6 cm^2 , centre 16 cm^2 , right 32 cm^2 .

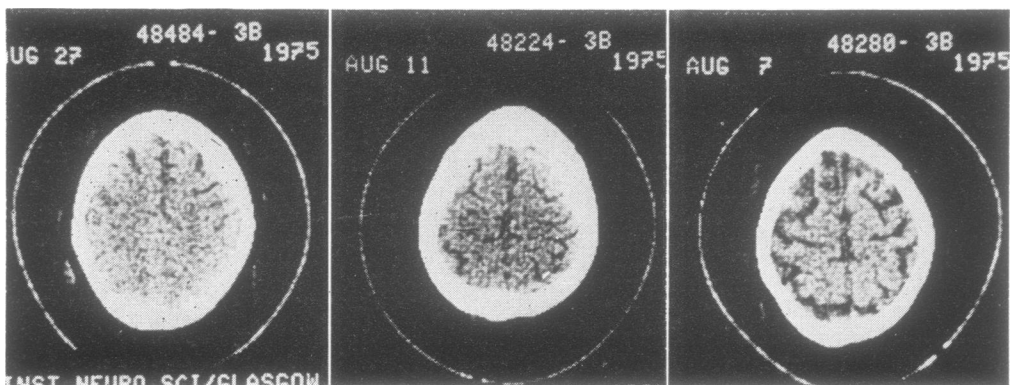


FIG. 2 Three measurements of cortical sulci: left, widest sulcus 3 mm, 16 low-density cells; centre, widest sulcus 6 mm, nine low-density cells; right, widest sulcus 12 mm, 102 low-density cells.

RESULTS

Figure 3 shows the relationship between the three methods of assessment of ventricular size on the lumbar pneumoencephalogram. There is clearly reasonable agreement between them.

Figure 4 shows the results of an intra- and interobserver variation study of the maximum ventricular area in 15 cases. The mean difference between the two observations in the intraobserver study was 0.7 cm², and in the interobserver study 0.9 cm², and the greatest difference was 3.6 and 2.5 cm² (18% and 25%) respectively.

The relations between the maximum ventricular area on the computerized tomogram, and the ventricular score and 'combined ventricular atrophy', are shown in Figs. 5 and 6 and Tables 1 and 2. Though there is considerable overlap between the groups, there is a clear general relationship. It seems reasonable to regard a maximum ventricular area of less than 10 cm² as normal, 10-14 cm² as showing slight, 14-18 cm² moderate, and greater than 18 cm² severe dilatation (*cf.* Fig. 1).

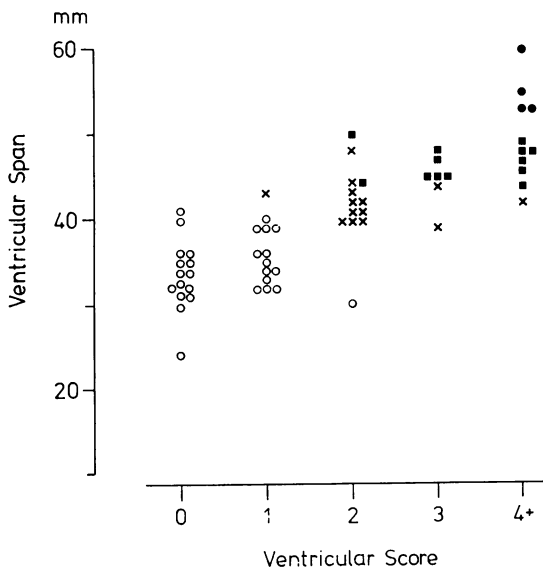


FIG. 3 Comparison of three methods of assessment of ventricular size on pneumoencephalography. Combined ventricular atrophy: absent ○, slight ×, moderate □, severe ●.

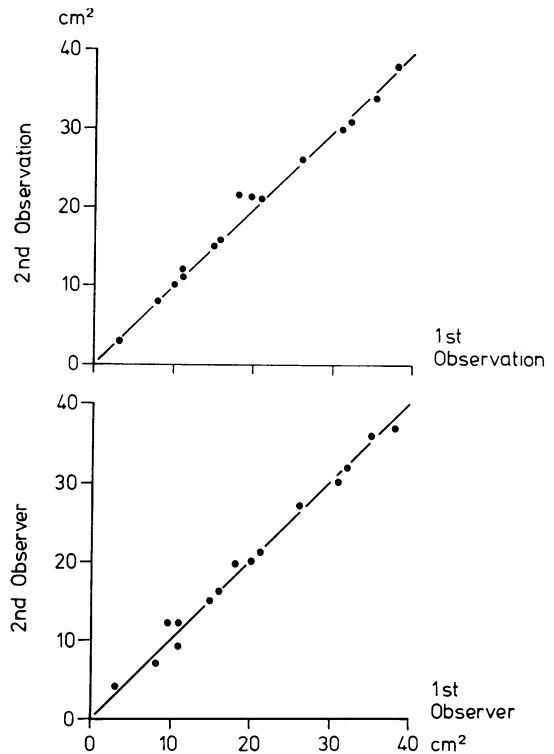


FIG. 4 Observer variation in measurement of maximum ventricular area: upper, intraobserver; lower, interobserver.

Figure 7 shows the relation between the ventricular span on the pneumoencephalogram and the maximum ventricular area on the computerized tomogram. There is a considerable scatter about the regression line, but the relationship is statistically highly significant.

Table 3 shows that there is an acceptable degree of agreement between the 'sulcal score' and 'cortical atrophy' on the pneumoencephalogram. Figures 8 and 9 show the relationship between the 'sulcal score' and 'cortical atrophy' on the pneumoencephalogram, and the number of low density cells on the computerized tomogram. Although the great majority of computerized tomograms from subjects without widening of the sulci on the pneumoencephalogram show five or fewer low density cells, only those whose cortical atrophy was considered on the pneumoencephalogram to be

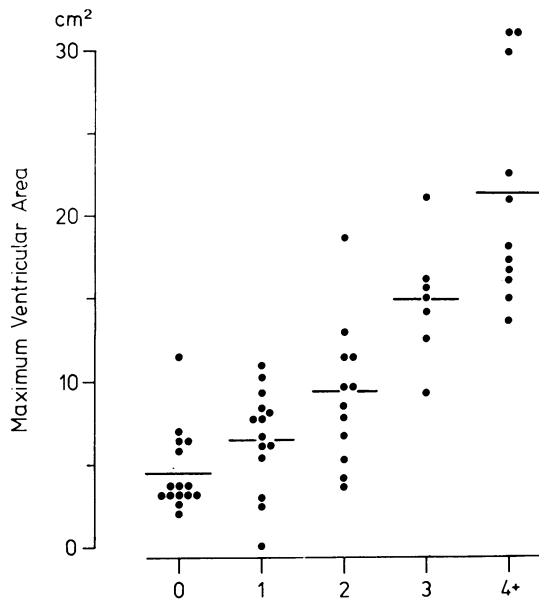


FIG. 5 Relationship of maximum ventricular area to ventricular score (abscissa). Horizontal bars indicate group mean.

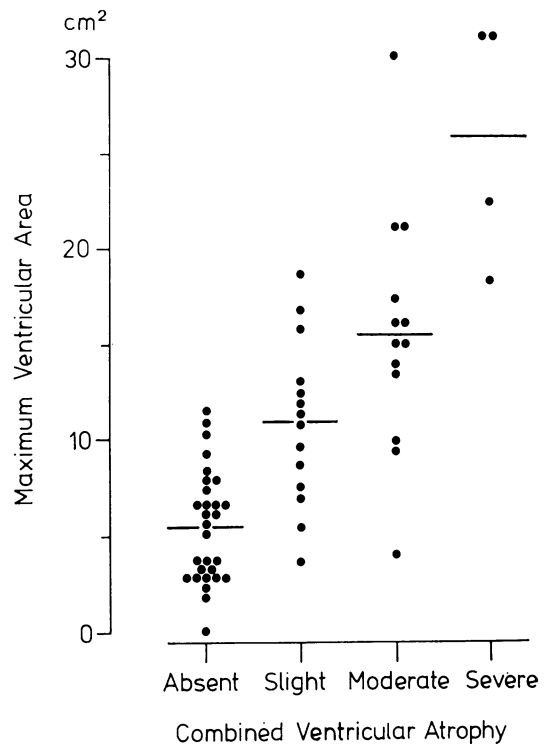


FIG. 6 Relationship of maximum ventricular area to degree of 'combined ventricular atrophy'. Horizontal bars indicate group mean.

TABLE 1

RELATIONSHIP OF MAXIMUM VENTRICULAR AREA ON COMPUTERISED TOMOGRAM TO 'COMBINED VENTRICULAR ATROPHY' ON PNEUMOENCEPHALOGRAM

	Combined ventricular atrophy			
	Absent	Slight	Moderate	Severe
No.	29	14	13	4
Maximum ventricular area: cm ² , mean ± SD	5.5 ± 2.9	10.9 ± 4.4	15.6 ± 6.4	26.1 ± 6.8

TABLE 2

RELATIONSHIP OF MAXIMUM VENTRICULAR AREA ON COMPUTERISED TOMOGRAM TO VENTRICULAR SCORE ON PNEUMOENCEPHALOGRAM

	Ventricular score				
	0	1	2	3	4+
No.	15	14	13	7	11
Maximum ventricular area: cm ² , mean ± SD	4.6 ± 2.4	6.5 ± 3.1	9.4 ± 4.1	14.9 ± 3.6	21.4 ± 6.8

TABLE 3

RELATIONSHIP BETWEEN CORTICAL ATROPHY AND SULCAL SCORE

Sulcal score	Cortical atrophy				Total
	Absent	Slight	Moderate	Severe	
0	22	1	0	0	23
1	8	3	0	0	11
2	4	1	3	0	8
3	0	0	2	3	5
4	0	0	0	2	2
Total	34	5	5	5	49

moderate or severe regularly fall outside this range.

Similarly, the apparent width of the widest sulcus on the computerized tomogram is well related to the presence of considerable degrees

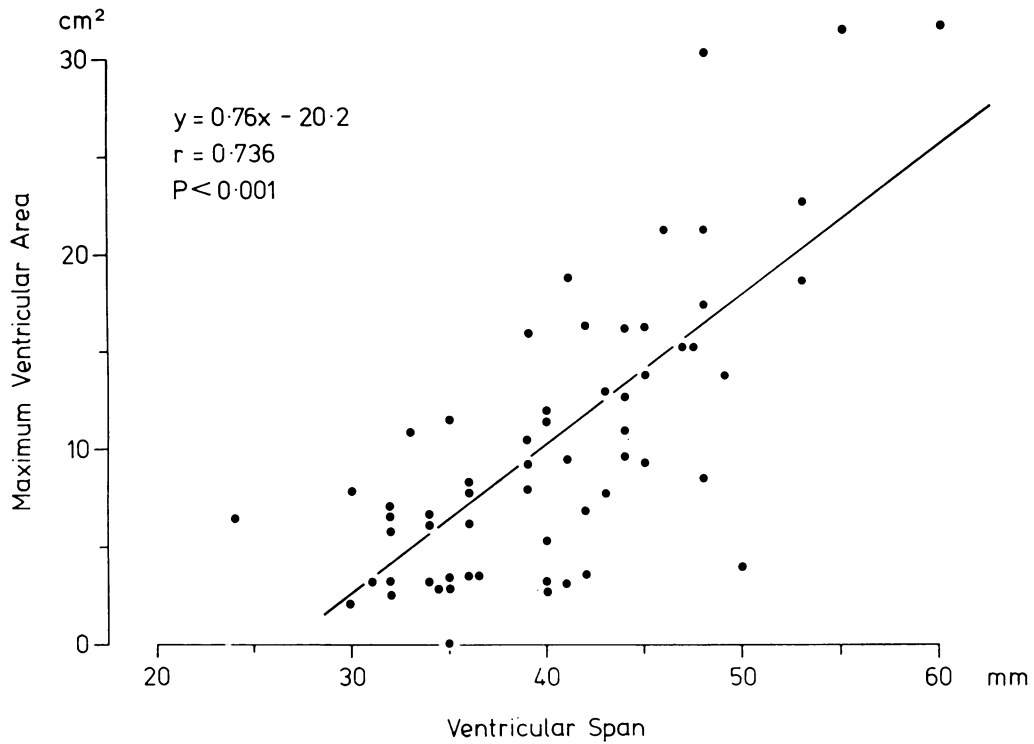


FIG. 7 Relationship of maximum ventricular area to ventricular span.

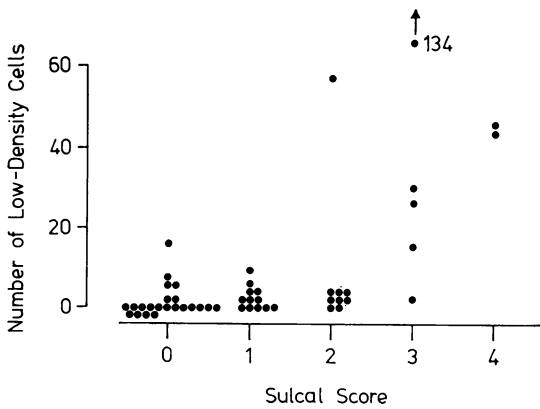


FIG. 8 Relationship of number of low-density cells to sulcal score.

of cortical atrophy as shown on the pneumoencephalogram (Tables 4 and 5), but lesser degrees are not so clearly represented (cf. Fig. 2).

TABLE 4
RELATIONSHIP OF CORTICAL ATROPHY TO WIDTH OF WIDEST SULCUS ON COMPUTERISED TOMOGRAM

Widest sulcus (mm)	Cortical atrophy				Total
	Absent	Slight	Moderate	Severe	
0	17	0	1	0	18
3	11	3	1	0	15
6	2	1	1	0	4
9	2	1	0	0	3
12+	2	0	2	5	9
Total	34	5	5	5	49

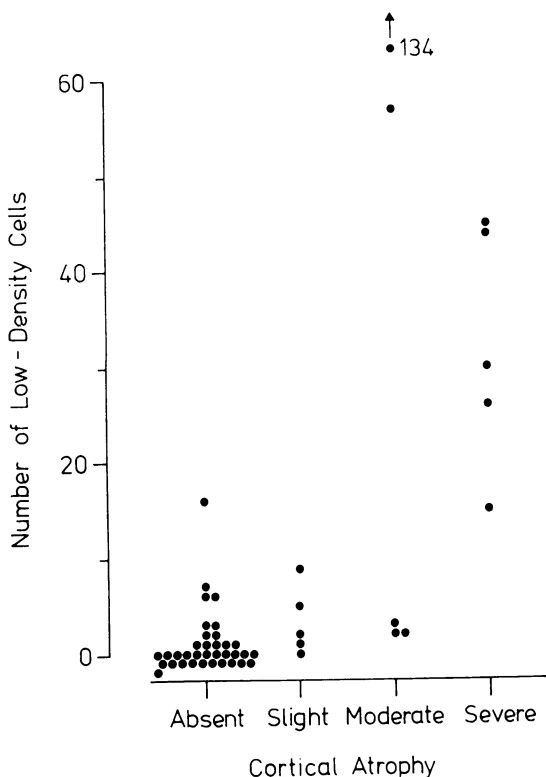


FIG. 9 Relationship of number of low-density cells to degree of 'cortical atrophy'.

TABLE 5
RELATIONSHIP OF SULCAL SCORE TO WIDTH OF WIDEST SULCUS ON COMPUTERISED TOMOGRAM

Widest sulcus (mm)	Sulcal score					Total
	0	1	2	3	4	
0	13	6	1	1	0	21
3	6	3	4	0	0	13
6	0	1	2	0	0	3
9	2	1	0	0	0	3
12+	2	0	1	4	2	9
Total	23	11	8	5	2	49

DISCUSSION

The complex shape of the ventricular system and the considerable degree of normal variation, particularly of the occipital horns, make measurement of its size extremely difficult. Many

methods have been proposed for the measurement of ventricular size on pneumoencephalograms, but Bruijn (1959) and Engeset and Skraastad (1964) have shown that no single measurement is superior to the 'ventricular span'; measurements which include the size of the head are in no way superior to those which do not. The method described by Nielsen *et al.* (1966a) is based on more measurements, while the simple 'ventricular score' takes account of the size of the whole ventricular system, rather than of the cellae mediae alone.

The measurement of the 'maximum ventricular area' on computerized tomograms is simple and, as Fig. 4 shows, reproducible. The shape on the printout was closely similar (allowing for the difference in presentation) to that displayed by the Polaroid photograph of the same tomographic cut.

Expression of the 'maximum ventricular area' as a proportion of the area enclosed within the inner table of the skull in the same cut did not alter to any significant degree the ranking order of subjects for ventricular size, and this procedure was therefore discarded. Gawler *et al.* (1976) describe a different technique for the assessment of ventricular size from the computerized tomogram. They use linear measurements made on the computer printout, and consider the ventricles to be represented by cells of 10 units or less (rather than nine units or less, as in the present study). They found an excellent correlation between measurements made by the two methods, although the measurements from the pneumoencephalograms tended to be slightly larger than those from the computerized tomogram.

Huckman *et al.* (1975) and Gyldensted and Kosteljanetz (1976) have described methods of measuring ventricular size from the Polaroid photographs of the computerized tomogram, but did not relate these measurements to findings on pneumoencephalography.

The measurement of sulci on the computerized tomogram is more difficult than that of ventricular size. Standard tomographic cuts are not always easily obtained, and normal sulci are not always demonstrable on 80x80 matrix scans (Gawler *et al.*, 1975). Low density areas may appear towards the vertex, occasionally for no clear reason, but more often when there is gross

ventricular dilatation, but these instances are relatively easy to exclude. The choice of an upper tomographic cut must often exclude areas of focal sulcal dilatation—for instance, at the frontal pole. For all these reasons there may well be discrepancies between the appearance and measurement of sulcal widening as shown by pneumoencephalography and computerized tomography, and it is therefore not surprising that the correlation between them is less satisfactory. However, the absence of cortical atrophy and the presence of severe atrophy can be identified with reasonable certainty (Tables 4 and 5).

Gawler *et al.* (1976) refrained from making actual measurements of cortical sulci on the computerized tomogram, but they noted that there was general agreement between observations based on the two methods. They put an upper limit of 4 mm on the pneumoencephalographic width of sulci, and from our study it seems reasonable to set a width of 3–4 mm as an appropriate upper limit of normal. Gyldensted and Kosteljanetz (1975) measured normal sulci from the Polaroid photographs and found a mean value of 3–4 mm, which correlated well with the generally accepted value found on pneumoencephalographs. Huckman *et al.* (1975) also suggest a normal value of about this order. Simple though both these latter methods are, we doubt the validity of measurements of 1 mm or less on Polaroid photographs.

The present study has demonstrated one way in which simple but objective measurements can be made on a computerized tomogram to establish the size of the ventricular system. Although the methods described for sulcal widening are less precise, the value of computerized tomograms for the diagnosis of cortical atrophy is apparent.

It is a pleasure to thank our colleagues in the Institute of Neurological Sciences, Glasgow for the opportunity to study patients under their care.

REFERENCES

- Ambrose, J. (1973). Computerised transverse axial scanning (tomography). Part 2: Clinical applications. *British Journal of Radiology*, **46**, 1023–1047.
- Bruijn, G. W. (1959). *Pneumoencephalography in the Diagnosis of Cerebral Atrophy*. Drukkerij H. J. Smits: Utrecht.
- Burhenne, H. J., and Davies, H. (1963). The ventricular span in cerebral pneumoencephalography. *American Journal of Roentgenology*, **90**, 1176–1184.
- Engeset, A., and Skraastad, E. (1964). Methods of measurements in encephalography. *Neurology (Minneapolis)*, **14**, 381–385.
- Gawler, J., Bull, J. W. D., du Boulay, G. H., and Marshall, J. (1975). Computerised axial tomography: the normal EMIScan. *Journal of Neurology, Neurosurgery, and Psychiatry*, **38**, 935–947.
- Gawler, J., du Boulay, G. H., Bull, J. W. D., and Marshall, J. (1976). Computerised tomography (the EMIScan): a comparison with pneumoencephalography and ventriculography. *Journal of Neurology, Neurosurgery, and Psychiatry*, **39**, 203–211.
- Gyldensted, C., and Kosteljanetz, M. (1975). Measurements of the normal hemispheric sulci with computer tomography. A preliminary study on 44 adults. *Neuroradiology*, **10**, 147–149.
- Gyldensted, C., and Kosteljanetz, M. (1976). Measurements of the normal ventricular system with computer tomography. *Neuroradiology*, **10**, 205–215.
- Hounsfield, G. N. (1973). Computerised transverse axial scanning (tomography). Part 1: Description of system. *British Journal of Radiology*, **46**, 1016–1022.
- Huckman, M. S., Fox, J., and Topel, J. (1975). The validity of criteria for the evaluation of cerebral atrophy by computed tomography. *Radiology*, **116**, 85–92.
- Nielsen, R., Petersen, O., Thygesen, P., and Willanger, R. (1966a). Encephalographic ventricular atrophy. *Acta Radiologica Diagnostica*, **4**, 240–256.
- Nielsen, R., Petersen, O., Thygesen, P., and Willanger, R. (1966b). Encephalographic cortical atrophy. *Acta Radiologica Diagnostica*, **4**, 437–448.