



Case report

Incarcerated ovarian herniation of the canal of Nuck in a female infant: Ultrasonographic findings and review of literature

Kwang Ho Choi ^a, Hye Jin Baek ^{b,*}

^a Research Institute for Convergence of Biomedical Science and Technology, Department of Thoracic and Cardiovascular Surgery, Pusan National University Yangsan Hospital, 20 Geumo-ro, Mulgeum-eup, Yangsan 50612, Republic of Korea

^b Department of Radiology, Gyeongsang National University School of Medicine and Gyeongsang National University Changwon Hospital, 11 Samjeongja-ro, Seongsan-gu, Changwon 51472, Republic of Korea

HIGHLIGHTS

- The canal of Nuck is an abnormal patent pouch of the parietal peritoneum extending to the round ligament of the uterus into the labia majora through the inguinal ring into the inguinal canal.
- Incomplete obliteration of canal of Nuck can result in either an inguinal hernia or a hydrocoele in female children.
- Awareness of ovarian herniation through the canal of Nuck and its embryologic mechanisms can be helpful for the identification of this disease and the prevention of its unexpected complication in clinical practice.

ARTICLE INFO

Article history:
Received 17 May 2016
Received in revised form
14 June 2016
Accepted 14 June 2016

Keywords:
Ultrasound
Inguinal hernia
Canal of Nuck
Ovary

ABSTRACT

Introduction: Inguinal hernia with containing the ovary presenting as a palpable groin mass is an uncommon congenital condition, and it may cause complications such as strangulation, torsion, and infertility. We present a case of ovarian herniation into inguinal canal with sonographic findings.

Presentation of case: A 15-day-old infant girl visited our hospital with the complaints of palpable mass in the right groin. On physical examination, a palpable non-movable mass was found in the right inguinal region, and it was irreducible. During sonographic examination, a well-circumscribed solid mass containing small cysts was found. Then, oophorectomy with high inguinal ligation was performed, and the patient was doing well after surgery.

Discussion: The canal of Nuck is an abnormal patent pouch of the parietal peritoneum extending to the round ligament of the uterus into the labia majora through the inguinal ring. When this canal obliterates incompletely, inguinal herniation of ovary or hydrocoele occur in the female children. In the clinical practice, ovarian herniation should be differentiated from a hernia containing intestine, fat, fluid, or lymph nodes. Therefore, a careful sonographic evaluation is mandatory to make an accurate diagnosis in female infants with palpable inguinal mass.

Conclusion: Ultrasound (US) with color Doppler US can be helpful to the diagnosis of ovarian herniation through the canal of Nuck and hernia-related complications.

© 2016 The Authors. Published by Elsevier Ltd on behalf of IJS Publishing Group Ltd. This is an open access article under the CC BY-NC-ND license (<http://creativecommons.org/licenses/by-nc-nd/4.0/>).

1. Introduction

Indirect inguinal hernia is one of the most common congenital anomaly requiring surgery in the pediatric patients with an incidence ranging from 0.8% to 4% [1]. It is seen more often in the first year of life, and the incidence increases up to 30% in premature

infants. Once the abdominal or pelvic organs slide through the defect into the hernia sac, they may become incarcerated and strangulated. Especially, in female infants, sliding inguinal hernias can contain the ovary, fallopian tube and rarely uterus which are usually caused by incomplete obliteration of canal of Nuck [2]. Since only a few cases are described in the literature, we present a case of inguinal hernia containing ovary in a 15-day-old female infant which was diagnosed with ultrasound (US). We also performed the relevant literature review regarding this congenital disease, and

* Corresponding author.

E-mail address: sartre81@gmail.com (H.J. Baek).

discussed its embryological background.

2. Presentation of case

A 15-day-old infant girl visited our hospital with the complaints of palpable mass in the right groin. She was delivered at 36 weeks of gestation (birth weight 2850 g, height 45 cm, and Apgar score 9/10) by normal vaginal delivery. At birth, there was no inguinal mass and her external genitalia appeared normal during her first examination. According to her parents, the palpable mass was found in the right inguinal region several hours ago and it became larger when she was crying or straining. There was no history of illness, vomiting, or pain before. On physical examination, this palpable mass was located in the right inguinal region and anterior labium major, and it was hard and irreducible with no overlying skin change. Her abdomen was soft and nondistended with normal bowel sounds. Laboratory findings were normal. US examination was performed because an incarceration of hernia was suspected. On gray-scale US, a well-circumscribed, oval solid mass was seen in the subcutaneous layer of the right inguinal region. This mass passed through the defect in the right inguinal canal, and it showed a heterogeneous hypochoogenicity containing small cysts. There was no evidence of peristalsis or visible fat within the mass, suggesting bowel or lymph node (Fig. 1A–C). Color Doppler US (CDUS) demonstrated the presence of blood flow toward the mass,

suggesting ovarian vessels. However, there was no blood flow within the mass, thus the strangulation was suspected (Fig. 1D, E). The sonographic diagnosis was an incarcerated right ovarian herniation through the canal of Nuck with possible strangulation. After that, emergent surgery was performed through an inguinal approach and the right ovary was found in the hernia sac with incarceration. Oophorectomy was performed for the patient because the herniated ovary was edematous with bluish color due to strangulation. A high ligation was also performed for preventing recurrence. The patient is doing well after surgery and discharged third postoperative day.

3. Discussion

In the pediatric population, inguinal hernia results from an incomplete obliteration of processus vaginalis (PV) developed at around the 6th month of fetal development [1]. PV is a small evagination of parietal peritoneum. According to gender, PV is accompanied by testis or round ligament of the uterus, and passes through the inguinal canal up to the scrotum or labium major. In the normally developing female fetus, PV is usually obliterated by 8 months of gestations. When complete closure of PV fails, the patent PV is named the canal of Nuck [1–4]. This structures results in an inguinal hernia containing bowel, omental fat, fluid, ovary, fallopian tube, rarely uterus and urinary bladder [5].

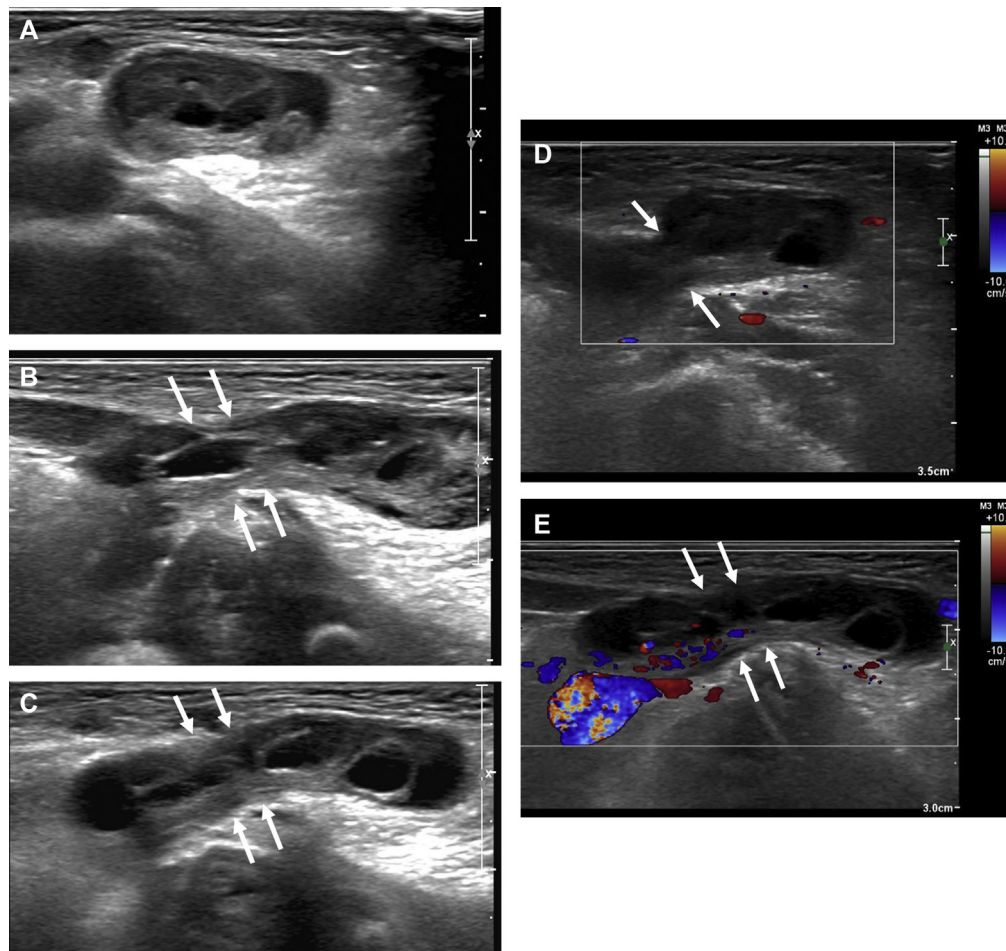


Fig. 1. A 15-day-old female infant presented with palpable mass in the right inguinal region. A–C. Transverse (A) and longitudinal (B, C) gray scale ultrasound (US) reveals a well-circumscribed, oval, hypoechoic solid mass with internal small cysts in the right inguinal area, and there is no evidence of peristalsis or fat within the mass. And the lesion extends to the abdominal cavity through the canal of Nuck (arrows). These sonographic findings suggest that the herniated content is the right ovary. D, E. On color Doppler US, blood flow is seen at the canal of Nuck, representing ovarian vessel. However, no blood flow was seen within the mass. This finding strongly suggests a strangulation of the ovary.

Although ovarian herniation of the canal of Nuck can occur at any age, they are most common in children [6]. Especially, in female infants, early diagnosis of ovarian herniation through the canal of Nuck is important because incarceration of the ovary is common which has been documented in 43% of cases [2]. Incarcerated ovarian herniation in infants increases a risk of torsion which results in the blockage of normal venous and lymphatic return of the ovary within the canal of Nuck. As increasing pressure of herniated sac by sustained vascular compromise, the herniated ovary can be infarcted with overlying tissue necrosis [7].

Herein, we present a case of incarcerated ovarian herniation of the canal of Nuck in an infant girl. On US, the herniated ovary demonstrated as a heterogeneously hypoechoic solid mass with small cysts and no blood flow within the mass. As is well-documented by previous reports, we also found that US was very useful to diagnose ovarian herniation with vascular compromise of the ovary.

For evaluating inguinal hernia, US examination with a high-frequency transducer is an easily available and accurate imaging modality of choice because it can be helpful to assess and characterize herniated contents due to excellent spatial and temporal resolutions. The sonographic diagnosis with an efficacy considered to be almost 100% in cases of inguinal hernia [8,9]. On US examination, ovarian herniation can be easily diagnosed when the herniated content shows a solid oval mass with small cystic components, representing ovarian follicles [6,8]. In addition, it is also possible to differentiate ovarian herniation from other types of inguinal hernia containing intestine, fat, fluid or lymph nodes, and to detect a complication of herniated contents by using high-resolution US with CDUS.

4. Conclusion

In conclusion, we present a case of incarcerated ovarian herniation of the canal of Nuck in a 15-day-old infant girl. The ovarian herniation was easily diagnosed by the characteristic US findings as described above. We also obtained additional information about perfusion state and viability of the herniated ovary on CDUS. Therefore, we suggested that the awareness of ovarian herniation through the canal of Nuck and its embryologic mechanisms can be helpful for the identification of this disease and the prevention of its unexpected complication in clinical practice.

Ethical approval

This was purely an observational case study. The patient's management and outcome were unaltered. Therefore, no ethical approval was required for this case report.

Funding

Nothing to declare.

Authors' contributions

1. Kwang Ho Choi: data design, data collection, literature review, manuscript writing and revision, review of final manuscript.
2. Hye Jin Baek: data collection and analysis, radiologic investigations, literature review, refinement of manuscript, review of final manuscript.

Conflict of interest

All authors declare that they have no conflict of interest.

Guarantor

Hye Jin Baek.

Consent

Written informed consent was obtained from the patient for publication of this case report and accompanying images. A copy of the written consent is available for review by the Editor-in-Chief of this journal on request.

References

- [1] E.K. George, A.M. Oudesluys-Murphy, G.C. Madern, P. Cleynert, J.G. Blomjous, Inguinal hernias containing the uterus, fallopian tube, and ovary in premature female infants, *J. Pediatr.* 136 (2000) 696–698.
- [2] B. Bronsther, M.W. Abrams, C. Elboim, Inguinal hernia in children: a study of 1000 cases and a review of the literature, *J. Am. Med. Womens Assoc.* 27 (1972) 522–535.
- [3] H. Yigit, I. Tuncbilek, S. Fitoz, N. Yigit, U. Kosar, B. Karabulut, Cyst of the canal of Nuck with demonstration of the proximal canal: the role of the compression technique in sonographic diagnosis, *J. Ultrasound Med.* 25 (2006) 123–125.
- [4] S.J. Park, H.K. Lee, H.S. Hong, H.C. Kim, D.H. Kim, J.S. Park, et al., Hydrocele of the canal of Nuck in a girl: ultrasound and MR appearance, *Br. J. Radiol.* 77 (2004) 243–244.
- [5] Y.C. Ming, C.C. Luo, H.C. Chao, S.M. Chu, Inguinal hernia containing uterus and uterine adnexa in female infants: report of two cases, *Pediatr. Neonatol.* 52 (2011) 103–105.
- [6] D.M. Yang, H.C. Kim, S.W. Kim, S.J. Lim, S.J. Park, J.W. Lim, Ultrasonographic diagnosis of ovary-containing hernias of the canal of Nuck, *Ultrasonography* 33 (3) (2014) 178–183.
- [7] T.E. Merriman, A.W. Auldist, Ovarian torsion in inguinal hernias, *Pediatr. Surg. Int.* 16 (2000) 383–385.
- [8] D.M. Yang, H.C. Kim, J.W. Lim, W. Jin, C.W. Ryu, G.Y. Kim, et al., Sonographic findings of groin masses, *J. Ultrasound Med.* 26 (2007) 605–614.
- [9] G. Jedrzejewski, A. Stankiewicz, A.P. Wiczorek, Uterus and ovary hernia of the canal of Nuck, *Pediatr. Radiol.* 38 (11) (2008) 1257–1258.