

Supratentorial intracerebral epithelial (ependymal) cysts: review, case reports, and fine structure

R. L. FRIEDE AND M. GAZY YASARGIL

From the Department of Neuropathology, Institute of Pathology and Clinic of Neurosurgery, University of Zurich, Switzerland

SUMMARY The paper concerns the rare supratentorial, intracerebral or convexity cysts in adults having a wall lined with an epithelium resembling ependyma. The clinicopathological aspects of such cysts are reviewed from 15 published cases and two specimens of the authors which could be examined with the electronmicroscope. These cysts manifest at a median age of 46 years as progressive, space occupying lesions with a fairly rapid clinical course of about one to two years. Twelve of 17 cysts were located in the frontal lobes, most were unequivocally intracerebral and none communicated with the lateral ventricle. Microscopic examination of the cyst wall disclosed some variance in structure, the most common feature being a monolayer of ciliated cells sitting on a very thin collagen membrane. One of the present cases was unique in that the compression by the cyst had caused a shell of infarction in the encompassing tissue. The fine structure of the cysts is described and compared with that of potential host tissues from which such cysts may originate. It is concluded that the cysts arise from displaced segments of the wall of the neural tube which correspond to the sites from which the tela chorioidea forms.

This report attempts to define the clinicopathological features of epithelium-lined supratentorial, intracerebral, or convexity cysts of adults, based on 15 published cases and two observations of our own. Both of the latter could be studied with the electronmicroscope; the only previous electronmicroscopic study of such a cyst was that of Ghatak *et al.* (1974). The report also contains a detailed comparison of the fine structure of the cyst wall with that of potential host tissues.

Review

The Table presents clinical and pathological data on 17 supratentorial epithelial cysts. The vast majority were unequivocally intracerebral, but for some the description is ambiguous and the cysts of Patrick (1971) and case 1 of Jakubiak *et al.* (1968) were probably primarily extracerebral, invaginating into the hemispheric surface. Median age of the patients was 46 years (range 22 to 74 years). There is a two to one preference for females but sample-size does not suffice to establish this trend. Most patients had a short history extending over one to two years;

none had an unbroken progression of symptoms from infancy. Migraine for 35 years, and a period of seizures between the age of 2 and 6 years were the only extended histories, and these were not unquestionably related to the presence of a cyst. Seizures or attacks of unconsciousness are a common presenting symptom being reported for half of the patients. Other manifestations include a progression of localising neurological deficits such as hemiparesis, hemihypaesthesia, hemianopsia, or ataxia, along with changes in memory or personality, confusion, drowsiness, headaches, or mental deterioration. A space-occupying process is evident from shifts across the midline, angiographic data, or papilloedema.

Eleven of the cysts were on the left side, six on the right, most commonly (12 cases) in the frontal lobes or frontoparietal; three cysts were central to parietal and only two temporoparietal. All cysts were large, 4 cm or more in diameter, and most occupied much of the thickness of the hemispheric wall. Many cysts had their entire perimeter encompassed by brain tissue; for others an apex was exposed at the hemispheric surface, presenting as a thin opaque membrane liable to rupture upon exposure. The inner surface of the cyst was mostly smooth, uniloculated, bordered by apparently intact white matter. Only one case had

Table Case reports on intracerebral or convexity gliependymal cysts

Author	Sex, age (yr)	Clinical course	Macroscopic findings	Microscopic structure of cyst wall
Zehnder (1938) case 6	M 34	Attacks of headache 1 yr, later associated with unconsciousness. Hemiparesis, papilloedema	R frontal, fist-sized, floor of cyst soft, yellow-whitish. Turbid milky fluid	Ciliated, cuboid to cylindrical epithelium on collagen membrane. Yellow pigment in basal portion of the cells.
Šimek and Gutmann (1949)	F 35	Seizures between 2–6 yr; recur since 21 yr. Terminal status epilepticus	L frontal to sulcus centralis 3 × 4 × 4 cm	Variable: nonreactive white matter; or ependyma or flattened mesothelial cells on connective tissue
Jakubiak <i>et al.</i> (1968) case 1	F 74	Seizures for 5 yr; 8 mm lateral shift on echo. Recovery postsurgery	L frontoparietal, parasag. Opaque membrane at cortical surface; 2 cm tissue to ventricle. Clear fluid, 280 mg/ml protein	Ciliated epithelium on glia; also papillary fronds with connective tissue core
	M 49	Headache, nausea, vomiting for 1 w	L frontal, abutting falx 100 ml clear fluid	Mature ependymal cells on brain tissue. Flat mesothelial cells on outer, meningeal surface
Argyopoulos and Heppner (1970)	M 31	Seizures for 1 yr. Disturb. vision, sensib. Recovery postsurgery	R temporoparietal, goose-egg size, subcortical. Clear fluid. Additional cysts on floor of middle fossa	Partially ciliated ependyma on glial tissue
Patrick (1974)	F 58	Diplopia 1 yr; staggering, sensory def., personality change; shift of mid. cer. a. Recovery postsurgery	R temporal, 60 ml. No evidence of cortical undermining	Non-ciliated, low cuboidal epithelium. Illustration suggests connective tissue basis
Tandon <i>et al.</i> (1972) case 1	F 36	Seizures 3 m; hemianopsia; papilloedema. Recovery postsurgery	L frontal; surface membrane continuous with pia-arachnoid; convolutions intact. 50 to 75 ml opalescent fluid, 850 mg/ml protein	Ciliated columnar epithelium. Illustration suggests connective tissue lining
	F 35	Headache 18m, papilloedema, optic atrophy. 8 mm lateral shift on echo. Recovery postsurgery	L frontal; lateral ventricle forms base of cyst. Opalescent fluid, 118 mg/ml protein	Ciliated columnar epithelium; fibrous wall, papillary fronds with connective tissue core
Bhandari (1972) case 4	F 49	Rigidity of L arm and leg, tremor 2 yr. Hemihyphaesthesia. Recovery postsurgery	R parietal, parasagittal, 5 cm abutting falx, impression in cortex. Clear fluid, 40 mg/ml protein	Flattened ependymal cells on collagen fibres
Bouch <i>et al.</i> (1973) case 1	F 64	Headache, mental deterioration 1 yr. Death	R frontal, subcortical; 6 × 4 cm; clear fluid	Ciliated cuboidal cells on white matter, minimal gliosis
	F 60	Hemiparesis—hyphaesthes. 1 y. Headache, memory def. Death.	R frontoparietal, small superficial exposure, 6 × 4 cm, clear fluid	Non-ciliated, flat cuboidal cells on gliotic white matter. Focally interposed connective tissue layer
Bouch <i>et al.</i> (1973) case 3	F 52	Confusion, drowsy, tremor, hemiparesis, hemihyphaesthesia 8 m. Death	L centrum semiovale, subcortical 4 × 3 cm	Epithelial cells, some ciliated, on gliotic white matter; focally deficient epithelium
Ghatak <i>et al.</i> (1974)	F 43	Seizures, headaches, hemianopsia, papilloedema. Died 3 m postsurgery from Hodgkin's disease	L temporoparietal, exposed, 7 × 7 × 5 cm	Low cuboidal cells without cilia, partly on white matter, partly on connective tissue membrane
MacGregor <i>et al.</i> (1976) case 1	M 38	Seizures 6 m, hemiparesis; surgery; continued seizures; reoperation 2 yr later	L frontoparietal, exposed surface. Milky fluid, 45 mg/ml protein. Fluid brownish on 2nd surgery	Columnar epithelium on glia. Second surgery; occasional cilia, connective tissue underneath epithelium
	M 22	Seizures, hemiparesis for 36 h	L frontal, 6 × 4 cm. Turbid fluid, 11 mg/ml protein	Cuboidal to low columnar cells, most ciliated, on collagen membrane
Present case 1	F 62	Migraine for 35 yr. Apathy 18 m, tremor, ataxic gait, blurred speech, loss of recent memory. Seizures 1 m. Hemiparesis. Angiogram: shift to right. Died 2m postsurgery from pulmon. embol.	L frontal, exposed at second frontal gyrus. 7 × 8 × 11 cm; clear slightly xanthochromic fluid	Non-ciliated columnar epithelium on connective tissue membrane
Present case 2	M 37	Attacks of vertigo, nausea, some with unconsciousness, for 1 yr. Recovery postsurgery	L frontal, occupies most of frontal lobe, exposed between gyr. front. sup. and medius. Turbid whitish fluid, 215 g/l protein	Ciliated cuboidal epithelium, thin collagen lamina, on white matter

multiple cysts. None of the cysts communicated with the lateral ventricle, although some were separated from it only by a thin layer of white matter. Many cysts compressed or displaced the lateral ventricles. Seven of the cysts contained clear fluid, six an opalescent, milky, or turbid fluid. The protein content was determined for seven cases, values ranging between 11 and 580 g/l. Surgical treatment of the cysts consisted of a wide resection of the dome of the cyst, often combined with resection of its floor opening a passage into the ventricle. Patients so treated recovered or they had died of intercurrent diseases unrelated to the cyst. Cases without surgery succumbed.

All cysts had an epithelial lining varying from flattened to low cuboidal or cylindrical, on occasion focally multilayered. Cilia were found in 10 cysts; for four the epithelium abutted glial tissue without any intervening elements. Thirteen cysts had a thin membrane or a layer of connective tissue between the epithelium and the white matter, at least in parts of the cyst wall. Occasionally the membrane would rise in fronds or villi with a connective tissue core. For four cysts the juxtaposition of epithelium on glia, and epithelium on connective tissue was specifically mentioned. The thin membrane of connective tissue may not be readily apparent in HE stained sections but is brought out sharply with collagen or reticulum stains. An indication of its presence is given if the subepithelial tissue cleaves, forming a sharply delineated sheet of epithelial cells meandering above the subjacent white matter.

A few notes are in order on the selection of cases for these statistics: not included were the incidental gliopendymal cyst of the olfactory bulb of a 70 year old woman reported by Baillie and Littler (1973) and the 40 year old woman of List and Williams (1961) in whom the first surgery had shown ciliated epithelium, whereas reoperation two years later showed a non-cornifying, stratified squamous epithelium and a mucinous cyst content. Furthermore, there are several references to cysts in infants or children having a glious wall lined with ependyma. These cysts behaved like arachnoid cysts, being located within the subarachnoid space and overlying the cerebral surface, such as two of the 12 supratentorial cysts of Aicardi and Bauman (1975), three of the five chiasmatic cysts of Harrison (1971) and the large interhemispheric cyst in a newborn containing choroid plexus of Loeser and Alvord (1968). Furthermore, we excluded the considerable number of case reports on infratentorial gliopendymal cysts particularly those of the tentorial hiatus, or the cisterna ambiens, respectively, or those in a retrocerebellar location; a general review of these lesions and their relations to arachnoid cysts was published recently (Friede, 1975).

Case reports

CASE 1

An abstract of the history of this 62 year old woman is in the Table. Necropsy examination of the brain disclosed a roughly rectangular 12×25 mm opening left precentral in the region of the second frontal gyrus (Fig. 1). The membrane covering the opening had been removed during surgery and a gliopendymal cyst was diagnosed by biopsy. The opening was fringed by normal gyri and led into a large cavity, expanding immediately underneath the hemispheric surface to a size of $7 \times 8 \times 11$ cm and occupying much of the white matter of the frontal lobe (Fig. 1). The floor of the cavity was formed by a membrane, 1 to 2 mm thick, corresponding to the dorsolateral wall of the frontal horn and pouching into it. There was no communication between cyst and ventricle. The entire perimeter of the cyst, excepting only the edges of the superficial porus and the membrane bordering the ventricle, was encompassed by a layer of softening and necrosis having a fairly uniform thickness of 2–4 mm. At the superficial porus the cortical ribbon could be traced turning inside the cyst cavity where it continued for approximately 10 to 15 mm to become necrotic from there on, being continuous with the necrotic white matter encompassing the cyst.

Microscopic examination of the biopsy specimen (superficial membrane) and of the entire perimeter of the cyst at necropsy gave similar results. The cyst wall was lined by a monolayer of low cuboidal cells lacking cilia; no goblet cells or mucin were found in any part. The epithelium sat on a thin membrane of connective tissue which was often difficult to distinguish in HE sections, but stained clearly with collagen and reticulum stains (Fig. 2, inset). Focally short epithelium-lined tufts of glial tissue projected into the cyst cavity. The membrane abutted a zone of organising infarction with early cavitation and numerous macrophages. The outer boundary of the zone of infarction generally paralleled the surface of the cyst, following its perimeter closely. The glial membrane bordering the ventricle had ependyma on glia on its inner side, and a connective tissue membrane with cyst epithelium at the outer.

Electronmicroscopic examination of several portions of the cyst wall was done on formalin-fixed specimens, postfixed in osmium tetroxide in 1% cacodylate buffer, 0.1 M. Specimens were embedded in Araldite, and sections stained with uranyl acetate and lead nitrate. The cyst membrane showed a monolayer of flattened cells with sparse, widely spaced microvilli of irregular length, none clavate, lacking any surface coating (Fig. 2). No cilia or centrioles were found. The lateral surfaces of the cells had

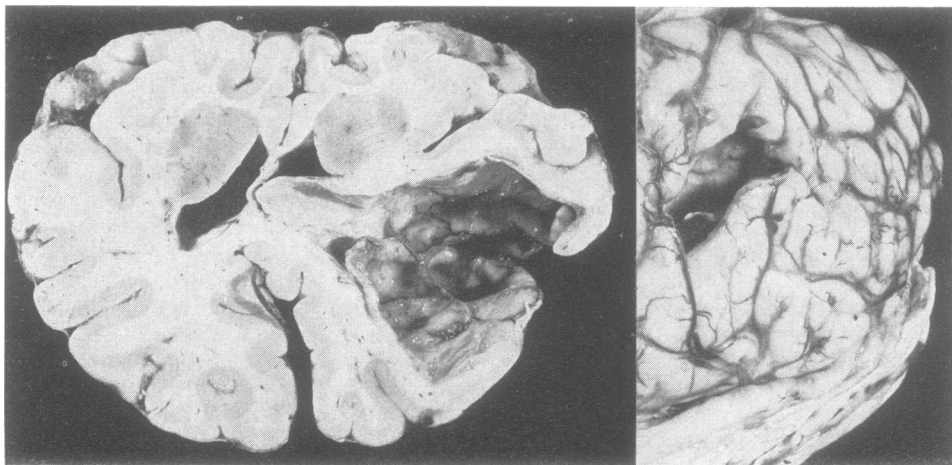


Fig. 1 Case 1. Left: cyst opening, fringed by normal gyri, at the lateral surface of the left frontal lobe: the membrane covering the opening had been removed surgically. Right: the cyst extends up to the frontal horn of the left lateral ventricle without communicating with it. There is subfalcial herniation and deformation of the ventricles. The cerebral cortex turns necrotic shortly after folding onto the inner surface of the cyst; a thin shell of organising infarction encompasses the remainder of the cyst surface except for the thin tissue membrane bordering the ventricle.

plicated, interdigitating membranes with numerous zonulae adherentes in which the intercellular gap of 200 to 250 Å was filled with an amorphous electron-dense material (Fig. 3). The subjacent cell membranes had increased density and electron-dense tonofilaments projected into the cytoplasm, often at a steep angle. Tight junctions (zonula occludens) were not found. The basal cell membranes had scattered pinocytotic vesicles and were bounded by a distinct basement membrane abutting a felt of collagen fibres (Fig. 3). The cytoplasm of the epithelial cells varied in electron-density from one cell to the next, rather dark cells bordering light ones. It contained filamentous material, large vesicles, rough endoplasmic reticulum, and relatively few mitochondria—that is, much fewer than seen in normal ependyma or in case 2. The nuclei were oval or rounded, with distinct nucleoli and a rather homogeneous chromatin. These aspects were very similar to the cyst reported by Ghatak *et al.* (1974).

CASE 2

For an abstract of the history of this 27 year old male see the Table. Only a biopsy specimen was available for light and electronmicroscopic examination. Light microscopic examination disclosed a columnar epithelium with abundant cilia on a non-reactive white matter (Fig. 4). A very thin layer of argyrophilic fibres was interposed between the epithelium and the white matter. No glycogen was

found in the cells, nor was there light microscopic evidence of mucin or goblet cells.

Electronmicroscopic examination (Figs. 4, 5; methods the same as for case 1) disclosed a profusion of cilia and microvilli at parts of the cyst wall. All cilia showed the typical nine paired tubules plus a central pair, and no abnormal forms were seen. The microvilli were of uniform length, some being clavate; many microvilli showed an irregular, amorphous, electron-dense coat, often attached in lumps to the surface of the villus. Some parts of the cyst wall were non-ciliated and showed fewer microvilli, reminiscent of the lining in case 1. The lateral borders of the cells were plicated and interdigitating, containing numerous zonulae adherentes with increased membrane density, tonofilaments projecting obliquely into the cytoplasm. The 200 Å wide junctional gap contained amorphous dense material varying somewhat in amount from one junction to the other. Rarely was there a hint of a linear midplane condensation, but no distinct midplane lamina with enlargement of the intercellular gap was seen. The basal portion of the cell membrane formed an abundance of pinocytotic vesicles and was situated on a distinct basement membrane abutting a very thin stratum of collagen fibres immediately overlying glial tissue. Compared with case 1, mitochondria were much more numerous. The profiles of the nuclei were less regular, showing indentation of the nuclear membrane and aggregation of chromatin

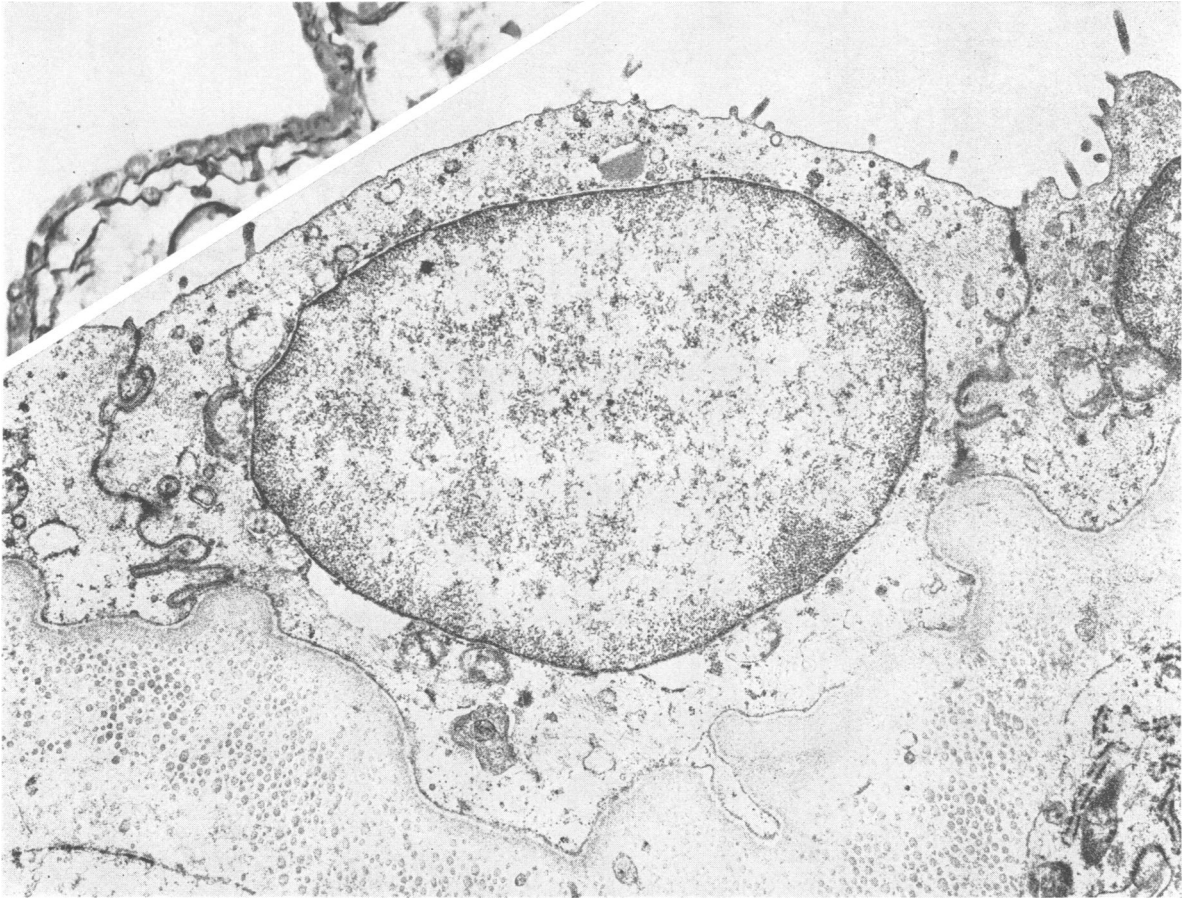


Fig. 2 Case 1. Inset: reticulum stain discloses tenuous connective tissue membranes underneath the non-ciliated low cuboidal epithelium lining the cyst. $\times 400$. Electronmicroscopy shows a low cuboidal epithelium with few microvilli and intensely plicated intercellular borders resting on a thick basement membrane. $\times 12\,370$.

in larger complexes. A small fraction of the cells contained membrane-lined cytoplasmic vesicles filled with a uniform, fine granular, electrondense material (Fig. 5); these occurred mostly in the apical portion of the cell and were interpreted as secretory vesicles. On average these cells had fewer cilia, but centrioles and cilia were definitely seen for many. Nowhere did one see the alternating arrangement of ciliated cells and non-ciliated goblet cells characteristic of respiratory epithelia.

Discussion

These 17 cases of supratentorial epithelial cysts are sufficiently characteristic to distinguish them from other fluid-filled cystic lesions such as the intraventricular colloid cysts or the extracerebral arach-

noid cysts. The high average age of 47 years is surprising for a lesion presumed to be of maldevelopmental origin, all the more as the symptoms, once manifest, progress rapidly, comparable with a neoplasm. Yet there is no evidence of neoplastic transformation of the cyst wall. Rather, the expansion of the cysts appears to be from active secretion of fluid into the cyst cavity. The unique findings in our case 1 support this assumption: the cyst was encompassed by a shell of infarcted tissue, indicating that the compression by the cyst had exceeded the capillary pressure in the adjacent tissue. This process is incompatible with the assumption that the cyst fills from a passive transudate from the blood or from the fluid in the extracellular compartment. The high protein content of the cyst fluid in seven cases without evidence of necrosis also speaks for a

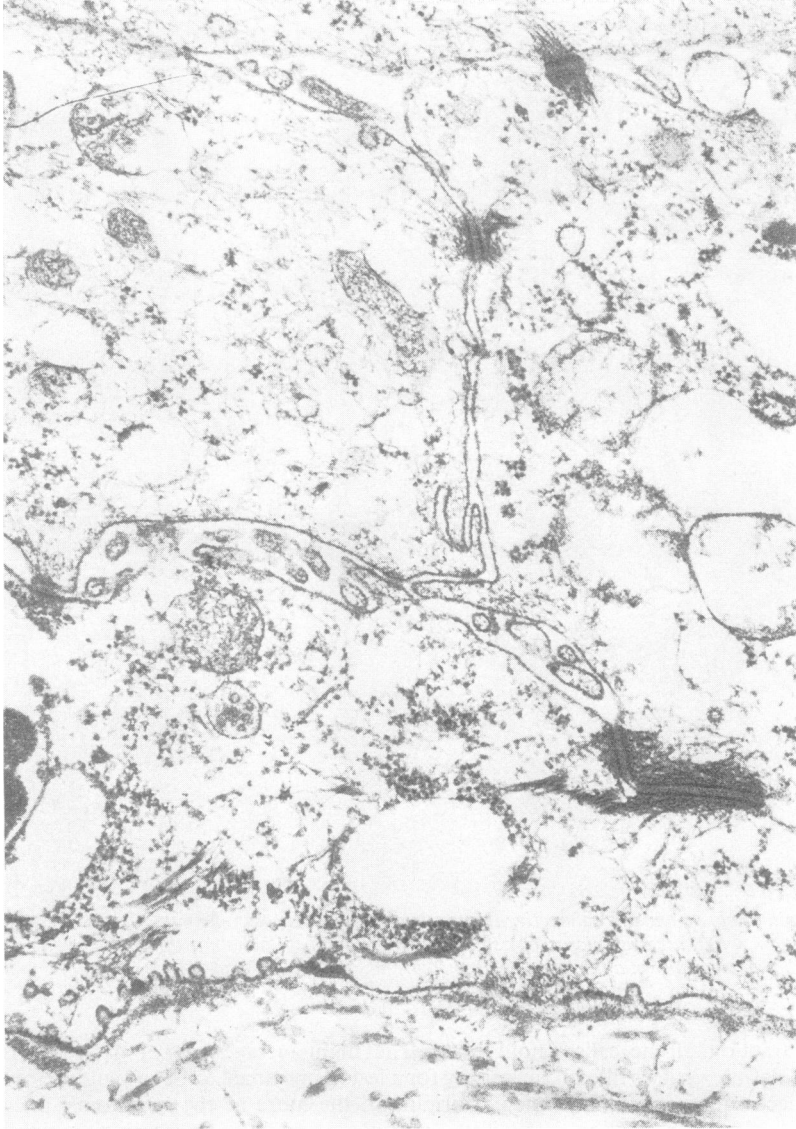


Fig. 3 Case 1. The lateral surfaces of the epithelial cells are joined by numerous zonulae adherentes. The basal cell plasma membrane abutting the basement membrane shows scattered pinocytotic vesicles. $\times 35\ 800$.

secretory process. Finally, the presence of numerous pinocytotic vesicles in the epithelia is a feature characteristic of cell layers having a high rate of transcellular fluid transport.

The composition of the cyst wall is particularly important to the surgical pathologist, as a connective tissue membrane covered with either non-ciliated or with ciliated cells resembling ependyma presents him with conflicting observations. The connective tissue cannot be reconciled with normal ventricular wall, nor the profusion of cilia found in some cysts with

choroid plexus. Interpretation of these aspects is important for the understanding of the origin of the cysts.

No serious consideration needs to be given to their distinction from porencephaly, being a residual defect of the hemispheric wall caused by an encephaloclastic process that produces a cavity with glial walls, communicating with the ventricle as well as with the subarachnoid space. Porencephalies never act as expanding, space-occupying processes.

As some of the cysts may have originated epi-

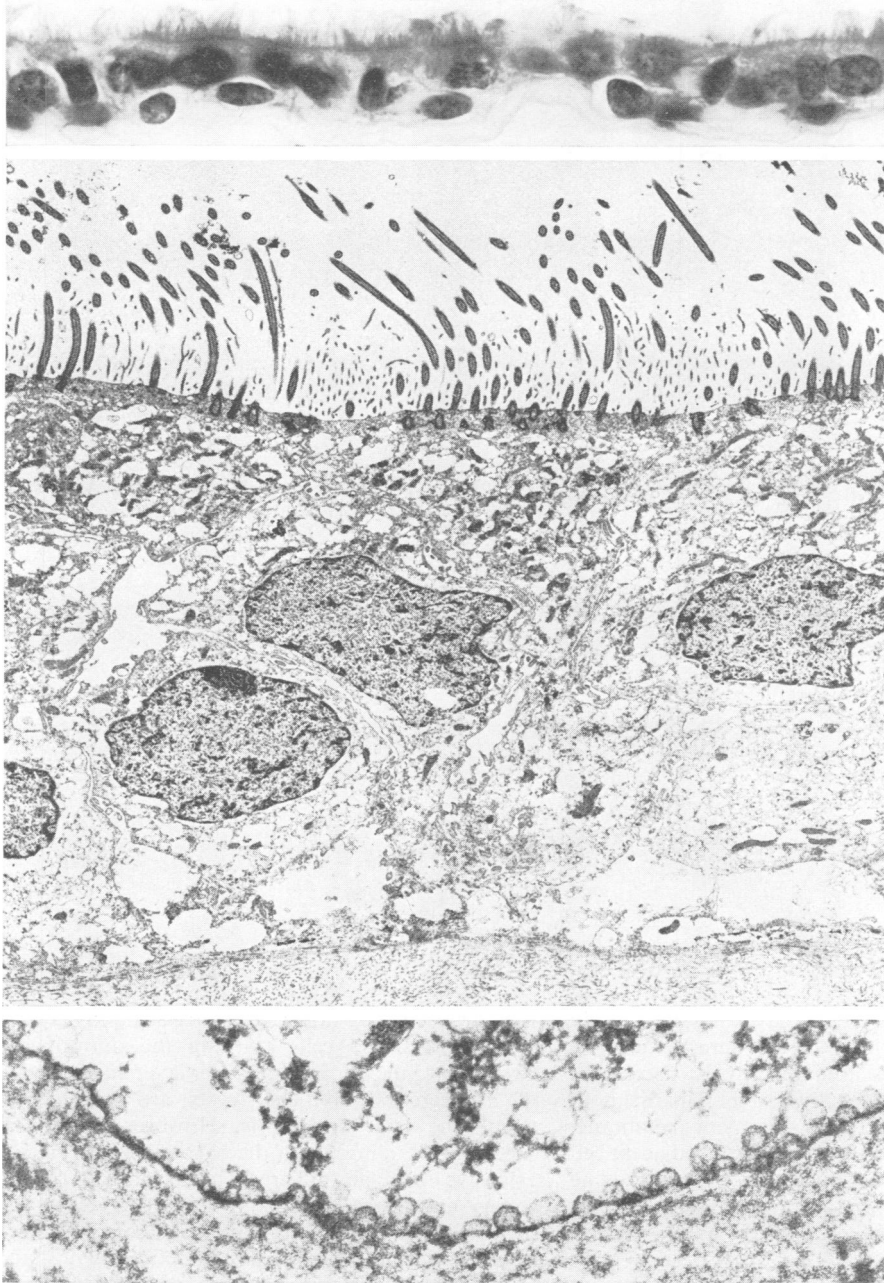


Fig. 4 Case 2.
Top: ciliated epithelial cyst lining, H.E., $\times 800$.
Middle: epithelium contains abundant cilia and microvilli and rests on a basement membrane abutting collagen fibres. $\times 5300$.
Bottom: basal cell membrane with profusion of pinocytotic vesicles. $\times 54\ 500$.

cerebral at the convexity, their derivation from arachnoid cysts needs to be considered, with particular attention to the interface between arachnoid and dura membranes; a pouch projecting from this interface may well generate a cyst. Electronmicro-

scopic studies of this interface (Andres, 1967; Waggner & Beggs, 1967; Nabeshima *et al.*, 1975) show that the outermost portion of the arachnoid membrane forms a compact layer, the barrier layer, composed of a sheet of flattened, interdigitating cells

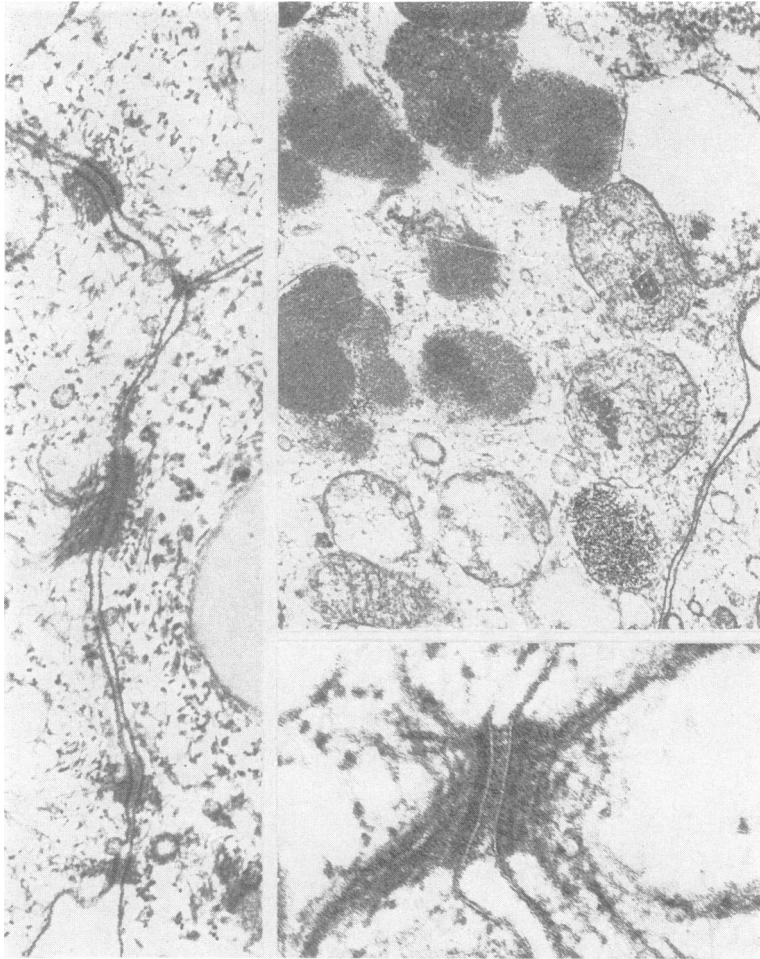


Fig. 5 Case 2. Left and bottom: abundance of intercellular junctions of the zonula adherens type. $\times 54\,500$ and $\times 120\,800$. Top right: cytoplasmic vesicles, presumably secretory, filled with a finely granular electron-dense material. $\times 35\,800$.

with many mitochondria; this layer adheres tightly to the innermost cell layer of the dura mater. The cells of the barrier layer are joined by extensive tight junctions and desmosomes; toward the subarachnoid space they are bounded by a basement membrane, and pinocytotic vesicles are found in the adjacent cell membranes. These data, however, pertain to the fine structure of the arachnoid-dura interface in laboratory animals; it is not established that a similar adherence exists in man. Yet, the barrier layer deserves consideration as a potential origin of expanding cysts, and it may, indeed, be more relevant to the pathogenesis of true arachnoid cysts than the commonly assumed developmental mid-plane-cleavage of this membrane (Starkman *et al.*, 1958). The arachnoid trabecules are formed of clear cells joined by desmosomes and having fragmentary basement membranes (Lopes and Mair, 1974);

these trabecules do not appear to be as tightly layered as the arachnoid cells abutting the dura mater. Common to the arachnoid barrier layer and the walls of intracerebral epithelial cysts are a basement membrane and pinocytosis. However, the intracerebral cysts differ from the barrier layer in having extensive zonulae adherentes instead of desmosomes and tight junctions; moreover there are microvilli and cilia. Cilia have been seen in a very small number of arachnoid villus core cells (Shabo and Maxwell, 1968) but the arachnoid barrier layer is typically devoid of any surface differentiations and is tightly attached to a loose layer of flattened dual fibrocytes, the dural border cells, which by their cleavage form the subdural space (Nabeshima *et al.*, 1975). In summary, therefore, one must reject the assumption of an arachnoid origin of intracerebral epithelial cysts.

The frequency with which cilia are found in the cyst epithelium suggests ependyma, but there is no basement membrane in ependyma except where it abuts capillaries, nor is there a collagen membrane, nor does the basal portion of the ependymal cells show a profusion of pinocytotic vesicles. On the other hand, extensive basement membrane formation has been found in myxopapillary ependymomas where ependymal cells abut a connective tissue stroma (Rawlinson *et al.*, 1973). It is unlikely that cysts acting as expanding lesions originate from an outpouching of ependyma-lined ventricular wall. Markers of high molecular weight may pass through the intercellular clefts between ependymal cells (Brightman, 1965) and electrolytes in the CSF equilibrate rapidly with the extracellular compartment of the brain tissue (Friede and Hu, 1971). Furthermore, the tips of the occipital horns of the lateral ventricles commonly form small cysts having no communication with the body of the ventricle. There is no record of such a cyst ever enlarging or acting as a space-occupying lesion.

Some features in the fine structure of the cyst implicate the choroid plexus. Basement membrane as well as pinocytosis are characteristic of the choroid plexus epithelium of mammals including man (Dohrmann and Bucy, 1970). The elaborate system of zonulae adherentes found in the cyst wall is rather similar to the junctions between ependyma cells (Brightman and Palay, 1963) as well as choroid plexus epithelium (Doolin and Birge, 1969). The tight junctions (zonulae occludentes) seen between ependymal cells were not observed in the cyst wall, perhaps due to the type of preservation of the tissue. Cilia and microvilli abound in ependyma, whereas the choroid plexus of squirrel monkey, cat, and rabbit was found to be completely free of cilia with the scanning electronmicroscope (Weindl and Joynt, 1972). Nonetheless, sparse cilia were seen in human (Dohrmann and Bucy, 1970), canine (Dohrmann, 1971), rabbit (Tennyson and Pappas, 1961), and cat (Santolaya and Echandia, 1968) choroid plexus with the transmission microscope. Furthermore, scanning electronmicroscopic studies of ventricular walls revealed regional variations in the abundance of cilia or microvilli—for example, in the lower part of the third ventricle (Bruni *et al.*, 1972) or near the circumventricular organs (Weindl and Joynt, 1972). Numerous mitochondria (our case 2) resemble ependyma or plexus, as does the juxtaposition of light and dark cells observed for mouse choroid plexus by Dohrmann (1970), presumably as an expression of differences in cellular hydration. Even the variance in the cyst lining of cases 1 and 2 may be explained by comparison with the developmental changes of normal choroid plexus epithelium or ependyma

(Tennyson and Pappas, 1961, 1962). These cells may already exhibit zonulae adherentes in the fetal rabbit but they show sparse, rudimentary microvilli, fewer cytoplasmic organelles, particularly fewer mitochondria, and fewer pinocytotic vesicles, reminiscent of the cyst lining in case 1.

One difficult point in the interpretation of the cyst lining is the occurrence of a few cells with secretory granules and an amorphous coating of microvilli for some cells of our case 2. These features were thought to be characteristic of respiratory epithelium in a spinal cyst examined by Hirano *et al.* (1971). However, Shuangshoti *et al.* (1965, 1966) report on scattered mucin containing cells in choroid plexus, and Oksche and Vaupel (1969) illustrate structures extremely similar to those in Fig. 5 in the choroid plexus of a child 1½ year old, calling them 'finely granulated cytosomes'. Therefore, one cannot accept these cytoplasmic structures as evidence of extra-cranial origin of the cysts.

On the whole, the available evidence indicates much greater similarities between the epithelial cysts and the intraventricular colloid cysts than between the epithelial cysts and arachnoid cysts. Electron-microscopy of one colloid cyst showed an epithelium with numerous cilia and microvilli, resting on a basement membrane. The cells contained many mitochondria and were apposed to each other by plicated membranes joined by terminal bars (Coxe and Luse, 1964). The fine structure of another colloid cyst (Landolt-Weber, 1973) showed ciliated, microvilli-bearing, cylindrical epithelial cells between secretory cells containing vesicles, some filled with electron-dense granular material rather similar to that found in a few cells in our case 2.

One has to conclude that the available data do not permit an unequivocal determination of the origin of intracerebral epithelial cysts. However, their location and fine structure is most compatible with the assumption that they originate from such segments of the wall of the neural tube as are equivalent to the tela chorioidea; this would account for all known aspects of the organisation of intracerebral cysts (Fig. 6) including the variance in wall structure within a given cyst. This pathogenetic concept, furthermore, permits generalisation, as dislocation of an equivalent segment into the subarachnoid space rather than into the brain substance may account for the development of gliopendymal cysts in the cisterna ambiens or the posterior fossa. Such cysts had been attributed to cystic degeneration of subarachnoid glial heterotopias (Alvord and Marcuse, 1962) or to a remnant of Blake's pouch, an ependyma-lined diverticulum projecting dorsally from the roof of the fourth ventricle (Gilles and Rockett, 1971). Neither of these concepts is applicable to intra-

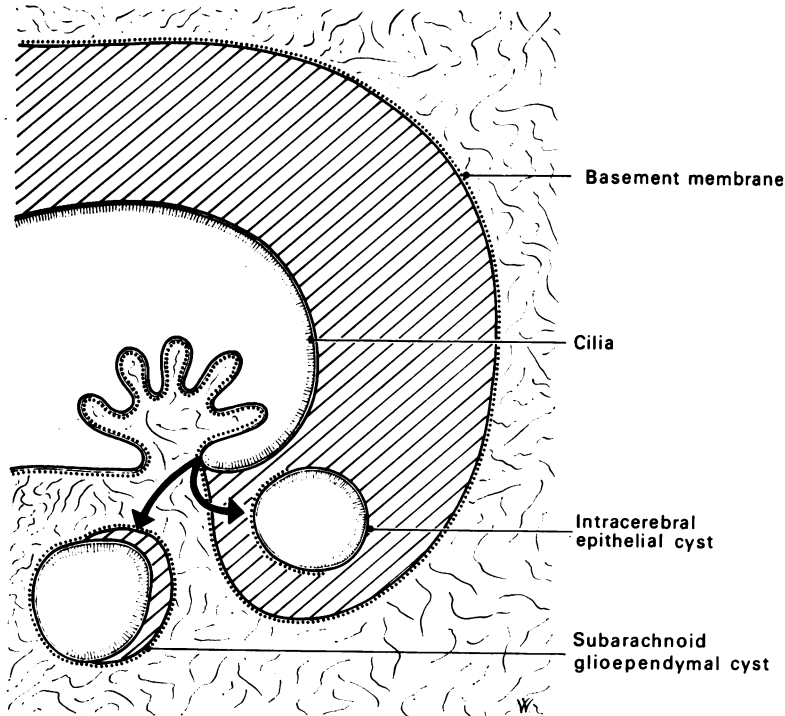


Fig. 6 Presumed pathogenesis of gliependymal cysts: a short segment of the wall of the neural tube becomes displaced either into the cerebral tissue or into the subarachnoid space (bold arrows). A cyst derived from this segment may be lined with a ciliated or a non-ciliated epithelium positioned either on glia, without having basement membrane, or it may sit on connective tissue, having a basement membrane. The variability of these features may even occur within one given cyst.

cerebral epithelial cysts, whereas our theory gives a satisfying explanation of gliependymal cysts whether they are localised in the subarachnoid space or are located intracerebrally.

References

- Aicardi, J., and Bauman, F. (1975). Supratentorial extracerebral cysts in infants and children. *Journal of Neurology, Neurosurgery, and Psychiatry*, **38**, 57–68.
- Alvord, E. C., and Marcuse, P. M. (1962). Intracranial cerebellar meningo-encephalocele (posterior fossa cyst) causing hydrocephalus by compression at the incisura tentorii. *Journal of Neuropathology and Experimental Neurology*, **21**, 50–69.
- Andres, K. H. (1967). Ueber die Feinstruktur der Arachnoidea und Dura mater von Mammalia. *Zeitschrift für Zellforschung*, **79**, 272–295.
- Argyopoulos, G., and Heppner, F. (1970). Angeborene Ependymzysten. *Zentrablatt für Neurochirurgie*, **31**, 39–41.
- Baillie, E. E., and Littler, E. R. (1973). Olfactory bulb cyst. *University of Michigan Medical Center Journal*, **39**, 172–173.
- Bhandari, Y. S. (1972). Non-communicating supratentorial subarachnoid cysts. *Journal of Neurology, Neurosurgery, and Psychiatry*, **35**, 763–770.
- Bouch, D. C., Mitchell, I., and Maloney, A. F. J. (1973). Ependymal lined paraventricular cerebral cysts; a report of three cases. *Journal of Neurology, Neurosurgery, and Psychiatry*, **36**, 611–617.
- Brightman, M. W., and Palay, S. L. (1963). The fine structure of ependyma in the brain of the rat. *Journal of Cell Biology*, **19**, 415–439.
- Brightman, M. W. (1965). The distribution within the brain of ferritin injected into cerebrospinal fluid compartments. *American Journal of Anatomy*, **117**, 193–220.
- Bruni, J. E., Montemurro, D. G., Clattenburg, E. R., and Singh, R. P. (1972). A scanning electron microscopic study of the ependymal surface of the third ventricle of the rabbit, rat, mouse, and human brain. *Anatomical Record*, **174**, 407–420.
- Coxe, W. S., and Luse, S. A. (1964). Colloid cyst of third ventricle. *Journal of Neuropathology and Experimental Neurology*, **23**, 431–445.
- Dohrmann, G. J. (1970). Dark and light epithelial cells in the choroid plexus of mammals. *Journal of Ultrastructure Research*, **32**, 268–273.
- Dohrmann, G. T. (1971). The choroid plexus in experimental hydrocephalus. A light and electron microscopic study in normal, hydrocephalic, and shunted hydrocephalic dogs. *Journal of Neurosurgery*, **34**, 56–69.
- Dohrmann, G. T., and Bucy, P. C. (1970). Human choroid plexus: A light and electron microscopic study. *Journal of Neurosurgery*, **33**, 506–516.
- Doolin, P. F., and Birge, W. J. (1969). Ultrastructural organization and histochemical profile of adult fowl

- choroid plexus epithelium. *Anatomical Record*, **165**, 515–530.
- Friede, R. L. (1975). *Developmental Neuropathology*. Springer: Vienna.
- Friede, R. L., and Hu, K. H. (1971). A new approach for determining the volume of cerebral extracellular fluid and demonstration of its communication with CSF. *Journal of Physiology*, **218**, 477–493.
- Ghatak, N. R., Hirano, A., Kasoff, S. S., and Zimmerman, H. M. (1974). Fine structure of an intracerebral epithelial cyst. *Journal of Neurosurgery*, **41**, 75–82.
- Gilles, F. H., and Rockett, F. X. (1971). Infantile hydrocephalus: Retrocerebellar 'arachnoidal' cyst. *Journal of Pediatrics*, **79**, 436–443.
- Harrison, M. J. G. (1971). Cerebral arachnoid cysts in children. *Journal of Neurology, Neurosurgery, and Psychiatry*, **34**, 316–323.
- Hirano, A., Ghatak, N. R., Wisoff, H. S., and Zimmerman, H. M. (1971). An epithelial cyst of the spinal cord. An electron microscopic study. *Acta Neuropathologica (Berl.)*, **18**, 214–223.
- Jakubiak, P., Dunsmore, R. H., and Beckett, R. S. (1968). Supratentorial brain cysts. *Journal of Neurosurgery*, **28**, 129–136.
- Landolt-Weber, U. M. (1973). Ultrastruktur einer Kolloidzyste des dritten Ventrikels. *Acta Neuropathologica*, **26**, 59–70.
- List, C. F., and Williams, J. R. (1961). Subdural epithelial cyst in the interhemispheric fissure. *Journal of Neurosurgery*, **18**, 690–693.
- Loeser, J. D., and Alvord, E. C. (1968). Clinicopathological correlations in agenesis of the corpus callosum. *Neurology (Minneapolis)*, **18**, 745–756.
- Lopes, C. A. S., and Mair, W. G. P. (1974). Ultrastructure of the arachnoid membrane in man. *Acta Neuropathologica (Berl.)*, **28**, 167–173.
- MacGregor, B. J. L., Gawler, J., and South, J. R. (1976). Intracranial epithelial cysts. *Journal of Neurosurgery*, **44**, 109–115.
- Nabeshima, S., Reese, T. S., Landis, D. M. D., and Brightman, M. W. (1975). Junctions in the meninges and marginal glia. *Journal of Comparative Neurology*, **164**, 127–170.
- Oksche, A., and Vaupel-Von Harnack, M. (1969). Elektronenmikroskopische Studien über Altersveränderungen (Filamente) der Plexus chorioidei des Menschen (Biopsiematerial). *Zeitschrift für Zellforschung*, **93**, 1–29.
- Patrick, B. S. (1971). Ependymal cyst of the Sylvian fissure. *Journal of Neurosurgery*, **35**, 751–754.
- Rawlinson, D. G., Herman, M. M., and Rubinstein, L. (1973). The fine structure of myxopapillary ependymoma of the filum terminale. *Acta Neuropathologica (Berl.)*, **25**, 1–13.
- Santolaya, R. C., and Rodriguez Echandia, E. L. (1968). The surface of the choroid plexus cell under normal and experimental conditions. *Zeitschrift für Zellforschung*, **92**, 43–51.
- Shabo, A. L., and Maxwell, D. S. (1968). The morphology of the arachnoid villi: a light and electron microscopic study in the monkey. *Journal of Neurosurgery*, **29**, 451–463.
- Shuangshoti, S., and Netsky, M. G. (1966). Histogenesis of choroid plexus in man. *American Journal of Anatomy*, **118**, 283–316.
- Shuangshoti, S., Roberts, M. P., and Netsky, M. G. (1965). Neuroepithelial (colloid) cysts. *Archives of Pathology*, **80**, 214–224.
- Šimek, J., and Gutmann, E. (1949). Kongenitální cysta mozková. *Časopis Lékařů Českých*, **88**, 923–926.
- Starkman, S. P., Brown, T. C., and Linell, E. A. (1958). Cerebral arachnoid cysts. *Journal of Neuropathology and Experimental Neurology*, **17**, 484–500.
- Tandon, P. N., Roy, S., and Elvidge, A. (1972). Subarachnoid ependymal cyst. Report of two cases. *Journal of Neurosurgery*, **37**, 741–745.
- Tennyson, V. M. (1960). An electronmicroscopic study of newborn choroid plexus from normal and hydrocephalic rabbits. *Anatomical Record*, **136**, 290.
- Tennyson, V. M., and Pappas, G. D. (1961). Electronmicroscopic studies of the developing telencephalic choroid plexus in normal and hydrocephalic rabbits. In *Disorders of the Developing Nervous System*. Springfield: Thomas.
- Tennyson, V. M., and Pappas, G. D. (1962). An electron microscope study of ependymal cells of the fetal, early postnatal and adult rabbit. *Zeitschrift für Zellforschung*, **56**, 596–618.
- Waggner, J. D., and Beggs, J. (1967). The membranous coverings of neural tissues: an electron microscopy study. *Journal of Neuropathology and Experimental Neurology*, **26**, 412–426.
- Weindl, A., and Joynt, R. J. (1972). Ultrastructure of the ventricular walls. *Archives of Neurology (Chic.)*, **26**, 420–427.
- Zehnder, M. (1938). Subarachnoidalzysten des Gehirns. *Zentrablatt für Neurochirurgie*, **3**, 100–112.