

Short report

Presenile dementia presenting as aphasia

ADAM F. WECHSLER

From the Neurology and Research Services, VA Wadsworth Hospital Center, and Department of Neurology, UCLA School of Medicine, Los Angeles, California, USA

SUMMARY A focal aphasic syndrome was the first and outstanding manifestation of a degenerative, presenile dementia in a 67 year old man. Computerised axial tomography showed a strikingly dilated left Sylvian fissure—particularly in its posterior aspect—in the presence of moderate diffuse cortical atrophy. The radiographic findings correlated well with the clinical data. This is the first report of an aphasic disturbance of language as the initial symptom in presenile dementia.

Although disturbances of language are not uncommon in the presenile degenerative dementias, usually they do not occur until relatively late (Sjögren *et al.*, 1952; Haase, 1971). Moreover, the types of language disturbances most frequently described are different from those usually encountered in aphasics (Critchley, 1964; Benson, 1973). This report details the case of a 67 year old, right handed man, with clinical and radiographic evidence of presenile dementia, in whom progressive deterioration of behaviour and intellectual function was heralded by an aphasic disturbance of language.

Case report

A 67 year old, right handed man was seen in neurological consultation with a chief complaint of trouble with speech of approximately two years duration. His wife stated that his illness began with the use of incorrect words in conversation, repetitiousness, and a tendency to reverse word order. At first this occurred only occasionally but it became progressively more frequent, resulting in instances when some of his sentences made no sense at all. In addition, he began to have trouble understanding what was said to him, although usually he would answer 'sure, sure', or 'yes, yes' to most questions. His handwriting deteriorated progressively, and he became more forgetful. Radiographs of chest and skull, an electroencephalogram, and a brain scan with a cerebral blood flow study were normal. The patient refused further diagnostic studies.

About a year after the onset of his symptoms, personality changes developed. At first he seemed merely to 'shy away from people' but subsequently he became irritable and suspicious. In addition his behaviour became stereotyped and inappropriate. For example, he would catch flies, proceed to pull off their wings, and then set them afire with matches.

There was no history of headaches, visual disturbances, seizures, focal weakness, paraesthesias, ataxia, incontinence, syncope, dizziness, or vertigo.

The patient's health had always been excellent and there was no history of neurological or psychiatric illness in the family. He was a high school graduate and had been very successful in business. He was always meticulous about dress and personal hygiene.

General physical examination was normal. On neurological examination, there were no focal motor or somatosensory deficits. Deep tendon reflexes were brisk and symmetrical, and the plantar responses were flexor. He had positive glabellar and snout reflexes, but no grasp or palmomental reflexes were elicited. Cranial nerves including visual fields were intact.

MENTAL STATUS AND LANGUAGE TESTING

The patient was alert and cooperative. He was very neatly dressed and was quite garrulous and good-natured. At times he seemed mildly euphoric and childlike in his behaviour, and he seemed uncertain why he was visiting a doctor. He said he had a slight memory problem but told the examiner 'it was nothing to worry about'. There was no inappropriate laughing or crying, and no evidence of depression. He stated vaguely that he had some trouble expressing himself at times but could not define the problem further. He did not appear to be

Address for reprint requests: Adam F. Wechsler, MD, Neurology Service 691/127, VA Wadsworth Hospital Center, Wilshire & Sawtelle Blvd., Los Angeles, California 90073, USA.

Accepted 1 November 1976

frustrated by his occasional inability to make himself understood.

He was oriented to time, place, and person. He knew the name of the President of the United States, but not the Vice-President, or the Governor of California. He was unable to say his address or telephone number but was able to write both correctly. He made several errors on tests of simple calculations when these were given to him verbally, but when the same problems were put on paper he got them all right. He was able to spell three, four, and five letter words accurately but made frequent errors with six and seven letter words. His performance was good on the block design subtest of the Wechsler Adult Intelligence Scale (WAIS), and he copied simple designs accurately. He was able to repeat seven digits forwards and five backwards. He remembered only one of five items after three minutes and short story recall was poor. He was unable to improve his performance by trying to give the answers in writing.

His conversational speech was fluent but there was occasional hesitation on attempting to initiate speech. There was occasional perseveration, frequent paraphasia—both phonemic (for example, 'home' for comb) and semantic (for example, 'diaper' for safety pin), and rare neologisms and jargon. For instance, on one occasion when asked how he was feeling, the patient responded, 'Well I found a very pain in the nostial area and it took a small little vick'. Echolalia and verbal stereotypy were also noted. An example of the latter was the patient's frequent use of the phrase 'way down too' in response to questions about his illness. He had a moderate comprehension deficit. He was able to follow most one-stage commands but more complex material confused him. Similarly, simple sentences were read quite well but more complex sentences, although read fairly rapidly, contained frequent errors of omission, substitutions, and mispronunciation; comprehension of what he had just read was poor. He was able to write spontaneously and to dictation, but his writing contained occasional perseveration, omissions, substitutions (usually inappropriate words), and other grammatical errors. He named many common objects correctly but made occasional errors. For example, he called a thermometer a 'temperature tube', a straw a 'saw' and a thimble 'a symbol'. When asked to identify a picture of Winston Churchill, he answered 'England too', and a picture of the Statue of Liberty was referred to as 'New York too'. He was able to select the correct name of an object or picture when it was provided by the examiner, and he had no difficulty demonstrating the use of objects he could not name. He made occasional errors naming or pointing to body

parts, and there was some right-left disorientation. Repetition of sentences was moderately impaired with a tendency to add or substitute words.

There was mild difficulty executing buccofacial and limb commands which did not significantly improve after demonstration by the examiner. He had no difficulty dressing.

Computerised axial tomography (Fig. 1a and b) revealed diffuse enlargement of the cortical sulci. The left Sylvian fissure, however, was remarkably dilated, particularly in its posterior aspect, indicating severe focal atrophy in that area. There was mild to moderate enlargement of the lateral ventricles. Contrast medium was infused and there was no evidence of any mass.

Discussion

Although the exact pathology is not known in this case, the clinical and radiographic findings are most consistent with either Alzheimer's disease or Pick's disease. What is so unusual, however, is the way in which the patient's illness first presented. To my knowledge, aphasia has not been previously reported as the initial symptom in presenile dementia. Not only do disturbances of language tend to occur relatively late in presenile dementia, but the types of language disturbances most frequently described are empty, circumlocutory speech, and difficulty in word-finding (Critchley, 1964; Benson, 1973). Unlike the anomia of aphasics, paraphasic errors and neologisms are rare (Benson, 1973). In the present case, both phonemic and semantic paraphasic errors occurred in conversational speech and on confrontation naming of objects. In addition, there were occasional neologisms, echolalia, verbal stereotypy, perseveration, and jargon. Together with the patient's fluent speech, these disturbances are most consistent with those observed in patients with aphasia secondary to temporal lobe involvement.

The changes seen in the degenerative dementias are generally thought of in terms of diffuse brain damage, and it may be that the presence of significant aphasia in this patient is simply a reflection of the fact that the degenerative process was sufficiently widespread to involve the main temporal language area of the brain. On the other hand it is important to recognise that, within the context of global impairment of intellectual function, cognitive abilities may be differentially affected depending upon which area of the brain is most severely involved.

The findings on the EMI scan were consistent with a diffuse degenerative process, namely, moderate enlargement of the lateral and third ventricles, a normal fourth ventricle, and increased size of the cortical sulci. Outstanding, however, was the

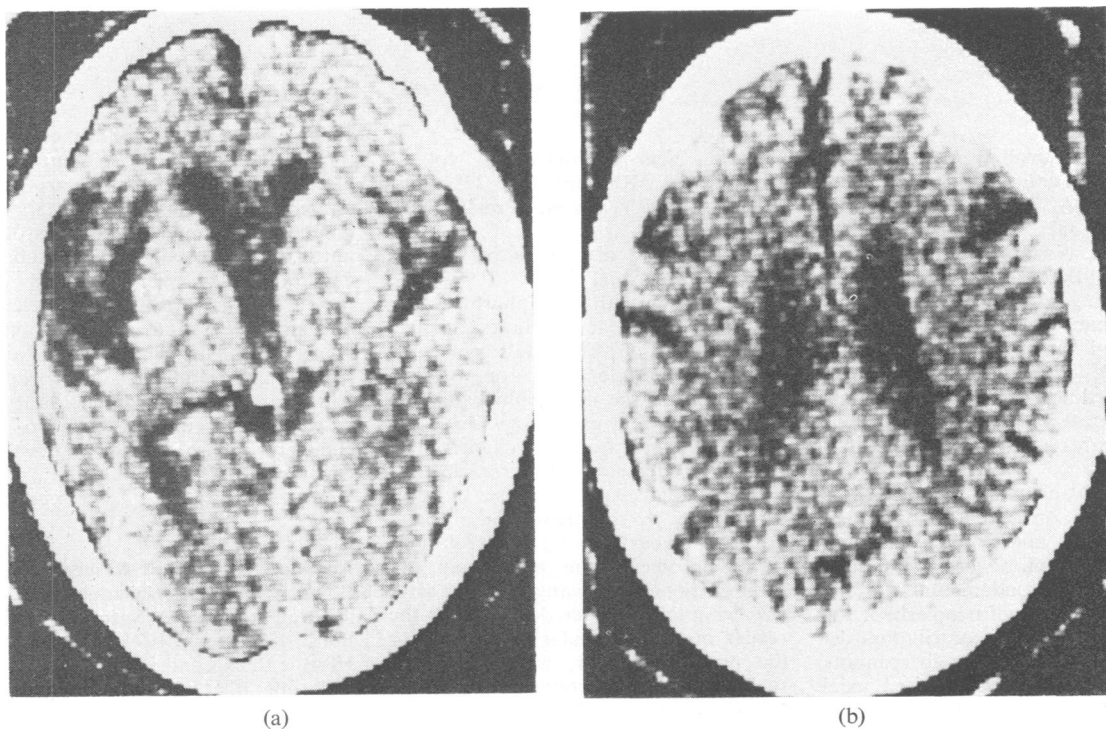


Fig. 1 EMI scan demonstrating striking dilatation of the left Sylvian fissure (a) in the presence of diffuse sulcal enlargement (b). The lateral ventricles are moderately enlarged.

presence of remarkable dilatation of the left Sylvian fissure—particularly in its posterior aspect—greatly out of proportion to the enlargement of the other cortical sulci. This radiological demonstration correlated well with the clinical data; it is not inconceivable that the greater extent of cortical atrophy in the region of the temporal language area may have accounted for the patient's aphasic presentation, and for the subsequent differential loss of higher cortical functions.

Although both the clinical picture of early language involvement associated with relative sparing of constructional ability, as well as the radiographic picture of such pronounced focal atrophy in the context of diffuse cortical involvement, are more suggestive of Pick's disease than Alzheimer's disease (Robertson *et al.*, 1958; Myre and Sussman, 1962; Strub and Geschwind, 1974), it is impossible to make an unequivocal diagnosis at this time. The main purpose of this report, however, is not to attach a precise diagnostic label to the patient's disease, but rather to call attention to the possibility that aphasia may be both the presenting and most prominent symptom of degenerative dementia, and that the EMI scan in this case may be providing an *in vivo* anatomi-

cal bridge between neuropathology and the neuropsychological assessment of behavioural deficits.

References

- Benson, D. (1973). Disorders of verbal expression. In *Psychiatric Aspects of Neurologic Disease*, pp. 121–136. Edited by D. Benson and D. Blumer. Grune and Stratton: New York.
- Critchley, M. (1964). The neurology of psychotic speech. *British Journal of Psychiatry*, **110**, 353–364.
- Haase, G. (1971). Diseases presenting as dementia. In *Dementia*, pp. 163–208. Edited by C. Wells. F. A. Davis Co: Philadelphia.
- Myre, S., and Sussman, I. (1962). Alzheimer's disease: its natural history and differential diagnosis. *Journal of Nervous and Mental Disease*, **135**, 489–499.
- Robertson, E., LeRoux, A., and Brown, J. (1958). The clinical differentiation of Pick's disease. *Journal of Mental Science*, **104**, 1000–1024.
- Sjögren, T., Sjögren, H., and Lindgren, A. (1952). Morbus Alzheimer and morbus Pick: genetic, clinical and pathoanatomic study. *Acta Psychiatrica et Neurologica Scandinavica*, Supplement 82.
- Strub, R., and Geschwind, N. (1974). Gerstmann syndrome without aphasia. *Cortex*, **10**, 378–387.