

THE ELECTROCARDIOGRAM IN AORTIC STENOSIS

BY

ZAHIRA H. ABDIN*

From the Department of Medicine, Postgraduate Medical School, London

Received July 19, 1957

Many papers have recently appeared on aortic stenosis (Boas, 1935; Friedberg and Sohval, 1939; Kiloh, 1950; Lewes, 1951; Campbell and Kauntze, 1953; Mitchell *et al.*, 1954). The electrocardiographic findings have been described as those of left ventricular hypertrophy, often with a vertical heart position in pure stenosis (Kiloh, 1950). Assessment of the severity of aortic stenosis often presents difficulty. This study reports the electrocardiographic changes in aortic stenosis, and a comparison with those in left ventricular hypertrophy from other causes.

METHODS AND MATERIAL

Electrocardiograms were recorded either by an Elmqvist photographic machine or a Sanborn Visocardiette direct-writing instrument. Standard and unipolar limb leads, and unipolar chest leads were used (Goldberger, 1947).

Electrocardiograms from 44 cases of aortic stenosis were studied at Hammersmith Hospital. Twenty-five patients were living, of whom 8 had had an aortic valvotomy. In addition the cardiograms from 9 living patients published by Kiloh (1950), and Campbell and Kauntze (1953) were also examined. The remaining 19 records were taken from case notes of patients who had come to necropsy.

The ages of the 53 patients whose cardiograms were studied varied from 6 to 60 years. Thirty-seven were between 20 and 50. Fifteen cases were female and 38 male. Forty-four patients presented with a well established lesion with symptoms. Chest pain occurred in 40 per cent, syncopal attacks in 8 per cent, exertional dyspnoea of variable severity in 70 per cent, and nocturnal dyspnoea or congestive heart failure in 40 per cent. Measurements of the systolic upstroke time of the arterial pulse tracing were made in 9 cases, and in 4 of these the severity of the aortic stenosis was further assessed by the examination of the relationship between the systolic upstroke time and changes in pulse pressure.

Four cases with aortic stenosis also had mitral stenosis, and one of these had tricuspid stenosis also. The electrocardiograms of 19 living patients with coarctation of the aorta whose ages varied from 19 to 50 years were studied as controls for the living cases, while those of 15 autopsy subjects with hypertensive heart disease formed the control for the post-mortem series. None of the latter had any evidence of ischæmic heart disease at necropsy.

The criteria for voltage of R and S waves for left ventricular hypertrophy used were those set by Sokolow *et al.* (1949): R voltage in V₅, 25 mm. or more; or R voltage in V₅+S voltage in V₁, 35 mm. or more; or R voltage in V_L, 13.0 mm. or more when the heart is horizontal; or R voltage in V_F, 20 mm. or more when the heart is vertical.

RESULTS

Aortic Stenosis (living series). Five cases showed extremely high voltage; these all had severe lesions with well established symptoms. ST-T wave changes were also studied. The two cases

* Present address: Children's Hospital, Kasr-el-Aini University Hospital, Cairo.

with bundle-branch block were not included. T wave inversion in left ventricular leads was present in 31 out of 32 cases. It was deep (over 5 mm.) in 16, moderate (3–5 mm.) in 14, and slight (less than 3 mm.) in one case (Table I). The correlation between symptoms and severity

TABLE I
INCIDENCE AND DEGREE OF T WAVE INVERSION IN AORTIC STENOSIS AND IN CONTROLS WITH
COMPARABLE DEGREES OF VENTRICULAR HYPERTROPHY

T inversion	Aortic stenosis, 19 autopsy cases (excluding 4 with bundle- branch block), 15 cases	Aortic stenosis, 34 living cases (excluding 2 with bundle- branch block), 32 cases	Hypertensive without ischæmia, 15 cases (excluding 1 with bundle- branch block), 14 cases	Aortic coarcta- tion, 19 cases (excluding 3 normal EC.) 16 cases	Hypertensive and ischæmic disease, 4 cases
Deep	10	16	1	1	3
Moderate	4	14	2	3	
Slight	0	1	4	4	
Absent	1	1	7	8	1
Total incidence	14	31	7	8	3

seemed to be close. Thus a boy of 17 years had normal exercise tolerance and no chest pain, his only symptom being occasional syncope; the systolic upstroke time of the femoral arterial pulse was 0.15 sec. (indicative of mild to moderate stenosis) and there was no T wave inversion (Fig. 1). Conversely a woman, aged 22 years, had had frequent chest pain since the age of 13, and had progressively increasing exertional dyspnoea; the systolic upstroke time was 0.24 sec. (indicating severe stenosis) and the electrocardiogram showed deeply inverted T waves (8 mm.) (Fig. 2). Table II illustrates the direct relationship between T wave inversion and systolic upstroke time in the 9 cases in which the latter was measured. T wave changes may precede the onset of symptoms.

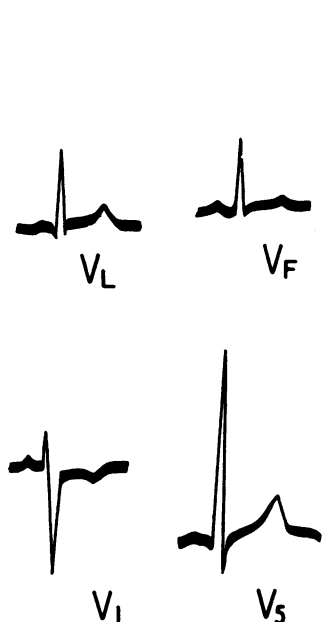


FIG. 1.—Facsimile cardiogram from a patient with mild aortic stenosis without symptoms. RV5=31 mm. T wave normal.

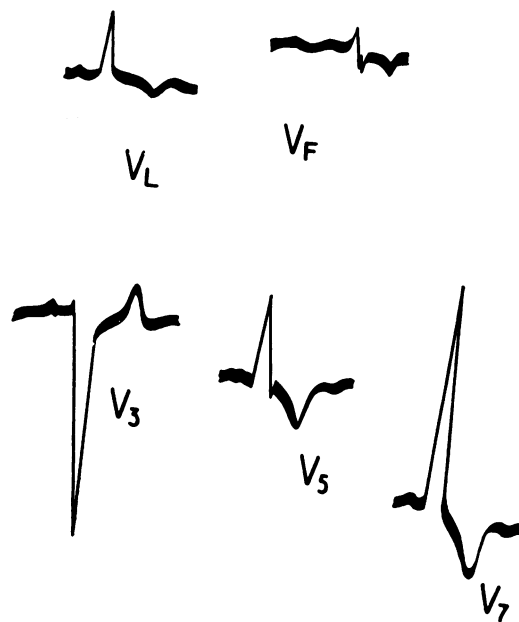


FIG. 2.—Cardiogram from a patient with severe aortic stenosis with frequent angina. RV5=14 mm.; RV7=32 mm.; TV5 is inverted (6 mm.); TV7 is inverted (8 mm.).

TABLE II
RELATION OF T WAVE INVERSION TO TIME TO PEAK OF FEMORAL ARTERIAL PULSE WAVE

Case No.	Time to peak (Tp) sec.	T wave inversion T (millimetre)
1	0.15	0
2	0.16	0
3	0.18	4
4	0.22	6
5	0.22	6
6	0.22	6
7	0.24	8
8	0.24	8
9	0.25	10

Tp=Time to peak in seconds measured on the arterial femoral pulse tracing.
T=Inversion of the T wave in left ventricular leads in millimetres.

Moderate to deep T wave inversion in V3 or V4 was present in 6 cases, and a biphasic T wave in V3 was present in 7 others. Although the patients with extreme voltage changes usually showed the deepest inversion of the T wave, in 2 instances there was T wave inversion (slight to moderate inversion in V5 or V7) with no increase in voltage of the QRS complexes. There was only one example of voltage being increased without associated T wave changes.

Depression of the S-T segment in left ventricular leads of 1-2 mm. occurred in 24 cases. In right ventricular leads S-T elevation (1-3 mm.) occurred in 22 electrocardiograms, and the T wave was upright in 24. One patient showed right bundle-branch block and one left bundle-branch block, while the P-R interval was over 0.2 sec. in 4 instances. Atrial fibrillation was not seen in the cases of isolated aortic stenosis, but was present in the three subjects with combined aortic and mitral valve stenosis. The Q-T ratio was normal.

The heart position was vertical in 17 of the 34 patients.

COARCTATION OF THE AORTA

Three patients with coarctation of the aorta had normal tracings. The other 16 had voltage changes of left ventricular hypertrophy, of moderate degree in 11, and extreme in 5. T wave inversion was present in only 8 of the 16 cases with voltage changes. The inversion was minimal in 4, slight to moderate (3 mm.) in 3, and deep (6 mm.) in only one (Fig. 3 and Table I). No inversion was seen in V3. S-T depression of 0.5-1.5 mm. was present in four cardiograms. In the right ventricular leads the T wave was upright, and there was S-T segment elevation of 0.5-1.5 mm. in 13 out of the 16 cases.

The mean values for R wave voltage and T wave inversion in the left ventricular leads (V5 or V7), and the mean ratio R voltage/T inversion in the cases with T wave inversion in the same leads, are compared for cases with aortic stenosis and cases with coarctation in Table III. It is clear that although the voltage of the R wave in the two groups is comparable, the T wave inversion in the patients with aortic stenosis is much greater than in those with coarctation. This is reflected in the much larger ratio R/T in the coarctation series than in those with aortic stenosis.

In one patient with coarctation the P-R interval was 0.24 sec., while none had bundle-branch block or arrhythmias. The Q-T ratio was normal. A vertical heart position was present in 10 out of 16 patients.

THE RELATIONSHIP BETWEEN CARDIOGRAPHIC CHANGES AND POST-MORTEM FINDINGS IN AORTIC STENOSIS AND IN HYPERTENSION

Left ventricular thickness and cardiographic voltage changes. At autopsy all the patients with aortic stenosis had left ventricular hypertrophy, the thickness of the left ventricle varying from

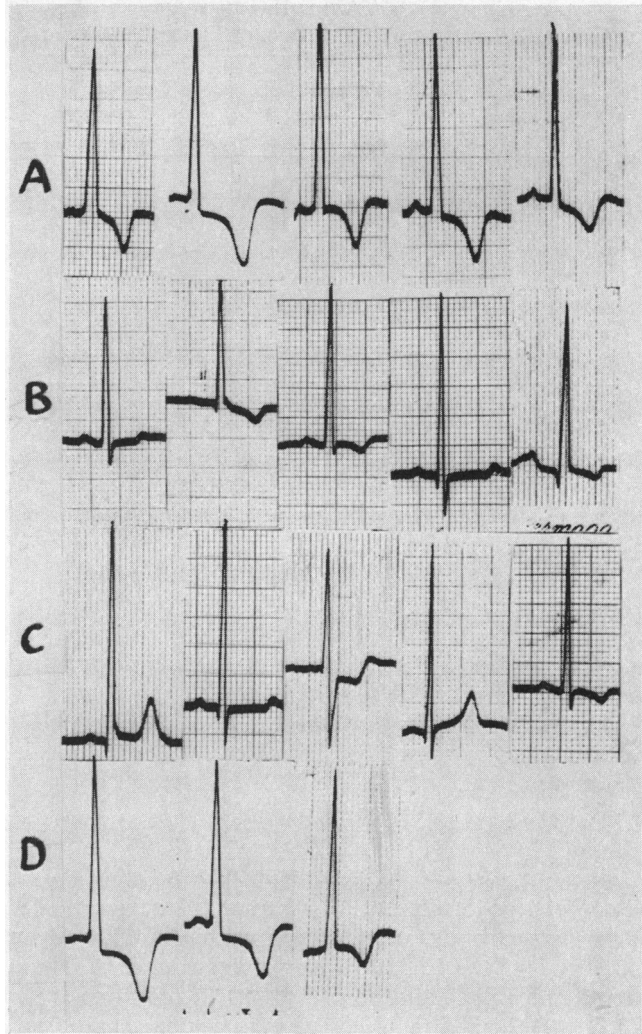


FIG. 3.—Multiple examples of left ventricular leads (V5 or V7) from aortic stenosis (A), coarctation (B), hypertension without coronary artery disease (C), and hypertension with ischaemic heart disease (D).

16 to 30 mm. All those with hypertension had left ventricular hypertrophy, the left ventricular thickness ranging from 18 to 25 mm. Most of the ventricles in hypertension had a thickness of 22–25 mm., while in most of the aortic stenosis cases the thickness was 20–22 mm. The average thickness in the two groups was 21 mm. for the aortic stenosis cases and 22 mm. for those with hypertension. Cardiographic voltage changes of left ventricular hypertrophy were present in all but one case of aortic stenosis, and all but one of the hypertensive subjects.

T wave inversion, left ventricular thickness, and aortic valve size. For comparable degrees of left ventricular hypertrophy, T wave inversion in left ventricular leads was much more frequent and more remarkable in the patients with aortic stenosis (Tables I and III). The frequency of deep T wave inversion (5 to 10 mm.) in the aortic stenosis series (10 out of 15 cases), and the scarcity of such deep T waves in the hypertensive cases (1 out of 14 cases), is particularly striking (Fig. 3C and Table I).

TABLE III

COMPARISON OF MEAN VALUES FOR VOLTAGE, LEFT VENTRICULAR THICKNESS, AND T WAVE INVERSION IN AORTIC STENOSIS AND CONTROLS

	Aortic stenosis (P.M.)	Aortic stenosis (living)	Hypertension	Coarctation
R*	19.5	19.8	20.0	22.4
V	21.0	—	22.2	—
T	4.8	4.1	1.2	2.4
R/T†	3.4	4.7	12.2	14.7

R=Voltage of R wave in lead V5 (mm.).

V=Thickness of left ventricle (mm.).

T=Inversion of T wave in lead V5 (mm.).

R/T=Ratio of mean voltage of R wave in lead V5 (mm.) to mean T inversion in lead V5 (mm.) for cases with T wave inversion in lead V5.

* Includes cases with and without T wave inversion.

† Includes only cases with T inversion.

Four other hypertensive cases were excluded because there was histological evidence of ischaemic heart disease. It is of interest that three of these had deeply inverted T waves of the type seen in aortic stenosis (Fig. 3D).

T wave inversion in the hypertensive patients occurred only in those who showed the maximum degrees of left ventricular hypertrophy. In the aortic stenosis patients the deeply inverted T waves again were usually but not always associated with the greater degrees of left ventricular hypertrophy. There was, however, a close relationship in the aortic stenosis patients between the degree of T wave inversion and valve size when this was measured at necropsy.

Three cases had only slight to moderate T wave inversion with a severe degree of aortic stenosis: two had cardiographic evidence suggestive of small myocardial infarctions with post-mortem evidence of macroscopic infarctions, and the third had bundle-branch block of indeterminate type. The incidence of inverted T waves in V5 and V6 in all groups is shown in Table I, cases with bundle-branch block being excluded. Of the 19 patients with aortic stenosis, one had right and two left bundle-branch block and one had a bundle-branch block of undetermined type. In all the lesions were severe. By contrast, only one of the 15 patients with hypertension had left bundle-branch block. In the presence of bundle-branch block there was no evidence of calcification of the bundle of His.

Of the 12 patients with aortic stenosis in sinus rhythm, one had a P-R interval longer than 0.2 sec. None of the hypertensive cases had a prolonged P-R interval. Atrial fibrillation was present in 7 instances of aortic stenosis: only one of these had mitral stenosis also. Atrial fibrillation occurred in two patients with hypertension. Ventricular ectopic beats were frequent in aortic stenosis, but not seen in the hypertensive cases. The Q-T ratio was normal in all groups.

The ratios between left ventricular and right ventricular thickness were examined in relation to vertical heart position and clockwise rotation. Seven patients with aortic stenosis and 6 of those with hypertension had a vertical or semivertical heart position, but only 4 of the former and 3 of the latter had right ventricular hypertrophy.

Extreme degrees of clockwise rotation of the heart with $S > R$ or $S = R$ in V5 (Pagnoni and Goodwin, 1952) were present in 6 cases with aortic stenosis and 3 with hypertension (Fig. 4). All had pathological evidence of right ventricular hypertrophy. However, right ventricular hypertrophy without clockwise rotation was present in 6 with aortic stenosis and in 4 with hypertension.

It is of interest to note that in 70 normal adult patients of all ages examined the electrocardiogram showed a vertical or semi-vertical electrical position of the heart in over one-third, while none had gross clockwise rotation with $S > R$ in V5.

The incidence of deeply inverted T waves in other cases of left ventricular hypertrophy was also

studied. Thirty patients were examined; they were mainly adults; 15 had aortic incompetence, 8 had patent ductus arteriosus, and 7 had ventricular septal defects. Only 2 cases among all the groups had a deeply inverted T wave 6 mm. in depth in V5 or V6. One was a child of 9 years with a septal defect, and the other was aged 17, and had free aortic incompetence and extreme enlargement of the left ventricle.




FIG. 4.—Facsimile cardiogram from a case of aortic stenosis, showing biventricular hypertrophy. There is clockwise rotation (R/S ratio=1 in V5) and a horizontal heart position with high voltage of R in V7 (33 mm.) and T wave inversion. The left ventricular thickness was 25 mm., while the right ventricular thickness was 8.0 mm. at necropsy.

the T wave is usually associated with ischæmic myocardial changes rather than with increase in muscle thickness. The frequency of these changes in aortic stenosis suggests the presence of ischæmic changes in the myocardium, either as a result of associated coronary artery disease or of impaired coronary blood flow resulting from the valvular obstruction. In favour of the latter hypothesis is the fact that deep T wave inversion occurs in children and adolescents with aortic stenosis, in whom coronary disease is unlikely to be present. Furthermore, cardiographic appearances suggestive of infarction are not infrequent in the second and third decade (Fig. 5 and 6). Similar changes have been reported by Friedberg and Sohval (1939). Deep inversion of the T wave in patients over 20 years may occur in the transitional zone as well as in left ventricular leads, suggesting septal ischæmia (Fig. 7). A positive effort test was present in three patients with aortic stenosis studied in this series. The relative frequency in aortic stenosis, compared with other causes of left ventricular hypertrophy as gauged from the present work as well as from previous records (Mitchell *et al.*, 1954; Lewes, 1951), of bundle-branch block, of prolongation of the P-R interval, and of atrial fibrillation also lend support to the suggestion that ischæmia is common in this disorder. It is of interest that the patients with left bundle-branch block had severe stenosis, but no gross evidence of calcification in the conducting tissue was found at necropsy. Friedberg and Sohval (1939) have reported that transient bundle-branch block may occur in aortic stenosis.

Supporting clinical evidence of ischæmia is derived from the frequency of anginal syndromes in aortic stenosis. Perhaps the strongest evidence that T wave inversion is not directly related to the degree of left ventricular hypertrophy is the rarity of deep T wave changes in coarctation of

DISCUSSION AND CONCLUSIONS

The most striking cardiographic abnormality in patients with aortic stenosis is inversion of the T wave in the left ventricular leads (Fig. 3, Tables I and III). The inversion is often deep and is almost invariably present when the voltage in these leads is high. On occasion, T wave inversion may occur without increased voltage. The T wave changes are in striking contrast to the findings in coarctation of the aorta, in hypertension without associated ischæmic heart disease, and in other conditions causing left ventricular hypertrophy in which T wave inversion is often not striking (Fig. 3). However, when hypertension is associated with ischæmic heart disease T wave inversion similar to that in aortic stenosis occurs. A deeply inverted asymmetrical T wave in left ventricular leads in the absence of coronary artery disease is highly suggestive of aortic stenosis. It is probable that the voltage changes commonly seen in conditions causing left ventricular hypertrophy are the result of the increased mass of the left ventricular muscle. However, deep inversion of

the aorta or hypertension even when these had left ventricular hypertrophy of a degree that, if present in aortic stenosis, was almost always accompanied by deep inversion of the T wave (Fig. 3). Furthermore T wave inversion in aortic stenosis may precede voltage changes (Campbell and Kauntze, 1953). The findings at necropsy also tend to support the primary ischæmic theory. Thirteen patients with aortic stenosis were found to have myocardial infarction or scattered areas of ischæmic fibrosis with patent coronary arteries and minimal or no atheroma. Of these, 3 had

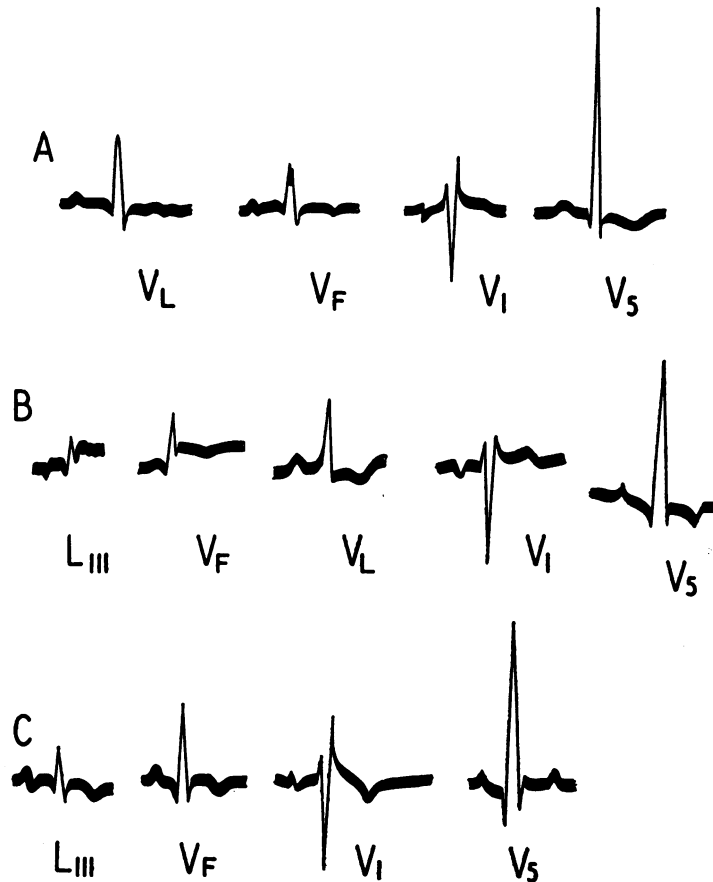


FIG. 5.—Facsimile cardiogram from a patient with aortic stenosis, aged 19 years. These three tracings were taken over a three-month period. In (B) small Q waves and S-T elevation are seen in leads III and VF. T in VI is upright while T in V5 is inverted (3.0 mm.). In (C) T in VI is inverted while T in V5 is upright. Appearances suggest the development of a posterior infarction in (B).

recent infarctions, 4 old infarctions, and 9 numerous microscopic areas of fibrosis presumably ischæmic in origin. Wigle (1957) has charted the areas of fibrosis in four cases and found them to be widespread with some predilection for the posterolateral region, and this site corresponds to the site of T wave inversion in the cardiogram. The relative infrequency of large Q waves in the electrocardiogram may be related to the small size of the areas of fibrosis and to the relative infrequency of large areas of infarction. The mechanism of the myocardial ischæmia is still uncertain. Green (1936) demonstrated a significant reduction in the minute volume flow through the coronary arteries and found that the flow could not easily be increased. Encroachment of the coronary orifices by calcification and fibrosis, the slow rise of the arterial pulse, acceleration

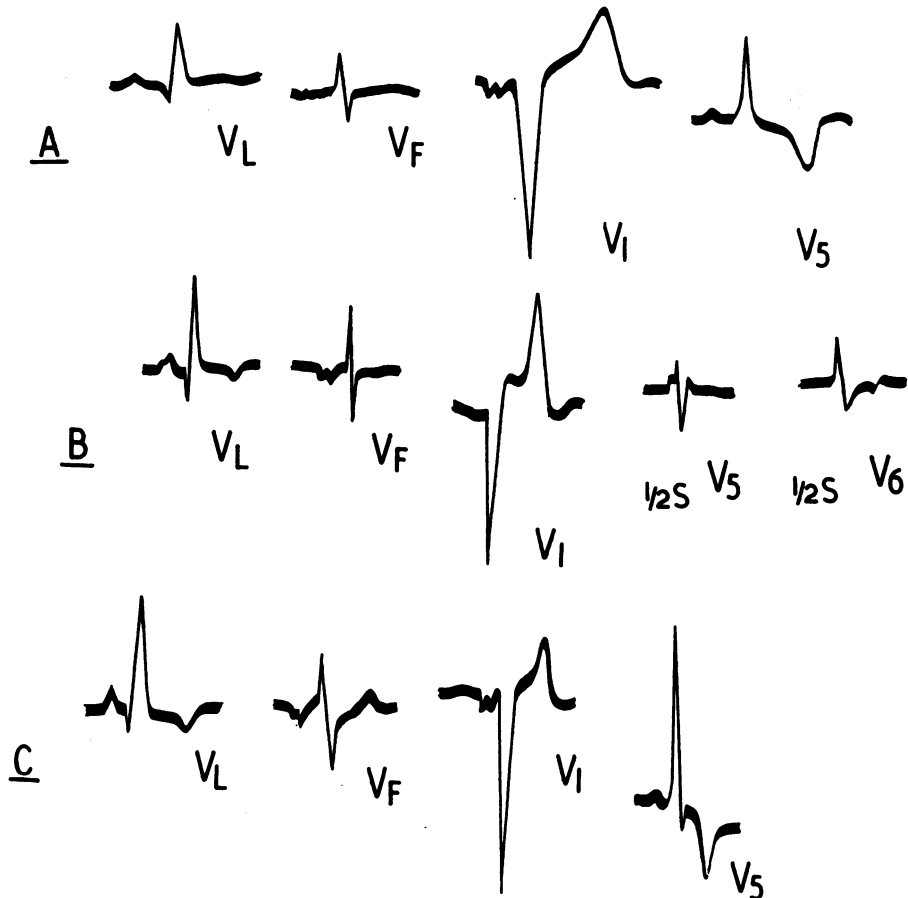


FIG. 6.—Facsimile cardiogram from a patient, aged 34 years, with aortic stenosis. These three tracings were taken over a three-month period. The appearance in (B) (Q waves 5 mm. in VL with inversion of the T waves and R/S ratio in V5 less than unity) suggests the development of an anterolateral infarction and/or associated right ventricular hypertrophy [$\frac{1}{2}$ S=half sensitivity].

of blood past the coronary orifices tending to produce a suction effect, and low pulse pressure may be all in part contributing factors.

The inverted T wave in left ventricular leads may also be of value in the assessment of the severity and the prognosis of aortic stenosis, for they may precede other signs and symptoms of aortic stenosis; furthermore they seem to bear a fairly close relationship to valve size. For example, T wave inversion 5 mm. or more in chest leads was usually associated in this series with a valve circumference 3 cm. or less (Fig. 7 and 8). It is of interest that there is a correlation between the depth of T wave inversion and the duration of the maximal ejection phase of ventricular systole as estimated by the time from the onset to the peak on the peripheral arterial pulse tracing (Table II).

A vertical electrical position in the cardiogram was common in less advanced aortic stenosis as well as in coarctation, but was less frequently found among the series studied after necropsy. The reason for this is not clear. The presence of associated right ventricular hypertrophy does not seem likely to be the factor responsible, for right ventricular hypertrophy is likely to be more common in advanced cases than in the less severe ones. Furthermore, half those with a vertical position shown electrocardiographically had no right ventricular hypertrophy, while less than half of those with right ventricular hypertrophy had shown a vertical position on the electrocardiograph.




FIG. 7.—Facsimile cardiogram from a patient, aged 48 years, with aortic stenosis. Systolic upstroke of arterial pulse wave was 0.22 sec., and gradient across the aortic valve was 120 mm. Note: R in V5=30 mm.; deeply inverted T in V5=8 mm.; inverted T in V3 and intermediate heart position.



FIG. 8.—Facsimile cardiogram of a patient with severe aortic stenosis, showing high voltage of R (29 mm.) and deep T wave (10.0 mm.) inversion, in V5 and horizontal heart position.

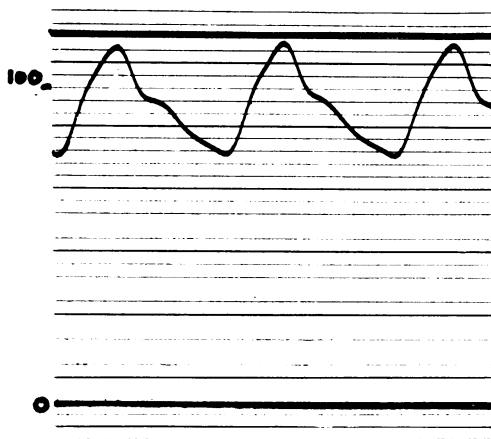


FIG. 9.—Femoral pulse tracing of the same patient. The author has omitted the time-marking but the time of the peak of the wave was 0.25 sec. The calibration is 10 mm. on the tracing = 20 mm. Hg actual pressure, so that this was 115/80 mm.

The present study has confirmed the report of Pagnoni and Goodwin (1952) that clockwise rotation in the presence of electrocardiographic evidence of left ventricular preponderance, suggests the presence of associated right ventricular hypertrophy. Using their criteria for clockwise rotation, all with this sign had associated right ventricular hypertrophy. However, of those with right ventricular hypertrophy less than half showed clockwise rotation.

SUMMARY

Cardiograms from 34 living patients with aortic stenosis have been compared with those of 19 with coarctation of the aorta.

Cardiograms from 19 patients with aortic stenosis who came to necropsy have been compared with those of 15 hypertensive subjects presenting no evidence of ischæmic heart disease at necropsy.

Although the voltage changes in all groups were comparable, T wave inversion was more frequent and of greater magnitude in aortic stenosis than in hypertension or coarctation of the aorta, and was of value in the diagnosis of aortic stenosis.

The depth of T wave inversion bore a close relationship to the severity of the stenosis of the aortic valve and was of value in clinical assessment.

Evidence is given to show that the T wave inversion in aortic stenosis is ischæmic in origin and due to poor coronary flow rather than to coronary artery disease.

Atrial fibrillation and bundle-branch block were late manifestations, but first degree heart block occurred early in the disease.

A vertical heart position was common in aortic stenosis and in coarctation of the aorta. It was much less frequent in the more advanced cases of aortic stenosis and therefore not necessarily related to associated right ventricular hypertrophy. By contrast extreme clockwise rotation ($R < S$ in V5) in aortic stenosis was likely to be due to associated right ventricular hypertrophy.

I am deeply indebted to Dr. J. F. Goodwin and to Dr. A. E. Doyle for assistance with this work. I also wish to thank Prof. C. V. Harrison for his help and for permission to examine necropsy material, and Dr. E. D. Wigle for permission to cite his detailed necropsy studies. Dr. G. H. Neilson kindly provided data on arterial pulse tracings in aortic stenosis.

REFERENCES

- Boas, E. P. (1935). *Amer. J. med. Sci.*, **190**, 376.
Campbell, M., and Kauntze, R. (1953). *Brit. Heart J.*, **15**, 179.
Friedberg, C. K., and Sohval, A. R. (1939). *Amer. Heart J.*, **17**, 452.
Green, H. D. (1936). *Amer. J. Physiol.*, **115**, 94.
Goldberger, E. (1947). *Unipolar Lead Electrocardiography*. Henry Kimpton, London.
Kiloh, G. A. (1950). *Brit. Heart J.*, **12**, 33.
Lewes, D. (1951). *Brit. med. J.*, **1**, 211.
Mitchell, A. M., Sackett, C. H., Hunzicker, W. J., and Levine, S. A. (1954). *Amer. Heart J.*, **48**, 684.
Pagnoni, A., and Goodwin, J. F. (1952). *Brit. Heart J.*, **14**, 450.
Wigle, E. D. (1957). Personal communication.