

# AUSCULTATION IN PATENT DUCTUS ARTERIOSUS

## WITH A DESCRIPTION OF TWO FISTULÆ SIMULATING PATENT DUCTUS

BY

CATHERINE NEILL\* AND PATRICK MOUNSEY

*From the Cardiac Department of The London Hospital*

Received May 23, 1957

The purpose of this paper is to describe the characteristics of the murmur of patent ductus, to show in what way auscultation may be modified by pulmonary hypertension, a large shunt, or associated heart disease, and to compare the continuous murmur of patent ductus with continuous murmurs due to other causes.

### THE INVESTIGATION DESCRIBED

A series of 73 patients with patent ductus is described, of whom 71 were selected for surgical treatment, while the two remaining patients had complicating severe pulmonary hypertension with a right-to-left shunt. The diagnosis of patent ductus was confirmed at operation in 71 patients. In the two patients with pulmonary hypertension, who were not treated by operation, necropsy proof of the diagnosis was obtained.

In the nine-year period, during which these patients were operated upon, six other patients were submitted to thoracotomy, in whom the ductus was found to be closed. In four of these patients the diagnosis remains in doubt, although one patient is thought to have an aorto-pulmonary septal defect. The other two patients with fistulae have been further investigated and submitted to a second operation; in one it has been shown to be between the aorta and right ventricle and in the other between the coronary artery and right ventricle.

Clinical examination was amplified by a phonocardiogram in every patient and in 20 a post-operative phonocardiogram was obtained. Routine examination before operation also included a teleradiogram and an electrocardiogram. Cardiac catheterization was performed in 12 patients in whom pulmonary hypertension, a large shunt, or associated heart disease indicated the need for fuller investigation. Angiocardiography was carried out in one patient, in whom coarctation and an aneurysm of the aorta were present in addition to a patent ductus.

### CLINICAL FEATURES

There were 63 female and 10 male patients. The age at operation ranged from 18 months to 63 years. Seven were under 5 years, 36 between 5 and 15, 23 between 15 and 30, and five over 30 years. The patients with severe pulmonary hypertension, not operated upon, were 15 and 56 years old respectively when they died; both were female. Seventy-one of the patients were in sinus rhythm, but the two oldest, aged 49 and 63 years, were in atrial fibrillation.

Two inter-related variables influence the clinical picture of patent ductus namely the volume of the left-to-right shunt and the degree of complicating pulmonary hypertension, which may be present. Most patients have a small shunt and their pulmonary arterial pressure is not significantly raised. There were 49 such patients in the present series. These patients were free from symptoms, had a typical continuous murmur, a pulse that was normal or only slightly collapsing in character

\* Now Assistant Professor of Pediatrics, Johns Hopkins University, Baltimore.

and a prominent pulmonary artery without much pulsation. In addition the signs of left ventricular enlargement were slight or absent both on screening and in the electrocardiogram, and at operation the ductus was found to be small, with an external diameter of less than 1 cm.

A *large shunt* was diagnosed in 22 patients in whom there was considerable left ventricular enlargement shown by a cardio-thoracic ratio of 60 per cent or more, left ventricular preponderance in the electrocardiogram, a large ductus with an external diameter of 1 cm. or more, and an unusually strong thrill at operation. In addition they had a wide pulse pressure, pulmonary plethora, obvious hilar dance, and in eight patients there was a functional mid-diastolic murmur. Cardiac catheterization was carried out in 6 of the 22 patients and indicated that the pulmonary flow was at least twice the systemic. Considerable variation may occur, however, in the oxygen content of samples from the pulmonary artery, withdrawn from different sites and at different phases in the cardiac cycle in patients with a patent ductus. This may be due to streaming of the blood entering simultaneously from the right ventricle and the ductus, and also to the fact that the pulmonary arterial blood is probably more saturated in diastole, when the ductus alone is feeding it, than in systole. These factors are likely to introduce a considerable margin of error into a detailed estimation of the volume of the shunt.

Whereas the presence of a large shunt does not make clinical diagnosis more difficult, *pulmonary hypertension* may profoundly modify the characteristic signs of patent ductus. Where the pulmonary arterial pressure, although raised, remains well below the systemic pressure, the clinical picture is little affected. A continuous murmur is audible, there is no right ventricular preponderance in the electrocardiogram, and the elevation of the pulmonary pressure is reversible by surgery, the increased pressure being directly related to the increased flow in these patients.

Where the pulmonary arterial pressure approaches that of the aorta, the characteristic continuous murmur of patent ductus is lacking. These patients, sometimes said to have "balanced ductus", form a small, but important, group. They have the clinical signs of a large left-to-right shunt, including a wide pulse pressure, pulmonary plethora, and radiological evidence of left ventricular enlargement. The electrocardiogram shows dominant left ventricular preponderance with added signs of right preponderance. The diagnosis can be suspected on clinical grounds, but can only be established with certainty by passage of a cardiac catheter through the ductus or by retrograde aortography. These patients are greatly benefited by surgery, if the diagnosis is made early, before calcification of the ductus and pulmonary artery or other complications ensue. There were two such patients in the present series. In one, aged 33, cardiac catheterization showed a continuing left-to-right shunt through the ductus, although the diastolic pressure in the pulmonary artery and aorta were equal, the aortic pressure being 150/60 and the pulmonary arterial pressure being 115/60 mm. Hg. At operation the external diameter of the ductus was very large and there was more extensive calcification than had been apparent radiologically (Fig. 1), which extended into the aorta and pulmonary artery. It was decided that neither ligation nor division of the ductus could be safely performed. In the other patient, aged 26, who was in heart failure during pregnancy, there was aneurysmal enlargement of the pulmonary artery, which showed vigorous pulsation, and plethora, so that the radiological picture closely resembled that of atrial septal defect. The electrocardiogram, however, showed dominant left ventricular preponderance and the pulse was collapsing in character. Cardiac catheterization was cut short by a serious arrhythmia. At operation the ductus, which was found to be very large, with an external diameter of 2 cm., was satisfactorily divided, and since operation the patient has made an uninterrupted recovery.

Where the pulmonary arterial pressure exceeds that in the aorta and the direction of the shunt through the ductus is reversed, there is cyanosis best seen in the lower extremities, no continuous murmur, a loud pulmonary second sound, a large pulmonary artery, clear peripheral lung fields and right ventricular preponderance in the electrocardiogram. Operation is contra-indicated in these patients (Johnson *et al.*, 1950; Cosh, 1953; Dammann *et al.*, 1953). Two patients with this clinical picture were included in the present series. One had been cyanosed since the age of five and dyspnoic since the age of ten; she died when she was 15 years old. The other had been cyanosed on

effort since childhood, becoming deeply cyanosed with clubbing of the toes and fingers and marked polycythæmia in her fourth and fifth decades. She died at the age of 56 with extensive thrombosis and infarction in the pulmonary arterial tree. At autopsy a large patent ductus with great pulmonary arterial enlargement and great right ventricular hypertrophy was found in both patients. In the older patient gross calcification was present in the pulmonary artery, the ductus, and the aorta.

#### AUSCULTATION

In patent ductus two opposing streams crash head on within the pulmonary artery, one surging from the right ventricle upwards and backwards along its course, the other, a narrower powerful jet, projected by the high aortic pressure through the ductus into the pulmonary artery, where it meets the on-coming stream from the right ventricle. Since the pulmonary valve orifice is larger than that of the ductus and since a different course is taken by the two streams, the greater flow into the pulmonary artery in early systole is from the right ventricle. Later, as ventricular systole nears completion, the greater flow is from the ductus, and one may imagine turbulent eddies forming at this Watersmeet of the main pulmonary artery, until finally in diastole the flow is from the ductus alone. The typical murmur of patent ductus seems to mirror these events, for not only has it the continuous quality heard in murmurs due to arterio-venous shunts, but also, as it increases towards the end of systole and beginning of diastole, it is often punctuated by reverberations which vary from beat to beat as eddies swirl within the pulmonary artery.

A loud *continuous murmur* in the pulmonary area, in which there was no interruption between the systolic and diastolic components at the time of the second heart sound, was heard in all patients in the series with the exception of four with pulmonary hypertension. An accompanying thrill was felt in most patients. The phonocardiogram showed that the murmur varied in length and in about half the patients it was almost continuous throughout the cardiac cycle, while in the remaining half there was a gap of about one-tenth of a second between the first heart sound and the beginning of the murmur and a second gap of varying duration between the end of the murmur and the succeeding first heart sound. The murmur was shown to be loudest around and immediately before the second heart sound in 64 of the 69 patients (Fig. 2). Of the five patients who did not show this sign, one had pulmonary incompetence which persisted after ligation of the ductus and was thought to be due to a congenital abnormality of the pulmonary valve, one had aortic stenosis and incompetence, one was a child of eighteen months, while in the remaining two patients no cause for the different form of the murmur was apparent. The accentuation of the murmur around the second heart sound has been emphasized by many authors (Levine and Geremia, 1947; Evans, 1954; Haring *et al.*, 1954), since Gibson first described it in 1900.

In 34 patients with louder continuous murmurs, multiple clanging "*eddy sounds*", relatively localized to the pulmonary area, punctuated the systolic and diastolic portions of the continuous murmur (Fig. 3). The sounds varied from beat to beat, both in number and the exact place in the cardiac cycle, and in some beats they were altogether absent. In certain cycles as many as five such sounds were heard and it was difficult to recognize the true second heart sound amongst them without the aid of a phonocardiogram. These sounds were thought to be due to turbulent eddying currents set up in the main pulmonary artery and were most frequent in the second half of systole

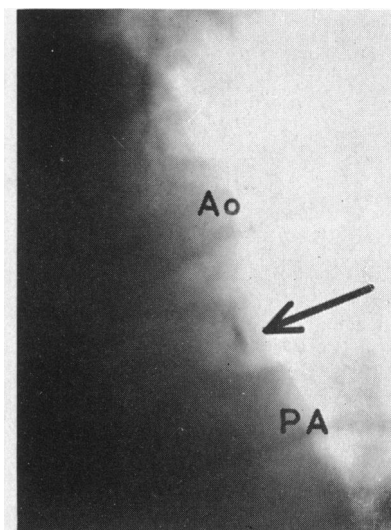


FIG. 1.—Portion of postero-anterior teleradiogram. Linear fleck of calcium (arrow) in the wall of a patent ductus in a patient with pulmonary hypertension. Ao=aorta. PA=pulmonary artery.

and beginning of diastole, when the flow from the ductus becomes the dominant and later the sole source feeding the pulmonary artery. Eddy sounds were not thought to be related to the closure of the semilunar valves, since the sounds were often more than two in number, sometimes widely separated from the second heart sound, and because of their great intensity even in the absence of pulmonary hypertension. In addition, comparison of the pressure records obtained at catheterization and the phonocardiogram indicated that these eddy sounds sometimes preceded and sometimes

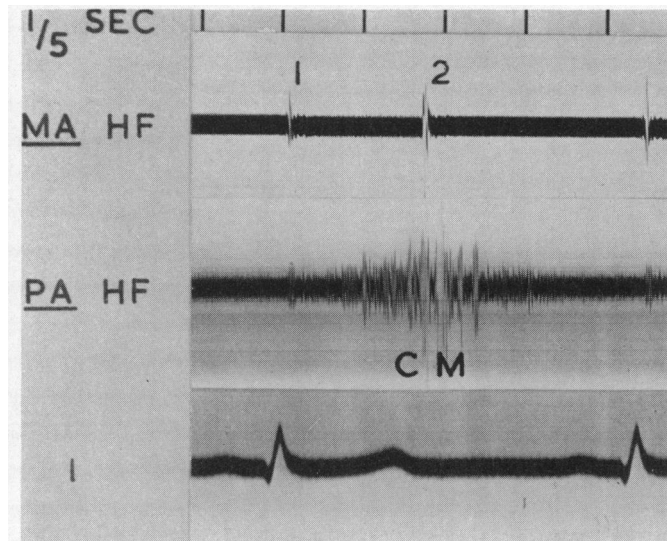


FIG. 2.—Phonocardiogram of the continuous murmur (CM) of patent ductus, loudest around the second heart sound (2). 1=first heart sound. MA and PA= mitral and pulmonary areas. HF=high frequency. I=electrocardiographic lead I.

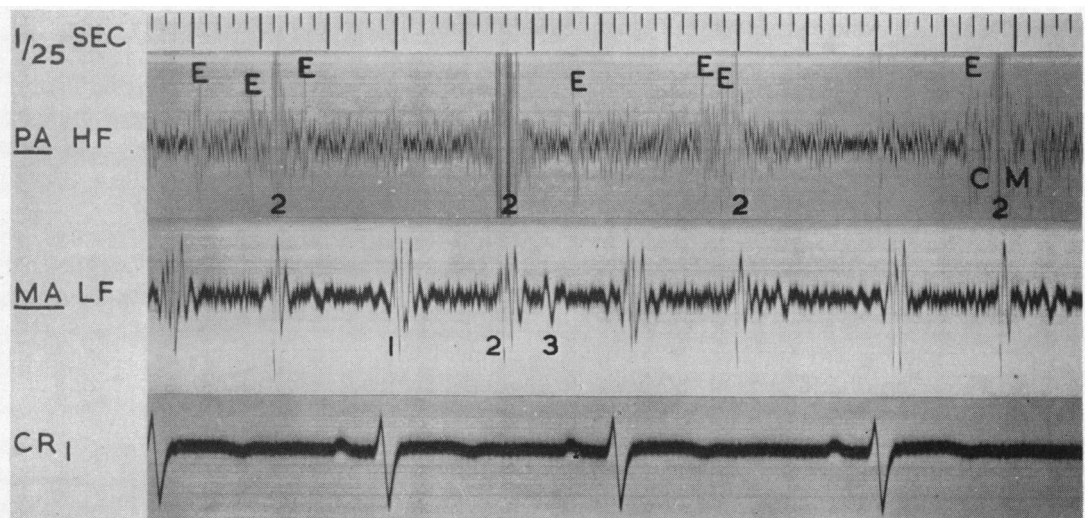


FIG. 3.—Eddy sounds (E), punctuating the continuous murmur (CM) of patent ductus in the pulmonary area. (PA). The timing and loudness of these sounds vary from beat to beat. 1, 2, and 3=first, second, and third heart sounds. MA=mitral area. HF and LF=high and low frequency. CR<sub>1</sub>=electrocardiographic lead CR<sub>1</sub>.

followed pulmonary and aortic valve closure, which could not, therefore, explain the sounds.

After ligation of the ductus the continuous murmur disappeared in all patients. It was often replaced by an insignificant and sometimes temporary systolic murmur in the pulmonary area, probably related to residual enlargement of the pulmonary artery.

The ductus is thought to have recanalized in the only two patients in whom the continuous murmur re-appeared after operation. In one of these the murmur returned within one month of operation, while in the other it was heard at the first attendance for review seven years later.

No *continuous murmur* was heard in the four patients with *severe pulmonary hypertension*. In the two patients with a reversed shunt, there was a soft early systolic murmur followed by an early diastolic murmur (Fig. 4A). In addition there was an atrial systolic murmur at the right sternal edge, probably due to a combination of right atrial hypertrophy and increased flow through the tricuspid valve due to the right-to-left shunt. Of the two patients in whom the pulmonary arterial pressure approached aortic pressure, one showed a soft early systolic murmur in the pulmonary area (Fig. 4B), while the second patient had a rough uneven systolic murmur followed by an early diastolic murmur (Fig. 4C). The early diastolic murmur was thought to be due to pulmonary regurgitation, resulting from dilatation of the pulmonary artery (Laubry, 1930). In the latter patient

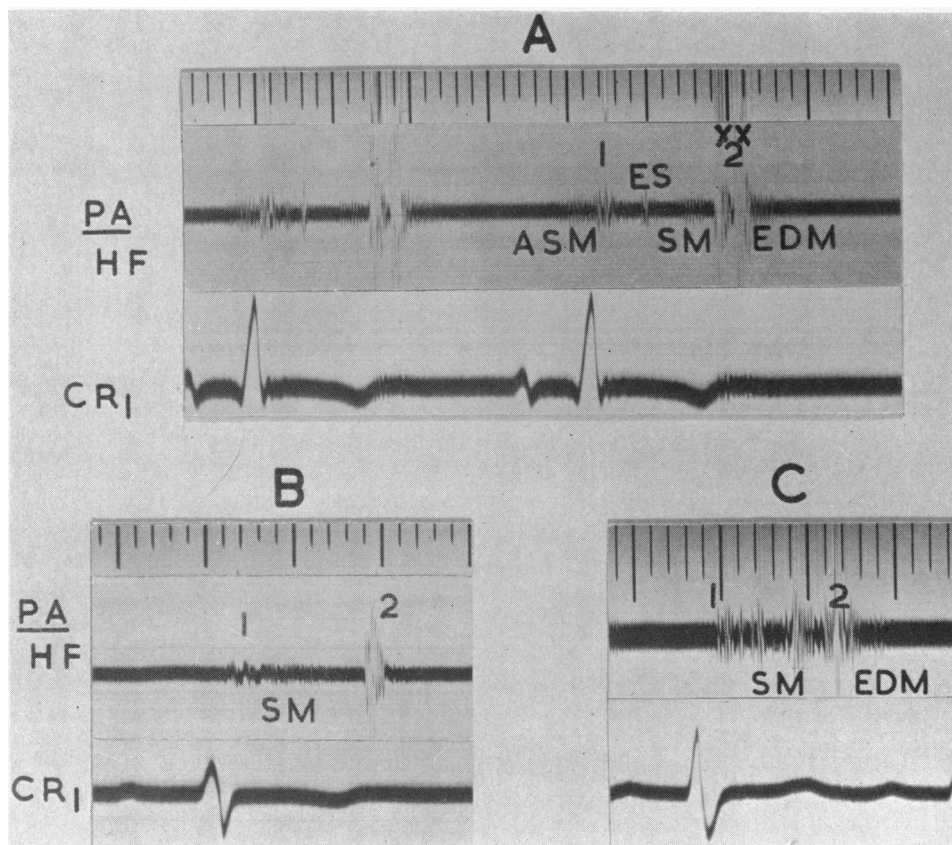


FIG. 4.—Absence of the continuous murmur in the pulmonary area (PA) in three patients (A, B, and C) with patent ductus complicated by pulmonary hypertension. Patient A had a reversed shunt. Patients B and C had balanced pressures. ASM=atrial systolic murmur. ES=ejection sound. SM=systolic murmur. EDM=early diastolic murmur. 1=first heart sound. 2xx=split second sound. HF=high frequency. CR<sub>1</sub>=electrocardiographic lead CR<sub>1</sub>.

it persisted for 48 hours after division of the ductus before disappearing permanently, this delay being presumably due to a gradual readjustment of pressures in the pulmonary circulation.

Mannheimer (1950) described four patients with proven patent ductus and pulmonary hypertension who had only a systolic murmur. Numerous reports have emphasized that there is no continuous murmur where pulmonary and aortic pressure levels approximate, either in adults with pulmonary hypertension (Wood, 1952; Hultgren *et al.*, 1953) or in infants with high pulmonary pressures and relatively low systemic pressures (Dammann and Sell, 1952; Ziegler, 1952; Bonham-Carter and Lovel, 1953). Although in an infant with a patent ductus a continuous murmur becomes more readily heard later, as the aortic pressure rises above that in the pulmonary artery (Gilchrist, 1945), the converse, namely the disappearance of a continuous murmur with increasing pulmonary hypertension, is rare (Campbell and Hudson, 1952).

The *second heart sound*, which is enveloped in the continuous murmur, was often difficult to analyse in detail. In 11 patients the phonocardiogram showed that the sound was clearly split, an interval of 0.03 to 0.04 sec. separating the two components, while in six patients it was clearly single. None of these patients had significant pulmonary hypertension and hence the pulmonary component of the second heart sound was not accentuated. Of the two patients with a *reversed shunt*, in one the second heart sound was widely split, the second or pulmonary component being very loud (Fig. 4A), while in the other the second sound was loud and single. Of the two patients with a "*balanced ductus*", in whom the pulmonary arterial pressure approached that in the aorta, in one the second sound was very loud and single (Fig. 4B), while reversed splitting of the second sound was thought to be present in the other patient, pulmonary valve closure preceding aortic valve closure in the phonocardiogram, as described by Gray (1956). In the latter patient we believe delayed aortic valve closure to have resulted from a conduction delay in the left ventricle, the electrocardiogram showing great left ventricular preponderance with broadening and notching of the QRS complex, which was 0.1 sec. wide. It is unlikely to have been directly related to increased left ventricular stroke output resulting from the large left-to-right shunt, since reversed splitting of the second sound persisted after ligation of the ductus.

In 34 patients eddy sounds made it impossible to recognize with certainty splitting of the second heart sound and in a further 18 patients the second sound could not be analysed in detail, since it was obscured by the murmur.

An *ejection sound* over the base of the heart, as described by Leatham and Vogelpoel (1954), was heard in three patients, of whom two (Fig. 4A) had aneurysmal dilatation of the pulmonary artery with pulmonary hypertension and the third enlargement of the ascending aorta due to coarctation. An ejection sound in patent ductus with a large pulmonary artery may be more frequent than we have found it, but its recognition in our patients was rendered difficult by the beginning of the continuous murmur.

A *third heart sound* was present in 33 of the 52 patients in whom a low-frequency phonocardiogram was recorded in the mitral area, but it was sometimes difficult to detect clinically owing to the intensity of the continuous murmur. The high incidence of a third heart sound in this series was expected, since 40 of the 52 patients were below the age of 25 and Evans (1943) showed a third heart sound to be a relatively common finding in healthy subjects in this age group. None of the patients over the age of 40 had a third heart sound.

An *apical mid-diastolic murmur* was present in 8 of the 22 patients with a large left-to-right shunt through the ductus (Fig. 5). The mid-diastolic murmur was usually soft and never of more than moderate intensity, and resembled in character a soft rumbling murmur of mitral stenosis. It was never accompanied by a thrill. It varied in length, averaging about 0.15 sec., although in one patient it was only 0.08 sec. long. The timing of the murmur was in mid-diastole, although in one patient this coincided with atrial systole, due to tachycardia. All the patients with a mid-diastolic murmur also had an apical systolic murmur.

A distant *snap-like* sound preceded the mid-diastolic murmur in five of these eight patients (Fig. 5). It resembled, both in character and in its place in the cardiac cycle, a distant opening snap

of mitral stenosis, although it was usually best heard a little further out towards the apex. The interval between the beginning of the second heart sound and the snap lay between 0.06 and 0.1 sec., which is within the range (0.03 to 0.14 sec.) found in mitral stenosis (Mounsey, 1953). The mid-diastolic murmur immediately followed the snap in three patients, and after an interval of 0.05 sec. in the remaining two. In addition to the snap a third heart sound was seen in the low-frequency phonocardiogram in all eight patients and in two of them it was abnormally large.

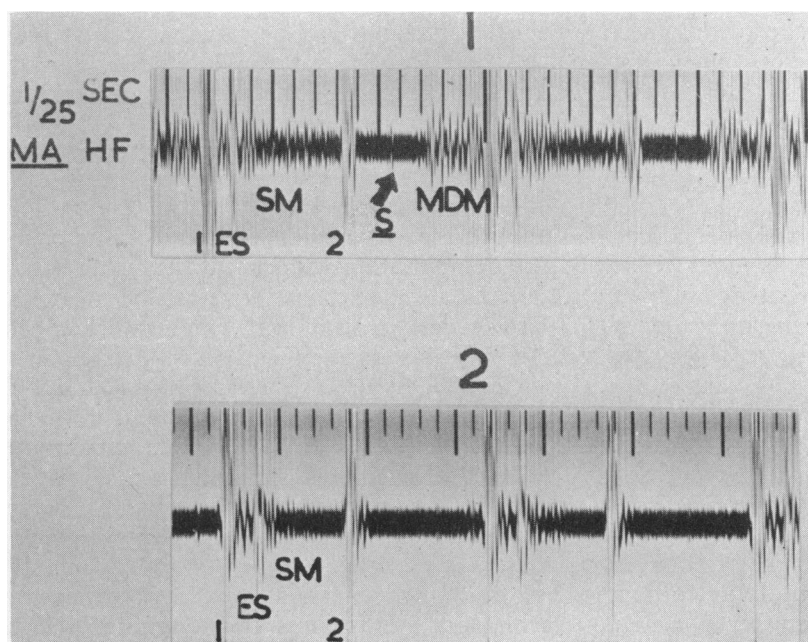


FIG. 5.—Phonocardiograms of the same patient (1) before and (2) after ligation of a patent ductus with a large left-to-right shunt. The snap (S) and mid-diastolic murmur (MDM) in the mitral area (MA) have disappeared after operation. 1 and 2=first and second heart sounds. ES=ejection sound. SM=systolic murmur. HF=high frequency.

After ligation of the ductus the mid-diastolic murmur and snap disappeared in seven of the eight patients (Fig. 5). The apical systolic murmur became softer, but it was never abolished completely. The abnormally large third heart sound in two patients disappeared.

The disappearance of the mid-diastolic murmur and snap in seven of the eight patients after operation indicated that these signs were not due to mitral stenosis, but resulted from increased flow through the mitral valve. Further support is lent to this theory by the presence of a large third heart sound in two of the patients, which is never found in tight mitral stenosis. Turbulent flow murmurs are well recognized (Nadas and Alimurung, 1952) and have been described in ventricular defect and patent ductus (Ravin and Darley, 1950). The origin of the snap is less clear. Whether it is produced at the mitral valve, and, if so, whether a healthy mitral valve can give rise to a snap in the presence of increased blood flow or whether some abnormality or scarring of the valve is necessary in addition is open to speculation. Leatham and Gray (1956) suggested that a similar snap sound and diastolic murmur may be produced at the tricuspid valve under conditions of increased blood flow in atrial septal defect.

The *simulation of mitral stenosis* in patent ductus with a large shunt has been referred to by Vernant *et al.* (1955) as the *syndrome pseudo-mitrale*. They found a mid-diastolic murmur, a rather abrupt first sound, fullness of the left atrium, bifid P waves, and a raised pulmonary capillary

pressure in some of their patients with a large shunt. They did not, however, comment on a snap sound. The mid-diastolic murmur disappeared after operation in all their patients, and the pulmonary capillary pressure returned to normal in those who were examined by cardiac catheterization after operation. Their conclusion was that increased blood flow through the mitral valve in patent ductus may give rise to relative mitral stenosis. In our series one patient with a snap and mid-diastolic murmur was found to have a raised pulmonary capillary pressure (15/12 mm. Hg) and both snap and murmur disappeared after operation. A mid-diastolic murmur was associated with fullness of the left atrium in two of our patients with a large shunt, and five had bifid P waves. The association of a snap sound with a mid-diastolic murmur in five of our patients further emphasizes the close similarity between the clinical signs of a large shunt in patent ductus and those of mitral stenosis.

#### ASSOCIATED HEART DISEASE

Aortic valve disease, coarctation of the aorta, ventricular septal defect, and pulmonary stenosis are the conditions most frequently met in association with patent ductus and examples of each were seen in our series of patients. Of the nine patients with associated heart lesions, two had coarctation of the aorta (one with a large aneurysm distal to it), one ventricular defect, one aortic stenosis, three aortic stenosis and incompetence, one simple pulmonary stenosis, and one pulmonary incompetence. An additional murmur, or the absence of the femoral pulse, made it possible in most patients to recognize the associated lesion and we were thus able to warn the patients before operation that surgery would not effect a complete cure. Where the continuous murmur was loud, it was not always easy to recognize the additional lesion. Thus, in the three patients with aortic stenosis and incompetence, the soft early diastolic murmur was only recognized before operation in one. The characteristic loud systolic murmur of aortic stenosis, with a gap before the second heart sound on the other hand (Alzamora-Castro *et al.*, 1948; Levine, 1949; Leatham, 1951), could be clearly made out in the aortic area both in these three patients and in the patient with lone aortic stenosis. In another patient mild pulmonary stenosis was only diagnosed after operation. In the patient with a ventricular septal defect and patent ductus the clinical signs suggested the double diagnosis, which was later confirmed by cardiac catheterization and by the persistence of the pansystolic murmur and thrill following ligation of the ductus.

#### DIFFERENTIAL DIAGNOSIS OF THE CONTINUOUS MURMUR

Since the continuous murmur holds pride of place in the diagnosis of patent ductus, there is need to compare its timing and quality with continuous murmurs due to other causes. The continuous murmur arising from bronchial arteries in pulmonary atresia, systemic and pulmonary arteriovenous aneurysms, and collateral arteries in coarctation were examined. All of these resembled patent ductus in that the murmur was loudest around the second heart sound, but its time of onset differed (Fig. 6) and it appeared to be related to the site in the circulation where the murmur was produced. Thus in pattern and timing the murmur of patent ductus and that arising from bronchial arteries in pulmonary atresia were similar: in systemic and pulmonary arterio-venous fistula and collateral arteries in coarctation, on the other hand, the crescendo to the murmur started later, the delay being probably due to the increased time taken by the pulse wave to reach the affected vessel. The murmur of venous hum differed from other continuous murmurs in that it was not loudest around the second heart sound, there being a crescendo in mid-diastole when rapid venous filling of the heart was taking place (Fig. 7). These lesions, however, seldom present a diagnostic problem, since the site where the murmur is best heard and the general clinical picture usually exclude patent ductus. Defects of the aortic and bulbar septa and abnormal coronary vessels, on the other hand, may sometimes be very difficult to distinguish clinically from patent ductus, and a description of three such patients is given below.



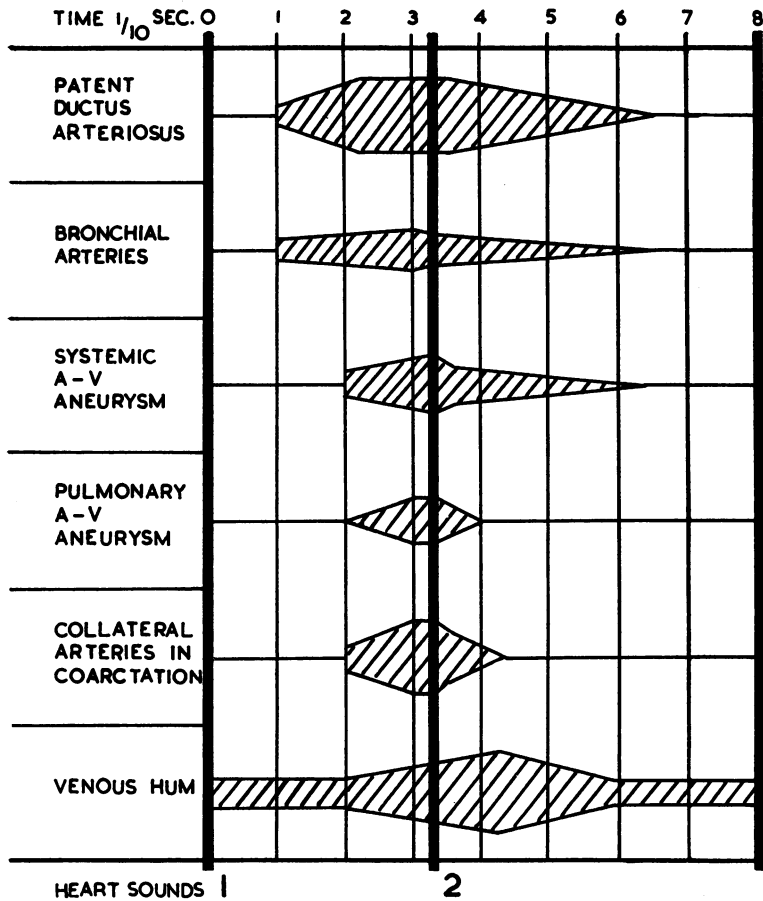


FIG. 6.—Diagram of phonocardiograms illustrating the relative place in the cardiac cycle of continuous murmurs due to different causes. The timing of a venous hum is also shown. The heavy vertical lines indicate the first and second heart sounds.

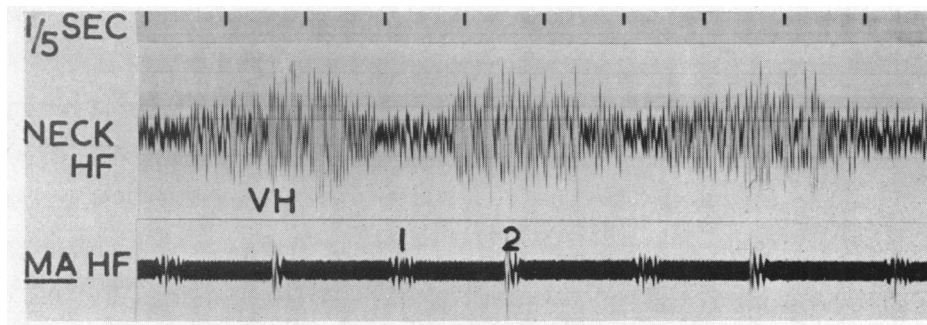


FIG. 7.—Venous hum (VH) recorded in the neck. 1 and 2=first and second heart sounds. MA=mitral area. HF=high frequency.

## SIX PATIENTS IN WHOM NO PATENT DUCTUS WAS FOUND

There were six patients in this series in whom thoracotomy was undertaken and no patent ductus found, but in only two of these was the continuous murmur completely typical of patent ductus. Three of the patients have not been further investigated since they have few symptoms. Their operations were performed between six and nine years ago and in view of their unusual murmurs a ductus would probably now have been excluded by cardiac catheterization rather than by an exploratory thoracotomy. Of the remaining three patients, a diagnosis of aorto-pulmonary septal defect was made at thoracotomy in one, while two have since been further investigated.

The patient believed to have an *aorto-pulmonary septal defect* is of special interest due to the progressive change in cardiac murmurs. She had at the age of four a continuous murmur, best heard in the pulmonary area and loudest around the second heart sound, typical in all respects of a patent ductus (Fig. 8). At thoracotomy no patent ductus was found, but there was a thrill low

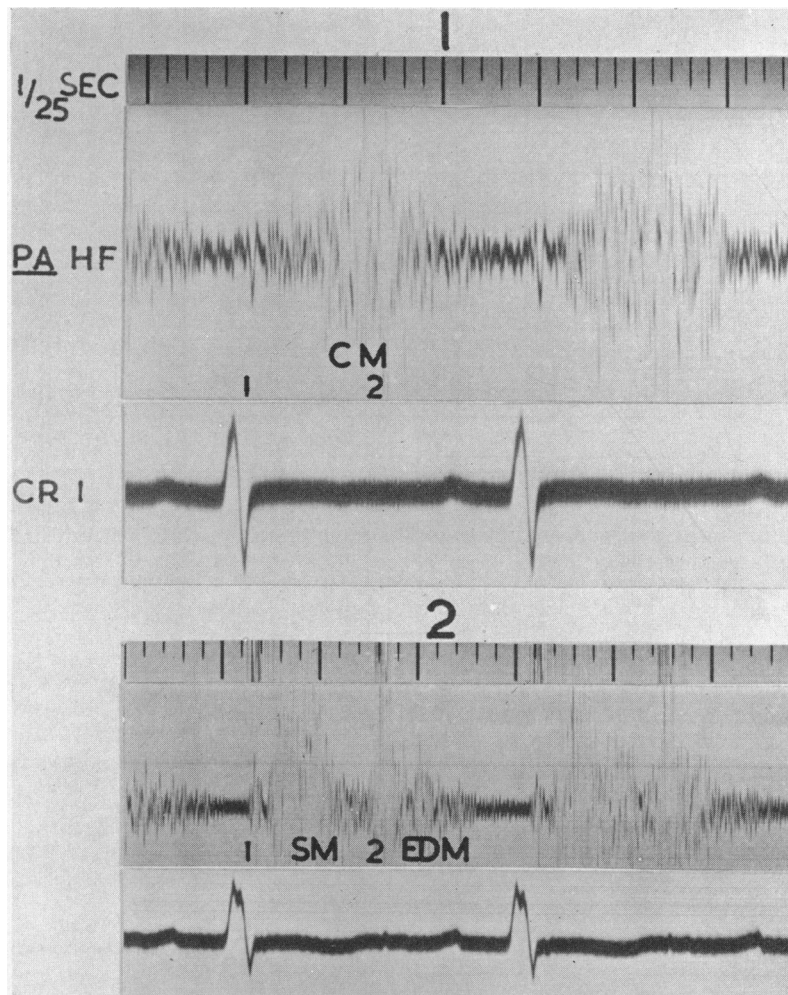


FIG. 8.—Phonocardiograms of the same patient, (1) aged four years and (2) aged eight, who is believed to have an aorto-pulmonary septal defect. Replacement of a continuous murmur (CM) in the pulmonary area (PA) by a systolic murmur (SM) and an early diastolic murmur (EDM). 1 and 2=first and second heart sounds. HF=high frequency. CR<sub>1</sub>=electrocardiographic lead CR<sub>1</sub>.

down near the base of the aorta and pulmonary artery, which was greatly enlarged. A diagnosis of aorto-pulmonary septal defect was made and it was decided not to attempt closure of the defect at that time. She has now been followed for four years since thoracotomy and the continuous murmur has been replaced by a systolic and early diastolic murmur (Fig. 8). Progressive electrocardiographic and radiological changes suggest that the alteration in the murmur is due to increasing pulmonary hypertension. Permission for cardiac catheterization has so far been refused.

An *aorto-right-ventricular fistula* was the cause of the continuous murmur in a man, aged 58 years. A cardiac murmur was first heard at the age of 11, and a continuous murmur had been known to be present since the age of 28 years. He had an obvious Corrigan pulse with vigorous pulsation of both aorta and pulmonary artery on screening and some left ventricular enlargement. There was a prominent thrill localized at the fourth space between the sternum and the apex beat. The murmur, which was superficial, very loud, and continuous, was greatest in mid-systole, waned around the second heart sound, and waxed again in mid-diastole (Fig. 9). It thus differed in site

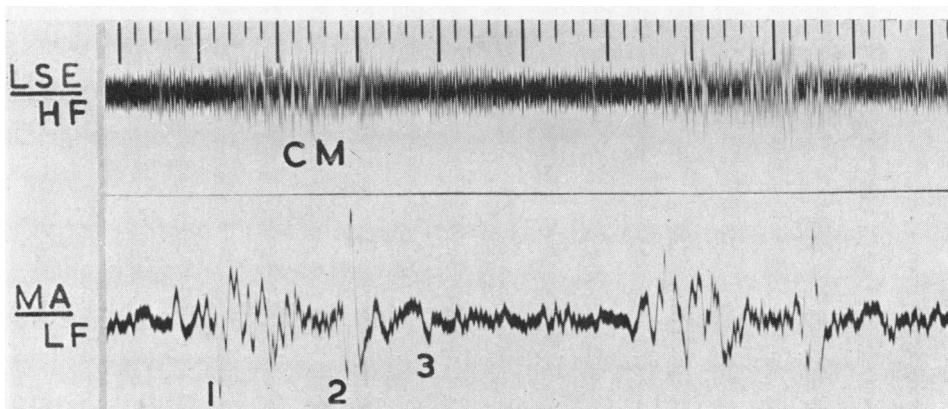


FIG. 9.—Continuous murmur (CM) in the fourth intercostal space at the left sternal edge (LSE) in a patient with an aorto-right-ventricular fistula. The murmur is not clearly loudest around the second heart sound (2). 1 and 3=first and third heart sounds. MA=mitral area. HF and LF=high and low frequency.

and timing from the characteristic murmur of patent ductus. At the first thoracotomy in 1945 no patent ductus was found, but following this, the patient complained of considerable anterior chest pain, which he stated was continuous and prevented him from working. In 1955, in view of the persistence of pain and continued evidence of intra-cardiac shunt, it was decided to investigate him further. Angiocardiography showed an anomalous channel arising anteriorly from the aorta and refilling of the pulmonary artery, simultaneously with aortic filling. Cardiac catheterization indicated a small left-to-right shunt in the upper part of the right ventricle. At the second thoracotomy, the abnormal channel was found to be within the right ventricular wall and appeared to be fed from an aneurysm of the sinus of Valsalva. The thrill diminished following insertion of five deep ligatures into the right ventricular muscle, but the channel could not be completely occluded. Its nature remains uncertain, but it is probably a congenital cardio-aortic fistula associated with an aneurysm of the sinus of Valsalva. The patient declares that his chest pain has been removed by the second operation, but the physical signs in the heart are unchanged. Jones and Langley (1949) in a review of the reported cases of cardio-aortic fistula noted that, where the fistula appeared from the history to be congenital, the condition was sometimes compatible with quite a long span of life, one patient dying at the age of 51 years from intercurrent disease. More recently Brown *et al.* (1955) reported a case of cardio-aortic fistula, which was closed by open heart surgery, after which the patient unfortunately died.

A coronary-right-ventricular fistula was the cause of the continuous murmur in a woman, aged 56, who presented with recent congestive failure after a very active life. A cardiac murmur was first heard at the age of 18, but there is no record of its nature at that time. The continuous murmur did not show definite accentuation around the second heart sound, but it was otherwise typical of patent ductus in site and quality (Fig. 10). There was left ventricular enlargement on screening

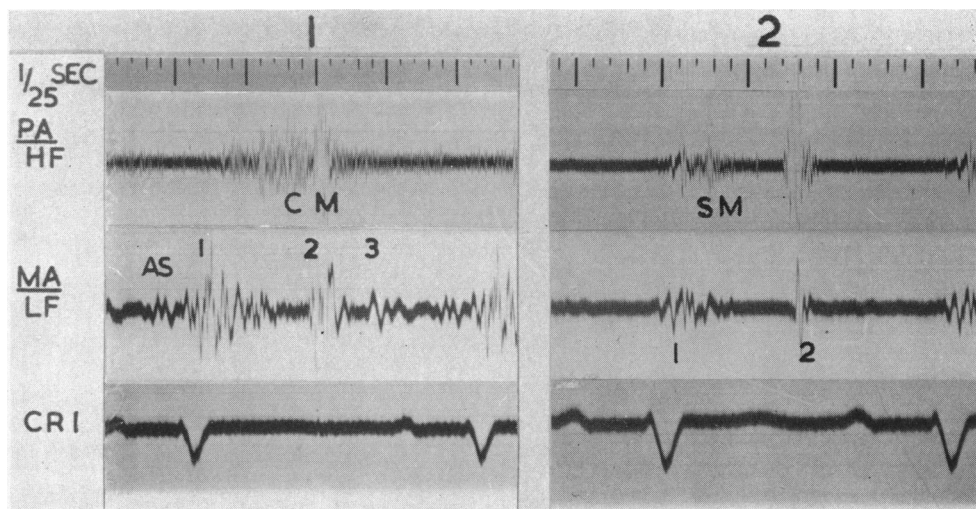


FIG. 10.—Phonocardiograms of the same patient, (1) before and (2) after ligation of a coronary-right-ventricular fistula. The continuous murmur (CM) in the pulmonary area (PA) has disappeared after operation and only a small murmur (SM) remains. AS=atrial sound. 1, 2, and 3=first, second, and third heart sounds. MA=mitral area. HF and LF=high and low frequency. CR<sub>1</sub>=electrocardiographic lead CR<sub>1</sub>.

and the main pulmonary arteries were enlarged and vigorously pulsating. The electrocardiogram showed considerable left ventricular preponderance. The pulse was full and the blood pressure 180/100 mm. Hg. A moderate increase in pulmonary arterial pressure was found at cardiac catheterization (70/25 mm. Hg) and there was evidence of a small left-to-right shunt in the pulmonary artery, but no shunt was demonstrated in the right ventricle. No patent ductus was found at thoracotomy, but large tortuous coronary arteries were seen and it was thought that the lesion might be a coronary anomaly similar to that described by Baylis and Campbell (1952) and by Davis *et al.* (1956), in which a branch of the left coronary artery entered the right ventricle. A subsequent angiocardiogram showed refilling of the pulmonary artery and in the lateral view an abnormal dilated tortuous coronary artery filling from the aorta (Fig. 11). At a second thoracotomy a dilated branch of the left coronary artery entering the conus of the right ventricle was ligated and the continuous murmur immediately disappeared (Fig. 10). It was noted, however, at both operations, that the whole coronary arterial tree appeared to be dilated and tortuous so that the shunt between the left coronary artery and the right ventricle may not have been the sole coronary anomaly. The initial improvement following operation has not been maintained, in spite of the permanent disappearance of the continuous murmur, and the patient remains in chronic congestive failure.

The simulation of the continuous murmur and general clinical picture of patent ductus by a high ventricular septal defect with aortic incompetence, due to a sagging aortic valve cusp, has been discussed by Gross and Longino (1951), Wood *et al.* (1954), and Bonham-Carter and Walker (1955), but no example of this condition has been proven among our patients.

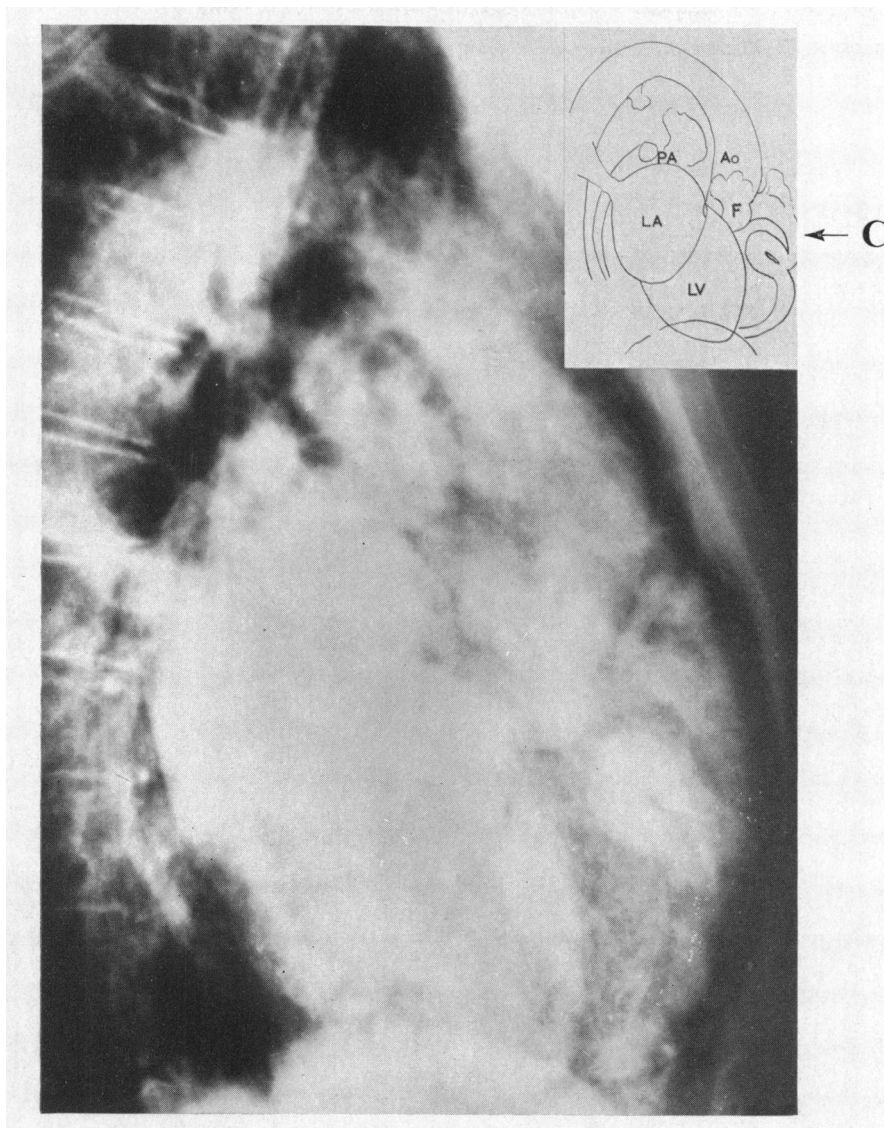


FIG. 11.—Angiocardiogram of patient with a coronary-right-ventricular fistula. A dilated, tortuous coronary artery (C) is seen anteriorly, while posterior to it is another coronary branch (F), which is probably the fistula entering the right ventricle, through which refilling of the pulmonary artery (PA) is taking place. LV=left ventricle. LA=left atrium. Ao=aorta. Angiocardiogram in left lateral position.

#### SUMMARY AND CONCLUSIONS

The auscultatory signs have been examined clinically and in the phonocardiogram in 73 patients with patent ductus arteriosus. The diagnosis was confirmed at operation in 71 patients and at autopsy in the remaining two.

In the absence of significant pulmonary hypertension a continuous murmur was always present. It was best heard in the pulmonary area and in 64 of the 69 patients it was loudest around the second heart sound.

Multiple eddy sounds were a feature of the murmur and were sometimes difficult to differentiate from the second heart sound.

In the four patients in whom the pulmonary artery pressure equalled or exceeded that in the aorta the continuous murmur was curtailed to a relatively soft systolic murmur; in three there was an early diastolic murmur from added pulmonary regurgitation.

A large left-to-right shunt through the ductus was judged to be present in 22 of the patients and in 8 of these there was an apical mid-diastolic murmur. In addition a distant snap sound preceded the mid-diastolic murmur in five of these eight patients. After ligation of the ductus, the mid-diastolic murmur and snap disappeared in all but one. Where the murmur and snap disappeared after abolition of the shunt, these signs were thought to arise from an increased flow through the mitral valve and did not indicate mitral stenosis.

In the two patients with a reversed shunt through the ductus due to pulmonary hypertension, an atrial systolic murmur was heard at the right sternal edge.

Aortic valve disease, coarctation of the aorta, ventricular septal defect, and pulmonary stenosis were the conditions met in association with patent ductus. An additional murmur, or the absence of the femoral pulse, made it possible, in most patients, to recognize the associated lesion before ligation of the ductus.

Continuous murmurs due to systemic and pulmonary arterio-venous aneurysm and to bronchial arteries in pulmonary atresia were found to show the same accentuation around the second heart sound as the characteristic murmur of patent ductus, but the crescendo to the murmur started later in arterio-venous aneurysm.

In the period during which these patients with patent ductus were seen six other patients were submitted to thoracotomy, without a patent ductus being found. The continuous murmur differed from the characteristic murmur of patent ductus in site or timing in four of the six patients, including one with an aorto-right-ventricular fistula, the diagnosis in the other three remaining uncertain. In the remaining two patients, however, one of whom had a coronary-right-ventricular fistula and the other a suspected aorto-pulmonary septal defect, neither the site, character, or timing of the continuous murmur distinguished the condition from patent ductus arteriosus.

We wish to express our sincere thanks to Dr. William Evans and Dr. Wallace Brigden for their help and criticism in the preparation of this paper and to Mr. Vernon Thompson and Mr. Geoffrey Flavell, who performed the operations, for their advice and encouragement. We also wish to thank Dr. L. J. Rae and the staff of the radiodiagnostic department for their help with the angiocardiogram. Thanks are also due to Mr. William Dicks for technical help.

#### REFERENCES

- Alzamora-Castro, V., Rubio W., C., and Battilana D., G. (1948). *Rev. argent. Cardiol.*, **15**, 25.  
 Baylis, J. H., and Campbell, M. (1952). *Guy's Hosp. Rep.*, **101**, 174.  
 Bonham-Carter, R. E., and Lovel, K. W. (1953). *Great Ormond St. J.*, **6**, 93.  
 — and Walker, C. H. M. (1955). *Lancet*, **268**, 272.  
 Brown, J. W., Heath, D., and Whitaker, W. (1955). *Circulation*, **12**, 819.  
 Campbell, M., and Hudson, R. (1952). *Guy's Hosp. Rep.*, **101**, 32.  
 Cosh, J. A. (1953). *Brit. Heart J.*, **15**, 423.  
 Dammann, J. F., and Sell, C. G. R. (1952). *Circulation*, **6**, 110.  
 —, Berthrong, M., and Bing, R. J. (1953). *Johns Hopk. Hosp. Bull.*, **92**, 128.  
 Davis, C., Fell, E. H., Gasul, B. M., and Dillon, R. (1956). *Arch. Surg., Chicago*, **72**, 838.  
 Evans, W. (1943). *Brit. Heart J.*, **5**, 205.  
 — (1954). *Cardiography*. Butterworth, London.  
 Gibson, G. A. (1900). *Edinb. med. J.*, **8**, 1.  
 Gilchrist, A. R. (1945). *Brit. Heart J.*, **7**, 1.  
 Gray, I. (1956). *Brit. Heart J.*, **18**, 21.  
 Gross, R. E., and Longino, L. A. (1951). *Circulation*, **3**, 125.  
 Haring, O. M., Luisada, A. A., and Gasul, B. M. (1954). *Circulation*, **10**, 501.  
 Hultgren, H., Selzer, A., Purdy, A., Holman, E., and Gerbode, F. (1953). *Circulation*, **8**, 15.  
 Johnson, R. E., Wermer, P., Kuschner, M., and Courmand, A. (1950). *Circulation*, **1**, 1293.  
 Jones, A. M., and Langley, F. A. (1949). *Brit. Heart J.*, **11**, 325.  
 Laubry, C. (1930). *Nouveau Traité de Pathologie interne*. 111. Doin, Paris.

- Leatham, A. (1951). *Brit. Heart J.*, **13**, 153.  
— and Gray, L. (1956). *Brit. Heart J.*, **18**, 193.  
— and Vogelpoel, L. (1954). *Brit. Heart J.*, **16**, 21.  
Levine, S. A., and Geremia, A. E. (1947). *Amer. J. med. Sci.*, **213**, 385.  
— (1949). *Clinical Auscultation of the Heart*. Saunders, Philadelphia and London.  
Mannheimer, E. (1950). *Arch. Mal. Cœur.*, **43**, 324.  
Mounsey, J. P. D. (1953). *Brit. Heart J.*, **15**, 135.  
Nadas, A. S., and Alimurung, M. M. (1952). *Amer. Heart J.*, **43**, 691.  
Ravin, A., and Darley, W. (1950). *Ann. intern. Med.*, **33**, 903.  
Vernant, P., Nouaille, J., Schweisguth, O., Labesse, J., Bouchard, F., Mathey, J., Binet, J. P., and Oustrières, G. O.  
(1955). *Arch. Mal. Cœur.*, **48**, 277.  
Wood, P. (1952). *Brit. med. Bull.*, **8**, 348.  
—, Magidson, O., and Wilson, P. A. O. (1954). *Brit. Heart J.*, **16**, 387.  
Ziegler, R. F. (1952). *Amer. Heart J.*, **43**, 553.