

# Subarachnoid haemorrhage of unknown aetiology

## A clinical and radiological study of 51 cases

R. D. HAYWARD

*From the Department of Neurosurgery, Atkinson Morley's Hospital, London*

**SUMMARY** A detailed clinical and radiological study of 51 patients presenting with a subarachnoid haemorrhage, for which no cause could be found, has been described. Although selection for full investigation has favoured the inclusion of younger and fitter patients, analysis of the information obtained suggests that haemorrhage could be due to: (a) aneurysms undergoing thrombosis at the time of haemorrhage, in which subsequent recanalisation will produce a low incidence of further bleeding; (b) minute (2 mm) aneurysms, destroyed at the time of haemorrhage and posing no subsequent threat.

Rupture of a berry aneurysm is the most frequent cause of subarachnoid haemorrhage (McKissock *et al.*, 1958; Sahs *et al.*, 1969). Blood can also appear in the cerebrospinal fluid after trauma or leakage of an intracerebral clot adjacent to the ventricular system or subarachnoid space. This intracerebral clot can in turn be caused by rupture of an arteriovenous malformation or by primary hypertensive haemorrhage. However, there are a significant number of patients who present with the clinical symptoms and signs of subarachnoid haemorrhage in whom no cause is ever found. Sahs *et al.* (1969) found 22% of their patients fell into this category while Walsh (1956) recorded a figure of 27% in a smaller series. It is often assumed (Walsh, 1956) that the pathogenesis of these 'negative' cases stretches across the same spectrum of pathology that underlies 'positive' cases, but that for various reasons the relevant lesion has not been revealed. The routine use of carotid and vertebral angiography together with the advent of computerised tomography (CT scanning), has given us more information with which to try to interpret the clinical findings in this interesting group of patients.

### Methods

All the patients admitted to the Neurosurgical Unit at Atkinson Morley's Hospital from February 1974 to February 1976 for investigation of sub-

arachnoid haemorrhage were reviewed. In each case the diagnosis had been made at a referring hospital on the basis of the history, clinical examination, and presence of blood stained or xanthochromic cerebrospinal fluid. In three cases there had been some initial doubt as to the significance of the CSF findings because the spinal puncture was thought to have been traumatic. However, in each instance the clinical picture was sufficiently convincing to warrant full investigation. One patient was known to be taking monoamine oxidase inhibitors at the time of her haemorrhage. No patient had a history suggestive of a previous bleeding tendency and none were taking anticoagulants. Out of a total of 592 cases of subarachnoid haemorrhage, there remained 91 in which the cause of the bleeding was unknown. Within this group there were 51 patients who had had bilateral carotid and vertebral (subclavian) angiography as well as CT scans. All scans were performed on an EMI 1000 head scanner using a 160×160 matrix. The remaining 40 patients were excluded from the study for the following reasons: (1) 20 patients had only bilateral carotid angiography and in whom investigation of the vertebrobasilar circulation was omitted, usually because of their poor neurological status or age; (2) 20 patients had satisfactory 'negative' four vessel angiography, but no CT scan; (3) eight patients were moribund on admission and died before any satisfactory investigations could be performed; and (4) in two patients subsequent review of the angiograms revealed a previously unnoticed berry aneurysm which could have been responsible for their haemorrhage.

Present address: Department of Neurosurgery, National Hospital for Nervous Diseases, Queen Square, London WC1.

Accepted 2 May 1977

It is the remaining 51 patients who form the basis of this study. The timing of their investigations ranged from day 2 to day 18 (counting the day of the haemorrhage as day 1). Thirty-one patients had arteriography and 25 patients had CT scanning performed during the first seven days.

## Results

Details of the patients' numbers, sex, age, blood pressure, and incidence of coma at the time of haemorrhage are given in Table 1. A blood pressure exceeding 160/90 mmHg on admission was taken as an arbitrary indication of hypertension as these were the figures used in previous studies of subarachnoid haemorrhage from this hospital (McKissock *et al.*, 1958). A more detailed analysis of the patients' ages is given in the Figure.

The results of four vessel angiography are given in Table 2. Three patients showed some displacement of the normal cerebral vessels without an obvious cause having been found. These have been recorded under the heading 'Mass effect'. In three patients a skull fracture was an incidental finding. All three had had a coma-producing subarachnoid haemorrhage and recent head injury was not suspected. In one case an aneurysm was seen, but was not thought to have been responsible for the patient's haemorrhage. This patient was a non-hypertensive lady aged 40 years who had a coma-producing subarachnoid haemorrhage which rendered her paraplegic. Cerebral angiography revealed a small distal left middle cerebral artery aneurysm without evidence of adjacent spasm and her CT scan was negative. Because of the possibility that the haemorrhage was due to a spinal lesion, a myelogram was performed, but this did not show a significant abnormality. It has not been routine policy to repeat angiography in our patients, but further studies were carried out in five cases for the reasons given in Table 3.

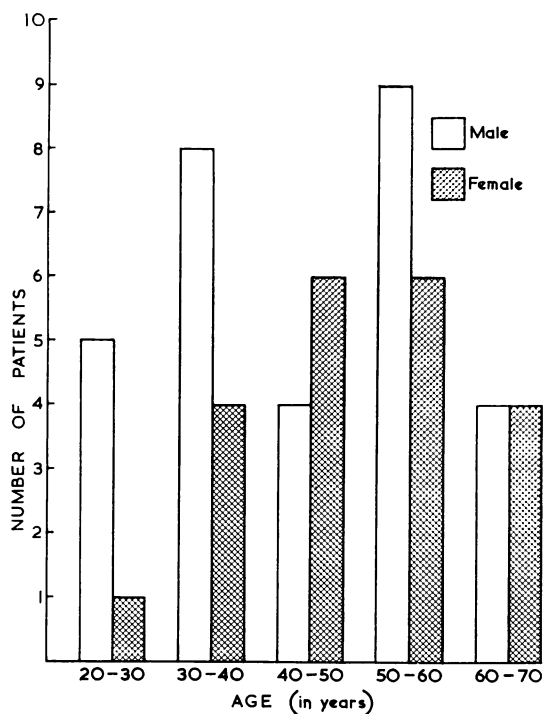


Figure Details of sex and age (per decade).

Details of the CT scan findings are given in Table 4. 'Mass effect' in this section refers to distortion of the ventricular system without an obvious density change (such as might be due to

Table 3 Details of repeat angiography performed in five patients

Number of patients	Reason for repeat study	Result
1	Angioma suspected clinically	Negative
1	Possibility of change in (inappropriate) aneurysm	No change
1	Original study inconclusive due to spasm	Negative
2	Aneurysm suspected on original study	Negative

Table 1 Details of patients

Number of patients	Sex		Average age (yr)		Blood pressure (> 160/90 mmHg)		Coma	
	Male	Female	Male	Female	Male	Female	Male	Female
51	30	21	45	51	9	4	11	9

Table 2 Results of angiography in 51 patients

Normal	Arterial spasm	Skull fracture	Mass effect	Extensive atheroma	Inappropriate aneurysm
38	4	3	3	2	1

Table 4 CAT scan findings in 51 patients

Normal	Subarachnoid blood	Hydrocephalus	Mass effect	Intracerebral haematoma	Atrophy	Large cisterna magna
36	4	4	3	2	1	1

blood clot or oedema) in the adjacent brain. These patients were not the same as the three noted to have some displacement of their cerebral vessels on angiography and all their angiograms were normal. Conversely, the three patients noted to have the angiographic displacements had normal CT scans. In all six patients the abnormalities were slight.

#### CLINICAL FINDINGS ON ADMISSION

The patients were grouped according to the grading system of Hunt and Hess (1968) as follows:

Grade 1 (alert with a little meningism)—36 cases.  
Grade 2 (alert with marked headache and meningism)—seven cases.

Grade 3 (drowsy, confused, with mild neurological signs)—eight cases.

Grade 4 (stupor, incontinence, severe neurological signs)—0 cases.

Grade 5 (deep coma)—0 cases.

#### COURSE IN HOSPITAL

Three patients deteriorated after angiography. All had been assessed as grade 1 on admission but two showed evidence of spasm on their arteriograms. Within 48 hours of the investigation there was a deterioration in their level of consciousness with the onset of focal neurological signs. Lumbar puncture showed no evidence of a new haemorrhage and they subsequently improved over a period of days on steroid therapy.

After investigations, all patients in this study were transferred back to their referring hospitals with a recommendation that they be treated with a period of six weeks bedrest (as measured from the time of their haemorrhage). In no case was there a further episode of subarachnoid haemorrhage during the patient's time in hospital.

#### SUBSEQUENT PROGRESS

Further information is available on 41 of the 51 patients after their final discharge from hospital. The periods of follow-up range from three and a half months to two and a half years. No patient has had a second subarachnoid haemorrhage. Their present clinical status, as assessed by the patients themselves, can be graded as follows: (a) returned to full activity—28 cases; (b) working, but at a reduced level (that is, lighter work, and/or shorter hours)—11 cases; (c) unable to work but

independent in all the activities of daily life—two cases; and (d) dependent and housebound—0 cases.

#### Discussion

Studies of subarachnoid haemorrhage have traditionally depended upon four methods—study of the clinical course, cerebral angiography, operative findings, and postmortem information—to discover the underlying aetiology.

The advent of CT scanning has made it possible to detect the rare cases of cerebral tumour presenting as intracranial haemorrhage. Of more importance, its accurate identification and localisation of intracerebral blood clot has now made it possible for the clinician to remove from the category of 'unknown aetiology' those cases of primary (hypertensive) intracerebral haemorrhage which have been suspected on clinical grounds, but whose angiograms do not show a typically localised mass (McKissock *et al.*, 1959). We have already shown in a previous study that differentiation of primary cerebral haemorrhage from cases due to rupture of a berry aneurysm can be made with an accuracy of 90% even in the absence of the relevant clinical information (Hayward and O'Reilly, 1976). Therefore, this study contains no cases that have the clinical and CT scan features typical of primary hypertensive haemorrhage. In the past, many of these patients have been included in the category 'subarachnoid haemorrhage of unknown aetiology', as can be seen from the figures in the cooperative study of intracranial aneurysms and subarachnoid haemorrhage (Sahs *et al.*, 1969) where the incidence of 'other causes' rose with age until, at approximately 65 years, it became the largest category responsible for all cases of subarachnoid haemorrhage. However, postmortem studies, when available, revealed that most of these patients had evidence of hypertension, atheroma and intracerebral blood clot.

The exclusion of primary intracerebral haemorrhage produces a dramatic change in the age spectrum for the patients remaining in the 'unknown aetiology' category. In fact, for both males and females, the ages are now closer to those noted in the cooperative study for ruptured berry aneurysm (Sahs *et al.*, 1969), being 50 and 55 years respectively. This approximation becomes even more striking when the figures for age and

sex are combined (Figure). The resulting preponderance of males in the younger age groups was exactly that noted in the cooperative study for ruptured aneurysm. The criteria for inclusion in the present study favour patients fit enough to undergo full investigation, and this is probably responsible for the larger number of younger patients and hence the male excess.

However, angiography has not revealed an aneurysm in any of these cases and on the CT scan there has been no evidence of blood clot in a position typically associated with aneurysmal rupture (Hayward and O'Reilly, 1976). Failure to visualise an aneurysm when the angiography has been technically satisfactory may be due to arterial spasm or to the presence of haematoma within the aneurysm itself. As it is not our general policy to repeat the angiograms, further information must come from study of the clinical presentation, course in hospital, and subsequent follow-up. The incidence of coma at the time of haemorrhage (40%) is close to the 50% found in another series of subarachnoid haemorrhage due to ruptured berry aneurysm from this hospital (McKissock *et al.*, 1958). The clinical condition noted on admission reflects the selection of patients by their fitness to undergo full angiographic studies. Thus only four patients showed radiological evidence of vasospasm compared to the 38% noted in a large series due to rupture of a confirmed berry aneurysm (Griffith *et al.*, 1972). Similarly, only three patients, none of whom were noted to have significant neurological abnormalities at the time of admission, showed evidence of subsequent deterioration in level of consciousness together with the focal neurological abnormalities that could be attributed to vasospasm. Again, this low figure is probably due to the factors governing admission to the study.

Information from the CT scans suggests that the presence of detectable blood in the subarachnoid space of patients in this study is less than that noted in other series of haemorrhage due to ruptured aneurysm (Kendall *et al.*, 1976). The incidence of hydrocephalus is also very low compared with the 34% recorded from the arteriograms in the study of Galera and Greitz (1970). However, these figures for hydrocephalus and (visible) subarachnoid blood may reflect the fact that only 25 patients had their scans performed during the first seven days after the haemorrhage.

All the patients in this series were treated with a period of six weeks hospital bedrest. If all the haemorrhages had been from undetected berry aneurysms, it would be expected that their subsequent clinical course would mirror that of the

patients treated conservatively in the trials of surgery versus conservative therapy that have already been reported from this hospital (Walsh, 1966). Thus approximately 50% (or 25 patients) should have bled again during the first two months. This did not occur on a single occasion, and there is no evidence that a patient received treatment at a hospital out of our usual catchment area for a further bleed.

Haemorrhage from an arteriovenous malformation produces evidence of haematoma on the CT scan in nearly 100% of cases (Hayward, 1976). The two patients in this series who had evidence of an intracerebral haematoma situated in the cerebellar vermis, both had symptoms and signs of brain stem dysfunction. Although arteriography revealed no arteriovenous malformation, it seems reasonable to speculate that a small lesion destroyed or thrombosed at the time of haemorrhage was responsible for their presentation. Microangiomas have been well described (Russell, 1954), but they are only found after scrupulous study of the walls of intracerebral haematomas, which means that they could not have been responsible for more than two of the haemorrhages in this series. Intracerebral blood clots certainly pass through a stage when their CT scan density becomes equal to that of the surrounding brain, but this does not occur during the first week, and the haematoma itself would cause displacement of the local ventricular system on the CT scan and of the adjacent arteries on the arteriogram.

By approximating clinical features of the patients in this series to various aetiologies, it is possible to categorise some of them in the following way.

1. Mistaken diagnosis—three cases where there had been doubt about the lumbar puncture at the referring hospital.
2. Trauma—three cases (where skull fractures were noted at the time of angiography, although head injury was not a feature of their admission).
3. Unseen angioma—two cases (those with small vermis haematomas).
4. Monoamine oxidase inhibitors—one case.

There remain 42 cases who are impossible to categorise. Because of their prognosis there are no postmortem studies to provide further information. What deductions can be drawn from the figures discussed above about the origin of their haemorrhages? Their clinical presentation, sex ratio, and immediate course in hospital are exactly those found after rupture of a berry aneurysm in a younger age group. However, their course after investigation is radically different. Patients with

a known, but untreated aneurysm can expect a high incidence of further bleeding within the six weeks after their initial haemorrhage. Therefore, if an aneurysm was the responsible lesion, it is now behaving as if it had been successfully 'treated' at the time of haemorrhage. The theory that the majority of cases of subarachnoid haemorrhage of unknown aetiology were due to aneurysms thrombosed at the time of haemorrhage was advanced by Walton in 1956 after reviewing the radiological, clinical and pathological information available at that time. After thrombosis the incidence of early rebleeding would be low, and only if subsequent 'recanalisation' occurred would the aneurysm present its further threat of haemorrhage in the years to come. This figure has been calculated at a rate of 3.5% a year by Winn *et al.* (1977) and only a longer follow-up of this series would provide information with which to judge the accuracy of this prediction.

Another possibility is that complete destruction of an aneurysm could have occurred at the time of haemorrhage. This implies that the aneurysm was small and that rupture would involve a relatively large area of the aneurysmal surface. Small aneurysms (less than 2 mm greatest diameter) have been described by Hassler (1961). In a necropsy series of 240 cases of patients dying without subarachnoid haemorrhage he found 32 minute aneurysms, in sites typical of the larger berry aneurysms, in 27 individuals. During 11 necropsies where death had been associated with subarachnoid haemorrhage, he found that minute aneurysms were responsible in two cases. However, in each, the major bleeding was intracerebral and the aneurysms are like those described on the small intracerebral vessels in hypertensive patients by Ross Russell (1963) and Cole and Yates (1967) rather than small berry aneurysms. Certainly, the necropsy studies of Crawford (1959) give no support to the theory that minute aneurysms of the major cerebral vessels can be responsible for subarachnoid haemorrhage.

However, in favour of these small aneurysms being responsible must be their relative frequency. Hassler found only one conventional berry aneurysm in his large postmortem series compared to 32 minute aneurysms. An individual aneurysm which was destroyed at the time of rupture would pose no further threat of bleeding and a longer follow-up study would be needed to refute the theory that they were causing 'subarachnoid haemorrhage of unknown aetiology'.

This study also emphasises the good prognosis to be expected in patients with subarachnoid haemorrhage when no cause for the bleeding can be

demonstrated. In the 337 cases where it was possible to identify the underlying aetiology, McKissock *et al.* (1958) had 139 deaths, and of the surviving 141 patients with aneurysms, 16 were recorded as being totally disabled and dependent. In the present series, no patient died or had a further haemorrhage and only two have been rendered unfit for work.

## References

- Cole, F. M., and Yates, P. O. (1967). The occurrence and significance of intracerebral microaneurysms. *Journal of Pathology and Bacteriology*, **93**, 393–411.
- Crawford, T. (1959). Some observations on the pathogenesis and natural history of intracranial aneurysms. *Journal of Neurology, Neurosurgery, and Psychiatry*, **22**, 259–266.
- Galera, R. G., and Greitz, T. (1970). Hydrocephalus in the adult secondary to the rupture of intracranial aneurysms. *Journal of Neurosurgery*, **32**, 634–641.
- Griffith, H. B., Cummins, B. H., and Thomson, J. L. G. (1972). Cerebral arterial spasm and hydrocephalus in leaking arterial aneurysms. *Neuroradiology*, **4**, 212–214.
- Hassler, O. (1961). Morphological studies on the large cerebral arteries; with reference to the aetiology of subarachnoid haemorrhage. *Acta Psychiatrica et Neurologica Scandinavica*, **36**, Supplement 154, 1–145.
- Hayward, R. D. (1976). Intracranial arterio-venous malformations: observations after experience with computerised tomography. *Journal of Neurology, Neurosurgery, and Psychiatry*, **39**, 1027–1033.
- Hayward, R. D., and O'Reilly, G. V. A. (1976). Intracerebral haemorrhage. *Lancet*, **1**, 1–4.
- Hunt, W. E., and Hess, R. M. (1968). Surgical risk as related to time of intervention in the repair of intracranial aneurysms. *Journal of Neurosurgery*, **28**, 14–20.
- Kendall, B. E., Lee, B. C. P., and Claveria, E. (1976). Computerised tomography and angiography in subarachnoid haemorrhage. *British Journal of Radiology*, **49**, 483–501.
- McKissock, W., Paine, K. W. E., and Walsh, L. (1958). Further observations on subarachnoid haemorrhage. *Journal of Neurology, Neurosurgery, and Psychiatry*, **21**, 239–248.
- McKissock, W., Richardson, A. E., and Walsh, L. (1959). Primary intracerebral haemorrhage. *Lancet*, **2**, 683–686.
- Ross Russell, R. W. (1963). Observations on intracerebral aneurysms. *Brain*, **86**, 425–442.
- Russell, D. S. (1954). The pathology of spontaneous intracranial haemorrhage. *Proceedings of the Royal Society of Medicine*, **47**, 689–693.
- Sahs, A. L., Perret, G. E., Locksley, H. B., and Nishioka, H. (1969). *Intracranial Aneurysms and Subarachnoid Hemorrhage*. J. B. Lippincott Company: Philadelphia and Toronto.

- Walsh, L. (1956). Subarachnoid haemorrhage. *Acta Radiologica*, **46**, 321–325.
- Walsh, L. (1966). Experience in the conservative and surgical treatment of ruptured intracranial aneurysms. In *Cerebrovascular Disease*, Association for Research in Nervous and Mental Disease. Volume XLI, Chapter IX. Williams and Wilkins: Baltimore.
- Walton, J. (1956). *Subarachnoid Haemorrhage*. E. and S. Livingstone Limited: Edinburgh and London.
- Winn, H. R., Richardson, A. E., and Jane, J. A. (1977). The long-term prognosis in untreated cerebral aneurysms. 1. The incidence of late haemorrhage in cerebral aneurysm: a 10-year evaluation of 364 patients. *Annals of Neurology*, **1**, 358–370.