

Median–ulnar nerve communications and carpal tunnel syndrome

LUDWIG GUTMANN

From the Department of Neurology, West Virginia University, Morgantown, West Virginia, USA

SUMMARY Carpal tunnel syndrome in the presence of anomalous median to ulnar nerve communications in the forearm produces a characteristic change in motor conduction studies. Median nerve stimulation at the elbow evokes a thenar muscle action potential (MAP) with an initial positive deflection not seen on stimulation at the wrist. In 63 patients this change occurred in 16 (25%) and is a useful additional criterion in the diagnosis of carpal tunnel syndrome. The initial positive deflection is due to the volume-conducted MAP from the first dorsal interosseous and some thenar muscles whose motor point lies some distance from the recording electrode over abductor pollicis brevis. The first dorsal interosseous and thenar MAPs resulting from elbow stimulation of those median nerve axons crossing to ulnar nerve in forearm, are generated before that from thenar muscles supplied by the axons going through the carpal tunnel.

Anomalous innervations of muscles in the extremities occur commonly and involve the median, ulnar, and peroneal nerves. It has been estimated that in the arms of 15–31% of people, motor axons descend in the median nerve which, in the forearm, cross over to the ulnar nerve, and ultimately innervate intrinsic hand muscles (Fig. 1) normally supplied by the ulnar nerve (Mannerfelt, 1966; Wilbourn and Lambert, 1976). This anomaly gives rise to changes in motor conduction studies identifying its presence. When this common anomaly occurs in association with the often seen carpal tunnel syndrome additional changes may occur in evoked muscle potentials (Lambert, 1962; Iyer and Fenichel, 1976). The most frequent of these has received very little attention and yet, in our laboratory, we view it as a useful additional criterion in the diagnosis of carpal tunnel syndrome in the presence of this anomaly. It is the purpose of this study to describe this change, its frequency, and the evidence that it is due to median–ulnar nerve communications.

Patients and methods

The study was carried out in two phases. In the first, the data from 63 consecutive patients with bilateral carpal tunnel syndrome were evaluated.

The diagnosis of carpal tunnel syndrome was made on the basis of a typical clinical history and accepted electrophysiological findings of prolonged distal motor and sensory latencies (or absent sensory nerve action potentials) in the median nerve and normal distal latencies in the ulnar nerve (Thomas *et al.*, 1967). Median and ulnar nerve conduction studies were performed in the conventional way, recording from thenar and hypothenar muscles respectively in the case of motor studies (Gutmann, 1969). Care was taken to limit the supramaximal nerve stimulation to the nerve being studied and the recording electrode was placed over the motor point of each muscle. Those patients with a thenar muscle action potential (MAP) preceded by a positive deflection on stimulating the median nerve at the elbow, but not the wrist, were identified.

In the second phase of the study, median and ulnar nerve conduction studies were performed in seven patients with this latter finding recording from thenar, hypothenar, and first dorsal interosseous muscles in the case of each nerve. Supramaximal nerve stimulation was again carefully performed to avoid stimulation of more than one nerve at a time. These studies were also performed on nine 'control' patients with carpal tunnel syndrome but without the initial positive deflection of thenar MAP on median nerve stimulation at elbow or wrist.

MEDIAN-ULNAR ANASTOMOSIS

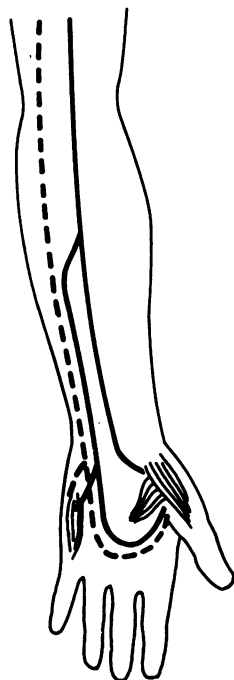

Fig. 1 Diagrammatic representation of median nerve axons crossing to the ulnar nerve in the forearm and supplying hypothenar, first dorsal interosseous, adductor pollicis, and thenar muscles (--- ulnar, — median).

Results

In 16 (25%) of the 63 consecutive patients with bilateral carpal tunnel syndrome, a thenar MAP with an initial positive deflection was evoked on stimulating the median nerve at the elbow but not at the wrist (Fig. 2). This change was present in 25 of 126 limbs (20%). In nine patients (56%) it was bilateral and seven (44%) unilateral.

In the seven patients (in phase 2 of the study) with thenar MAP preceded by a positive deflection on median nerve stimulation at the elbow but not at the wrist, this change was present bilaterally in six and unilaterally in one. In these 13 involved extremities the supramaximal stimulation of the median nerve at the elbow evoked an MAP from thenar, hypothenar, and first dorsal interosseous muscles (Fig. 3). Thenar MAP on median nerve elbow stimulation was 0.5–14.0 mV in amplitude. On median nerve stimulation at the wrist it was smaller in eight median nerves (28–

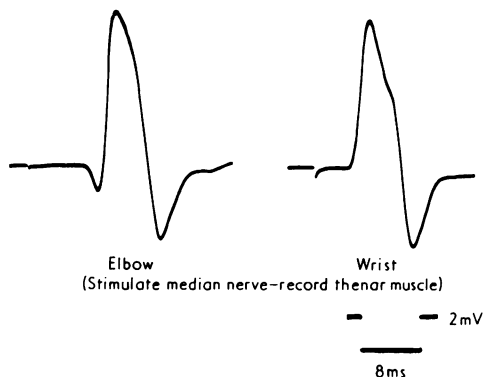


Fig. 2 Thenar MAP after median nerve stimulation at elbow and wrist in patient with carpal tunnel syndrome and median-ulnar communications. The MAP evoked on elbow stimulation is larger and is preceded by an initial positive deflection.

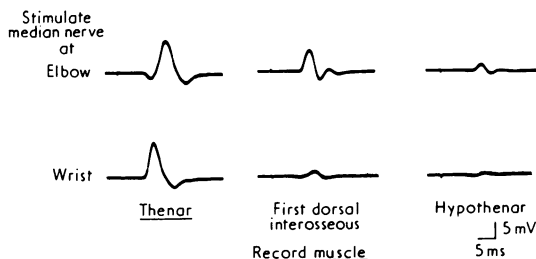


Fig. 3 Muscle action potential evoked from several muscles on median nerve stimulation at elbow and wrist in patient with carpal tunnel syndrome and median-ulnar communications. The thenar MAP on elbow stimulation is preceded by characteristic positive deflection. Stimulation at the elbow evoked a MAP from first dorsal interosseous and hypothenar muscles. Wrist stimulation evoked a very small MAP which, by virtue of the preceding positive deflection, probably arose from the thenar muscle.

86% of the amplitude compared with elbow stimulation). It was normal in five median nerves (100–120%). The normal range is 90–120%. In one case, with marked thenar atrophy, no thenar MAP was evoked on median nerve stimulation at the wrist while the thenar MAP on median nerve stimulation at the elbow was 0.5 mV.

Hypothenar MAPs on median nerve stimulation at the elbow were 0.5–5.5 mV. No hypothenar MAPs were evoked on stimulating any of the 13 median nerves at the wrist.

First dorsal interosseous MAPs on median nerve stimulation at the elbow were 2.0–12.0 mV. No first dorsal interosseous MAPs were evoked on stimulating eight median nerves at the wrist.

In the remaining five, a small MAP was evoked but this was 3.0–5.0 mV smaller than that evoked on elbow stimulation (Table).

Stimulation of the ulnar nerve evoked MAPs, all of which were larger on wrist than elbow stimulation (Fig. 4). The first dorsal interosseous MAPs were 3.0–12.0 mV larger on wrist stimulation; the hypothenar MAP 0.5–4.5 mV larger; and thenar MAPs 1.0–8.0 mV larger. The differences in amplitude were comparable to that seen in the median nerve conduction studies.

In the nine patients with carpal tunnel syndrome who did not have a preceding positive deflection of the thenar MAP on elbow stimulation, the carpal tunnel syndrome was bilateral in five and unilateral in three. Supramaximal median nerve stimulation at the wrist in these 13 extremities evoked a thenar MAP 0–0.5 mV larger than at the elbow. A small first dorsal interosseous MAP (0.5–3.0 mV) was evoked on both elbow and wrist stimulation of each median nerve but the MAPs from these two sites never varied more than 0.5 mV in amplitude. No hypothenar MAP was evoked from any median nerves stimulated at elbow or wrist. Ulnar nerves showed no pertinent differences in hypothenar, first dorsal interosseous and thenar MAPs on elbow and wrist stimulation.

Discussion

Because of increased synchronisation, a MAP tends to be slightly higher in amplitude (and shorter in duration) when a nerve is stimulated supramaximally distally (wrist) as compared with more proximally (elbow). In phase 2 of this study the thenar MAP was larger in eight of 13 median nerves on elbow stimulation. The hypothenar MAP was present only on elbow stimulation. The

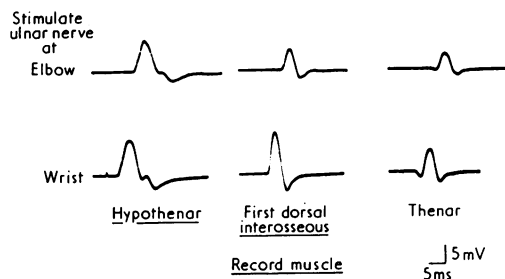


Fig. 4 Muscle action potential from several muscles on ulnar nerve stimulation at elbow and wrist in a patient with carpal tunnel syndrome and median–ulnar communications. Hypothenar and first dorsal interosseous MAPs are larger on stimulation at wrist than elbow. Thenar MAP is slightly larger on wrist stimulation.

first dorsal interosseous MAP was present only on elbow stimulation in eight of 13 median nerves and was much larger in the other five on elbow stimulation (Fig. 3).

These findings indicate that in each of the 13 extremities a pool of axons to intrinsic hand muscles is being stimulated in the median nerve at the elbow but not at the wrist. This must be due to median–ulnar nerve communications below the elbow since we were careful to exclude improper stimulating techniques. This anomalous innervation occurred to 61% of thenar muscles. In one extremity this was the only innervation to the thenar muscle group because of complete loss of median axons at the wrist resulting from the carpal tunnel syndrome. The evidence indicates that this anomaly involved the hypothenar and first dorsal interosseous muscle, in all 13 extremities. In the case of the latter muscle a relatively small MAP was evoked on median nerve stimulation at the wrist in five extremities, while

Table Muscle action potential evoked by median nerve stimulation

		Thenar		Hypothenar		First dorsal interosseous	
		elbow (mV)	wrist (mV)	elbow (mV)	wrist (mV)	elbow (mV)	wrist (mV)
Case 1	R	10.5	9.0	2.0	0	3.0	0
	L	10.0	5.0	2.0	0	2.0	0
Case 2	R	1.5	1.0	3.0	0	8.0	0
	L	0.5	0	0.5	0	2.0	0
Case 3	R	5.0	3.0	1.0	0	4.0	0
	L	9.0	2.5	5.5	0	6.0	0
Case 4	R	9.0	9.5	2.5	0	5.0	2.0
	L	2.0	2.5	2.0	0	4.0	0.5
Case 5	R	8.5	8.5	2.0	0	6.0	1.0
	L	4.0	4.0	1.5	0	6.0	0
Case 6	R	4.0	4.0	1.5	0	6.0	0
	L	7.0	5.5	1.5	0	4.0	1.0
Case 7	R	6.5	6.5	1.5	0	4.0	1.0
	L	14.0	11.5	2.0	0	12.0	0

that on elbow stimulation was much larger. The small first dorsal interosseous MAPs on median nerve wrist stimulation were interpreted as being volume-conducted potentials from adjacent thenar muscles. Similar small volume-conducted MAPs were evoked from first dorsal interosseous muscles on median nerve stimulation at wrist in the nine 'control' patients with carpal tunnel syndrome. The MAPs evoked on elbow stimulation in these latter patients were similar in amplitude (within 0.5 mV) showing no evidence of median-ulnar communications.

The larger first dorsal interosseous, thenar, and hypothenar MAPs on stimulating the ulnar nerve at the wrist, as compared with the elbow, further indicate that the anomalous axons are now located in the ulnar nerve at the wrist (Fig. 4). These findings represent the major evidence that in each of these extremities there are median-ulnar nerve communications in the forearm (Fig. 1).

The seven patients with carpal tunnel syndrome, all showing evidence of median-ulnar communications in the forearm, investigated in phase 2 of the study were selected because the thenar MAP, in phase 1, was preceded by a positive deflection when the median nerve was stimulated at the elbow but not at the wrist. When this latter change was not present in patients with carpal tunnel syndrome, evidence of median-ulnar communications in the forearm did not occur. The results of phase 2 of the study suggest that the thenar MAP preceded by a positive deflection on elbow stimulation of the median nerve only, in the presence of a carpal tunnel syndrome (Fig. 2), is indicative of median-ulnar communications. Further, we have not seen this finding except in patients with this anomaly and the carpal tunnel syndrome.

This finding in phase 1 occurs because conduction in the median nerve axons going through the carpal tunnel, and innervating thenar muscles, is slower than in those median nerve axons crossing to the ulnar nerve and supplying first dorsal interosseous, adductor pollicis, abductor digiti minimi, and flexor pollicis brevis muscles. The MAP from the latter muscles, on median nerve stimulation at the elbow, is generated before that from thenar muscles innervated by median axons going through the carpal tunnel. The earlier appearing MAP is incorporated into the overall compound MAP but, since it originates at some distance from the recording electrode, produces an initial positive deflection. This initial positive deflection is due to the volume conduction effect and is not present when the median nerve is

stimulated at the wrist, below the level of the anomalous interchange. This indicates clearly that the positive deflection on median nerve stimulation at the elbow is not due to incorrect placement of the recording electrode.

Kimura (1976) and Iyer and Fenichel (1976) reported cases of carpal tunnel syndrome in whom there were erroneously normal proximal (elbow) motor latencies in the median nerve with prolongation of distal motor latencies. The near normal proximal latency is due to the median-ulnar communications and resulted in a spuriously fast calculated conduction velocity. In phase 1 of our series this occurred in only one patient and is, therefore, a less useful finding.

The occurrence of the anomaly in 25% of our patients (20% of limbs) with carpal tunnel syndrome in phase 1 of our study is similar to the incidence of 15–31% in normal individuals reported in the literature (Mannerfelt, 1966; Wilbourn and Lambert, 1976). The anomalous axons were reported by Wilbourn and Lambert to innervate the first dorsal interosseous much more commonly than the hypothenar and thenar muscles, occurring in the first dorsal interosseous 95% of the time, hypothenar 41%, and thenar 14%. This differs from the 13 extremities studied in phase 2 of our study. Anomalous innervation was present to hypothenar and first dorsal interosseous muscles 100% of the time and to thenar muscles 61%.

Since the MAP arising from the first dorsal interosseous muscle is easily recorded by recording electrodes over the thenar muscle, the anomaly produces its most characteristic effect in almost all cases of carpal tunnel syndrome when the former is present. This certainly accounts for the high incidence of the thenar MAP with an initial positive deflection on proximal but not distal medial nerve stimulation. We view this finding, seen in 25% of our patients, as an additional and useful criterion in confirming the diagnosis of carpal tunnel syndrome.

References

- Gutmann, L. (1969). The intramuscular nerve action potential. *Journal of Neurology, Neurosurgery, and Psychiatry*, **32**, 193–196.
- Iyer, V., and Fenichel, G. M. (1976). Normal median nerve proximal latency in carpal tunnel syndrome: a clue to coexisting Martin-Gruber anastomosis. *Journal of Neurology, Neurosurgery, and Psychiatry*, **39**, 449–452.
- Kimura, J. (1976). Collision technique. *Neurology (Minneapolis)*, **26**, 680–682.
- Lambert, E. H. (1962). Diagnostic value of electrical

- stimulation of motor nerves. *Electroencephalography and Clinical Neurophysiology*, **22**, 9–16.
- Mannerfelt, L. (1966). Studies on the hand in ulnar nerve paralysis. A clinical experimental investigation in normal and anomalous innervation. *Acta Orthopaedica Scandinavica*, **87**, 23–142.
- Thomas, J. E., Lambert, E. H., and Cseuz, K. A. (1967). Electrodiagnostic aspects of the carpal tunnel syndrome. *Archives of Neurology (Chicago)*, **16**, 635–641.
- Wilbourn, A. J., and Lambert, E. H. (1976). The forearm median-to-ulnar nerve communication; electrodiagnostic aspects. *Neurology (Minneapolis)*, **26**, 368.