

# Hemifacial spasm: treatment by posterior fossa surgery

G. C. A. FABINYI AND C. B. T. ADAMS

*From the Department of Neurosurgery, Radcliffe Infirmary, Oxford*

**SUMMARY** Nine cases of hemifacial spasm have been treated by posterior fossa exploration without mortality or significant morbidity. In only three was definite pathology found, but the hemifacial spasm was abolished in eight patients and markedly diminished in the remaining patient. The condition has recurred in one patient. Microsurgical techniques make the operation safe and accurate. We suggest that this procedure is the best approach for hemifacial spasm requiring treatment. Where no definite pathology is found, the effectiveness of the procedure is probably due to fibrosis and hence mild trauma to the facial nerve induced by the sponge wrapped around the nerve.

Hemifacial spasm is a distressing, common, and well-defined condition which is difficult to treat. It is an involuntary unilateral spasm of the muscles supplied by the facial nerve and is intermittent and usually worsened by fatigue or emotional upsets. It most often occurs in middle-aged women and tends to be gradually progressive in both intensity and frequency of attacks, although in some cases remissions of varying times may be seen. With this progression there is an associated mild weakness of the facial muscles, but the condition itself is rarely associated with other neurological disorders. It may be seen with trigeminal neuralgia (Campbell and Keedy, 1947), and the combination of trigeminal neuralgia and facial hemispasm is sometimes called tic convulsif (Cushing, 1920). Hemifacial spasm should be differentiated from facial myokymia (Matthews, 1966) and other nervous tics or abnormal facial movements which have been described and classified (Harrison, 1976) but do not resemble true hemifacial spasm, which is quite characteristic.

The difficulty in treating hemifacial spasm is reflected in the many surgical approaches (Scoville, 1969b; Potter, 1972; Harrison, 1976) described to deal with it. As yet no simple operation or medication has been devised that will relieve the distressing spasm without the penalty of facial weakness or possible return of the spasm after a varying length of time.

Address for reprint requests: Mr C. B. T. Adams, Department of Neurosurgery, Radcliffe Infirmary, Oxford OX2 6HE.

Accepted 30 March 1978

## **Patients and methods**

In the last two years we have treated nine patients, seven females and two males. The ages ranged from 40–76 years with a mean of 54 years. In each case the diagnosis has been made on clinical grounds. Tomography of the petrous bones was performed in the first six patients but no case showed any abnormality. In one case a computer tomograph scan was performed in a patient with both trigeminal neuralgia and hemifacial spasm who was shown to have a meningioma of the petrous bone (Fig. 1). We have not used electromyography in the diagnosis or assessment of these patients. In four cases previous surgery on the peripheral facial nerve had been performed. This was with success of varying duration, but in each case the spasm returned to its initial severity. Two patients had had snaring of the facial nerve by wire at the stylomastoid foramen while two had had partial extracranial division of this nerve.

## **OPERATIVE TECHNIQUE**

The operative approach was via a small suboccipital craniectomy through a curved retromastoid skin incision. Bony removal was extended to the angle between the sigmoid and transverse sinuses. The dura mater was opened in a cruciate fashion, the cerebellum exposed to reveal the subarachnoid cistern which was opened, and CSF sucked out. The cerebellum was gently retracted, although in older patients it hardly required any retraction. The eighth nerve was identified passing to the

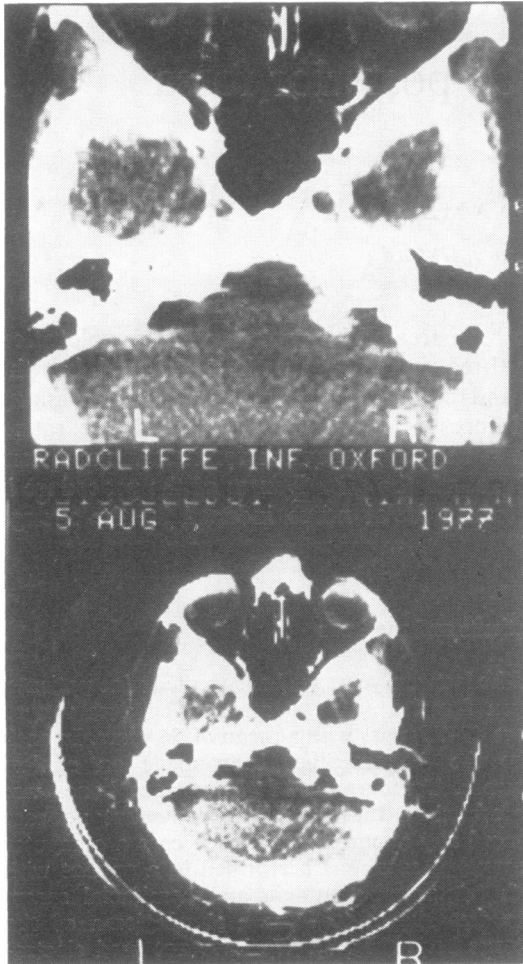


Fig. 1 CT scan to show meningioma arising from the right cerebellopontine angle.

internal acoustic meatus. The arachnoid mater was cut around this, and the seventh nerve and nervous intermedius exposed by gently retracting the eighth nerve. The flocculus of cerebellum was retracted to reveal the choroid plexus of the foramen of Luschka and the vein of the lateral recess passing immediately behind the eighth nerve as it entered the brainstem. Note was taken of the arteries in relation to the seventh and eighth nerves. These were very variable but were usually the anterior inferior cerebellar artery and its branches but occasionally the vertebral artery itself or the posterior inferior cerebellar artery looped against these nerves. Vessels—arteries or veins—frequently lay against the seventh nerve but were not considered pathological unless indenting

(causing an obvious groove in the nerve when the artery was separated from the nerve) or splitting the nerve.

Where there was no evidence of any pathology the seventh nerve was dissected free and a small triangular piece of nonabsorbable (Ivalon) sponge was introduced between the eighth and seventh nerves and then wrapped around the seventh nerve. After haemostasis a tight dural closure was performed and the wound closed with multiple layers of silk.

A possible cause was found in three cases. In one case a small branch of the anterior inferior cerebellar artery was found splitting the facial nerve into two unequal parts. This was treated by division of the smaller bundle of nerve fibres and separation of the artery away from the remaining nerve (Fig. 2). The patient with trigeminal neuralgia and hemifacial spasm, caused by a meningioma arising from the apex of the petrous bone, was treated by removal of the tumour alone. A prominent vertebral artery impinged on the nerve in the third case and a piece of sponge was interposed between the nerve and vessel. The average operating time has been one to two hours and in each case has been performed under general anaesthesia. We consider the operative microscope an essential adjunct to the safe and accurate performance of this procedure.

### Results (Table)

Most patients left hospital by the tenth postoperative day. There was no mortality. Morbidity was due to damage of the seventh and eighth nerves except in the patient with a petrous meningioma (age 76 years) who had transient postoperative confusion. Partial deafness was seen in five patients. In one patient the deafness already existed and was unchanged after operation. In none of the other four was it of clinical significance. A temporary conductive deafness occurred in three of these four, probably because of small amounts of blood entering the middle ear via mastoid air cells. A nerve deafness and vertigo was a transient problem in one patient, and another patient had postoperative vomiting for five days. There has been no episode of CSF leakage via the wound or middle ear. Facial weakness was present in two patients before operation and in the one with severe preoperative weakness it was worse afterwards. Temporary mild weakness occurred after operation in one other patient.

Follow-up of these patients has extended from three to 22 months. In each case there has been diminution of the hemifacial spasm. On two oc-

Table Summary of findings in nine cases of hemifacial spasm treated by posterior fossa exploration

Patient number	Unit number	Age (yr)	Sex	Date of operation	Operative findings	Complications	Result
1	39078	57	F	11/2/76	Prominent vertebral artery compressing facial nerve	Temporary vertigo and minimal facial weakness	No spasm
2	39143	76	F	29/3/76	No apparent abnormality	Increased pre-existing facial weakness, mild nerve deafness (temporary)	No spasm
3	37476	55	F	12/4/76	No apparent abnormality	None	Immediate relief—mild asymptomatic spasm returned after 18 months
4	37943	38	M	14/9/76	Artery found splitting facial nerve	None	Spasm ceased completely after several weeks—has not recurred
5	39976	41	F	30/11/76	No apparent abnormality	Temporary mild conductive deafness	No spasm
6	38339	40	F	12/5/76	No apparent abnormality	Temporary mild conductive deafness	Spasm ceased after several weeks
7	40815	42	F	1/8/77	No apparent abnormality	Temporary nausea and mild conductive deafness	Occasional spasm—“80% improvement”
8	36685	59	F	8/8/77	No apparent abnormality	None	No spasm
9	40859	76	M	11/8/77	Meningioma of petrous temporal compressing trigeminal and facial nerves	Temporary confusion. Preoperative partial nerve deafness unchanged	Both spasm and trigeminal neuralgia relieved

casions the spasm has taken up to four weeks after operation to disappear but in four patients the relief was immediate and complete. In one case there has been recurrence of occasional twitching some 18 months after operation but this is not particularly worrisome to the patient. Another patient still experiences mild twitching three months after operation but is no longer embarrassed by it. There has been no difference in the results between those patients with pathology and those in whom there were no apparent abnormalities.

## Discussion

The cause of hemifacial spasm is disputed. Rare causes such as facial neurinomas, cerebello-pontine angle tumours, basilar impression, and various vascular lesions, such as a basilar artery aneurysm or redundant arterial loops, have been described in association with hemifacial spasm (Ehni and Woltman 1945). It is probable that the benign nature of this condition has discouraged many clinicians from extensive or invasive neuro-radiological procedures. The treatment is also problematical. Until recently the treatment has been deliberately to traumatise the peripheral part of the facial nerve. Alcohol injection, partial nerve section, or facio-hypoglossal or facio-accessory anastomoses have all been recommended (Harrison, 1976). These procedures all produce a profound, if temporary, facial weakness. As the facial weakness recovers, usually after 12–24 months, the spasm often recurs. Our experience with partial

nerve section at the stylomastoid foramen has been extremely unsatisfactory for these reasons, and made us consider exploration of the posterior fossa.

Whether this nonlethal and, to some, trivial condition should be treated at all is a matter for judgment. Only the patient can say if the social or professional embarrassment of the condition warrants surgical intervention, although the frequent eye closure during car driving may be an important factor in deciding whether or not to ask for treatment. Clearly the effectiveness, safety, and side effects of any treatment need to be considered when making a decision.

The first series of cases treated by posterior fossa exploration was described by Gardner and Sava (1962) who found 14 of 19 patients had compression of the facial nerve by either an arteriovenous malformation, a cirroid aneurysm of the basilar artery, or a redundant anterior inferior cerebellar artery or internal auditory artery. Others have shown that when the facial nerve is explored in its intracranial part, compressing vascular structures appeared in a consistently high percentage of patients, (Neagoy and Dohn, 1974; Janetta *et al.*, 1977; Petty and Southby, 1977). Janetta (1976) considers that compression distortion of the facial nerve at the brainstem, at the point where the myelin changes from oligodendroglia to Schwann cells, is the cause of hemifacial spasm. What exactly constitutes a pathologically placed vessel is open to varying interpretations (Morley, 1976).

Various complications have been reported after

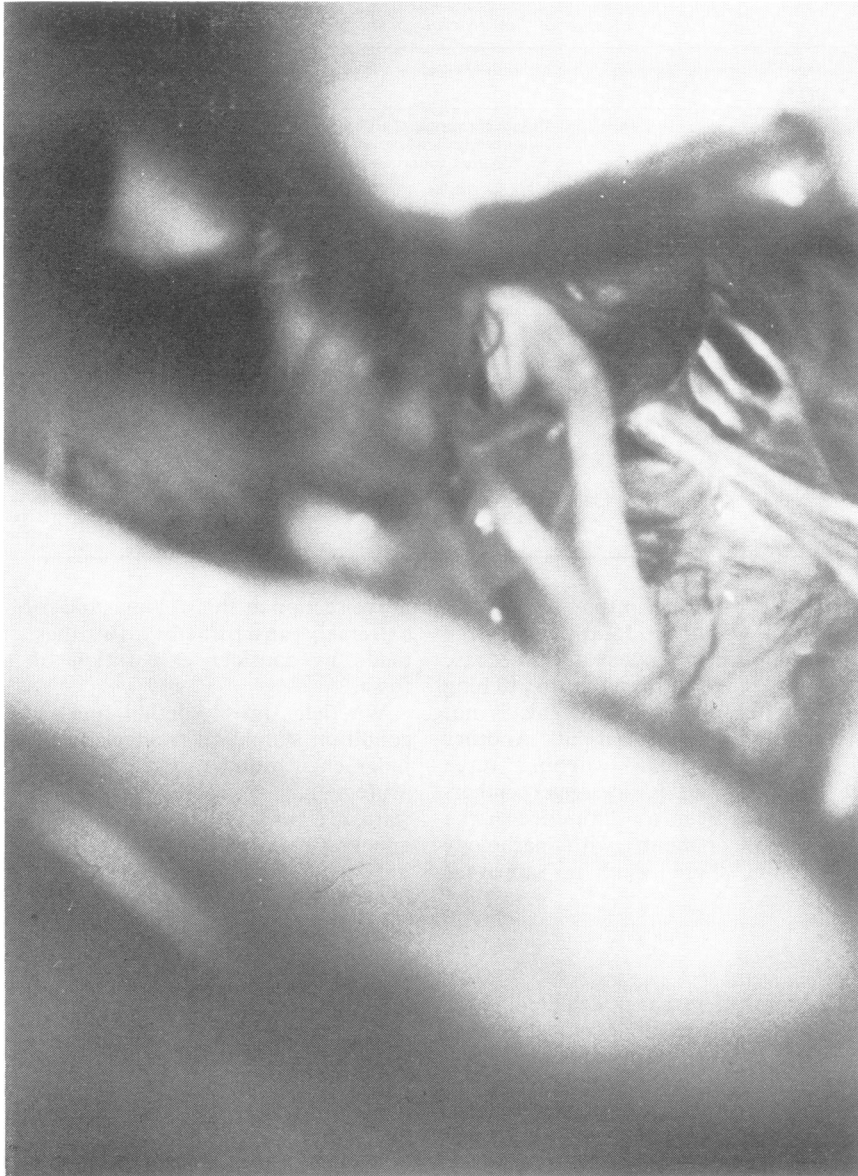

Fig. 2 *Eighth nerve retracted by the sucker to show the facial nerve split into two by the anterior inferior cerebellar artery.*

this operation (Scoville, 1969a; Janetta, 1976). In particular deafness of a varying degree is common, and it should certainly be explained to the patient before operation that such a complication is possible. Contralateral deafness may be a contraindication to this procedure.

The results of the posterior fossa approach with decompression of the facial nerve (usually by interposing sponge or gelatin foam between it and

the offending vessel) have so far appeared excellent. Janetta reports excellent to good results in 40 of 45 patients so treated, with follow-up extending up to seven years (Janetta *et al.*, 1977). It is known that this condition has a tendency to recur even several years after nerve division or other surgery. For this reason long-term studies will be needed to ascertain definitively the place of posterior fossa exploration. Previous authors have

suggested that the good effect of the operation is due to the separation of the compressing vessel from the nerve by interposing a prosthesis of sponge or gelatin foam. However, in most of our cases, although we could see vessels near the facial nerve, we could not convince ourselves that they were pathological. In such cases the operation was just as effective, and we suggest that where compression is of doubtful significance, the relief of spasm is brought about by a mild degree of trauma to the nerve at its exit from the brainstem by the fibrosis induced by the nonabsorbable sponge. The delay in complete abolition of the spasm for several weeks, which was noted in two patients, supports the concept that it is the fibrosis around the nerve that produces the cessation of spasm.

We thank various neurological colleagues for entrusting their patients to us.

#### References

- Campbell, E., and Keedy, C. (1947). Hemifacial spasm: a note on the aetiology in two cases. *Journal of Neurosurgery*, **4**, 342-347.
- Cushing, H. (1920). The major trigeminal neuralgias and their surgical treatment based on experiences with three hundred and thirty-two gasserian operations. *American Journal of Medical Science*, **160**, 157-184.
- Ehni, G., and Woltman, H. W. (1945). Hemifacial spasm. Review of one hundred and six cases. *Archives of Neurology and Psychiatry*, **53**, 205-211.
- Gardner, W. J., and Sava, G. A. (1962). Hemifacial spasm—a reversible pathophysiologic state. *Journal of Neurosurgery*, **19**, 240-247.
- Harrison, M. S. (1976). The facial tics. *Journal of Laryngology and Otolaryngology*, **90**, 561-570.
- Janetta, P. J. (1976). Vascular compression of the facial nerve at the brainstem in hemifacial spasm: treatment by microsurgical decompression. In *Current Controversies in Neurosurgery*. Edited by T. P. Morley. W. B. Saunders: Philadelphia.
- Janetta, P. J., Abbasy, M., Maroon, J. C., Ramos, F. M., and Albir, M. S. (1977). Aetiology and definitive microsurgical treatment of hemifacial spasm. *Journal of Neurosurgery*, **47**, 321-328.
- Matthews, W. B. (1966). Facial myokymia. *Journal of Neurology, Neurosurgery, and Psychiatry*, **29**, 35-39.
- Morley, T. P. (1976). Introduction to article by Janetta, P. J. In *Current Controversies in Neurosurgery*. Edited by T. P. Morley. W. B. Saunders: Philadelphia.
- Neagoy, D. R., and Dohn, D. F. (1974). Hemifacial spasm secondary to vascular compression of the facial nerve. *Cleveland Clinic Quarterly*, **41**, 205-214.
- Petty, P. G., and Southby, R. (1977). Vascular compression of lower cranial nerves: observations using microsurgery, with particular reference to trigeminal neuralgia. *Australian and New Zealand Journal of Surgery*, **47**, 314-320.
- Potter, J. (1972). The surgical treatment of hemifacial spasm. *Journal of Laryngology and Otolaryngology*, **86**, 889-892.
- Scoville, W. B. (1969a). Hearing loss following exploration of the cerebello-pontine angle in the treatment of hemifacial spasm. *Journal of Neurosurgery*, **31**, 47-49.
- Scoville, W. B. (1969b). Partial extracranial section of the seventh nerve for hemifacial spasm. *Journal of Neurosurgery*, **31**, 106-108.