

Electrophysiological aspects of sensory conduction velocity in healthy adults

1 Conduction velocity from digit to palm, from palm to wrist, and across the elbow, as a function of age

A. CRUZ MARTÍNEZ, M. BARRIO, M. C. PÉREZ CONDE,
AND A. M. GUTIÉRREZ

From Servicio de Neurofisiología Clínica, Ciudad Sanitaria de la Seguridad Social La Paz, Madrid, Spain

SUMMARY The sensory conduction velocity from digit to palm and from palm to wrist was determined in median (digit 3) and ulnar (digit 5) nerves in 47 healthy subjects with age range from 21 to 77 years. The decrement of the sensory conduction as a function of age was more marked in the palm to wrist than in the digit to palm segment. Sensory conduction velocity of the ulnar nerve across the elbow was also studied. Irregularities in the shape of the sensory evoked potential recorded above the cubital sulcus were found in 12.76% of cases, especially in subjects over 50 years of age. These results suggest that aging causes decrement in sensory conduction and changes in the shape of the evoked potentials, especially at points where the nerves are more frequently compressed.

Digital nerve conduction using mechanical (McLeod, 1966) and electrical stimulation (Casey and LeQuesne, 1972a) of the fingers, and sensory conduction velocity (SCV) from digit to palm have been described (Buchthal and Rosenfalck, 1971; Buchthal *et al.*, 1974). Both methods have a particular value since the more distal part of the peripheral nerves can be studied. The distal part of the nerves is fundamentally affected in diabetes (Casey and LeQuesne, 1972a) and alcoholism (Casey and LeQuesne, 1972b), whereas in the carpal tunnel syndrome the changes are more severe at the wrist (McLeod, 1966; Buchthal and Rosenfalck, 1971; Casey and LeQuesne, 1972a; Buchthal *et al.*, 1974).

The SCV from digit to palm and from palm to wrist, and the evolution of the normal parameters of the sensory evoked potential (SEP) at the palm and wrist, were determined in the present study according to age in healthy adults. The SCV of the ulnar nerve across the sulcus of the elbow was then studied, in the same series of normal adults, to obtain information about electrophysiological

changes in the nerve fibres in sites where the nerves are more frequently compressed. We have already published the results of SCV and mixed nerve conduction velocity in the upper and lower limbs of healthy subjects of different ages (Cruz Martínez *et al.*, 1978).

Subjects and methods

Forty-seven healthy subjects, 25 women and 22 men, whose ages ranged from 21 to 77 years were explored. None had signs or symptoms of neuromuscular disease. The series was distributed in three groups: 21 to 29 years, 30 to 49 years, and 50 to 77 years.

The maximum SCV was determined for digit to palm and palm to wrist (median and ulnar nerves), and wrist to elbow (ulnar nerve) segments. The stimulus (square electric pulse of 0.1 ms duration and 0.5 ms interval between stimuli) was delivered through metal ring electrodes on digits 3 and 5.

The SEP was recorded with surface electrodes and a bipolar technique (20 mm fixed interelectrode distance) at the palm, wrist, and elbow. An average of 100 co-ordinates was used to study the SEP, the amplitude of which was calculated

Address for reprint requests: Dr A. Cruz Martínez, C/Toledo, 144C.D, Madrid 5, Spain.

Accepted 19 June 1978

peak to peak. The conduction velocity of the mixed nerve (MxCV) was measured in the cubital nerve, stimulating the ulnar nerve at the wrist and recording the mixed evoked potential (MxEP) at the elbow and axilla.

The skin was prepared before exploration and, when necessary, the hand was warmed by immersion in hot water. The temperature of the skin over the nerves was 33°C (palm and wrist) and 33.5°C (elbow). The fingers were covered and separated from each other with cotton. All explorations were performed on the right hand.

Results

The mean values of the SCV digit to palm and palm to wrist for ulnar and median nerves, and the amplitude and duration of the SEP at palm and wrist, with error and standard deviation are shown, according to age, in Table 1.

In the median nerve the maximum SCV was moderately faster (4%) in the palm to wrist segment than in the digit to palm segment in subjects below 50 years of age. In the group from 50 to 77 years of age, SCV was the same for both segments (Table 1). In the ulnar nerve the maximum SCV was also faster in the proximal than in the distal segment (15% in the group aged 21–29 years and 11% in the other age groups).

The SCV decreased as a linear function of age, but the decrement was more marked in the palm to wrist than in the digit to palm segment, especially in the median nerve, in which the regression lines for both segments coincide at about 70 years of age (Fig. 1).

The amplitude of the SEP at the palm was higher than at the wrist, whereas the duration was shorter (Table 1). The amplitude was 30% (digit 3) and 35% (digit 5) higher in the palm, and the duration was 18% (digit 3) and 13% (digit 5) larger in the wrist. The amplitude and duration of the SEP were a linear function of the age, the former decreasing and the later increasing (Fig. 1).

The SCV and MxCV of the ulnar nerve were faster in the wrist below cubital sulcus and above sulcus axilla segments (Table 2) than in the wrist above sulcus segment. The SCV across the cubital sulcus averaged 17.3 m/s slower than in the wrist above sulcus segment. The MxCV across the sulcus was also slower than in other segments of the nerve (Table 2).

The SEP recorded above the sulcus was desynchronised in 12.76% of subjects (Fig. 2). The shape of the potential was abnormal, but the maximum conduction velocity was normal in the wrist above sulcus segment. The shape of the SEP did not show abnormalities in the palm, wrist, and below sulcus segment. None of the subjects

Table 1 Sensory conduction velocity digit to palm and palm to wrist—amplitude and duration at palm in median and ulnar nerves in 47 healthy adults. Mean values \pm standard error

Digit	Age (yr)	Digit-palm				Palm-wrist			
		SCV (m/s)	SD	Amplitude (μ V)	SD	Duration (ms)	SD	SCV (m/s)	SD
3	< 30	52.0 \pm 0.97	3.78	26.5 \pm 2.37	9.18	0.90 \pm 0.02	0.08	54.1 \pm 1.27	4.94
	31–49	52.3 \pm 1.20	4.50	25.9 \pm 2.59	9.71	0.88 \pm 0.02	0.09	54.6 \pm 1.33	5.00
	\geq 50	51.4 \pm 1.05	4.07	17.0 \pm 1.34	5.20	0.93 \pm 0.02	0.09	51.2 \pm 1.31	5.09
5	< 30	50.0 \pm 1.12	4.20	17.5 \pm 1.64	6.15	0.91 \pm 0.02	0.10	57.6 \pm 1.20	4.49
	31–49	50.6 \pm 1.36	5.10	17.4 \pm 1.62	6.08	0.90 \pm 0.02	0.10	56.3 \pm 1.32	4.96
	\geq 50	48.4 \pm 1.54	5.57	11.2 \pm 1.38	4.98	0.97 \pm 0.03	0.11	54.1 \pm 1.50	5.42

SD=standard deviation.

Table 2 Sensory and mixed conduction velocities for the different segments of the ulnar nerve. Mean values \pm standard error

	Age (yr)	Digit-wrist		Wrist above sulcus		Wrist below sulcus		Below—above sulcus		Above sulcus axilla	
		m/s	SD	m/s	SD	m/s	SD	m/s	SD	m/s	SD
SCV	< 30	53.1 \pm 0.60	2.36	61.4 \pm 1.11	4.31	70.5 \pm 0.99	3.86	45.7 \pm 1.65	6.39	69.3 \pm 1.48	5.74
	31–49	53.8 \pm 1.23	4.61	60.3 \pm 1.06	3.99	69.8 \pm 1.20	4.52	41.7 \pm 1.61	6.03	69.2 \pm 1.63	6.11
	\geq 50	51.4 \pm 0.98	3.80	56.2 \pm 1.59	6.16	64.9 \pm 1.25	4.69	39.3 \pm 1.52	5.69	67.6 \pm 2.21	8.30
MxCV	< 30			63.2 \pm 0.91	3.56	73.0 \pm 1.34	5.21	46.0 \pm 1.43	5.57	73.3 \pm 1.91	7.16
	31–49			60.7 \pm 0.93	3.49	70.8 \pm 1.18	4.42	43.2 \pm 1.80	6.74	70.9 \pm 2.00	7.50
	\geq 50			58.9 \pm 1.74	6.74	68.1 \pm 1.67	6.47	39.6 \pm 1.60	6.22	70.2 \pm 2.01	7.25

SD=Standard deviation.

had signs, symptoms, or history of cubital neuropathy. Four of the six patients with abnormally shaped SEP above the cubital sulcus were over 50 years old.

Discussion

The study of the SCV in the distal part of the nerves (from digit to palm and from palm to wrist) has obvious value and clinical application allowing a decision as to whether abnormalities in conduction velocity are at the wrist or in a more distal part of the sensory nerve fibres. An example is the recurrent familial neuropathy with liability to pressure palsies. When the median nerve was clinically affected, the slowest SCV lay in the palm to wrist segment; whereas in the clinically unaffected median nerve, electrophysiological study showed a more severe impairment in the digit to

palm segment (Cruz Martínez *et al.*, 1977).

Buchthal and Rosenfalck, 1971) found that the SCV was the same in the digit to palm and palm to wrist segments. Our results are similar, but they show that the conduction from palm to wrist is moderately faster than in the more distal segment. The SCV decreases as a function of age, but the decrement is more marked in the palm to wrist segment in the oldest subjects, especially in the median nerve. The more marked slowing caused by age in the proximal part of the nerves has been reported by Nielson (1973), but the differences between ulnar and median nerves might have their explanation in subclinical changes suffered by the median nerve in the carpal tunnel (Neary *et al.*, 1975). A subclinical entrapment of the ulnar nerve at the elbow may explain the anomalies in the shape of the SEP recorded above the elbow.

Neary *et al.* (1975) have described necropsy

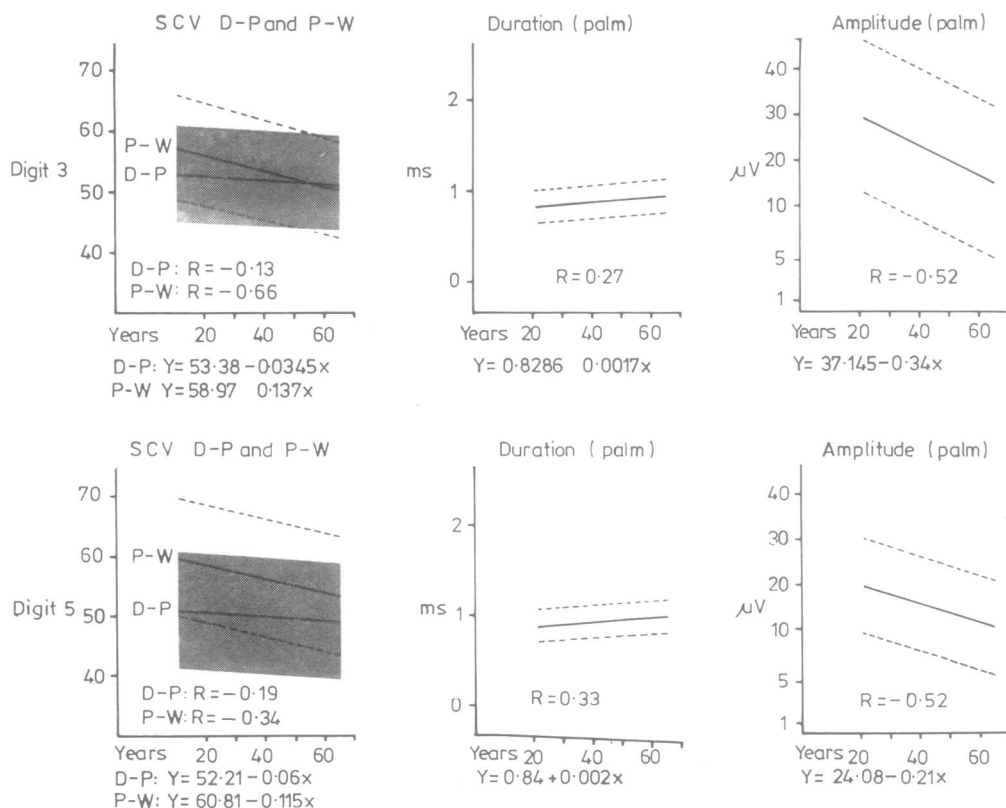


Fig. 1 Sensory conduction velocity, amplitude, and duration of the SEP in median and ulnar nerves as a function of age in 47 healthy adults. Regression lines for SCV in P-W (palm to wrist) and D-P (digit to palm) segments, duration, and amplitude at the palm. R=correlation coefficient; Y=m/s, ms, and μV ; X=years of age; Shaded area=95% confidence limits for D-P conduction; dashed lines =95% confidence limits for P-W conduction, amplitude, and duration.

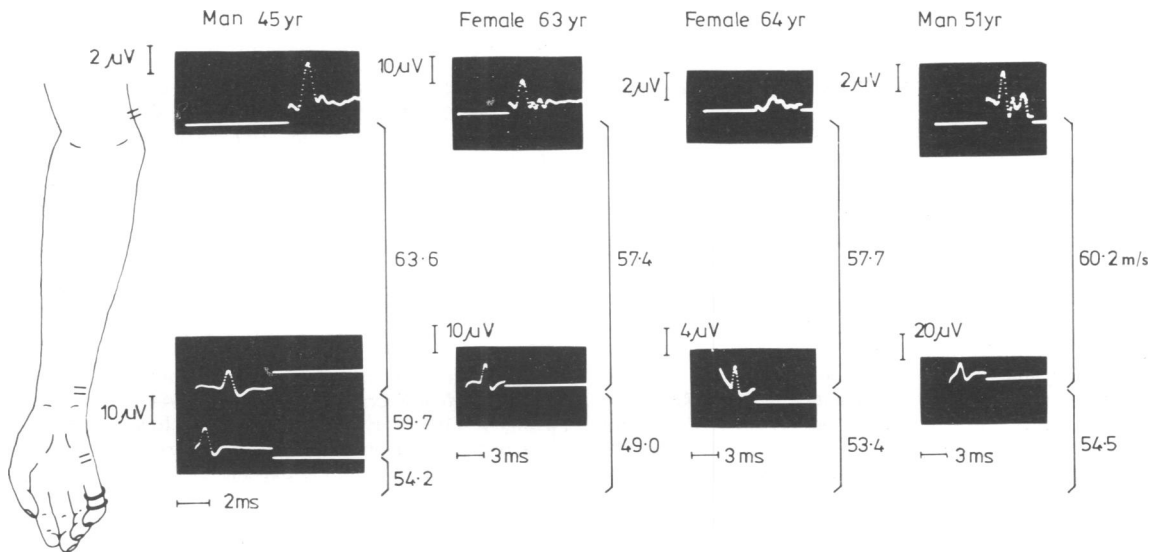


Fig. 2 Abnormalities in the shape of the SEP recorded above sulcus in four subjects without signs or symptoms of ulnar neuropathy. The shape of the SEP at the palm and wrist, and SCV in the different segments of the nerve are normal.

studies of patients without diseases of the peripheral nerve. Mild changes in ulnar nerve at the elbow and in the median nerve at the wrist were observed, and they concluded that a subclinical entrapment can exist in apparently unaffected adult subjects. Other electrophysiological results pointed to the same conclusion (Kaeser, 1963; Payan, 1969). In our series, the abnormal shape of the SEP at the elbow, and the decrement of the SCV in the palm to wrist segment predominated in older subjects. Both results suggest that age causes decrement of the SCV, changes in the shape of the SEP, or both in all peripheral nerve segments, but essentially in the sites where the nerves are habitually compressed.

Other changes related to age, such as increment in duration and reduction of the amplitude of the SEP, are well known (Buchthal and Rosenfalck, 1966; Payan, 1969; Nielsen, 1973; Cruz Martínez *et al.*, 1978). The amplitude and duration of the SEP are a function of the distance between stimulating and recording points (Buchthal and Rosenfalck, 1966). As the distance from digit to palm is short, the amplitude of the SEP is higher and the duration is shorter than at the proximal recording points.

The SCV and MxCV calculated in the wrist below sulcus, wrist above sulcus, and below-above sulcus segments, support the main information for diagnosis of ulnar nerve entrapment at the elbow. The cases of subclinical entrapment with abnormal

shape of the SEP above the sulcus and normal SCV have been mentioned above. Nevertheless, the difficulty lies in the estimation of the changes in SCV across the sulcus, because of differences in the normal values reported by various authors. Our results show that the SCV across the sulcus is slower than in the forearm, in healthy adult subjects, as previously reported by Carpendale (1966) and Payan (1969). However, the SCV across the sulcus is the same above and below, when the distance between electrodes is measured with the forearm in pronation (Shubert, 1964) or with the elbow at a right angle (Kaeser, 1963). We have measured the distance with the forearm in supination and the elbow in extension. In this position the distance measured is less than the real length of the nerve (Payan, 1969), and an apparent local slowing in the calculated SCV can be noticed. It is necessary to be acquainted with this technical problem for a correct evaluation of the results.

References

- Buchthal, F., and Rosenfalck, A. (1966). Evoked action potentials and conduction velocity in human sensory nerves. *Brain Research*, **3**, 1-121.
- Buchthal, F., and Rosenfalck, A. (1971). Sensory conduction from digit to palm and from palm to wrist in the carpal tunnel syndrome. *Journal of Neurology, Neurosurgery, and Psychiatry*, **34**, 243-252.
- Buchthal, F., Rosenfalck, A., and Trojaborg, W. (1974). Electrophysiological findings in entrapment

- of the median nerve at wrist and elbow. *Journal of Neurology, Neurosurgery, and Psychiatry*, **37**, 340-360.
- Carpendale, M. T. (1966). The localization of ulnar nerve compression in the hand and arm: an improved method of electroneuromyography. *Archives of Physical Medicine*, **47**, 325-330.
- Casey, E. B., and LeQuesne, P. M. (1972a). Digital nerve action potentials in healthy subjects, and in carpal tunnel and diabetic patients. *Journal of Neurology, Neurosurgery, and Psychiatry*, **35**, 612-623.
- Casey, E. B., and LeQuesne, P. M. (1972b). Electrophysiological evidence for a distal lesion in alcoholic neuropathy. *Journal of Neurology, Neurosurgery, and Psychiatry*, **35**, 624-630.
- Cruz Martínez, A., Pérez Conde, M. C., Ramón y Cajal, S., and Martínez, A. (1977). Recurrent familial polyneuropathy with liability to pressure palsies. Special regards to electrophysiological aspects of seventy-five members from seven families. *Electromyography and Clinical Neurophysiology*, **17**, 101-124.
- Cruz Martínez, A., Barrio, M., Pérez Conde, M. C., and Molinero, D. (1978). Estudio de la conducción nerviosa sensitiva y mixta en miembro superior. *Revista Clínica Española*, **148**, 247-254.
- Kaesler, H. E. (1963). Erregungsleitungsstörungen bei ulnarisparese. *Deutsche Zeitschrift für Nervenheilkunde*, **185**, 231-243.
- McLeod, J. G. (1966). Digital nerve conduction in the carpal tunnel after mechanical stimulation of the finger. *Journal of Neurology, Neurosurgery, and Psychiatry*, **29**, 12-22.
- Neary, D., Ochoa, J., and Gilliatt, R. W. (1975). Subclinical entrapment neuropathy in man. *Journal of the Neurological Sciences*, **24**, 283-298.
- Nielsen, V. K. (1973). Sensory and motor nerve conduction in the median nerve in normal subjects. *Acta Medica Scandinavica*, **194**, 435-443.
- Payan, J. (1969). Electrophysiological localization of ulnar nerve lesions. *Journal of Neurology, Neurosurgery, and Psychiatry*, **32**, 208-220.
- Shubert, H. A. (1964). Conduction velocities along course of ulnar nerve. *Journal of Applied Physiology*, **19**, 423-426.