



Contents lists available at ScienceDirect

## International Journal of Surgery Case Reports

journal homepage: [www.casereports.com](http://www.casereports.com)

# Stoppa approach for intrapelvic damage control and reconstruction of complex acetabular defects with intra-pelvic socket migration: A case report



Antonio Murcia-Asensio<sup>a,\*</sup>, Francisco Ferrero-Manzanal<sup>a</sup>, Raquel Lax-Pérez<sup>b</sup>,  
Mariano Fernández-Fairén<sup>c</sup>

<sup>a</sup> Hospital General Universitario Santa Lucía, C/Mezquita, s/n, Paraje Los Arcos, 30202, Santa Lucía, Cartagena, Spain

<sup>b</sup> Hospital General Universitario Reina Sofía, Avda. Intendente Jorge Palacios, 1, 30003 Murcia, Spain

<sup>c</sup> Instituto de Cirugía Ortopédica y Traumatología de Barcelona, C/Diputación, 321-Pral. 2<sup>o</sup> Les Corts, 08029 Barcelona, Spain

## ARTICLE INFO

### Article history:

Received 13 April 2016

Received in revised form 14 June 2016

Accepted 14 June 2016

Available online 25 June 2016

### Keywords:

Stoppa approach

Total hip revision

Trabecular metal

## ABSTRACT

**INTRODUCTION:** Failed hip arthroplasty with intrapelvic acetabular migration can be challenging due to the potential damage of intrapelvic structures.

**PRESENTATION OF THE CASE:** We present a case of a 75 year-old lady with failed hip arthroplasty with loosening of implants and intra-pelvic migration of the cup, antiprotrusio cage mesh, screws and plate. A modified Stoppa approach was performed, a part of the migrated elements were safely removed, the intrapelvic structures were controlled, and the bone defect was reconstructed through the Stoppa approach combined with the lateral window of ilioinguinal approach by means of bone struts and metallic plates, which is a novel technique. Then an extended posterolateral hip approach was done and the acetabulum was reconstructed using porous tantalum augments and morselized allograft. A cemented constrained socket was implanted. After one-year follow-up the patient is able to walk with one crutch without pain.

**DISCUSSION:** Due to intrapelvic migration, the implants used in hip arthroplasty may become entrapped between the anatomical structures lodged in the pelvis and cause damage to them. A careful preoperative assessment and planning are mandatory. A migrated socket can be inaccessible through a conventional hip approach and removal could be very difficult and dangerous.

**CONCLUSION:** The Stoppa approach in hip revision surgery can be a complement to traditional approaches to control the intrapelvic structures, remove migrated implants of previous surgery and reconstruct the pelvic defect.

© 2016 The Author(s). Published by Elsevier Ltd on behalf of IJS Publishing Group Ltd. This is an open access article under the CC BY-NC-ND license (<http://creativecommons.org/licenses/by-nc-nd/4.0/>).

## 1. Introduction

A large acetabular bone defect, with loss of columns and migration of the acetabular component into the pelvic cavity is a hazardous condition that anticipates a difficult and potentially harmful revision of the failed arthroplasty. The cup, cement, screws and other items used in the previous surgery may become entrapped between the anatomical structures lodged in the pelvis and cause damage to them [1]. Vascular [2,3], neural [4], and visceral [5,6] complications have been reported in those cases. We present a novel surgical technique employed in a patient with

loosening and intra-pelvic migration of the acetabular construct through a very large and complex osseous defect.

## 2. Presentation of the case

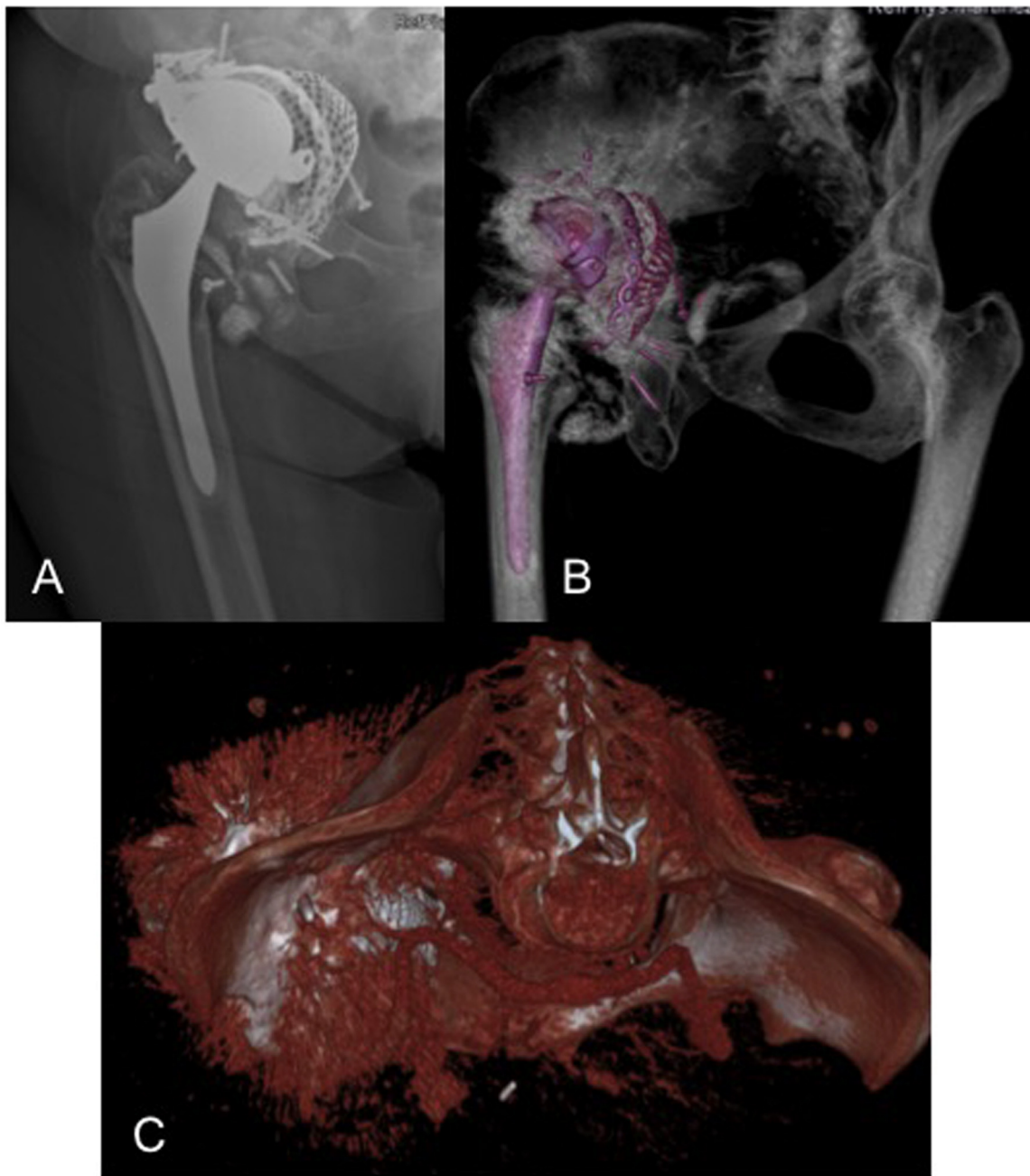
We present a case of a 75 year-old lady who complained of progressive pain in her right hip. She had been operated six years ago for total hip replacement that needed hip revision surgery one year later. The patient had no relevant medical history. The physical examination showed severe impairment for hip movement and shortening of the right limb.

The x-rays showed loosening of implants and intrapelvic protrusion of the prosthetic cup as well as the metallic elements from the previous surgery including mesh, screws, plate and antiprotrusio cage (Fig. 1A).

The CT scan showed a huge bone defect that was labelled as major pelvic column loss, consisting on the total absence of the anterior or posterior column such that less than 50% of the acetab-

\* Corresponding author.

E-mail addresses: [amurciasensio@gmail.com](mailto:amurciasensio@gmail.com) (A. Murcia-Asensio), [frankferrero@gmail.com](mailto:frankferrero@gmail.com) (F. Ferrero-Manzanal), [laxpe@yahoo.es](mailto:laxpe@yahoo.es) (R. Lax-Pérez), [mferfai@gmail.com](mailto:mferfai@gmail.com) (M. Fernández-Fairén).



**Fig. 1.** Radiological images: AP x-ray view (A); CT scan views showing the intrapelvic prosthetic migration (A) and its relationship with vessels (B).

ular component could be supported by the remaining ilium and ischium segments and stable press-fit acetabular fixation is not possible. As a rudiment of posterior column remained intact, we did not consider the bone defect as pelvic discontinuity. Proximity of prosthetic implants to the pelvic vessels was also seen by CT scan (Fig. 1B and C).

C-reactive protein, erythrocyte sedimentation rate and leukocyte blood level were negative for infection. There were no external signs of infection.

The surgical procedure was done in two following stages. The first stage was done in supine position. A modified Stoppa approach was performed to access the internal pelvic ring. The corona mortis was identified and ligated in order to avoid bleeding and to retract vessels more easily. Intraoperative tissue samples were

obtained from the peri-implant membrane being negative for infection. Some screws were removed by this approach, but not the totality of the metallic elements, because of the risk of damage of intrapelvic structures. Two constructs plate-strut were used to reinforce the anterior column and quadrilateral lamina, pushing the foreign remnants medially. The constructs were made by using two reconstruction contoured plates (LCP 3.5 mm, Synthes). Fresh-frozen femoral-allograft bone struts were attached to the middle part of the plates by using monocortical screws.

The first plate was fixed anteriorly to the superior surface of pubic rami and laterally to the iliac wing through the lateral window of ilioinguinal approach. The other was fixed anteriorly to the inner surface of pubis and posteriorly near the sacroiliac joint following the inner pelvic ring (Figs. 2A and B, 3 video).

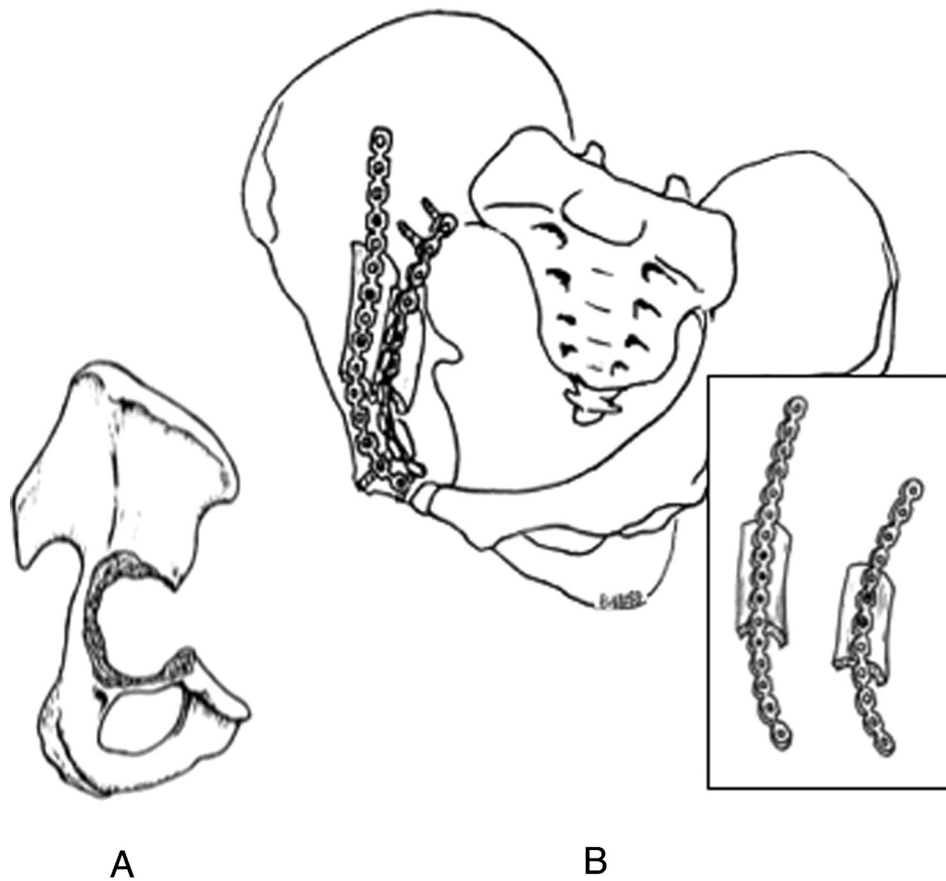


Fig. 2. schematic representation of pelvic bone defect (A) and the position of the strut-plate constructs.

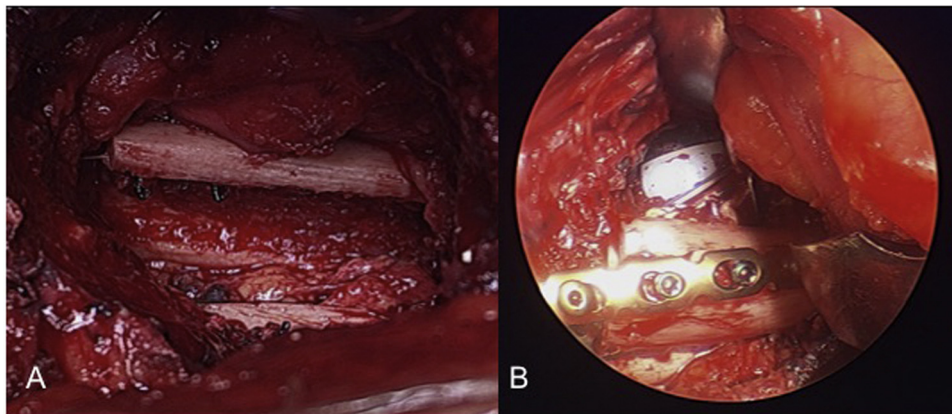


Fig. 3. Intraoperative images of the plates set in place (extrapelvic (A) and intrapelvic (B) views) (Intrapelvic image taken with an arthroscopic cam).

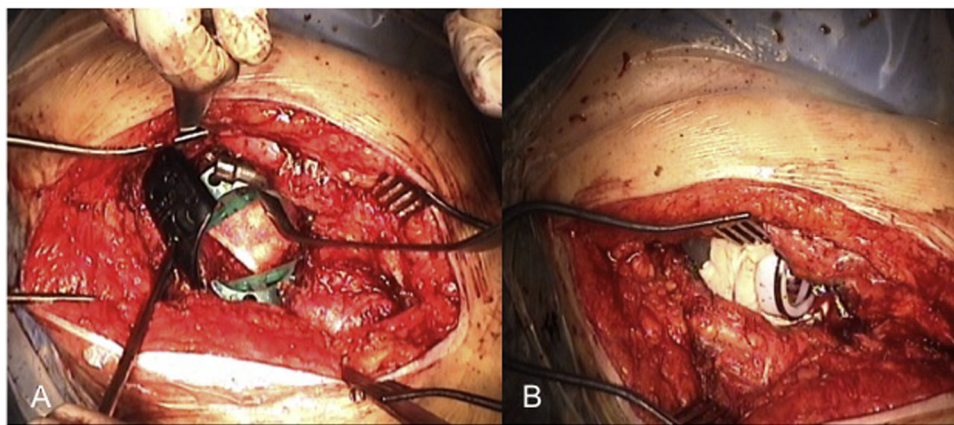
The patient was changed to lateral position to perform the second stage of the surgical procedure. An extended posterolateral approach was done with tenotomy of gluteus maximus femoral insertion to obtain better exposure. The rest of the material was removed carefully by this approach. A free cortical strut was placed to reinforce the medial wall and morsellized cancellous bone chips and was impacted over the inner surface of struts set in place in the first surgical stage. Two porous tantalum augments (Trabecular Metal, Zimmer) were placed in antero-superior and postero-inferior position to make the big defect hemispheric.

A third buttress augment was placed in the superior zone to reconstruct the rim defect, and was fixed with screws (Fig. 4A). A cemented constrained liner (Tripolar cup, Stryker®) was employed to prevent dislocation (Fig. 4B).

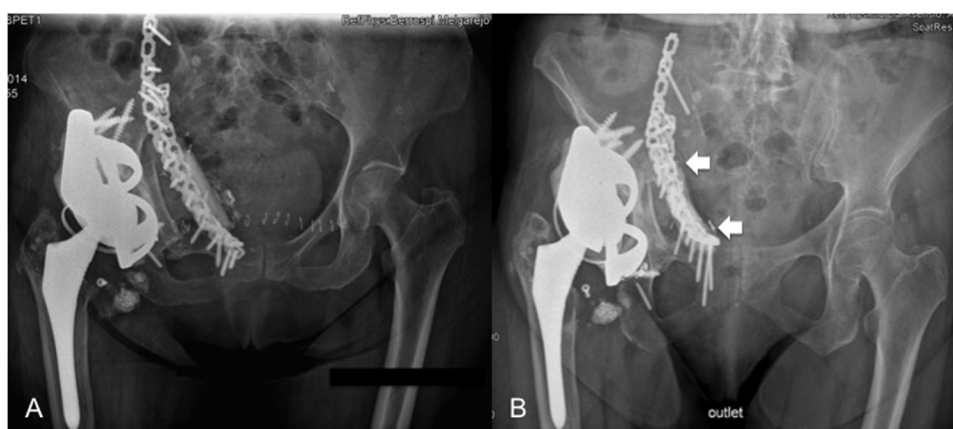
As the femoral stem didn't show neither radiological nor clinical signs of loosening, it was left in place and only the femoral head was exchanged.

The patient was operated under general anaesthesia and the duration of the surgery was 345 min. In the postoperative period, 3 red cells concentrates were transfused due to anemia.





**Fig. 4.** Intraoperative images of reconstruction strategy and after cup cementation (A) trial augment components setting in place; (B) cemented constrained liner in the reconstructed hemispheric cavity.



**Fig. 5.** Postoperative x-ray (25 days after surgery) (A) and one-year follow-up x-ray (B) (arrows show the image of strut allograft remodelling).

The postoperative x-ray showed adequate correction of the centre of rotation (Fig. 5A)

At one-year follow-up the patient was able to walk with only a crutch and had no pain on her right hip. In the radiological images obtained at that time, there were no changes in the position of the strut-plate-screw constructs with areas that suggested incorporation of the allografts. The tantalum augments and the prosthetic components had no mobilization with no images of loosening of screws (Fig. 5B). The patient is satisfied with the result of the surgery.

### 3. Discussion

When the intra-pelvic prosthetic migration exists and the migrated components are in close vicinity to vital organs, a wide approach inside and outside to the pelvis is needed. A staged operation in one surgical session has been recommended to obtain a direct and extensive view of the neurovascular and visceral structures, to mobilize, retract and protect those avoiding risks and complications when removing the intra-pelvic components, and to perform an accurate and stable reconstruction of the hip [3].

A careful preoperative assessment and planning are mandatory. The radiological study must include AP pelvic x-ray and AP and lateral hip images, and three-quarter views to search for pelvic discontinuity that is not always identified on CT because of artifacts caused by metallic objects. To evaluate the bone defect a contrast enhanced helical CT is of maximum aid. The angio-CT with venous

return is the best exam to know the location and the potential damage of intra-pelvic structures. Angio-CT is the key exam displaying the vascular components related to nerve, urogenital, and digestive structures, including the examination of veins and the lower urinary system at late phases. It is preferable to more invasive and expensive methods such as the arteriogram and venogram, and to the angio-MRI for the artifacts above mentioned [7,8]. If there is any doubt, a full screening of infection must be carried out.

The treatment of such as severe lesion as that of the present case, supposes a major surgical challenge. The migrated socket can remain inaccessible through a conventional approach to the hip joint and removal could be very difficult and dangerous [3]. A limited retroperitoneal approach through the lateral window of the ilioinguinal or Stoppa approach allows relatively simple and safe removal of cups with severe medial migration [8–10]. However, the displaced implant can be much more medial, surrounded by fibrous tissue and adherent to the main intra-pelvic structures. The rough outer surface of the socket and the presence of screws and other sharp metallic elements threaten those structures and increase the risk of damage during withdrawal [7,3]. In these cases, or when the iliopsoas muscle is dilacerated and the foreign components are in contact with the peritoneum, the transabdominal approach seems preferable, despite the discomfort of postoperative period [8].

In our case the modified Stoppa approach was used to retrieve part of the migrated components because this anterior intra-pelvic retroperitoneal approach gives a wide view and direct control of intra-pelvic organs, being less invasive than the trasperi-

toneal approach, avoiding the vascular window of the ilioinguinal approach, and minimizing the perioperative morbidity. A socket removal by the Soppa approach was not possible, as the screws made the maneuvers to remove it very dangerous even with direct visualization of the intrapelvic structures.

There are references in the literature of treatment of severe acetabular defects by reconstructing the pelvic columns with osteosynthesis [11,12]. Extensile triradiate approach and ilioinguinal approaches have been proposed to manage such scenarios.

The intrapelvic approach described by Rives and Stoppa [13], often mentioned as the “Stoppa approach”, was initially used for repairing inguinal hernias using Dacron mesh. It has been described a modification of this approach for internal fixation of pelvic and acetabular fractures with an anterior intrapelvic extraperitoneal approach through the rectus abdominis muscle [14,15]. Through this approach it is possible to access the pubic body, the superior ramus, pubic root, the ilium above and below the pectineal line, the quadrilateral lamina, the medial aspect of the posterior column, the sciatic butress and the anterior sacroiliac joint [16].

Once controlled the potential intrapelvic organ damage, the acetabulum was exposed by a conventional hip approach to perform the subsequent reconstruction and socket implantation. Having no objective data indicative of infection, the replacement was performed staged but in one time [7,8,3], contrary to that advocated by some other authors [9].

The acetabular reconstruction was done using metallic plates [17,18] and allograft struts [19] to stabilize the impaired anterior column and the medial wall [18], and porous TM augments to reconstruct the periacetabular defect, reducing the volume of acetabular bone loss and achieving a hemispheric cavity [20–22]. This cavity contained by the plates, struts and TM augments was filled with impacted morsellized cancellous bone graft, and a cemented cup was implanted. We have preferred this method, used successfully by many authors, even in Paprosky Type 3 defects [23,24], to enhance the biological response instead the insertion of a non-cemented socket, as advocated by some authors [17]. The constrained liner can improve the joint stability without increasing loosening in these cases [25].

#### 4. Conclusion

The Stoppa approach allows for pelvic damage control and reconstruction of large bone defects in failed hip prosthesis with intrapelvic socket migration. By this approach, bone strut graft-plate construct can be used to supplement the pelvic wall prior to the reconstruction of the socket by a conventional approach.

#### Conflicts of interest

One author has received funding from Zimmer (MFF) as a possible conflict of interest.

#### Funding

Each author certifies that he or she has not received and will not receive payments or benefits from a commercial entity related to this work.

#### Ethical approval

Not needed.

#### Consent

The patient signed the informed consent and accepted the case could be submitted for publication.

#### Author contribution

The authors have:

- (1) Designed the study: MFF, AMA, FFM, RLP.
- (2) Gathered the data: AMA, RLP, FFM.
- (3) Analyzed the data: AMA, FFM, RLP.
- (4) Written the initial draft: FFM, MFF.
- (5) Ensured the accuracy of the data and analysis: MFF, AMA.

#### Guarantor

AMM.

#### References

- [1] C.M. Bach, I.E. Steingruber, M. Ogon, H. Maurer, M. Nogler, C. Wimmer, Intrapelvic complications after total hip arthroplasty failure, *Am. J. Surg.* 183 (2002) 75–79.
- [2] O. Barbier, C. Pierret, F. Bazile, X. De Kerangal, V. Duverger, G. Versier, Vascular complications following total hip arthroplasty: a case study and a review of the literature, *Eur. J. Orthop. Surg. Traumatol.* 22 (Suppl. 1) (2012) S121–S125.
- [3] L. Maeckelberg, J.P. Simon, D. Naudie, S. MacDonald, K. Corten, Removal of an intra-pelvic socket: description of a safe surgical algorithm, *Acta Orthop. Belg.* 78 (2012) 152–158.
- [4] Z. Isiklar, R. Lindsey, H.S. Tullos, Sciatic neuropathy secondary to intrapelvic migration of an acetabular cup. A case report, *J. Bone Joint Surg. Am.* 79 (1997) 1395–1397.
- [5] R. Gani, S. Andronikou, R. Truter, J. Deale, Protrusion acetabuli prosthetica—a cause of a pelvic mass presenting by the gynaecologist, *J. Orthop. Case Rep.* 2 (2012) 27–28.
- [6] S.W. Palmer, H.H. Luu, H.A. Finn, Hip-vagina fistula after acetabular revision, *J. Arthroplasty* 18 (2003) 533–536.
- [7] S. Foster, H. Chaudhary, B. Assenmacher, Immediate triflange acetabular reconstruction using the retroperitoneal approach, *J. Arthroplasty* 24 (2009) 323 (e1–e5).
- [8] J. Girard, A. Blairon, G. Wavreille, H. Migaud, E. Senneville, Total hip arthroplasty revision in case of intra-pelvic cup migration: designing a surgical strategy, *Orthop. Traumatol. Surg. Res.* 97 (2011) 191–200.
- [9] F. Chana-Rodríguez, M. Villanueva-Martínez, D. Crego-Vita, J. Rojo-Manaute, J. Vauquero-Martín, Stoppa approach, an alternative for total hip arthroplasty in an intra-pelvic cup, *J. Arthroplasty* 28 (2013) 198 (e1–e4).
- [10] P. Grigoris, P. Roberts, D.J. McMinn, R.N. Villar, A technique for removing an intrapelvic acetabular cup, *J. Bone Joint Surg. Br.* 75 (1993) 25–27.
- [11] B.A. Rogers, P.M. Whittingham-Jones, P.A. Mitchell, O.A. Safir, M.D. Bircher, A.E. Gross, The reconstruction of periprosthetic pelvic discontinuity, *J. Arthroplasty* 27 (2012) 1499–1506.
- [12] J.B. Stiehl, R. Saluja, T. Diener, Reconstruction of major column defects and pelvic discontinuity in revision total hip arthroplasty, *J. Arthroplasty* 15 (2000) 849–857.
- [13] J. Rives, R. Stoppa, L.N. Fortesa, Dacron patches and their place in surgery of groin hernia 65 cases collected from a complete series of 274 hernia operations, *Ann. Chir.* 22 (1968) 159–171 (Article in French).
- [14] J.D. Cole, B.R. Bolhofner, Acetabular fracture fixation via modified Stoppa limited intrapelvic approach. Description of operative technique and preliminary treatment results, *Clin. Orthop. Relat. Res.* 305 (1994) 112–123.
- [15] E. Hirvensalo, J. Lindahl, V. Kiljunen, Modified and new approaches for pelvic and acetabular surgery, *Injury* 38 (4) (2007) 431–441.
- [16] H.C. Sagi, A. Asfari, D. Dziadosz, The anterior intra-pelvic (modified Rives-Stoppa) approach for fixation of acetabular fractures, *J. Orthop. Trauma* 24 (2010) 263–270.
- [17] D.J. Berry, D.G. Lewallen, A.D. Hanssen, M.E. Cabanela, Pelvic discontinuity in revision total hip arthroplasty, *J. Bone Joint Surg. Am.* 81 (1999) 1692–1702.
- [18] D. Pope, S. Blankenship, G. Jones, B.S. Robinson, W.J. Maloney, W.G. Paprosky, M.D. Ries, K.J. Saleh, Maximizing function and outcomes in acetabular reconstruction: segmental bony defects and pelvic discontinuity, *Instr. Course Lect.* 63 (2014) 187–197.
- [19] W.G. Paprosky, P.G. Perona, J.M. Lawrence, Acetabular defect classification and surgical reconstruction in revision arthroplasty. A 6-year follow-up evaluation, *J. Arthroplasty* 9 (1994) 33–44.
- [20] M. Abolghasemian, S. Tangsataporn, A. Sternheim, D. Backstein, O. Safir, A.E. Gross, Combined trabecular metal acetabular shell and augment for acetabular revision with substantial bone loss: a mid-term review, *Bone Joint J.* 95-B (2013) 166–172.

- [21] J.J. Ballester Alfaro, J. Sueiro Fernandez, Trabecular metal buttress augment and the trabecular metal cup-cage construct in revision hip arthroplasty for severe acetabular bone loss and pelvic discontinuity, *Hip Int.* 20 (2010) 119–127.
- [22] M. Fernández-Fairen, A. Murcia, A. Blanco, A. Meroño, A. Murcia Jr., J. Ballester, Revision of failed total hip arthroplasty acetabular cups to porous tantalum components, *J. Arthroplasty* 25 (2010) 865–872.
- [23] Y. Kosashvili, D. Backstein, O. Safir, D. Lakstein, A.E. Gross, Acetabular revision using an anti-protrusion (ilio-ischial) cage and trabecular metal acetabular component for severe acetabular bone loss associated with pelvic discontinuity, *J. Bone Joint Surg. Br.* 91 (2009) 870–876.
- [24] N. van Egmond, D.C.J. De Cam, J.W.M. Gradeniers, B.W. Schreurs, Revisions of extensive acetabular defects with impaction grafting and cemented cup, *Clin. Orthop. Relat. Res.* 469 (2011) 562–573.
- [25] M.J. Christie, S.A. Barrington, M.F. Brinson, M.E. Ruhling, D.K. DeBoer, Bridging massive acetabular defects with the triflange cup: 2- to 9-year results, *Clin. Orthop. Relat. Res.* 393 (2001) 216–227.

#### Open Access

This article is published Open Access at [scimedirect.com](http://scimedirect.com). It is distributed under the [IJSCR Supplemental terms and conditions](#), which permits unrestricted non commercial use, distribution, and reproduction in any medium, provided the original authors and source are credited.