

The incidence of abnormality in control human peripheral nerves studied by single axon dissection

N. ARNOLD AND D. G. F. HARRIMAN

From the Neuropathology Laboratory, The General Infirmary, Leeds

Dissection and staining of single myelinated axons from peripheral nerves is a procedure useful for the study of peripheral neuropathies, and has been revived in recent years (Cavanagh and Jacobs, 1964; Thomas and Lascelles, 1966) after a long period of neglect. The method demands qualities of patience and artistic agility more readily available when it was introduced over a century ago, and the beautiful pictures published by such workers as Gombault (1880/1), whose demonstration of segmental demyelination in lead poisoning is well known, have not since been equalled. Later observers relied on conventional histological methods for the examination of peripheral nerves, but these often fail to show demyelination adequately, especially segmental demyelination, in which it is necessary to see a portion of nerve long enough to demonstrate intact myelin both proximal and distal to the demyelinated internode or internodes. With revival of the technique segmental demyelination has been shown in diabetic neuropathy (Thomas and Lascelles, 1966), liver disease (Dayan and Williams, 1967), diphtheria (Cavanagh and Jacobs, 1964), peroneal muscular atrophy (Gutrecht and Dyck, 1966), and in myxoedema (Harriman, 1968), and knowledge has been gained of the pathogenesis of those disorders. However, it has also been realized that segmental demyelination may occur in normal nerves (Lubinska 1958), so that it becomes difficult to evaluate its significance in routine nerve biopsies unless it is extensive.

To help to assess the value of this technique as a routine procedure for nerve biopsy a control series of 51 nerves has been examined. Of these, 46 were obtained at necropsy of patients with no known peripheral neurological abnormality, without evidence of chronic disease or of cardiac failure with oedema. It was obviously necessary to avoid bedridden subjects in whom pressure palsies might have occurred. The specimens were obtained from a wide age range. Patients suffering from acute disease were

selected, dying after a short illness, and the causes of death were as follows: acute head injury (15); cerebral aneurysm (six); cerebral haemorrhage or thrombosis (six); myocardial infarction (six); CNS malformation (children) (four); acute infection (four); cerebral tumour (two); pulmonary embolism (two); and thrombotic microangiopathy (one). Fascicular specimens were also available from five peripheral sensory nerves obtained at motor point muscle biopsy, in which no abnormality had been detected in fascicles of the same nerve examined by the Marchi, Palade, and routine paraffin methods. Myelinated axons were dissected and measurements made of internodal length and fibre diameter, and the data from different age groups were compared. Any abnormalities found were recorded. It was found that segmental demyelination occurred in a significant proportion, but rarely more than once in 24 axons. Internode lengths at first increased and then decreased during the life span.

MATERIALS AND METHODS

The majority of nerve funiculi were taken from the musculocutaneous branch of the lateral popliteal nerve 3 in. above the lateral malleolus; many of our routine nerve biopsies are taken from this site, which conveniently overlies the peroneus brevis, often used for motor-point muscle biopsy. Other sites examined were the median nerve at least 3 in. proximal to the carpal ligament, a cutaneous nerve overlying the palmaris longus, a cutaneous nerve overlying the vastus internus, and the sural nerve from the dorsum of the foot. The nerves were classified as follows: group 1: musculo-cutaneous nerves at necropsy (34); group 2: musculo-cutaneous nerves at biopsy (three); group 3: median nerves at necropsy (10); group 4: other nerves—two at necropsy and two at biopsy (four).

Each specimen 1 to 2 cm long was placed on a piece of card, allowed to adhere to it, and then fixed in Palade solution (1% buffered osmium tetroxide) for 18 to 24 hours. It was then washed in running tap water for 24 hours and stored in 60% glycerol solution until required

Dissection of each nerve was carried out using a Zeiss stereomicroscope with twin transillumination at magnifications of $\times 20$ and $\times 60$. Three or four bundles of nerve fibres selected at random from each funiculus were teased out and individual fibres placed on a glass slide. Fibres of varying calibre from each bundle were selected without regard for the presence or absence of abnormality. The individual fibres on the glass slide were dehydrated and cleared in creosote. Most of the creosote was then removed with filter paper, the fibres straightened, some remaining creosote allowed to evaporate, and the axons then mounted in balsam. Twenty-four fibres of varying calibre were mounted from each nerve.

The diameter of each fibre was measured (see below), and the internode lengths were determined. Abnormalities including the number of demyelinated or regenerated segments were noted.

FIBRE DIAMETER The diameter of individual fibres was not always constant, and presented a problem in selection of the site for diameter measurement. As most variation occurred in the paranodal region, the most vulnerable part of the nerve fibre (Lubinska and Lukaszewska, 1956) and liable to myelin retraction and swelling, it was decided to restrict measurements to the more central parts of the internodes. Several measurements were made along the course of the internode and the mean recorded.

Greatest variation in diameter was found in some fibres of narrow calibre (6μ), which had a beaded catenate appearance throughout most or all of their length (Fig. 3). Here maximum diameter was recorded. Ochs (1965) showed that beading of myelinated fibres in rat sciatic nerve could result from stretching of the nerve: when tension was removed, the beading disappeared. In a fibre in which beading occurred only in part of its length, the diameter of the beaded or catenate area was greater than the diameter of the non-beaded section of the fibre, and this we confirmed in human nerve. We are uncertain of the cause of beading in our material, but consider it is artifactual. Care taken to avoid stretching did not prevent its occurrence.

INTERNODE LENGTH This was measured at a magnification of $\times 100$, except for small calibre fibres, where a greater magnification was sometimes necessary in order to determine the site of the node. Where the myelin had retracted from the node, it was normally possible to detect the constriction of the endoneurium at the node itself. In any one fibre, internode length was found to vary considerably, up to 200μ from the mean for that particular fibre. In abnormal fibres the variation in internode length was usually greater.

HISTOGRAMS For each nerve examined, a histogram was charted recording the internode length of each fibre against the fibre diameter (Fig. 1). Each point represents one internode length, as measured from the base line, and each line represents one fibre—this is a slight modification of the method used by Fullerton, Gilliatt, Lascelles, and Morgan-Hughes (1965). Wide variations in internode lengths in one fibre indicate an abnormality, such as segmental demyelination, and such fibres can be recognized on the histograms (C45, C48).

RESULTS

EFFECT OF AGE AND SITE Representative histograms in Fig. 1 illustrate the findings at four different ages, and Figs. 2 and 3 include normal nerve fibres at different ages.

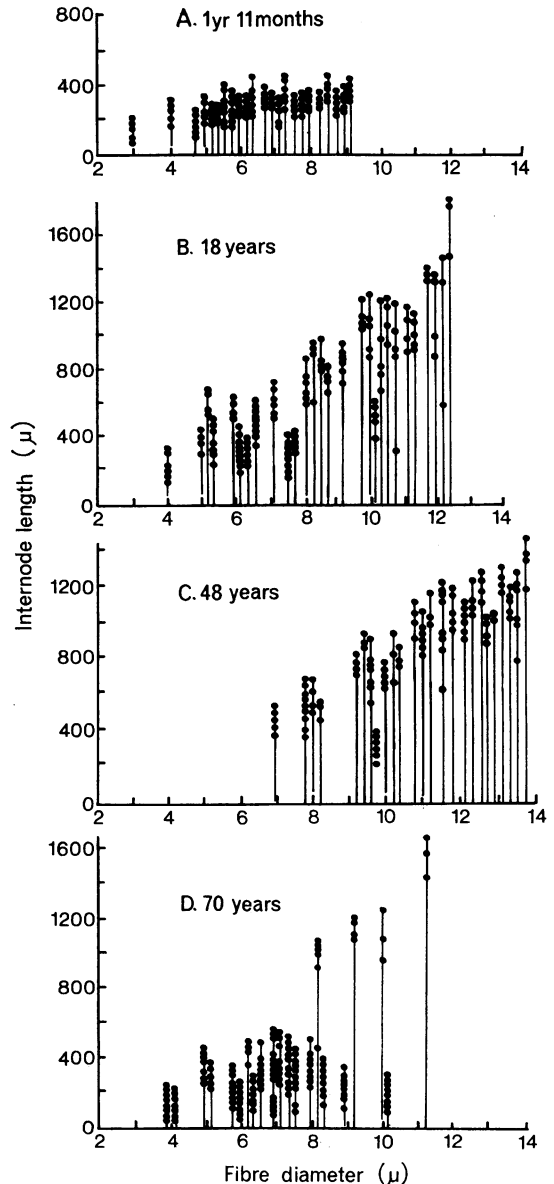


FIG. 1. Representative histograms showing increase and variation in internode length with increasing age (see text). Ordinate: internode length (μ), abscissa: fibre diameter (μ). A. (C31) 1 year 11 months. B. (C45) 18 years. C. (C51) 48 years. D. (C48) 70 years.

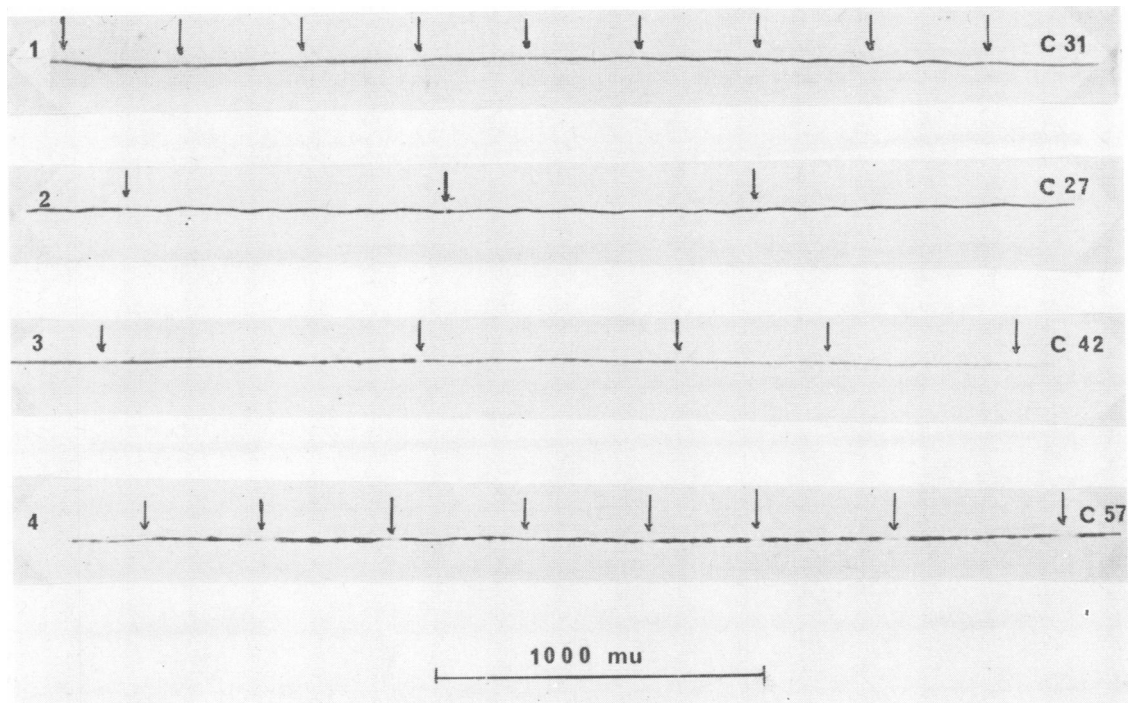


FIG. 2. 1. Normal fibre, age 1 year 11 months, calibre 6μ . 2. Normal fibre, age 25 years, calibre 10μ . 3. Short and long internodes. 4. Paranodal oedema and short internodes.

a. *From 4 weeks to 5 years* In this age group there is very little variation in internode length in fibres of different calibre—for example, the 4μ fibres have internodes of the same length as the 8μ fibres and there are very few internodes longer than 600μ . At 5 years there is a little more variation in internode length. In the youngest case the greatest calibre recorded is 9μ , whereas at 5 years two fibres with calibres of 10 and 11μ have been isolated.

b. *From 12 years to 23 years* There is now a definite increase in internode length commensurate with increased fibre calibre. Fibre calibre varies from 4μ to 12μ , and internode lengths up to $1,600\mu$ are recorded indicating considerable growth.

c. *From 34 years to 50 years* The histograms show the same graded relationship between fibre calibre and internode length as in the previous group. The greatest internode lengths recorded are of $1,500\mu$ and fibre calibres of 13 to 14μ are common.

d. *From 60 years to 75 years* There is a definite preponderance of fibres with short internode lengths especially in the fibres of 6 to 10μ calibre. These may indicate regeneration when present throughout the fibre, and are common findings in this age group.

The results are similar to those of Lascelles and

Thomas (1966), who reported on the effect of increasing age on internode length, and their findings were confirmed by Dyck, Gutrecht, Bastron, Karnes, and Dale (1968) in nine normal sural nerves. In early development internodes are all of the same short size, and this increases in proportion to the fibre diameter as growth takes place. Vizoso (1950) showed that the growth of the part from which the nerve is taken has an important influence on internode length, and in this connection it is noteworthy that we found no difference between the internode lengths of the median nerve in the forearm and the musculo-cutaneous nerve above the ankle at corresponding ages.

ABNORMALITIES Table 1 shows the number of cases in each group affected by the following abnormalities: 1 *Pale internodes between normal segments* Myelin was minimal or absent in these internodes, and their internodal length and calibre were usually less than those of the adjacent normal segments (Fig. 3). For example, a fibre (case C61) was composed of internodes of the following lengths in micra: 840—872—656—368—776—872—710. The underlined internodes were pale.

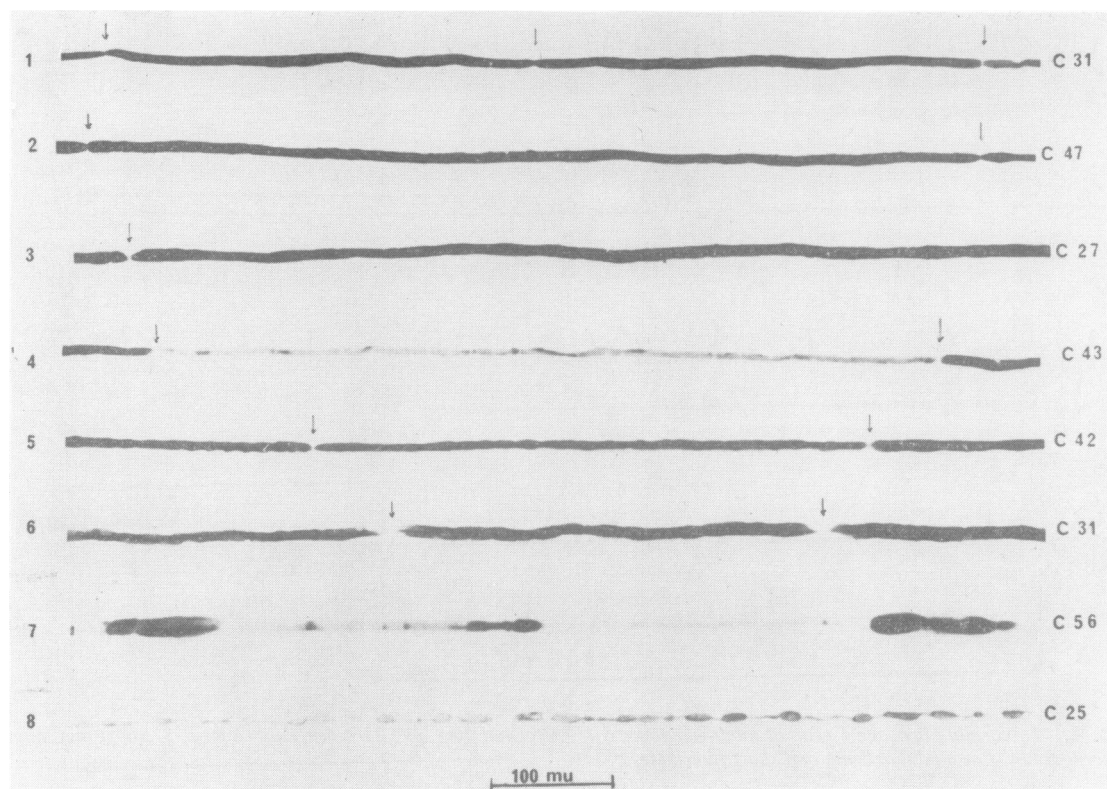


FIG. 3. 1. Normal fibre, age 1 year 11 months, calibre 6μ . 2. Normal fibre, age 5 years, calibre 8μ . 3. Normal fibre, age 25 years, calibre 10μ . 4. Segmental demyelination. 5. Fibre with intercalated short internode. 6. Paranodal oedema. 7. Wallerian-type degeneration. 8. Catenate fibre.

This indicated segmental demyelination affecting one or more segments; one fibre was isolated in which five segments were involved. The abnormal internodes were either in sequence or separated by normal internodes.

No fibres of the nerves in Group 3 (median nerves)

showed segmental demyelination, but the group was relatively small and the subjects mainly young.

2 *Short internodes between normal segments* Fibres with normally myelinated but short internodes, intercalated between normal segments (Fig. 3). For the purpose of this study a 'short' internode was

TABLE 1
INCIDENCE OF ABNORMALITIES IN EACH GROUP OF NERVES EXAMINED¹

Nerve	Pale internodes between normal segments (1)	Short internodes between normal segments (2)	Short internodes enclosed by normal segments (3)	Wallerian-type degeneration (4)	Short internodes alone (5)	Paranodal oedema (6)	Catenate fibres (7)
1. Musculo-cutaneous (necropsy)	12 (34)	6 (34)	6 (34)	3 (34)	13 (34)	23 (34)	30 (34)
2. Musculo-cutaneous (biopsy)	0 (3)	1 (3)	0 (3)	0 (3)	1 (3)	3 (3)	2 (3)
3. Median (necropsy)	0 (10)	2 (10)	1 (10)	0 (10)	6 (10)	9 (10)	7 (10)
4. (a) Other nerves (necropsy)	0 (2)	0 (2)	0 (2)	0 (2)	0 (2)	2 (2)	2 (2)
(b) Other nerves (biopsy)	1 (2)	0 (2)	1 (2)	0 (2)	2 (2)	1 (2)	1 (2)
Total	13 (51)	9 (51)	8 (51)	3 (51)	22 (51)	38 (51)	42 (51)

¹The figure in parentheses shows the total number of nerves in each group.

defined as an internode not more than half as long as the average internode length of the fibre concerned. As in demyelinated segments, the short internodes were usually slightly narrower than normal. They were thought to be due to remyelination by one or more Schwann cells of previously demyelinated segments, and hence to indicate previous segmental demyelination. Significantly, two cases showing active segmental demyelination also demonstrated short intercalated internodes.

3 Short internodes not enclosed by normal segments Here short internodes occurred at either end of a dissected fibre, in sequence with a normal internode but not intercalated (Fig. 2). There was, thus, no indication whether the short segments were due to previous segmental demyelination or to previous Wallerian-type¹ degeneration. If the latter, all segments in the regenerated portion of nerve would have been short and more or less equal (Vizoso and Young, 1948), whereas the former would have been intercalated between normal segments, no matter how far apart. In these specimens intercalation could not be determined. Seven of the eight cases in this group also had fibres with short internodes alone (see section 5), suggesting that Wallerian-type degeneration was the more likely cause.

4 Wallerian-type degeneration Active Wallerian-type degeneration was seen in only three nerves, all in necropsy musculo-cutaneous nerves. In one of the nerves concerned, two fibres with only a few remnants of myelin were seen. In the other two nerves, the appearances of the degeneration were more conventional (Fig. 3).

5 Short internodes alone In these fibres all the internodes were 'short' in comparison with normal fibres in the same funiculus (Fig. 2). It was not uncommon, occurring in 22 out of 51 cases, and indicated regeneration of the fibre after Wallerian-type degeneration.

6 Paranodal oedema Paranodal oedema was very common, and more frequent in necropsy than in biopsy material. When present, it affected most nodes in the fibre concerned. The 'oedema' was more often within myelin adjacent to the node, but occasionally was manifest as a retraction of myelin from the node (Figs. 2 and 3).

7 Catenate fibres Catenate fibres were small calibre fibres with a marked beaded appearance (Fig. 3).

INCIDENCE OF ABNORMALITIES Table 2 shows the number of fibres in each specimen affected by the various abnormalities.

¹This term is used in preference to 'Wallerian' degeneration, which, strictly speaking, refers to the sequence of events following nerve section only.

It will be seen that segmental demyelination and remyelination occurred infrequently, and then usually once only per 24 fibres. The three specimens with two affected fibres were from patients with myocardial infarction, pulmonary embolism, and cerebral haemorrhage respectively, and the specimen with four affected fibres was from a case of myocardial infarction.

Wallerian-type degeneration or its effects (columns 4 and 5 respectively) was rather more common, but did not usually affect more than three fibres per specimen unless the patient was over 60 years in age. The patient who had five fibres/24 with short internodes was aged 75 years (myocardial infarction), and the two patients with eight fibres/24 affected by this change were aged 68 years and 70 years (both myocardial infarction). Paranodal oedema and catenate fibres were frequent and occurred in more than two-thirds of the cases in up to six fibres/specimen.

AGE AT WHICH ABNORMALITIES DEVELOP Table 3 shows the incidence of abnormalities in different age groups.

It will be seen that segmental demyelination occurred only once in the first decade, and showed a low incidence thereafter, becoming commoner over 60. The effects of Wallerian-type degeneration appeared after 10 and rose steadily with age. Paranodal oedema and catenate fibres did not appear to be age related in incidence.

DISCUSSION

If dissection of individual axons is to have a place in routine examination of nerves taken at motor-point muscle biopsy, it must be able to provide information not available in the paraffin sections. It is an ideal method for the demonstration of segmental demyelination, which can only be imperfectly seen in sectioned material and may go unrecognized in embedded nerves. However, in any given nerve, the investigator requires to know how much emphasis may be put on the discovery of, say, a single fibre showing segmental demyelination, when it is realized that it may occur normally (Lubinska, 1958), and what significance can be attributed to paranodal oedema or to beading of myelin sheaths (catenate fibres).

The present study was designed to provide evidence of the incidence of abnormalities in 'normal' nerves at sites commonly used for biopsy in our hospital. It may be objected that the main nerve selected, the musculocutaneous branch of the lateral popliteal nerve, is not ideal for biopsy, as its parent nerve is liable to compression at the head of the fibula. We

TABLE 2
THE INCIDENCE OF ABNORMAL FIBRES IN EACH NERVE (PER 24 FIBRES DISSECTED)

Affected fibres in each specimen (no.)	Pale internodes between normal segments (1)	Short internodes between normal segments (2)	Short internodes not enclosed by normal segments (3)	Wallerian-type degeneration (4)	Short internodes alone (5)	Paranodal oedema (6)	Catenate fibres (7)
0	38	42	43	48	28	12	9
1	9	8	5	2	9	2	6
2	3	1	3	0	5	9	10
3	0	0	0	1	6	8	10
4	1	0	0	0	0	4	6
5	0	0	0	0	1	6	3
6	0	0	0	0	0	2	5
7	0	0	0	0	0	0	1
8	0	0	0	0	2	3	1
9	0	0	0	0	0	1	0
10 or more	0	0	0	0	0	4	0
Total	51	51	51	51	51	51	51

believe that the risks of misinterpretation of a biopsy for this reason are real, but have been exaggerated. One of us (D.H.) has used the musculocutaneous nerve for fascicular biopsy routinely since 1958 without inconsistent findings, whereas sural nerve branches on the dorsum of the foot, used before then, were not infrequently misleading, because of perineurial fibrosis and fibre loss. The most popular site for nerve biopsy in the leg nowadays is the sural nerve, behind and above the lateral malleolus, but even it is subject to fascial compression proximally and distally, and it is joined in midcalf by a branch of the lateral popliteal nerve. No long nerve is ideal for biopsy towards the periphery of its course, and it is better to be aware of the risks of abnormality being present as a result of local pressures and to assess their incidence in a 'control' series than to assume normality in controls. Anderson, Fullerton, Gilliatt, and Hern (1969) have recently shown that distal nerve compression may lead to retrograde degeneration, and this must increase our awareness of the risks of misinterpretation of nerve biopsies. Minor compressive

effects are, perhaps, unavoidable and may be responsible for the abnormalities seen in the present series of nerves as a wear and tear phenomenon.

The results show that segmental demyelination was seen in 12 out of 37 musculocutaneous nerves, and in the majority was seen in only one fibre out of 24 dissected. In three cases, two fibres were affected, and in one case, four fibres. This would indicate that on dissection of 24 fibres from a given biopsy no diagnostic significance should be attributed to segmental demyelination in one or two fibres, and increasing significance to three or more. In the case of Wallerian-type degeneration, unless the patient is over 60 years of age, the discovery of two fibres/24 showing active degeneration would be significant, whereas no diagnostic importance would be attached to evidence of former Wallerian-type degeneration unless it occurred in three or more fibres/24. Even this would not be significant in patients over 60 years old, when it is a more frequent finding.

The other abnormalities of paranodal oedema and catenate fibres are much less likely to indicate disease, the latter not at all, and the former only if it

TABLE 3
INCIDENCE OF ABNORMALITIES BY AGE

Age groups (yr)	Pale internodes between normal segments (1)	Short internodes between normal segments (2)	Short internodes not enclosed by normal segments (3)	Wallerian-type degeneration (4)	Short internodes alone (5)	Paranodal oedema (6)	Catenate fibres (7)
0-9	0 (9)	1 (9)	0 (9)	0 (9)	0 (9)	4 (9)	4 (9)
10-19	3 (7)	0 (7)	1 (7)	1 (7)	1 (7)	7 (7)	7 (7)
20-29	1 (9)	1 (9)	2 (9)	0 (9)	4 (9)	8 (9)	9 (9)
30-39	2 (9)	2 (9)	0 (9)	0 (9)	4 (9)	6 (9)	7 (9)
40-59	0 (4)	2 (4)	1 (4)	1 (4)	2 (4)	4 (4)	4 (4)
60-89	7 (13)	3 (13)	4 (13)	1 (13)	11 (13)	9 (13)	11 (13)
Total	13 (51)	9 (51)	8 (51)	3 (51)	22 (51)	38 (51)	42 (51)

occurs in more than two-thirds of the dissected fibres.

SUMMARY

Peripheral nerves obtained at biopsy or necropsy of 51 subjects were examined by single axon dissection in order to provide a control series for biopsies of diseased nerve studied by the same method.

Evidence of past or present segmental demyelination and also of active or preceding Wallerian-type degeneration was found in a small number of fibres. Their incidence suggested that on dissecting 24 fibres, diagnostic significance should be ascribed to three or more abnormal fibres, whether the abnormality consisted of previous or current segmental demyelination or active or preceding Wallerian-type degeneration. If the patient is over 60, preceding Wallerian-type degeneration should be present in six or more fibres before it is considered abnormal.

The influence of increasing age on internode length and on the incidence of abnormalities was demonstrated and the known relationships of internode length and fibre diameter confirmed.

Grants from the Muscular Dystrophy Group of Great Britain and from the National Fund for Research into Crippling Diseases are gratefully acknowledged.

REFERENCES

- Anderson, M. H., Fullerton, P. M., Gilliatt, R. W., and Hern, J. E. C. (1970). Changes in the forearm associated with median nerve compression at the wrist in the guinea-pig. *J. Neurol. Neurosurg. Psychiat.*, **33**, 70-79.
- Cavanagh, J. B., and Jacobs, J. M. (1964). Some quantitative aspects of diphtheritic neuropathy. *Brit. J. exp. Path.*, **45**, 309-322.
- Dayan, A. D., and Williams, R. (1967). Demyelinating peripheral neuropathy and liver disease. *Lancet*, **2**, 133-134.
- Dyck, P. J., Gutrecht, J. A., Bastron, J. A., Karnes, W. E., and Dale, A. J. D. (1968). Histologic and teased-fiber measurements of sural nerve in disorders of lower motor and primary sensory neurons. *Mayo Clin. Proc.*, **43**, 81-123.
- Fullerton, P. M., Gilliatt, R. W., Lascelles, R. G., and Morgan-Hughes, J. A. (1965). The relation between fibre diameter and internodal length in chronic neuropathy. *J. Physiol. (Lond.)*, **178**, 26 P-28 P.
- Gombault, M. (1880/1). Contribution à l'étude anatomique de la névrite parenchymateuse subaiguë et chronique-névrite segmentaire péri-axile. *Arch. Neurol. (Paris)*, **1**, 11-38.
- Gutrecht, J. A., and Dyck, P. J. (1966). Segmental demyelination in peroneal muscular atrophy: nerve fibres teased from sural nerve biopsy specimens. *Mayo Clin. Proc.*, **41**, 775-777.
- Harriman, D. G. F. (1968). Unpublished observations.
- Lascelles, R. G., and Thomas, P. K. (1966). Changes due to age in internodal length in the sural nerve in man. *J. Neurol. Neurosurg. Psychiat.*, **29**, 40-44.
- Lubinska, L., and Lukaszewska, I. (1956). Shape of myelinated nerve fibres and proximo-distal flow of axoplasm. *Acta Biol. exp. (Warszawa)*, **17**, 115-133.
- (1958). 'Intercalated' internodes in nerve fibres. *Nature (Lond.)*, **181**, 957-958.
- Ochs, S. (1965). Beading of myelinated nerve fibres. *Exp. Neurol.*, **12**, 84-95.
- Thomas, P. K., and Lascelles, R. G. (1966). The pathology of diabetic neuropathy. *Quart. J. Med.*, **35**, 489-509.
- Vizoso, A. D., and Young, J. Z. (1948). Internode length and fibre diameter in developing and regenerating nerves. *J. Anat. (Lond.)* **82**, 110-134.
- (1950). The relationship between internodal length and growth in human nerves. *J. Anat. (Lond.)*, **84**, 342-353.