

Gelastic epilepsy

JOHN GUMPERT, PHIROZE HANSOTIA, AND ADRIAN UPTON

From the Department of Applied Electrophysiology, The National Hospital for Nervous Diseases, Queen Square, London, and the Department of Neurology, United Sheffield Hospitals

SUMMARY A case of retinitis pigmentosa with laughing epilepsy is described. Stereotyped repetitive episodes of limb movement, rigidity, and cackling laughter responding to diazepam are recorded. One episode is presented as gelastic status epilepticus and the clinical and EEG features are reported. Features of gelastic epilepsy are discussed and briefly compared with other laughing disorders. A short history of the condition is accompanied by a relevant review of the literature. The possible importance of hypothalamic lesions in laughing epilepsy is discussed and the absence of consistent EEG findings is noted.

Compulsive bursts of laughter or giggling are a rare, but well-recognized feature of epilepsy. In 1873 Trousseau first observed that bursts of laughter or giggling might constitute an epileptic fit. Oppenheim (1889) reported compulsive laughter in disseminated sclerosis and in 1902 recorded two cases in which the laughter appeared to precede epilepsy; an observation which he thought was original. However, Féré in 1898 reported a similar phenomenon. The terms 'Gelosyncope' and 'Geloplegia' were used by Oppenheim to describe patients in whom laughter precipitated loss of consciousness in the first case and loss of postural tone in the second. Frigerio's patient, described in 1889, had episodes of babbling and laughter. In another paper in 1903 Féré described a patient in whom prolonged laughter was followed by hemiplegia and he called this phenomenon 'le fou rire prodromique'. Two cases of laughter and automatism were reported by Mills (1912) and Rogal (1937).

In 1919 Meige and Béhague described a patient with very prolonged attacks of involuntary laughter without loss of consciousness. One episode lasted for 15 days and the attacks were then followed by unconsciousness or frank convulsions. Further reports have appeared since (Badt, 1927; Wilder, 1931; Wilson, 1935; Andersen, 1936; Le Gros Clark, Beattie, Riddoch, and Dott, 1938; Roubíček, 1946; Martin, 1950; Gibbs and Gibbs, 1952; Jewesbury, 1954; and List and Bebin, 1956). Druckman and Chao (1955) described laughter as an occasional manifestation of the seizure pattern in massive spasms. Two years later the same authors described 11 cases with laughter as an epileptic manifestation.

The term gelastic epilepsy (*Yelos* = mirth) was

used by Daley and Mulder (1957) to describe two cases where laughter formed a definite fixed part of the seizure pattern. Two cases of epileptic laughter were discussed by Jaros (1968). We wish to present a further case of gelastic epilepsy and furthermore to describe a period in this patient's illness which would appear to be the first description of a gelastic status epilepticus, although Symonds (personal communication, 1969) saw a case which had not been reported. In addition, we have reviewed the literature on this subject and discussed some aspects of the condition.

CASE REPORT

The patient was first seen in March 1961, because of gradual failure of vision since the age of 5.

She was a full-term normal delivery baby who was thought to develop normally until the age of 5. She was able to read before she was 7, but soon after she was noted to be having difficulty in reading—having to hold the book very close to her face. From then on her vision steadily deteriorated and only light perception remained when she was first seen.

In May 1961, aged 13, she was first admitted to the National Hospital (Dr. Meadows) when examination showed her to appreciate only finger movements and the colours green and white. The fundi were pale, had narrow vessels, and showed some spider-like pigment deposits.

She had brisk tendon reflexes, but otherwise the neurological and general medical examination were normal. The blood pressure was 120/70 mm Hg, but psychological testing showed an intelligence quotient of only 86 (WISC).

Radiographic studies of the skull, optic foramina, and chest were normal. Routine examination of blood and CSF, including the Wassermann reaction, were

unhelpful. Urinary examination for metachromatic granules was negative and amino acid estimation was within normal limits. The ferric chloride test was also negative. The diagnosis of retinitis pigmentosa was made at this time.

In June 1962 she had her first major convulsion and a further one in December of that year. These were not reported until February 1963, when phenobarbitone was commenced.

She was seen again in February 1964. In the preceding three weeks she had developed a negative attitude to her family, having become withdrawn, and refusing to eat. This was followed by bouts of crying and periods of incessant chatter of unusual content. She talked of a fiancé called Dennis waiting for her in America. (There was a boy called Derek in the ward on her previous hospital admission.) She had been confusing past and present events, but kept returning to the story of her fiancé—each telling becoming more involved and confused. She then refused to return to school. She had experienced two further seizures since her last visit and in the out-patient department was noted to be noisy and difficult to manage. In view of this she was re-admitted to the National Hospital direct from out-patients. At this time she did not seem to be hallucinated, though her speech was slurred. Her visual acuity and fundi showed little change and the rest of the examination was unremarkable. Psychological testing showed a fall in IQ to 71 (WISC). Repeat haematological and urinary studies were again unhelpful.

A further seizure occurred in July, and in September 1964 she was unable to go on attending the special school where attempts had been made to teach her Braille. By March 1965 she was exhibiting bouts of extreme agitation. They were treated with chlorpromazine 25 mg three times a day, but this led to rigidity of the limbs which disappeared with the substitution of amylobarbitone. At this time the plantar responses were noted to be extensor, though the frequency of her seizures seems uncertain.

In March 1967 she had a series of generalized convulsions after which she became withdrawn, complained of feeling unsteady, and took to her bed. When seen she was uncooperative, her speech was unintelligible, and she had marked hypertonia of all four limbs.

She was not seen again until June 1968, when she was admitted as an emergency. Two weeks earlier she had become less cooperative in her eating and walking. Nine days before she had had a major convulsion, and five days before two further seizures. She was noted to be pyrexial and was treated by her general practitioner with penicillia. She then became confused and restless, exhibiting a constant stream of senseless chatter with elevations and depressions of mood. These manifested themselves from tears to bouts of uncontrollable and noisy laughter which might last all night. For the 24 hours before admission there had been continuous laughter, crying, and shouting, but there had been no aggression. For some months she had been totally blind and was unable to walk unaided. She was no longer able to put on her clothes, but she could still feed herself.

On arrival in the ward she exhibited a bout of extremely

noisy and uncontrollable laughter followed by a bout of pitiful sobbing. During examination she was entirely uncooperative; the physical findings, apart from pyrexia, remaining unchanged.

She continued to exhibit short episodes of laughter in rapid succession for three or four days, each attack being similar in content and intensity.

The attacks had the following characteristic features. An initial, but brief vacant expression appeared. The eyes then became deviated to the right and showed slow nystagmoid movements. Both arms would then be raised in front of the chest the hands showing fumbling movements of the fingers. The head then turned to the right and this was associated with a high pitched, monotonous, cackling laugh lasting for several seconds. Examination during the attack suggested that muscle tone was increased generally, particularly on the right side. The end of the episode was as abrupt as the onset—the patient remaining quiet for some seconds and then the whole process would be repeated. The attacks were stereotyped and repetitive. During the laughter external stimuli did not evoke appropriate responses.

On the following day she was seen by the nursing staff to have a typical grand mal seizure. Soon afterwards an EEG performed at the bedside, and including periods of laughter, suggested that she was in status epilepticus. The record showed little electrical activity during the periods of laughter (Figure), and bursts of irregular high voltage generalized slow wave activity with spikes occurring between the episodes of laughter. Throughout the record intermittent low voltage activity was consistently associated with the periods of cackling. The symptoms responded initially to intravenous diazepam (Valium), though for a further day or two occasional episodes of laughter were noted. This clinical improvement was reflected in further EEG studies.

One week after admission she was again conscious, able to converse with her parents and to feed herself. Soon after this she was allowed home.

Five weeks later—again after a pyrexia—she was re-admitted because of a similar episode. This responded rapidly to intravenous Valium and when she was last seen in out-patients some weeks later there had been no further attacks.

DISCUSSION

'Forced laughter' is well recognized as a symptom of pseudo-bulbar palsy in motor neurone disease, or as an effect of bilateral pyramidal damage from cerebrovascular disease. It may also be occasionally observed in disseminated sclerosis. In such cases the patient, if capable of introspection, and able to communicate, will almost always describe an appropriate mood with excessive and uncontrollable expression. At other times 'forced weeping' will be manifest, associated with sadness, but of a degree that would not ordinarily have occasioned tears. In both instances the sufferer is aware of, and usually embarrassed by, the discrepancy. In other cases,

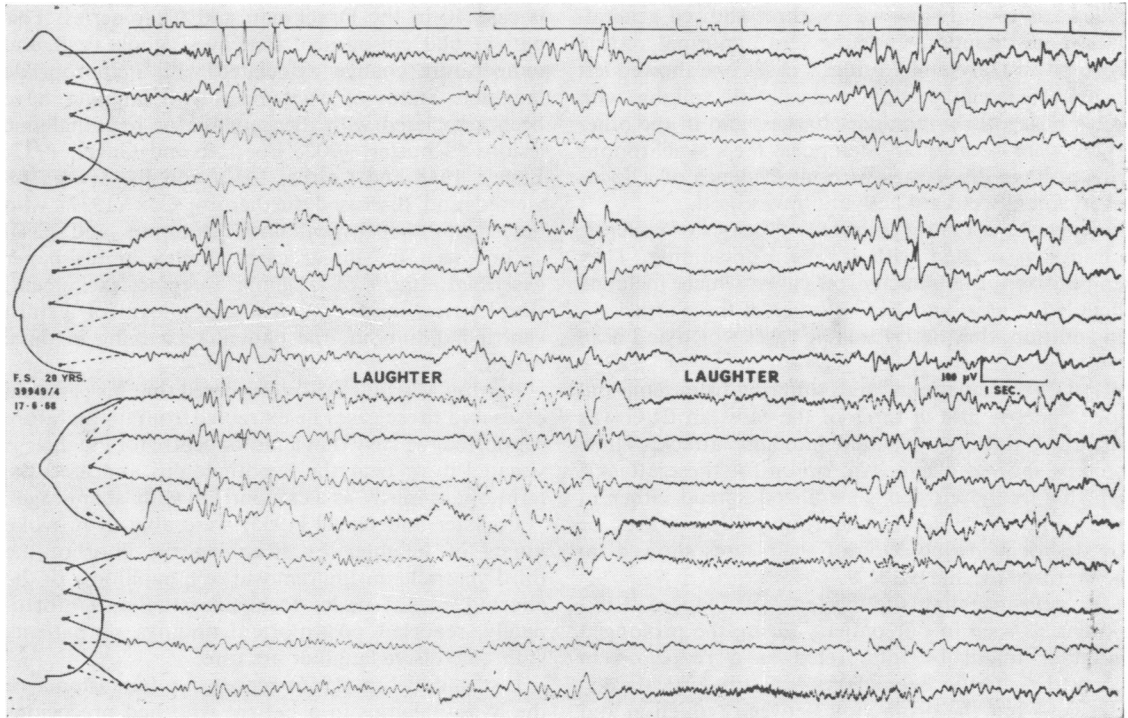


FIG. An EEG of the patient in gelastic status epilepticus

however, there would be an episode of laughter without any associated change of mood and this involuntary laughter may continue for hours or days as in the case of Meige and Béhague (1919). One such patient, a young nurse, in apparently normal health, suddenly began to laugh without reason and continued to do so incessantly for many hours, when there was an equally abrupt cessation and she was able to describe the involuntary character of the episode. She was by this time seriously exhausted. Subsequently she developed a typical clinical picture of disseminated sclerosis (Symonds, 1969).

The possible epileptiform nature of some laughter is indicated by the absence of appropriate precipitation, by the nature of the laughter, by concomitant epileptiform manifestations, and by the response to anti-convulsant drugs.

In our case the attacks were stereotyped and repetitive. The onset was abrupt with associated arm movements, head turning, and increased tone on the right. No precipitating factors were discovered. The high, cackling, monotonous laugh was unusual and was not infectious. She was unresponsive during laughter and seemed to fulfil all the necessary criteria of gelastic epilepsy. The fact that non-

soporific doses of phenytoin sodium (Epanutin) may stop the laughing attacks has been taken as evidence of their epileptic nature, but clearly the tranquillizing effect of such drugs may be important. In our case intravenous diazepam (Valium) terminated the attacks. The increased tone seen during these attacks contrasts with the reduced tone noted during laughter in normal patients by Paskind (1932).

The pyrexia which was noted in our patient before the episode of laughing epilepsy might be taken as evidence of a diencephalic origin for the attacks. No cause of the pyrexia was discovered and it was always recorded in the pre-ictal phase. However, it could clearly have precipitated the attacks without actually being part of them.

EEG FINDINGS In our case there was conspicuous absence of electrical activity during the laughter attacks and similar features have been noted by Druckman and Chao (1955) in one of their cases and by Roger, Lob, Waltregny, and Gastaut (1967) in one of their cases. Four of the cases reported by Gibbs and Gibbs (1952) showed 14 c/s and 6 c/s positive spike patterns and one showed a temporal focus. Two of the Druckman and Chao cases showed hypsarrhythmic features, four showed right-

sided spikes and slow waves, three showed generalized abnormalities, and one had a normal resting record. In Daly and Mulder's cases one showed left posterior irregular slow waves with spiking with 4 c/s bilateral rhythmic discharges, and in the other there were occasional bitemporal 6 c/s synchronous low voltage discharges without evidence of a focus even when Metrazol activation was used.

Roger *et al* (1967) collected 100 cases of epileptic attacks associated with laughter or smiling. They emphasized the paucity of cases which included detailed clinical and EEG studies of these attacks—in addition, they described five cases which had been personally observed.

All of these patients were suffering from temporal lobe epilepsy and in three of the cases an EEG was recorded during an actual laughing attack. These studies showed a temporal origin for these attacks, which rapidly showed generalized spread either in the form of bilateral synchronous slow waves or by desynchronizing. One of their cases showed no generalized discharge.

It may be that the periods of reduced EEG potentials seen in our patient during the prolonged laughter might be interpreted as a reduction in cortical activity secondary to sub-cortical discharges—but the distinction between reduction and suppression of cortical rhythms would probably require extensive depth electrode recording. Reduced cortical voltages are, of course, well recognized in temporal lobe attacks. There are no consistent EEG correlates associated with the reported cases of gelastic epilepsy. Some of the records are consistent with sub-cortical discharges and some show cortical features. The recent experimental work with monkeys (Wilder, King, and Schmidt, 1969) on cortical and sub-cortical epileptogenesis adds interest to this apparent discrepancy.

HYPOTHESIS On the slim evidence available, there has been a great deal of speculation on the neurological mechanisms of laughter. Earlier studies were those of Oppenheim and Siemerling (1886), Nothnagel (1899), and Brissaud (1895). Kinnier Wilson (1924) wrote a paper on 'Pathological laughing and crying' and in it he postulated a facio-respiratory centre under voluntary and involuntary control, using the work of W. Spencer in 1894.

Davison and Kelman in 1939 described 33 necropsies from 53 cases of pathological laughter or crying. They concluded that the hypothalamic or some other nuclei under voluntary control were the main centres for the release of affective responses.

The quality of the epileptic attacks has also been taken as evidence of a diencephalic origin. The example usually quoted to add weight to this theory

is case 10 in the Druckman and Chao series. This patient had episodes of sleepiness, goose flesh, and temperature change associated with inappropriate laughter. States of excitement with laughter have been associated with diencephalic or hypothalamic lesions (Schuster, 1902; Foerster and Gagel, 1933; Bailey, 1948 and Cairns, 1952) and these were reviewed and discussed further by Cox (1937) who described other hypothalamic tumours and basal lesions seen in similar cases. Bailey in his paper described attacks of laughing, weeping, excitement, sleeplessness, and pyrexia after removal of a third ventricular tumour, the patient recovering in three weeks.

Purdon Martin (1950) considered that his personal cases and those cases he extracted from the literature supported the view that a motor centre for laughter is situated in or near the hypothalamus and used the term 'sham-mirth' as a comparison with 'sham-rage'.

Foerster and Gagel (1933) were able to provoke bursts of laughter by swabbing the floor of the third ventricle during removal of a papilloma of the choroid plexus under local anaesthesia. Unfortunately, reported post-mortem findings on patients with convulsive laughter are rare.

List and Bebin (1956) reported a hamartoma of the hypothalamus in a patient who had precocious puberty associated with laughing attacks.

Purdon Martin (1950) described a patient who died soon after the onset of fits of laughter. Necropsy showed a ruptured basal aneurysm involving the corpora mamillaria.

From the work described it would, therefore, seem reasonable to say that to date the hypothalamic region is thought to be important in many of the reported cases of emotional disturbance and epileptic laughter. However, in Meige and Béhague's case a shell splinter was removed from the right parietal region. A large traumatic subdural haematoma was found and it is suggested that raised intracranial pressure could have damaged the deep midline structures.

Case 2 of Daly and Mulder's cases had a left temporo-occipital oligodendroglioma removed. The recent work of Wilder on monkeys raised the possibility that local cortical lesions could cause mid-brain focal lesions before the production of mirror foci, and it is suggested that this may be how those reports of epileptic laughter caused by local cortical lesions may be related to those cases with lesions in the hypothalamic region.

There is no doubt that some evidence of brain damage seems to be the usual accompaniment of epileptic laughter. In our personal case the scored intelligence quotient (WISC) showed a fall in four years from 86 to 71. We know that our patient

developed normally until the age of 5 and Druckman and Chao record that all their patients were thought to have symptomatic rather than idiopathic or genetic epilepsy. In our case there was no clear evidence of a hypothalamic lesion, but one could speculate upon the association of retinitis pigmentosa and the Lawrence-Moon-Biedl syndrome.

We are grateful to Dr. Ross Russell for permission to study this patient, We would especially like to thank Sir Charles Symonds for his persistent encouragement and help.

REFERENCES

- Andersen, C. (1936). Crise de rire spasmodique avant décès: Hémorragie thalamique double. *J. belge Neurol. Psychiat.*, **36**, 223-227.
- Badt, B. (1927). Lachen als erstes Symptom eines apoplektischen Insultes. *Z. Neurol. Psychiat.*, **110**, 297-300.
- Bailey, P. (1948). *Intracranial Tumours*, 2nd edn. Springfield; Illinois, p. 134.
- Brissaud, E. (1895). *Leçons sur les maladies nerveuses (Salpêtrière, 1893-94)*. Masson: Paris.
- Cairns, H. (1952). Disturbances of consciousness with lesions of the brain-stem and diencephalon. *Brain*, **75**, 109-146.
- Cox, L. B. (1937). Tumours of the base of the brain: their relation to pathological sleep and other changes in the conscious state. *Med. J. Aust.*, **1**, 742-752.
- Daly, D. D., and Mulder, D. W. (1957). Gelastic epilepsy. *Neurology (Minneapolis)*, **7**, 189-192.
- Davison, C., and Keiman, H. (1939). Pathological laughing and crying. *Arch. Neurol. Psychiat. (Chic.)*, **42**, 595-643.
- Druckman, R., and Chao, D. (1955). Massive spasms in infancy and childhood. *Epilepsia (Amst.)*, **4**, 61-72.
- Druckman, R., and Chao, D. (1957). Laughter in epilepsy. *Neurology (Minneapolis)*, **7**, 26-36.
- Féré, C. (1898). Accès de rire chez un épileptique. *C.R. Soc. Biol. (Paris)*, **50**, 430.
- Féré, C. (1903). Le fou rire prodromique. *Rev. neurol.*, **11**, 353-358.
- Foerster, O., and Gagel, O. (1933). Ein Fall von Ependymcyste des III Ventrikels: Ein Beitrag zur Frage der Beziehungen psychischer Störungen zum Hirnstamm. *Z. Neurol. Psychiat.*, **149**, 312-344.
- Frigerio, L. (1899). Riso spasmodico automatico accessionale in un epilettico. *Arch. Psychiat.*, **1**, 305; *Arch de Psich, sc. penali ed antrop. crim.*, **20**, 305.
- Gibbs, F. A., and Gibbs, E. L. (1952). *Atlas of Electroencephalography. Vol. 2. Epilepsy*. Addison-Wesley: Cambridge, pp. 167, 332.
- Jaros, O. (1968). Das Epileptische Lachen. Nervenabt., Militär Krankenh., Jaromer. *Sborn. věd. Práci Lék. Fak. Hradci Králové*, **11/1** 85-90.
- Jewesbury, E. C. O. (1954). Some clinical epileptic oddities. *Brit. med. J.*, **2**, 1518-1520.
- Clark, W. E. Le Gros., Beattie, J., Riddoch, G., Dott, N. M. (1938). *The Hypothalamus*, p. 179. Oliver and Boyd: Edinburgh.
- List, C. F., and Bebin, J. (1956). Hamartoma of the hypothalamus causing a syndrome of precocious puberty and petit mal epilepsy with paroxysmal laughter. Presented to the American Academy of Neurology. April 26.
- Martin, J. P. (1950). Fits of laughter (sham-mirth) in organic cerebral disease. *Brain*, **73**, 453-464.
- Meige, H., and Béhague, P. (1919). Troubles épileptiques chez un blessé du crâne précédés d'une turgescence douloureuse de la brèche et s'accompagnant de rire incoercible. Possibilité d'un traitement préventif. *Rev. neurol.*, **36**, 585-587.
- Mills, C. K. (1912). The cerebral mechanism of emotional expression. *Trans. Coll. Physns. Philad.*, **34**, 147-178.
- Nothnagel, H. (1889). Zur Diagnose der Schügelkrankungen. *Z. klin. Med.*, **23**, 791-794.
- Oppenheim, H. and Siemerling, E. (1886). Mittheilungen über Pseudobulbärparalyse und acute Bulbärparalyse. *Berl. Klin. Wschr.*, **23**, 791-794.
- Oppenheim, H. (1889). Weitere Notizen zur Pathologie der disseminirten sklerose. *Charité-Ann.*, **14**, 412-418.
- Oppenheim, H. (1902). Ueber Lachschlag. (Lach-Schwindel. Lach-Ohnmacht). *Mtschr. Psychiat. Neurol.*, **11**, 241-247.
- Paskind, H. A. (1932). Effect of laughter on muscle tone. *Arch. Neurol. Psychiat. (Chic.)*, **28**, 623-628.
- Rogal, O. (1937). Lachanfalle als epileptisches Äquivalent. *Nervenarzt*, **10**, 93-95.
- Roger, J., Lob, H., Waltregny, A., and Gastaut, H. (1967). Attacks of epileptic laughter: on 5 cases. *Electroenceph. clin. Neurophysiol.*, **22**, 279.
- Roubíček, J. (1946). Laughter in epilepsy, with some general introductory notes. *J. ment. Sci.*, **92**, 734-755.
- Schuster, P. (1902). *Psychische Störungen bei Hirntumoren, Klinische und statistische Betrachtungen*. Enke: Stuttgart.
- Spencer, W. G. (1894). The effect produced upon respiration by faradic excitation of cerebrum in the monkey, dog, cat and rabbit. *Phil. Trans. B.*, **185**, 609-657.
- Symonds, C. P. (1969). Personal communication.
- Trousseau, A. (1873). *Clinique Médicale de l'Hôtel-Dieu de Paris*, 4th edit., Baillière: Paris. p. 109.
- Wilder, J. (1931). Zwangslachen mit Erektion als epileptisches Äquivalent (nebst Beobachtungen über Beziehungen von Erektionen zum Fliegen.). *Nervenarzt*, **4**, 75-83.
- Wilder, B. J., King, R. L., and Schmidt, R. P. (1969). Cortical and subcortical secondary epileptogenesis. *Neurology (Minneapolis)*, **19**, 643-652.
- Wilson, S. A. K. (1924). Pathological laughing and crying. *J. Neurol. Psychopath.*, **4**, 299-333.
- Wilson, S. A. K. (1935). The Epilepsies, in *Handbuch der Neurologie*, Vol. 17, p. 1. Edited by O. Bumke and O. Foerster. Springer: Berlin.