

Released involuntary laughter after temporal lobe infarction

MICHAEL SWASH

*From the Department of Neurology, Section of Neurological Sciences,
The London Hospital, London*

SUMMARY A case of sustained involuntary laughter is described, with accompanying alteration of mood, due to infarction of the inferior and lateral aspects of the left temporal lobe. The lesion was localized by the clinical findings, by electroencephalography, by a radioisotope brain scan, and by angiography. The problem of the neurology of emotional behaviour is discussed in the context of the localization of the lesion in this case.

Changes in emotional state are common in neurological disease but involuntary laughter occurring either as an epileptic event (gelastic epilepsy) or as a released phenomenon in destructive lesions is very rare. Gumpert, Hansotia, and Upton (1970) have recently described one further case of gelastic epilepsy and have reviewed some of the previously reported instances of pathological laughter. They were unable to draw any firm conclusions about the nature of the underlying mechanisms responsible for the production of laughter in their patient, although they thought that a hypothalamic lesion was the most likely cause.

It is the purpose of this paper to present a case of sustained involuntary laughter, with accompanying alteration of mood, due to left temporal lobe infarction.

CASE REPORT

Mrs. D.E.G. (LH 31891/57), aged 45 years, was admitted to the London Hospital as an emergency. She had been well until the evening before admission when she suddenly began to laugh. Her laughter was loud and continuous and although it was obviously inappropriate it seemed, in itself, to be like her usual laughter, so that her husband thought, at first, that something had amused her. However, she continued laughing and was unable to stand unaided or use her right arm to support herself. During the first hour her right arm flung wildly about in the air. She laughed almost continuously for the first three hours, with pauses only to draw breath, but then her laughter gradually subsided and was replaced by frequent giggles, low laughs, grimaces, and smiles so

that she seemed to be continuously muttering and laughing to herself. In this state loud laughter occurred in response to any environmental stimulus. Any attempt at conversation, or even the noise of a door slamming, induced a burst of loud, natural-sounding laughter which often continued for five or 10 minutes. She seemed to understand what was said to her but her own speech was jumbled and incomprehensible, and when asked to write down what she wanted she wrote nonsense. During the night she was quiet, although her husband had difficulty in preparing her for sleep because of her noisy laughter. The next morning she woke at the usual time, but immediately began to laugh uncontrollably and with apparent amusement, and was brought to the hospital, still laughing and giggling.

There was no history of previous physical or psychiatric illness and there was no family history of vascular disease. Menstruation had ceased seven years previously.

On examination she was an obese woman lying on her right side in a generally flexed posture chuckling and laughing to herself in a natural but wholly inappropriate manner. Frequent noisy yawns interrupted her otherwise almost continual and often noisy laughter. She responded to simple questions by nodding or shaking her head and with louder and more prolonged laughter. Sometimes she muttered inaudibly. If left alone she became drowsy and drifted into a light sleep from which she could easily be awakened by calling her name. Her laughter was so natural and so apparently enjoyable that it provoked amusement and laughter among the physicians, nurses, and other patients who saw her, although it was plain to them that her laughter was both involuntary and pathological. Even her husband found it difficult not to laugh with her. She did not

make puns or jokes and there was no word association or flight of ideas.

She moved all limbs voluntarily and to command, but the right arm was consistently moved less than the left and the stretch reflexes were exaggerated in this limb. The right plantar response was extensor and the left flexor. There was a right facial weakness of supranuclear type which was less obvious during the almost continuous mimetic facial movement than during voluntary movement. She responded less well to painful stimuli in the right arm than elsewhere. The visual acuity was normal but there was a right upper quadrantic field defect to confrontation with bilateral, simultaneously presented, stimuli. The pupils were normal. The general examination was within normal limits and the blood pressure was 115/75 mm Hg.

By the third day she was improved and could sit out in a chair. However, even at rest she still smiled and chuckled to herself without apparent cause and when her attention was attracted by auditory or visual stimuli she burst into prolonged and hearty laughter. Each laugh seemed to precipitate another, so that louder and longer peals of laughter succeeded each other, speech was impossible, and her whole body seemed to be taken up with laughter and respiration. It was possible, however, to modify the degree of her mirth. Even a faint smile from the examiner provoked instant violent laughter but these outbursts could be slowly and partially suppressed by a serious or factual question or by an emotionless expression on the part of the examiner. She could not voluntarily suppress her laughter as when requested to 'stop laughing'. Such commands only increased the laughter. Her laughter was always accompanied by reddening of the face, an alteration of facial expression, by hand and arm movement, and sometimes by tear formation appropriate to the degree of mirth. During these episodes of laughter she would sometimes say 'funny, funny'. Inappropriate crying, fear, or anger were not observed at this or any other time in her illness.

She was unable to describe the events of her illness or to talk about her home and although she responded to simple commands she failed to perform two-stage requests. Perseveration, both of speech and of gesture, was very marked and normal prosody was lost. She often spoke spontaneously, but in a soft mumbling voice, and her speech contained frequent neologisms and repeated meaningless phrases. She could not repeat simple phrases either verbally or in writing. There was a severe naming defect both to visual and tactile tests, although it was clear that she knew the use of the objects presented. There was no echolalia. Calculations were performed inaccurately, but not out of proportion to the degree of aphasia, and there was no significant left-right disorientation. During reading aloud neologisms and perseveration were prominent and comprehension was very poor.

Writing of remembered material—for example, her address—and of copied sentences showed similar errors. There was no gross limb apraxia or agnosia.

A right upper quadrantic visual field defect persisted and she often neglected right-sided visual and auditory stimuli. There was a mild right hemiparesis, most marked in face and shoulder, and the right-sided stretch reflexes were brisk. The right plantar response was extensor. There was impairment to all sensory modalities in the right limbs but perseveration and aphasia made detailed examination impossible.

The skull and chest radiographs and routine haematological and urine tests were normal. An electroencephalogram showed poorly organized background activity bilaterally and a focus of theta and delta activity in the left fronto-temporal region. The brain scan (Tc99m) showed increased uptake of radioisotope in the deep and inferior aspects of the left temporal region (Figure) but an echoencephalogram showed no shift of the midline echoes from the acoustical midline. A left carotid angiogram, performed by left common carotid puncture, showed deformation of the stream of contrast medium by atheroma at the carotid bifurcation and reduction of the flow of contrast in the territory of an insular and an anterior temporal branch of the left middle cerebral artery (Dr. Leon Morris). Only the origin and proximal part of the anterior temporal vessel could be seen and filling of its terminal branches occurred retrogradely through leptomeningeal anastomotic vessels. The CSF was clear and colourless and contained 30 mg protein/100 ml. The WR was negative in both blood and CSF. The serum uric acid and an oral glucose tolerance test were normal.

PROGRESS Improvement continued during the next month, although throughout this time prolonged bursts of loud, inappropriate laughter could be elicited by sympathetic smiles or by slightly humorous stimuli presented either visually or verbally. She continued to smile and chuckle to herself without apparent cause but this phenomenon gradually became less evident. On questioning she admitted that her laughter was abnormal but could not explain what it was that she found amusing or why she laughed so easily. She was adamant that she was actually amused during the act of laughing. She was rarely downcast and was never seen to be depressed, or to cry, or weep, although she clearly understood that she had had a stroke.

Six weeks after the onset of her illness she returned from convalescence. She remembered and described the period of continuous laughter in detail and with amusement, although she realized that it was abnormal. She still laughed suddenly and too easily but was able to control these outbursts by a conscious effort. She had had no visual or auditory hallucinations. She was aware that her speech was still not

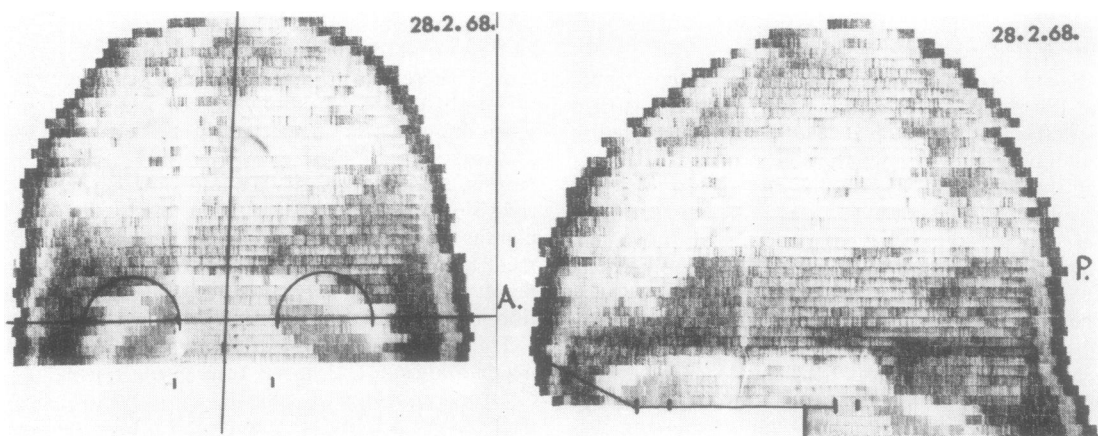


FIGURE *Left lateral and AP radioisotope brain scan, showing an area of increased uptake of isotope in the lateral, anterior, and inferior aspects of the left temporal region.*

normal. On examination she was euphoric and humourous and speech was frequently interrupted by sudden and often unexpected bursts of laughter which were quickly and voluntarily inhibited. She was still easily distracted by random events in her environment and she was unable to attend to any task for more than a minute or so. The resultant sudden changes of attention were particularly likely to be accompanied by a burst of laughter. There was a mild residual aphasia and the right upper quadrant visual field defect and the mild right-sided signs persisted.

The electroencephalogram was improved but showed similar abnormalities to the previous recording. A repeat left carotid angiogram again showed a paucity of vessels in the left anterior temporal region, but collateral and anastomotic vessels were more extensive. The radioisotope brain scan still showed increased uptake of isotope in the left inferior temporal region but a third scan performed four months after the first showed less uptake in this region, and this seemed compatible with the diagnosis of cerebral infarction.

At home she was at first unable to do much housework and was embarrassed by her tendency to laugh at inappropriate moments, but a year later she had taken part time employment as a packer on an assembly line. At this time she still had some difficulty performing fine coordinated tasks with her right hand and her friends still noticed that she laughed too easily.

DISCUSSION

The clinical evidence strongly supports a diagnosis of infarction of the lateral and inferior aspects of the left temporal lobe and its underlying white

matter, extending into the hemisphere as far as the genu of the internal capsule. The significance of the flinging movements of the right arm at the onset of the illness is uncertain. There was no evidence, from the clinical information, of any other lesion in the nervous system. Her laughter was neither epileptic nor part of an epileptic aura. There was no history of cyclic variations in mood and the clinical features of her laughter were unlike those found in psychiatric disease.

In our patient the lesion was left sided. Poeck and Pilleri (1963) found a left-sided lesion in six patients and a right-sided lesion in four patients with pathological laughing and crying who were shown, at necropsy, to have single lesions in the nervous system. In all their cases the lesion was subcortical, extending into the anterior limb of the internal capsule together, in three cases, with the adjacent caudate nucleus, in four with the left putamen, in four with the left claustrum and the external and extreme capsules, and in three with insular cortex. The hypothalamus and brain-stem were spared in all their cases. Poeck (1969) has not observed pathological laughter or crying with a single circumscribed cortical lesion and this experience is in accord with the clinical evidence of infarction extending from temporal cortex to internal capsule in our patient. The relative sparing of right facial movement during smiling and laughing may have an anatomical explanation, since the lesion must have spared the central fibres subserving this emotional movement. These fibres are thought to travel through the thalamus (Monrad-Krohn, 1924), and not through the internal capsule, and there-

fore this finding may be further evidence that the thalamus was not involved in the lesion.

Involuntary laughter may occur as a released phenomenon with destructive lesions or as part of an epileptic discharge (gelastic epilepsy). Thus it is commonly released in pseudobulbar states and very rarely as a prodrome of cerebral haemorrhage or infarction. It is extremely rare for it to occur as a released phenomenon with single cerebral lesions, as in our patient. Laughter may also be released after prefrontal lobotomy (Kramer, 1954), and in psychiatric disorder when it is part of a more generalized disturbance of function. These various categories of involuntary laughter will be discussed briefly.

Released involuntary laughter, usually accompanied by involuntary weeping and crying, is a common finding in patients with diffuse or multifocal lesions in cerebral hemispheres or brain-stem. It is usually taken to indicate bilateral lesions. The laughing and weeping may occur spontaneously or as an exaggerated response to a minor stimulus and it is usually obvious from the quality, intensity, and duration of the response that it is pathological, so that it only rarely stimulates similar emotions in experienced observers.

Released involuntary laughter may occur as a prodrome of cerebral haemorrhage or infarction. Féré's (1903) patient was a 64 year old man who laughed suddenly and loudly for several minutes without cause on several occasions and after one such attack had a left hemiplegia. During the remaining 18 months of life he had no further attacks of laughter. Badt (1927) and Andersen (1936) have described similar instances of pathological laughter occurring with fatal haemorrhage into both thalami and both internal capsules. Martin (1950) described a patient with a large aneurysm of the basilar artery which deformed the upper brain-stem and the posterior part of the third ventricle whose death from rupture of the aneurysm was preceded by an attack of prolonged laughter.

Involuntary laughter may also occur as a released phenomenon after a single cerebral infarct, but this is extremely rare (Poecck and Pilleri, 1969). Ironside (1956) described a patient with cerebral vascular disease whose third stroke was heralded by a sudden feeling of dizziness after which she laughed continuously for three hours. She was then found to have a right hemiparesis with aphasia. The tendency to laughter persisted as an immoderately easily induced

alteration of emotional state without weeping or crying for the remainder of the patient's life, and she remained incontinent and demented with a double hemiplegia until her death some months later. Post mortem examination was not performed but it is clear from the clinical description that this patient had multiple, bilateral cerebral infarcts and, although Ironside regarded the case as an example of 'le fou rire prodromique' (Féré, 1903), it is difficult to exclude a pseudobulbar cause for the laughter. Our patient, however, is an example of the extremely rare phenomenon of released laughter occurring as a sequel to a single cerebral lesion.

Gelastic epilepsy is a rare phenomenon and its pathophysiology is not understood. Some of the reported cases have been associated with temporal lobe tumours (Daly and Mulder, 1958) or with temporal EEG discharges both in the resting record and actually during the attacks of laughter (Weil, Nosik, and Demmy, 1958; Roger, Lob, Waltregny, and Gastaut, 1967), but suppression of paroxysmal EEG activity during the attacks has also been observed (Druckman and Chao, 1955; Gumpert *et al.*, 1970). In patients with temporal lobe epilepsy ictal laughter is very rare (Daly, 1958; Weil, 1959) but sensations of ictal pleasure, without laughter, occur more frequently, and feelings of fear or anger are quite common (Williams, 1956; Currie, Heathfield, Henson, and Scott, 1971). Penfield and Jasper (1954) never observed laughter during their experiments with electrical stimulation of the human cerebral cortex, but Sem-Jacobsen and Torkildsen (1960) reported smiling accompanied by a feeling of joy, and, in one case, laughter, when stimulating a temporal lobe.

Other clinical reports of epileptic laughter have described lesions in the basal ganglia, in the hypothalamic region and in the walls of the third ventricle. These reports have been discussed in some detail by Ironside (1956) and more recently by Gumpert *et al.* (1970) and by Gascon and Lombroso (1971). Many of the reports of laughter occurring with hypothalamic disorders cited by these authors, and a case of laughter caused by surgical manipulation of the walls of the third ventricle (Foerster and Gagel, 1933), have described states of excitement, depression, fear, and anger as well as outbursts of laughter. These symptoms are, perhaps, more closely related to pseudobulbar laughing and crying than to gelastic epilepsy.

Released laughter occurring after prefrontal

lobotomy (Kramer, 1954) is pathological in the sense that it is abnormal but is not involuntary since it is always the result of stimulation, either internal or from the environment. It is always accompanied by a sense of amusement. Laughter as a symptom of psychiatric disorder is similar to that occurring after prefrontal lobotomy and can be distinguished from involuntary laughter due to neurological disease by the presence of thought disorder or flight of ideas and by the characteristic accompanying disorder of affect and behaviour. Focal neurological signs are not present in such cases.

The localization of lesions responsible for both released and epileptic involuntary laughter has excited considerable interest. While hypothalamic lesions may release involuntary laughter, as the review of Gumpert *et al.* (1970) confirms, Ironside (1956), who himself thought that the role of the hypothalamus in emotional disorders had been underestimated, was careful to point out that such disorders could be released or could occur as epileptic phenomena with lesions both at lower and higher levels in the nervous system. Alpers (1940) commented similarly that the hypothalamus is only one of a series of stations concerned with the control of emotional feeling and behaviour. Nonetheless the hypothalamus has come to be regarded as of special importance in this regard (Masserman, 1941). The evidence for this view rests largely upon descriptions of cases of released or ictal laughter associated with tumours or haemorrhages in this region. Caution must, however, be exercised when interpreting the localization of disorders of function in such cases, since it is not usually possible to state with certainty that the disordered function was released as a consequence of destruction of tissue by the tumour itself, or because of surrounding oedema, infiltration, or displacement of nearby structures by the tumour. The cases of hypothalamic tumour with ictal laughter and precocious puberty described by Dott (1938) and List, Dowman, Bagchi, and Bebin (1956) cited by Ironside (1956) and by Gumpert *et al.* (1970) are open to this criticism and the point is further exemplified by the case of Wood, Svien, and Daly (1958). In this latter patient gelastic epilepsy occurred in association with a neurofibroma of the trigeminal nerve which had deformed the inferomedial aspect of the left temporal lobe, the hypothalamus and other basal structures.

Although in other cases of involuntary

laughter there was no accompanying change of emotional feeling (Martin, 1950; Wood *et al.*, 1958) our patient always experienced an appropriate alteration of mood during her involuntary laughter, smiling and chuckling. In pseudobulbar disorders some patients with involuntary laughter experience an accompanying change in emotional feeling but others do not (Ironside, 1956). In temporal lobe epilepsy ictal changes in emotional expression, with accompanying changes in affect, occur relatively frequently and Sem-Jacobsen and Torkildsen (1960) have recorded feelings of joy accompanying the smiling and laughter induced by electrical stimulation of the human temporal lobe. In destructive cerebral lesions the association of a sense of amusement or joy with involuntary laughter, or the lack of it, is likely to be dependent on the location of the lesion or lesions responsible. Such an association seems more likely to occur if functional temporal connections with deeper structures are maintained and in our case, for example, there is evidence that the thalamus was not involved in the lesion. It is clear from the cases of involuntary laughter cited from the literature that patients with lesions in thalamus, hypothalamus, or brain-stem do not usually experience an accompanying sense of amusement or joy, but when involuntary laughter occurs with lesions in the temporal lobe, as in temporal lobe epilepsy, a feeling of amusement is more likely to accompany it.

Klüver and Bucy (1939) noticed that the normal emotional reactions of fear and anger were absent in the monkey after bilateral temporal lobe excision, although they, and others (Horenstein and Conomy, 1969), have not observed such changes after unilateral temporal lobectomy. In man bilateral temporal lobectomy has produced a similar psychological disorder to that observed in the monkey (Terzian and Ore, 1969). Infarction of the inferior surface of both temporal lobes and of the underlying white matter in man gives rise to a state of agitated delirium with visual agnosia, compulsive oral tendencies, and reduced emotional responses, although pseudobulbar laughing and crying occurred when the lesions were more extensive (Horenstein, Chamberlin, and Conomy, 1967). This syndrome must clearly be related to the Klüver-Bucy syndrome as observed in monkeys.

Papez (1937) and MacLean (1955) have discussed the role of the temporal lobe, and of the limbic system of which it is a part, in the control

of emotional feeling and behaviour. In their scheme the temporal lobes act as higher integrating cortex within the limbic apparatus and are closely connected through this system with the hypothalamic, cingulate, and brain-stem pathways which have themselves been the site of lesions in the cases of involuntary laughter discussed above and in the reviews of Ironside (1956), Gumpert *et al.* (1970), and Gascon and Lombroso (1971). Smythies (1970) has recently reviewed the anatomical and physiological evidence for this role of the limbic system in the control of emotional and other behaviour in man.

The precise localization of lesions causing released laughter without accompanying crying, fear, or anger is uncertain, but there is some evidence (see Smythies, 1970) that lesions in the most medial part of the inferior aspect of temporal lobe are more likely to produce this isolated functional disorder. The clinical information in our case is not sufficient to allow such precise localization, although the role of the temporal lobe is clearly demonstrated.

I would like to thank Dr. R. A. Henson for allowing me to report this patient, who was under his care, and Dr. D. F. Scott for critically reviewing the manuscript.

REFERENCES

- Alpers, B. J. (1940). Personality and emotional disorders associated with hypothalamic lesions. In *The Hypothalamus. Proceedings of the Association for Research in Nervous and Mental Diseases*, **20**, 725-752.
- Andersen, Ch. (1936). Crise de rire spasmodique avant décès: hémorragie thalamique double. *Journal Belge de Neurologie et de Psychiatrie*, **36**, 223-227.
- Badt, B. (1927). Lachen als erstes Symptom eines apoplektischen Insultes. *Zeitschrift für die gesamte Neurologie und Psychiatrie*, **110**, 297-300.
- Currie, S., Heathfield, K. W. G., Henson, R. A., and Scott, D. F. (1971). Clinical course and prognosis of temporal lobe epilepsy. A survey of 666 patients. *Brain*, **94**, 173-190.
- Daly, D. D. (1958). Uncinate fits. *Neurology*, **8**, 250-260.
- Daly, D. D., and Mulder, D. W. (1957). Gelastic epilepsy. *Neurology*, **7**, 189-192.
- Davison, C., and Kelman, H. (1939). Pathologic laughing and crying. *Archives of Neurology and Psychiatry*, **42**, 595-643.
- Dott, N. M. (1938). Surgical aspects of the hypothalamus. In *The Hypothalamus, Morphological, Functional, Clinical and Surgical Aspects*, pp. 179-181. Edited by W. E. Clark, Beattie, J., Le Gros, G. Riddoch, and N. M. Dott. Oliver and Boyd: Edinburgh.
- Druckman, R., and Chao, D. (1957). Laughter in epilepsy. *Neurology*, **7**, 26-36.
- Féré, Ch. (1903). Le fou rire prodromique. *Revue Neurologique*, **11**, 353-358.
- Gascon, G. G., and Lombroso, C. T. (1971). Epileptic (gelastic) laughter. *Epilepsia*, **12**, 63-76.
- Gumpert, J., Hansotia, P., and Upton, A. (1970). Gelastic epilepsy. *Journal of Neurology, Neurosurgery, and Psychiatry*, **33**, 479-483.
- Horenstein, S., Chamberlin, W., and Conomy, J. P. (1967). Infarction of the fusiform and calcarine regions: agitated delirium and hemianopia. *Transactions of the American Neurological Association*, **92**, 85-89.
- Horenstein, S., and Conomy, J. P. (1969). Oral prehension and impaired visual discrimination after basal temporal lobectomy. *Transactions of the American Neurological Association*, **94**, 279-282.
- Ironside, R. (1956). Disorders of laughter due to brain lesions. *Brain*, **79**, 589-609.
- Kramer, H. C. (1954). Laughing spells in patients, after lobotomy. *Journal of Nervous and Mental Diseases*, **119**, 517-522.
- Klüver, H., and Bucy, P. C. (1939). Preliminary analysis of functions of the temporal lobes in monkeys. *Archives of Neurology and Psychiatry*, **42**, 979-1000.
- List, C. F., Dowman, C. E., Bagchi, B. K., and Bebin, J. (1958). Posterior hypothalamic hamartomas and gangliogliomas causing precocious puberty. *Neurology*, **8**, 164-174.
- MacLean, P. D. (1955). The limbic system ('visceral brain') and emotional behavior. *Archives of Neurology and Psychiatry*, **73**, 130-134.
- Martin, J. P. (1950). Fits of laughter (sham mirth) in organic cerebral disease. *Brain*, **73**, 453-464.
- Masserman, J. H. (1941). Is the hypothalamus a center of emotion? *Psychosomatic Medicine*, **3**, 3-25.
- Monrad-Krohn, G. H. (1924). On the dissociation of voluntary and emotional innervation in facial paresis of central origin. *Brain*, **47**, 22-35.
- Papez, J. W. (1937). A proposed mechanism of emotion. *Archives of Neurology and Psychiatry*, **38**, 725-743.
- Penfield, W., and Jasper, H. H. (1954). *Epilepsy and the Functional Anatomy of the Human Brain*, pp. 141, 447-451. Little, Brown: Boston.
- Poeck, K. (1969). Pathophysiology of emotional disorders associated with brain damage. *Handbook of Clinical Neurology*, vol. 3, pp. 343-367. Edited by P. J. Vinken and G. W. Bruyn. North-Holland: Amsterdam.
- Poeck, K., and Pilleri, G. (1963). Pathologisches Lachen und Weinen. *Schweizer Archiv für Neurologie und Psychiatrie*, **92**, 323-370.
- Roger, J., Lob, H., Waltregny, A., and Gastaut, H. (1967). Attacks of epileptic laughter: on 5 cases. *Electroencephalography and Clinical Neurophysiology*, **22**, 279 (abstract).
- Sem-Jacobsen, C. W., and Torkildsen, A. (1960). Depth recording and electrical stimulation in the human brain. In *Electrical Studies on the Unanesthetized Brain*, pp. 275-290. Edited by E. R. Ramey and D. S. O'Doherty. Hoeber: New York.
- Smythies, J. R. (1970). *Brain Mechanisms and Behaviour*. 2nd Ed. Blackwell: Oxford.
- Terzian, H., and Ore, G. Dalle (1955). Syndrome of Klüver and Bucy reproduced in man by bilateral removal of the temporal lobes. *Neurology*, **5**, 373-380.
- Weil, A. A. (1959). Ictal emotions occurring in temporal lobe dysfunction. *Archives of Neurology*, **1**, 87-97.
- Weil, A. A., Nosik, W. A., and Demmy, N. (1958). Electroencephalographic correlation of laughing fits. *American Journal of Medical Science*, **235**, 301-308.
- Williams, D. (1956). The structure of emotions reflected in epileptic experiences. *Brain*, **79**, 29-67.
- Wood, M. W., Svien, H. J., and Daly, D. (1958). Involuntary laughter. *Proceedings of the Mayo Clinic*, **33**, 266-275.