

Axial enlargement of the 3rd ventricle, and displacement of the brain-stem in benign aqueduct stenosis

JAN JAKUBOWSKI AND ANTONY JEFFERSON

From the Department of Neurological Surgery, The Royal Infirmary, Sheffield

SUMMARY A personal series of 12 patients with benign aqueduct stenosis has been surveyed. A review of the radiographs has shown that in chronic aqueductal stenosis there is axial enlargement of the 3rd ventricle and displacement of the brain-stem. When these two features are pronounced, blockage of the basal cisterns will occur. We propose that when unsatisfactory flow of fluid through the basal cisterns may be inferred, then ventriculocisternostomy should be avoided. Evidence that the ventricular drainage is continuing satisfactorily after operation may be obtained either by echoencephalography, or by radiography, or by both means.

There is available an almost bewildering choice of surgical treatments for benign aqueduct stenosis. In 1936 Stookey and Scarff (see Scarff, 1963) reported transfrontal puncture of the lamina terminalis and the floor of the 3rd ventricle and this procedure remained the basis of their subsequent modifications. Torkildsen introduced his operation of ventriculocisternostomy in 1939 and it has been regarded by many (Fincher, Strewler, and Swanson, 1948; Herlin, 1950; Paine and McKissock, 1955) as the most effective method for the management of benign aqueduct stenosis. This view is still held by some authors (see Gröschel and Marguth, 1963; Nag and Falconer, 1966; Cantu, Michelson, and White, 1970). However, it should be remembered that Torkildsen's (1960) long-term follow-up of his own case material showed that only three of the original six patients with benign aqueduct stenosis were still alive. Pennybacker in 1940 reported 18 patients with aqueduct stenosis and discussed the merits of subtemporal decompression, cerebellar decompression, and various types of third ventriculostomy.

A new era in treating the hydrocephalus of benign aqueduct stenosis was opened by Nulsen and Spitz who described a shunting operation between the lateral ventricle and the right atrium, using a special valve designed by Holter. (In addition, various neurosurgeons have tried to connect the lateral ventricle with almost every physiological cavity. The results varied.)

Elvidge (1966) published 10 cases of aqueduct stenosis treated with third to fourth ventriculostomy by a short length of plastic tube pushed through the stenosed area. This method has never been widely adopted.

In this paper we wish briefly to present our own case material and to put forward some points which on theoretical grounds should allow one to choose whether to employ ventriculocisternostomy or to insert a ventriculoatrial shunt.

TABLE
AGE AND SEX OF PATIENTS IN SERIES

	Age (yr.)						No.
	0-1	2-10	11-20	21-30	31-40	41-50	
Male	0	0	2	1	0	1	4
Female	1	1	4	1	1	0	8
Totals	1	1	6	2	1	1	12

CASE MATERIAL

An unselected series of 12 patients with benign aqueduct stenosis treated mainly by one of us (A.J.) between 1956 and 1970 forms the basis of this study. The age and sex of the patients are listed in the Table.

The duration of the history varied between one month and more than five years. Two patients in this series died (one of infection, the other from a technical failure); the outcome in the other 10 patients has been excellent in nine, and satisfactory in one. For reasons which will be explained, we have had a bias in favour of the use of the shunt, and a

ventriculoatrial shunt has been employed in the management of 10 of these patients. For one of the two remaining cases the ventriculoatrial shunt was not available in Sheffield at the time the treatment was carried out; for the other, the diagnosis was in doubt and exploration of the posterior fossa was required.

In a minority of the patients, the initial treatment was not the definitive one. In two of them the valve assembly had to be removed because of infection, and a ventriculocisternostomy was then performed to take over the function of the failed shunt system. In one patient this exchange occurred after eight weeks and in the other after nine months. In one additional patient, admitted with gross axial 'dislocation' of the ventricular system, the shunt functioned inefficiently. (In retrospect the correct treatment would have been immediately to commence continuous ventricular drainage and then to replace the valve. In fact various decompressive operations were performed and the child eventually died.) In another child with considerable dilatation of the ventricular system and displacement of the 3rd ventricle posteriorly a Torkildsen operation was performed. This had to be replaced by ventriculoatrial shunt three weeks later.

RADIOLOGICAL FEATURES OF AXIAL ENLARGEMENT AND 'DISLOCATION' OF THE VENTRICULAR SYSTEM
We suggest that the following radiological features should be considered in every patient with benign aqueduct stenosis and we believe it helpful to consider the ventricular pattern in two categories:

1. 'UNDISLOCATED' VENTRICULAR SYSTEM In this category there is either no displacement (Fig. 1) or else only minimal displacement of the posterior end of the 3rd ventricle towards the foramen magnum (Fig. 2a). The degree of ventricular dilatation will vary both with the duration and the completeness of the aqueduct stenosis. When there is considerable ventricular enlargement, the antero-inferior limit of the 3rd ventricle bulges downwards into the suprasellar region (Fig. 2b).

2. 'DISLOCATED' VENTRICULAR SYSTEM The chief feature of this category is the pronounced axial displacement of the posterior end of the 3rd ventricle beneath the normal level of the tentorium (see Fig. 3, also Fig. 4) towards the foramen magnum. Associated with this one can usually observe varying degrees of enlargement and distortion of the posterior portion of the 3rd ventricle (see Fig. 4), also bulging of the

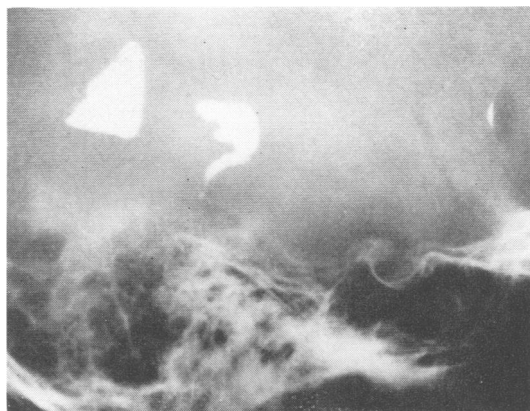

FIG. 1. Female, aged 25. Myodil ventriculogram, lateral projection. The posterior end of the aqueduct is blocked. The posterior end of the 3rd ventricle occupies a normal position, and there is only slight ventricular distension.

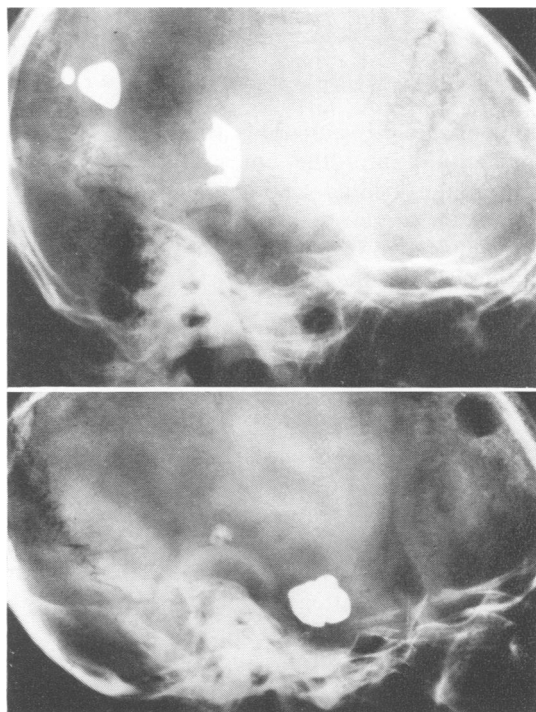


FIG. 2 a and b. Myodil ventriculograms, lateral projection. (a. above): Female, aged 10. The aqueduct is completely blocked. There is some enlargement of the 3rd ventricle together with minimal displacement of the posterior end of the 3rd ventricle towards the foramen magnum. (b. below): Male, aged 21. Considerable enlargement of the ventricular system. Antero-inferior limit of the 3rd ventricle is rounded and bulges downwards, almost reaching the pituitary fossa, which is somewhat enlarged.

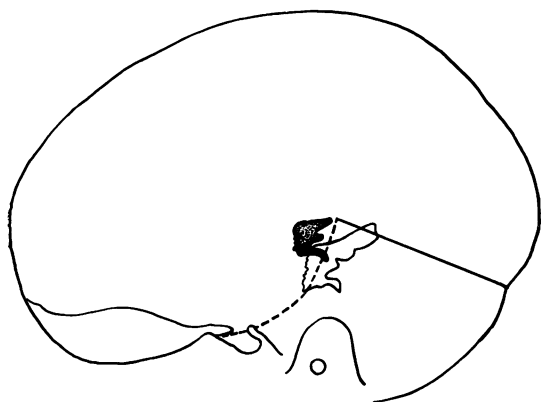


FIG. 3. Tracings of the posterior ends of the 3rd ventricle as seen in two patients with aqueduct stenosis. Both patients had a similarly shaped skull. The estimated position of the tentorium is marked. The stippled ventricle shows obstruction of the aqueduct with minimal distension and no displacement, whereas the unshaded ventricle is distended and displaced ('dislocated') postero-inferiorly towards the foramen magnum.

floor of the 3rd ventricle both into the pituitary fossa and into the interpeduncular cistern immediately behind the dorsum sellae (see Fig. 5).

In the most severe instances of 'dislocation' of the ventricular system there may be evidence of obliteration of the pontine cistern (Fig. 6a, b) or of severe tonsillar herniation (Fig. 7a, b).

One should be aware that the changes shown in Fig. 5 may be inferred from the plain radiographs of the skull. Figure 8 shows the four features which we regard as characteristic (see legend).

It is commonplace that benign aqueduct stenosis seldom involves a complete anatomical obstruction. This fact may be readily confirmed. For example, in Fig. 9 the obstruction appears complete, but after the establishment of a ventriculoatrial shunt some Myodil may be observed lying within the 4th ventricle. In another patient, who must have had a minimal anatomical obstruction, Myodil was initially completely unable to pass along the aqueduct. Twenty-four hours after ventricular puncture and before definitive surgery, it was demonstrated that the Myodil had reached the lumbar region.

Ventriculoatrial shunts, like all methods of ventricular drainage, are liable to failure. Thus it is essential to have some means of confirming that satisfactory relief of the obstruction has

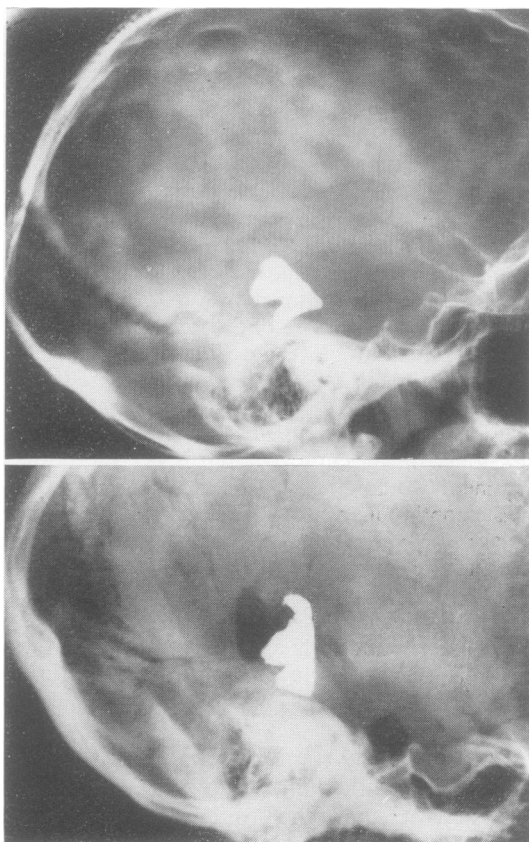


FIG. 4. Myodil ventriculograms, lateral projections. (a. above): Female, aged 11. Complete and long-standing aqueduct obstruction, gross enlargement of the ventricular system. Note the position of the posterior end of the 3rd ventricle which lies abnormally close to the foramen magnum. (b. below): Female, aged 16. A large degree of distortion and displacement of the posterior end of the 3rd ventricle. Note that in this case the upper part of the pontine cistern is preserved, but air (from a preceding pneumoencephalogram) did not ascend beyond this point.

occurred. If sufficient Myodil remains, one may compare the preoperative and postoperative appearances of the 3rd ventricle. Figure 10 illustrates this (see legend). Confirmation of this striking alteration of the 3rd ventricle was found in the anteroposterior projections, which showed that the width of the 3rd ventricle preoperatively was 16 mm as compared with 9 mm postoperatively.

For the long-term follow-up of the width of the 3rd ventricle, echoencephalography provides a more convenient alternative method. In the presence of severe hydrocephalus, additional (and perhaps confusing) echoes are common,

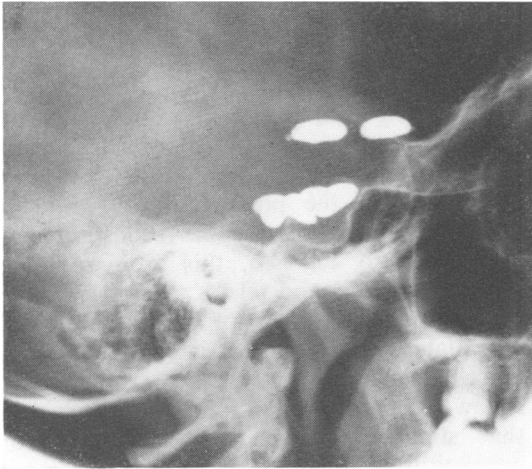


FIG. 5. Myodil ventriculogram, lateral projection. Same patient as Fig. 4a. The floor of the enlarged 3rd ventricle bulges fairly deeply into the pituitary fossa and lies against the shortened dorsum sellae. Note that the postero-inferior portion of the floor extends downwards behind the dorsum towards the clivus. The distended antero-inferior limit of the 3rd ventricle has eroded the region of the tuberculum sellae. The chiasmatic cistern must be obliterated, and the interpeduncular cistern must, at least, be diminished.

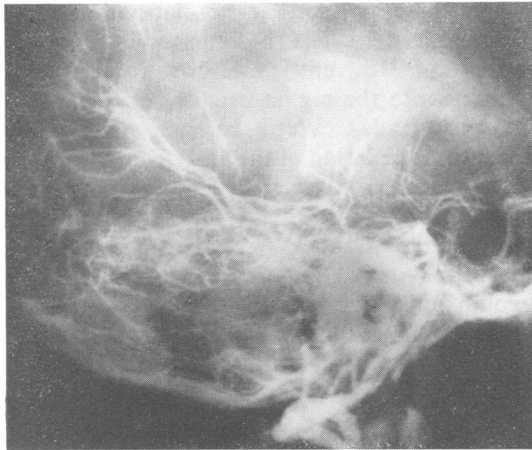
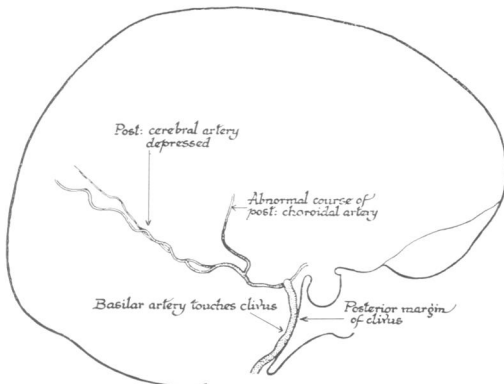


FIG. 6. Vertebral angiogram, lateral projection. Male, aged 12. Note that the pontine cistern is obliterated; the basilar artery touches the clivus. The posterior cerebral arteries are depressed. In consequence of the 'dislocation' of the brain-stem towards the foramen magnum, the posterior choroidal artery runs an abnormally vertical course.



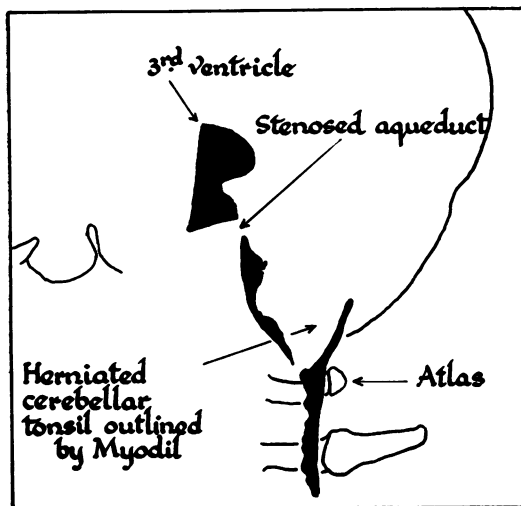
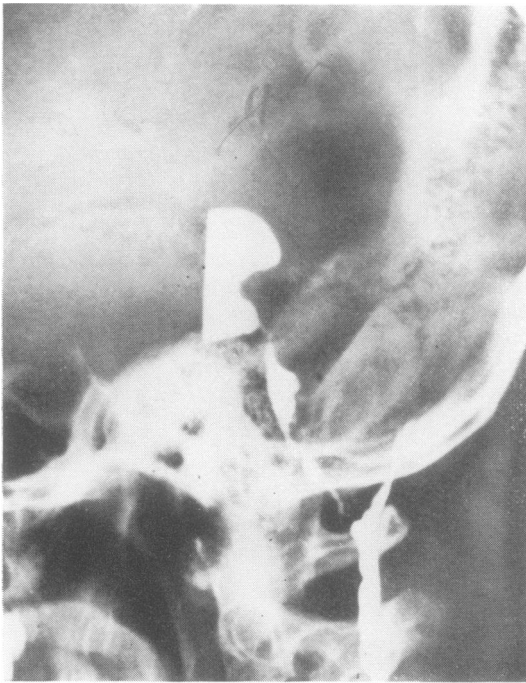


FIG. 7. Myodil ventriculogram, lateral projection. Enlargement and displacement of the posterior end of the 3rd ventricle, and evidence of tonsillar herniation in a patient with aqueduct stenosis. (This figure is reproduced from Jefferson, A. A., and Occlshaw, J. V. (1960). *Acta Neurochirurgica*, Vol. VIII, by kind permission of the publishers.)

but one can usually form a valid conclusion concerning the width of the 3rd ventricle and thus be able to detect resolution of an obstructive hydrocephalus (see Fig. 11).

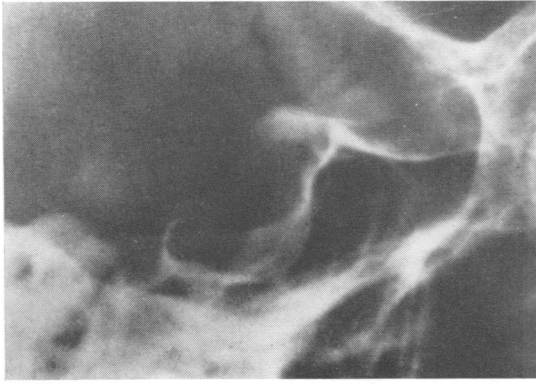As a long-term policy, there is one further means by which one may confirm the relief of the obstructive hydrocephalus. A true lateral radiograph of the pituitary fossa will show whether the sella has become reconstituted. To refer back to Fig. 8b, this radiograph was obtained in 1956 and relates to a girl who was then aged 11 years. Figure 12 was obtained 14 years later and shows considerable reconstructive changes. We have no systematic radiological follow-up of these patients, but we have evidence that similar, although less extensive, bony reconstitution occurred in two other patients.

With regard to the surgical management of this condition we would suggest that when the posterior end of the 3rd ventricle is significantly 'dislocated' towards the foramen magnum it is probably inappropriate to perform a ventriculocisternostomy. The decision to avoid this method of treatment would be strengthened when there is tonsillar herniation, when the pontine cistern has become obliterated, and when the 3rd ventricle shows a diverticulum bulging into the region usually occupied by the interpeduncular cistern. In such circumstances effective circulation of the CSF from the cisterna magna to the convexity of the hemispheres is unlikely to occur. In these cases either a ventriculoatrial shunt or perhaps a Stookey-Scarff operation would seem more appropriate. (We would add that these considerations can usefully be applied to the management of some other types of chronic obstructive hydrocephalus.)

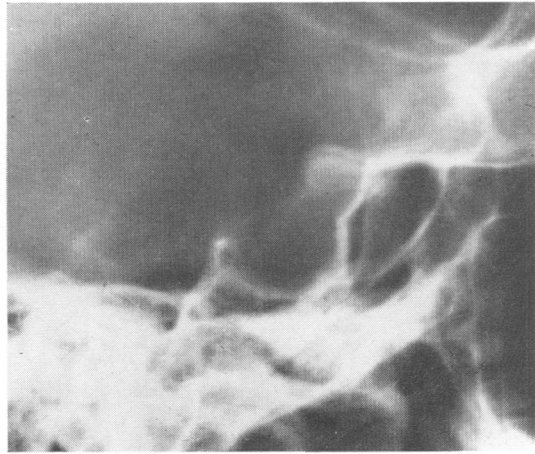
DISCUSSION

Cantu, Michelson, and White (1970) have recently stressed the importance of avoiding ventriculocisternostomy when the basal cisterns are obstructed. It will be noted that, in preferring ventriculocisternostomy to ventriculoatrial shunts, they found repeated lumbar punctures necessary in the postoperative management of several of their patients. Consideration of the anatomical changes seen in our Figs 6 and 7, makes us reluctant to employ lumbar punctures, although we recognize that if they proved harmless they would contribute to the resolution of the dangerous 'dislocation'.

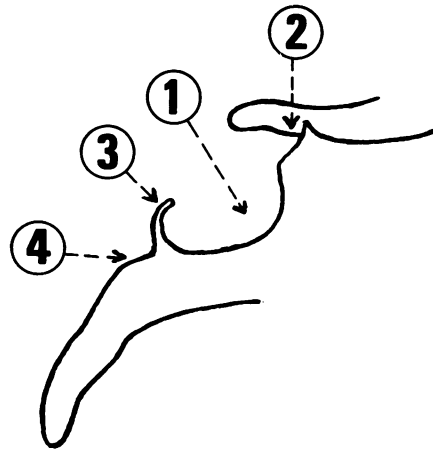
There seems to us good evidence that in



(a)

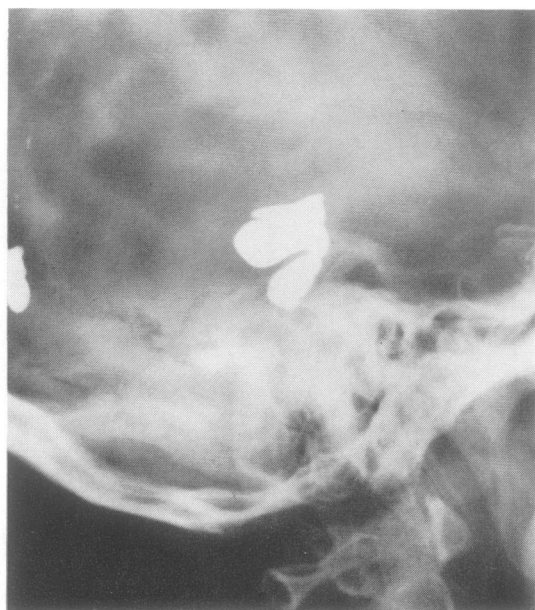

(b)

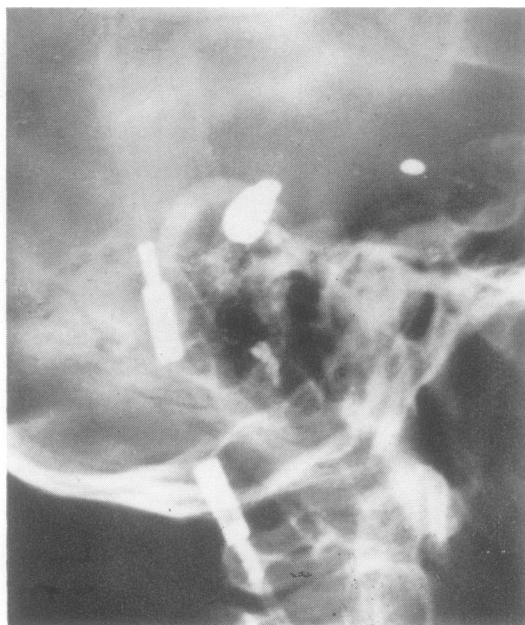


(c)

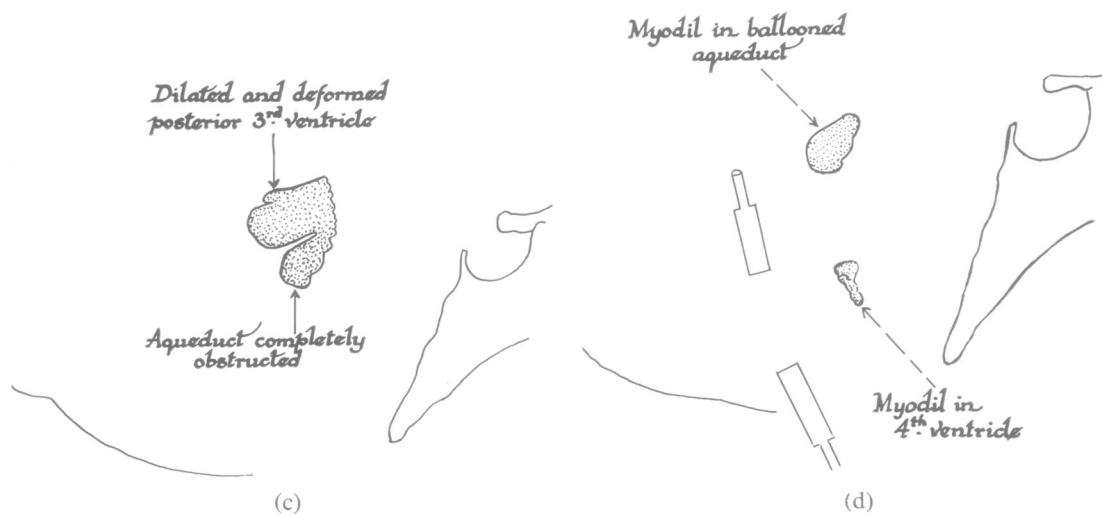
FIG. 8. Lateral view of pituitary fossa to show changes produced by long-standing enlargement of the 3rd ventricle. (a): Female, aged 19. (b): Female, aged 11; same patient as Figs 4a and 5. (c) Tracing of (a) to stress four characteristic features: (1) ballooning of the pituitary fossa with erosion of its floor; (2) erosion of the tuberculum sellae; (3) shortening of the dorsum sellae with loss of the posterior clinoid processes; (4) flattening of the upper part of the clivus, caused by that portion of the 3rd ventricle which bulges into the interpeduncular cistern.



(a)



(b)



(c)

(d)

FIG. 9. Myodil ventriculogram, lateral projection. Male, aged 48. (a): Preoperatively the aqueduct is completely occluded. (b): One day after the insertion of a Spitz-Holter valve. Drainage of the ventricles has resulted in some Myodil passing the obstruction. (c and d): Diagrams of a and b.

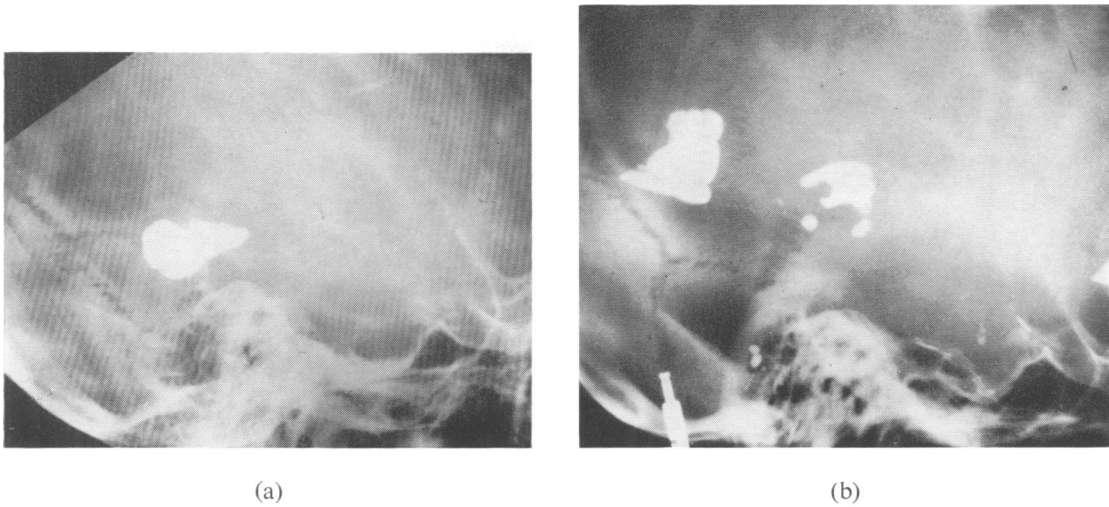
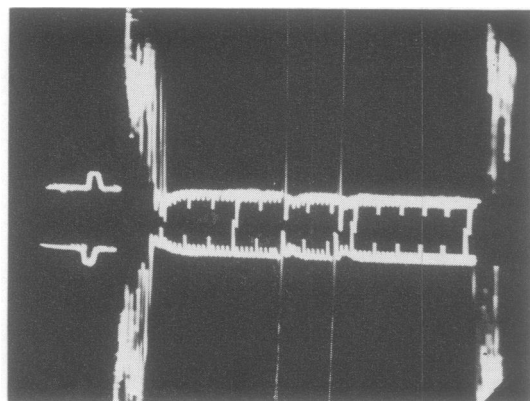
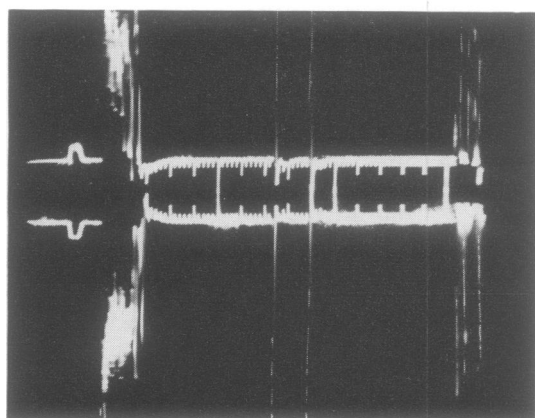


FIG. 10. Myodil ventriculogram, lateral projection. Same patient as Fig. 8a: a severely distended ventricular system and complete obstruction of the aqueduct. (a): Note the enormously dilated aqueduct and posterior end of the 3rd ventricle, which are 'dislocated' towards the foramen magnum. (b): Sixteen days after insertion of a Spitz-Holter valve. Observe that the aqueduct and posterior end of the 3rd ventricle are much less distended and are restored to their normal position. Note also that some Myodil now lies in the 4th ventricle. (c): Tracing of a and b.



(a)



(b)

FIG. 11. *Serial echogram tracings. (a): Before operation: width of 3rd ventricle = 24 mm. (b): Five days after inserting Spitz-Holter valve; 3rd ventricle now measures 17 mm.*

aqueduct stenosis the ballooned lateral ventricles depress the tentorium and drive the contents of the posterior fossa downwards against the clivus and towards the foramen magnum. There is, however, an additional important factor. This is that, at the level of the tentorial opening, the medial portions of the distended hemispheres are capable of causing side to side compression of the midbrain, thus converting partial aqueduct obstruction into a complete 'dynamic' block. This phenomenon would explain the passage of Myodil past an obstruction, which had appeared complete initially, after ventricular drainage alone. The well-documented fact (Huang, Wolf, Antin, Okudern, and Kim, 1968) that in benign

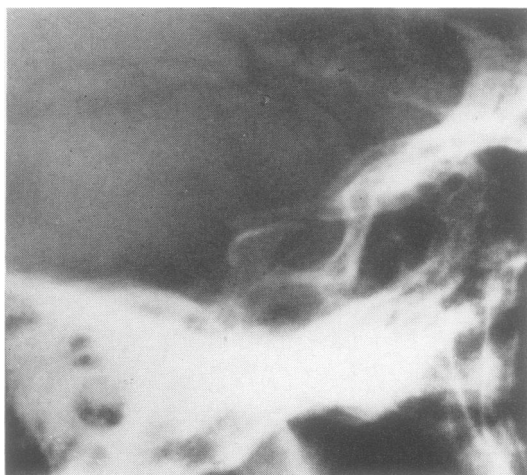


FIG. 12. *Lateral projection of pituitary fossa. Same patient as Fig. 8b. Fourteen years after inserting a Spitz-Holter valve.*

aqueduct stenosis the arteries encircling the upper brain-stem lie abnormally close together is consistent with the belief that herniation of the posterior uncus causes bilateral compression of the midbrain. This concept also implies that with obstructions of the aqueduct the relief of tense ventricular compression may break a vicious circle and allow sufficient fluid to flow through the stenosed aqueduct to restore the circulation of the cerebrospinal fluid (CSF) to normal. This view would explain why various decompressive operations were sometimes effective in the treatment of aqueduct stenosis before methods of direct ventricular drainage were introduced (see Pennybacker, 1940).

The effectiveness of breaking the vicious circle is shown by the following experience. In a boy aged only 11 months, in whom infection led to removal of a Spitz-Holter valve after eight weeks, a ventriculocisternostomy was performed. However, this operation was also complicated by infection so that all ventricular drainage was discontinued and the child was carefully observed. We were intrigued to find that the child remained entirely well and has continued symptom free for a further four and a half years.

From an analysis of the case histories of the patients in this series, we conclude that the grades of axial enlargement of the 3rd ventricle (degrees of ventricular 'dislocation') will provide the only rational guide to the selection of patients for the different surgical techniques available. We believe that routine employment

of the criteria which we have found useful will lead to a consequential improvement in the results which may be expected.

It is a pleasure to record our gratitude to Dr. N. A. Lewtas for his unfailing help in radiological matters and for his valued criticism during the preparation of this paper. We are also profoundly grateful to the radiographic staff, particularly to Miss J. M. Osborne and Mrs. K. Byron-Thompson.

REFERENCES

- Cantu, R. C., Michelson, J. J., and White, J. C. (1970). *Ventriculocisternostomy: Long-term Experiences*, p. 138. Thomas: Springfield, Ill.
- Elvidge, A. R. (1966). Treatment of obstructive lesions of the aqueduct of Sylvius and the fourth ventricle by inter-ventriculostomy. *Journal of Neurosurgery*, **24**, 11–23.
- Fincher, E. F., Strewler, G. J., and Swanson, H. S. (1948). The Torkildsen procedure. A report of 19 cases. *Journal of Neurosurgery*, **5**, 213–229.
- Gröschel, D., and Marguth, F. (1963). Ergebnisse der Ventrikulocisternostomie nach Torkildsen. *Zentralblatt für Neurochirurgie*, **23**, 262–281.
- Herlin, L. (1950). Ventriculocisternostomy according to Torkildsen. A report of twenty-two cases. *Journal of Neurosurgery*, **7**, 403–411.
- Huang, Y. P., Wolf, B. S., Antin, S. P., Okudera, T., and Kim, I. H. (1968). Angiographic features of aqueductal stenosis. *American Journal of Roentgenology*, **104**, 90–108.
- Nag, T. K., and Falconer, M. A. (1966). Non-tumoral stenosis of the aqueduct in adults. *British Medical Journal*, **2**, 1168–1170.
- Paine, K. W. E., and McKissock, W. (1955). Aqueduct stenosis. Clinical aspects, and results of treatment by ventriculocisternostomy (Torkildsen's operation). *Journal of Neurosurgery*, **12**, 127–145.
- Pennybacker, J. (1940). Stenosis of the aqueduct of Sylvius. *Proceedings of the Royal Society of Medicine*, **33**, 507–512.
- Scarff, J. E. (1963). Treatment of hydrocephalus: an historical and critical review of methods and results. *Journal of Neurology, Neurosurgery, and Psychiatry*, **26**, 1–26.
- Torkildsen, A. (1939). A new palliative operation in cases of inoperable occlusion of the Sylvian aqueduct. *Acta Chirurgica Scandinavica*, **82**, 117–124.
- Torkildsen, A. (1960). A follow-up study 14 to 20 years after ventriculocisternostomy. *Acta Psychiatrica et Neurologica Scandinavica*, **35**, 113–121.