

Traumatic cerebral aneurysms

Clinical features and natural history

BRIEN G. BENOIT and GEORGE WORTZMAN¹

*From the Division of Neurosurgery and Department of Radiology,
Toronto General Hospital, Toronto, Canada*

SUMMARY Six cases of traumatic cerebral aneurysm are presented, four situated at the base of the brain, and two on peripheral branches. Serial radiography was obtained in five patients, and in each the aneurysms had changed: spontaneous thrombosis, enlargement and change in shape, or rupture with destruction occurred. If surgical treatment of the aneurysm is delayed after the diagnosis has been made by angiogram, repeated angiography is recommended.

Traumatic aneurysms of intracranial arteries are very infrequent (Brihaye, Mage, and Verriest, 1954; Hirsch, David, and Sachs, 1962; Taveras and Wood, 1964; Burton, Velasco, and Dorman, 1968; Salmon and Blatt, 1968; Chaddock, 1969). Despite this rarity, the probability of rupture, combined with a readily available surgical cure, make early diagnosis imperative. Traumatic aneurysms may be situated on such extradural vessels as the internal carotid artery (Birley and Trotter, 1928; Seftel, Kolson, and Gordon, 1959; Araki, Handa, Handa, and Yoshida, 1965); the middle meningeal artery (Pouyanne, Leman, Got, and Gouaze, 1959; Wortzman, 1963b; Kuhn and Kugler, 1964), or on scalp vessels (Wortzman, 1963a; Lau and Knutson, 1969) but their occurrence on intracerebral arteries is quite unusual (Brihaye *et al.*, 1954; Hirsch *et al.*, 1962; Burton *et al.*, 1968; Rumbaugh, Bergeron, Talalla, and Kurze, 1970). This report deals only with this latter group of aneurysms, caused by closed trauma to a cerebral vessel.

The rarity of these aneurysms may be assessed against the incidence of the usual cerebral aneurysms, for, of over 850 intracranial aneurysms treated at the Toronto General Hospital since 1954, in only four cases was trauma the indisputable cause of vascular dam-

age with subsequent aneurysm formation. This report includes two cases of similar nature obtained from other institutions.

There were an additional eight cases where an aneurysm was demonstrated after craniocerebral injury. In six of these cases the aneurysm was at a site typical of congenital berry aneurysm, placing them in the group of 'trauma with coincidental aneurysm'. The two other cases were pericallosal in site and distal to the site of the usual pericallosal aneurysm which normally is seen proximal to or at the genu of the corpus callosum. These two cases were over the mid-portion of the corpus callosum and were felt to be secondary to trauma due to the margin of the falx striking the anterior cerebral artery and similar to the case reported by Smith and Bardenheier (1968). As this supposition remains unproven, these two cases, as well as the six berry type aneurysms, are not included in this report. Also excluded are the aneurysms seen after damage to meningeal vessels and associated with epidural haematomas.

The series of six cases reported below followed closed head trauma and are divided between aneurysms situated at basal and peripheral locations. In the five cases in which serial angiographic studies were available, the clinical course was variable and unpredictable with all of the aneurysms changing in some way, either by alteration in size or shape or by disappearance after rupture or thrombosis.

¹ Address for reprints: Dr. G. Wortzman, Department of Radiology, Toronto General Hospital, Toronto 2, Ontario, Canada.

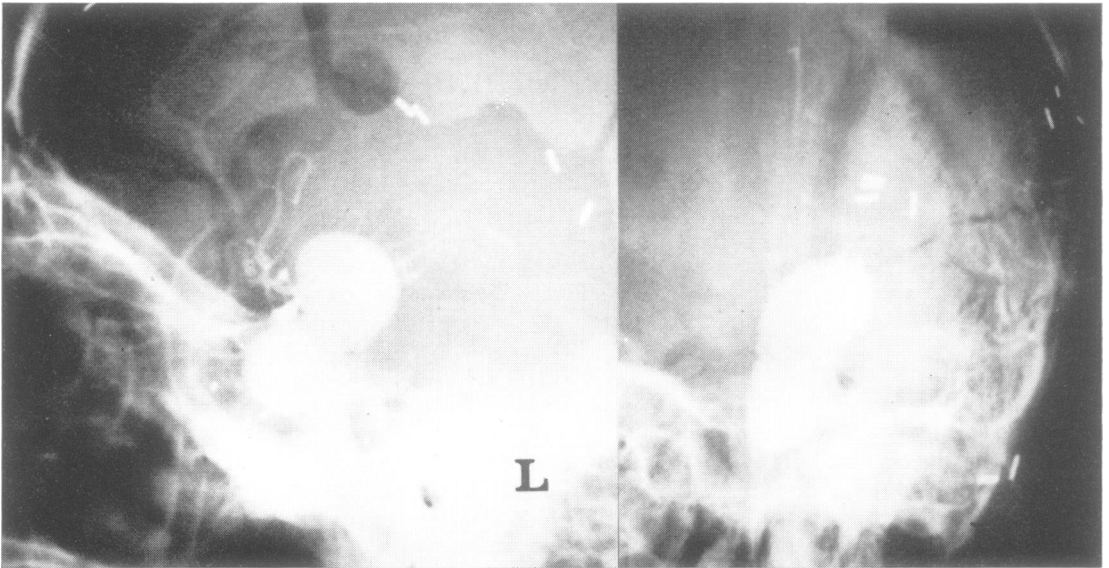


FIG. 1. Case 1. AP and lateral views showing a large internal carotid aneurysm both within and superior to the cavernous portion of the internal carotid artery. (Reproduced with the permission of Dr. T. P. Morley and the Congress of Neurological Sciences).

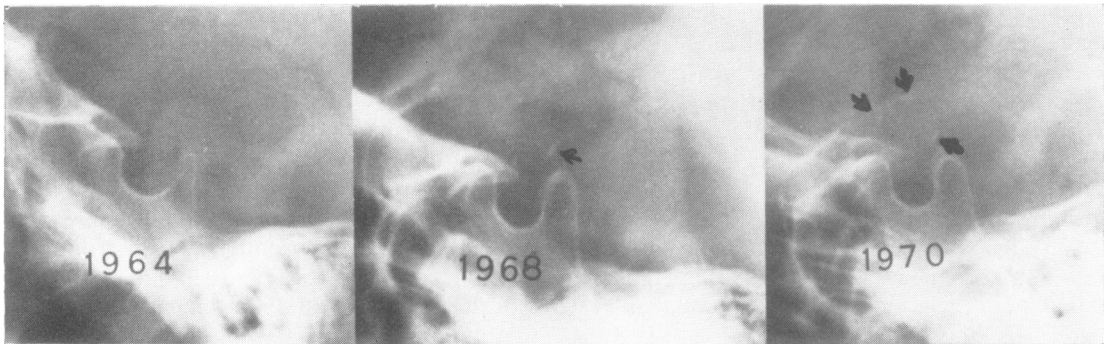


FIG. 2. Case 2. Skull radiographs from 1964 to 1970 showing the gradual appearance of suprasellar calcification, this first appearing in 1968 and being much more marked by the time of the examination in 1970 (arrows).

CASE 1

A 30 year old man was struck in the left fronto-temporal region by fragments from an exploding oil drum. There was immediate coma, a right hemiparesis, disruption of the left orbit and eye, and herniation of cerebral tissue through a large laceration.

At craniotomy, numerous vault and an orbital

roof fractures were found. Debridement and sub-total temporal lobectomy were carried out. The patient improved markedly but, 13 days later, his condition suddenly deteriorated. Subhyaloid haemorrhages were present, and a loud bruit was audible over the left cranium. Angiography revealed a giant dumbbell shaped aneurysm arising from the cavernous portion of the left carotid artery with an associated fistula (Fig. 1) (Morley and

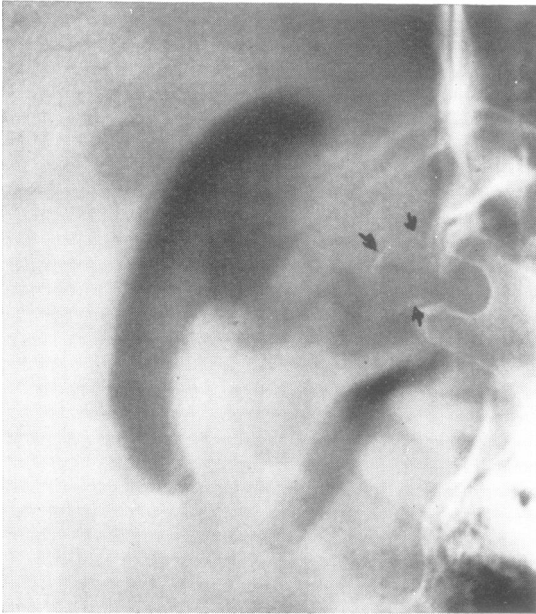

FIG. 3. *Case 2. Pneumoencephalogram. A brow-up lateral film shows a space-occupying lesion indenting the anterior third ventricle. The tumour mass is outlined by the calcification.*

Barr, 1969). There was also vasospasm of the distal internal carotid and proximal middle cerebral arteries on the right. The following day, the left common carotid artery was gradually occluded with a Selverstone clamp. The patient subsequently developed a communicating hydrocephalus which required a shunt. He remains severely handicapped with dementia, left-sided blindness, a right homonymous hemianopia, and hemiparesis.

CASE 2

A 9 year old boy was admitted for investigation of headaches, absence attacks, nausea, and vomiting, as well as progressive visual loss in the left eye. At the age of 2 he had suffered a severe head injury, at which time bilateral acute subdural haematomas were evacuated. A shunt was subsequently performed for communicating hydrocephalus. Plain skull films were normal at the time of injury, but later showed an area of calcification in the suprasellar region (Fig. 2). A pneumoencephalogram demonstrated upward displacement of the anterior part of the third ventricle, plus a soft tissue mass at the site of the calcification (Fig. 3), but a carotid angiogram was normal (Fig. 4).

At an exploratory craniotomy, a firm calcified mass lying between the optic tracts and thinning the chiasm was exposed. Needle aspiration was negative, but brisk arterial haemorrhage arose

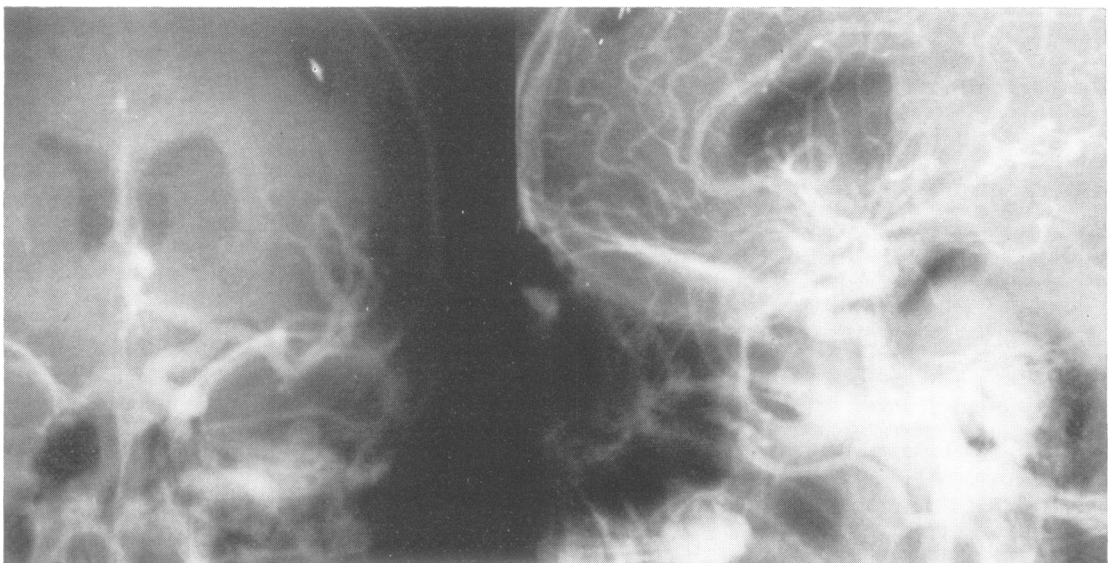


FIG. 4. *Case 2. Left carotid angiogram does not show an aneurysm or other abnormality.*

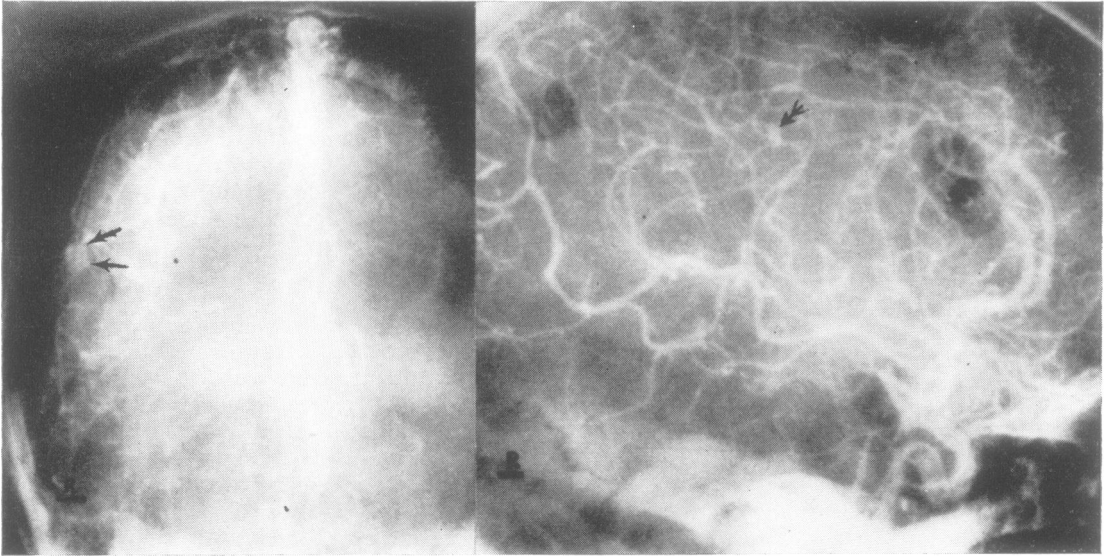


FIG. 5. Case 3. AP and lateral films show a subdural haematoma over the right cerebral hemisphere. The barbed arrows point to a small peripheral middle cerebral aneurysm. The AP view is later in the sequence and shows persistence of contrast medium in the aneurysm.

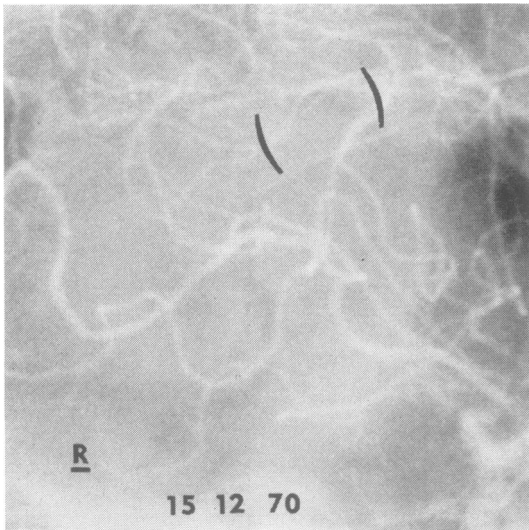


FIG. 6. Case 3. A magnified lateral view with the brackets about the area of the previously noted aneurysm. The aneurysm has thrombosed and is no longer visualized. This angiogram was done 17 months after the first study.

during dissection. The operation confirmed the lesion to be an aneurysm which must have originated from the injury seven years before and thrombosed some time subsequently.

CASE 3

A 73 year old widow fell down a flight of stairs. There was no immediate loss of consciousness, but two hours later she became drowsy and lapsed into coma. On admission, there was a dilated right pupil and left hemiparesis. Mannitol was rapidly infused and angiography performed. This study revealed a large acute subdural haematoma, as well as a small cortical aneurysm of the middle cerebral artery on the right (Fig. 5). The latter was not diagnosed initially, and the subdural clot was evacuated uneventfully.

There was a slow but progressive improvement post-operatively, and at re-examination 16 months after the injury, the patient was neurologically intact. A right carotid arteriogram did not demonstrate the traumatic aneurysm (Fig. 6).

CASE 4

A 45 year old man fell on to a concrete platform and immediately lost consciousness. On admission, the left pupil was unreactive to direct light, and there

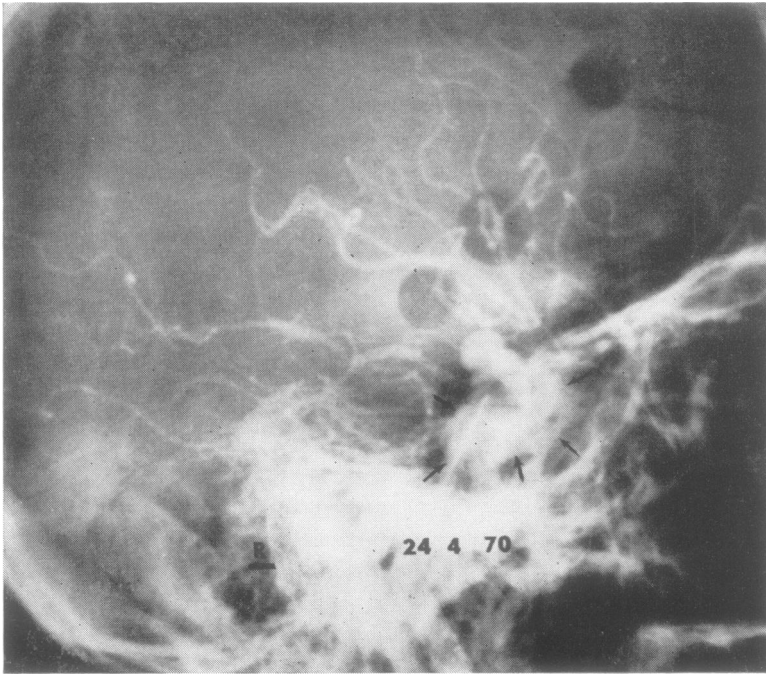


FIG. 7. Case 4. Right lateral views show an aneurysm arising in the cavernous sinus and extending into a suprasellar position. The arrows point out the borders of the opacified cavernous sinus. There is a carotid-cavernous fistula present. The shunting of the contrast medium is not marked in degree and there is still good opacification of middle and anterior cerebral vessels.

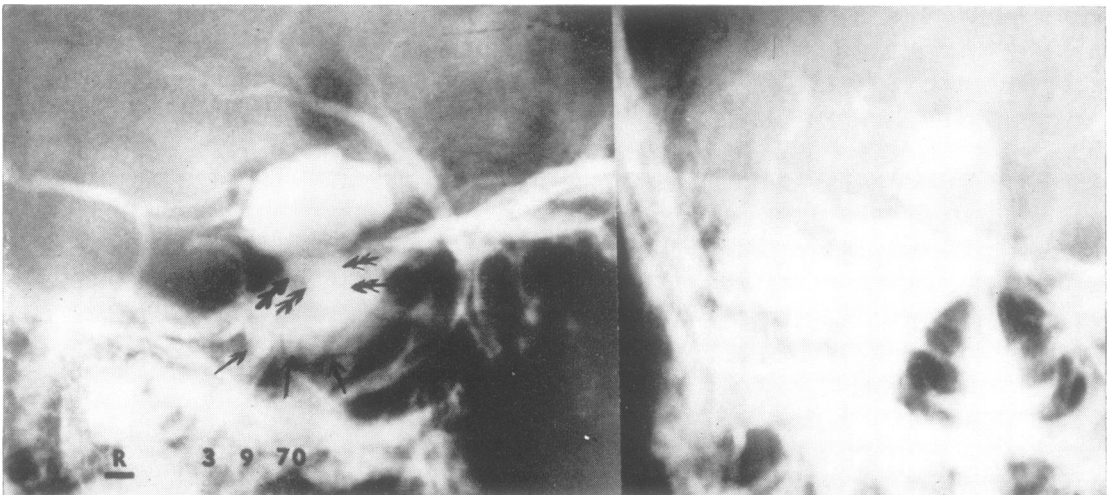


FIG. 8. Case 4. Right carotid angiogram – four and a half months later. The cavernous sinus is again outlined with small arrows. The double barbed arrows point to the neck of the aneurysm which arises within the cavernous sinus. The suprasellar extension is seen to have markedly increased in size with the aneurysm being irregular in contour. Very large draining veins are seen secondary to the carotid-cavernous fistula with the shunting of blood being much more marked and there being no opacification of middle or anterior cerebral vessels.

was a slight right hemiparesis, as well as a compound depressed fracture of the left frontal region. Debridement was carried out, the fracture elevated, and a thin acute subdural haematoma evacuated.

The patient gradually improved postoperatively, until 11 days later when he suddenly became drowsy and more dysphasic. The right eye became slightly proptosed, partial right abducens and oculomotor

palsies were present, and a harsh bruit could be heard over the entire cranium.

Cerebral angiography revealed a large aneurysm, measuring 10 mm in diameter, arising from the supraclinoid portion of the right internal carotid artery, associated with a carotid-cavernous fistula and vasospasm of the left anterior and middle cerebral arteries (Fig. 7).

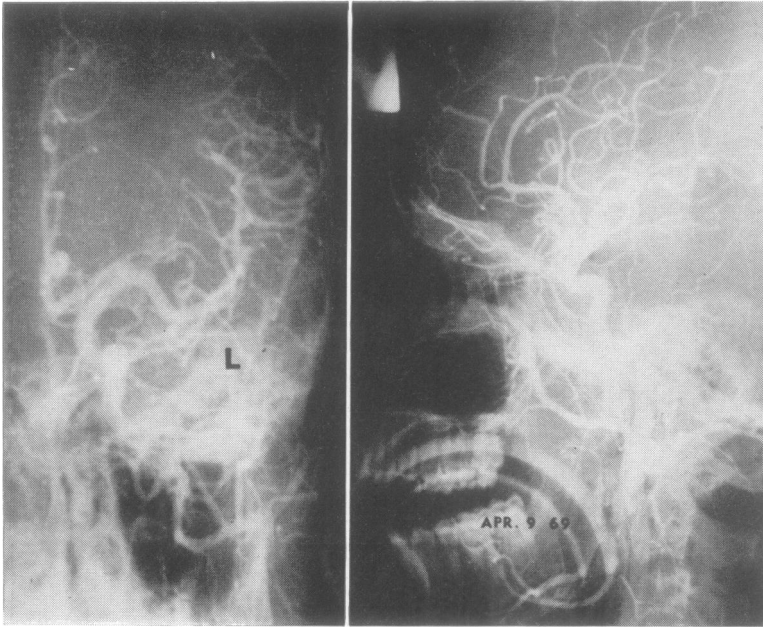


FIG. 9. Case 5. Left carotid angiogram. AP and lateral views showed no abnormality of the internal carotid artery or of anterior or middle cerebral branches.

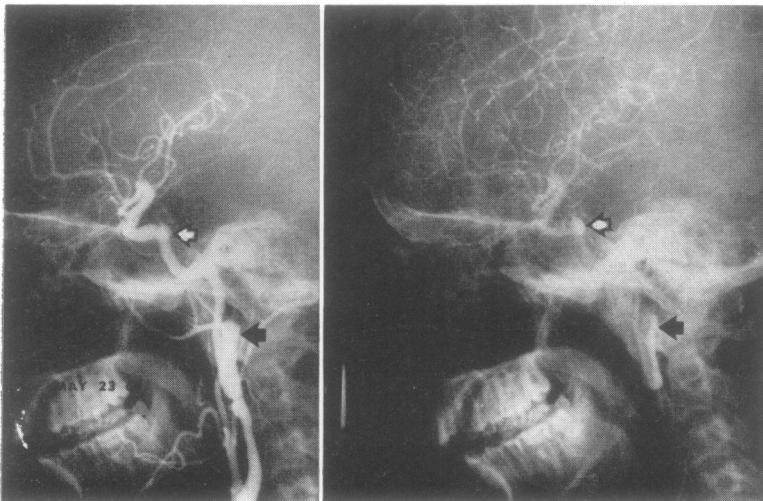


FIG. 10. Case 5. Left carotid angiogram done six weeks later showed a large aneurysm of the internal carotid artery in its extracranial portion opposite C2 and C1 (closed arrow) and a second aneurysm arising off the internal carotid artery in its precavernous portion (open arrow).

After an initial period of deterioration, the patient slowly improved and was transferred to a convalescent hospital to await the development of collateral circulation. The left eye was blind, and visual acuity on the right was 20/40.

Four and a half months later, the proptosis had increased, there was chemosis of the right eye with arteriolized fundal veins, and the visual acuity had deteriorated to 20/80. Angiography showed that the aneurysm had greatly increased in size to 32 mm, was irregular and lobulated (Fig. 8). The carotid-cavernous fistula remained unchanged.

At surgery, a large diastatic fracture of the floor of the anterior fossa was encountered, extending from the crista galli through the right anterior clinoid process. The internal carotid artery was ligated in the neck, and above the aneurysm; the carotid artery was opened, and ground muscle inserted to fill both the aneurysm and the cavernous part of the internal carotid artery.

Postoperatively the bruit disappeared immediately, the proptosis gradually subsided, visual acuity stabilized at 20/30 but the oculomotor pareses remained unchanged.

CASE 5

A 16 year old male student suffered an injury to his head and neck in a motorcycle accident. On ad-

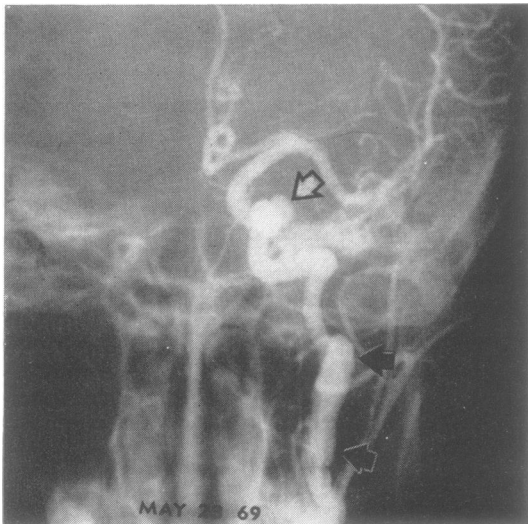


FIG. 11. Case 5. AP views showing the same two aneurysms.

mission, he was comatose, with early decerebrate posturing of the right limbs. A left carotid angiogram was normal (Fig. 9). Improvement was slow, with persistent dysphasia and right hemiparesis. The arteriogram was repeated six weeks later, and demonstrated a traumatic aneurysm arising from the internal carotid artery in the neck and a second aneurysm at the base of the skull (Figs 10 and 11). No surgical treatment was given, and the patient's condition has remained essentially unchanged.

CASE 6

A 49 year old male psychiatric patient sustained a severe head injury in a fall downstairs. On admission, he was deeply comatose, with a larger right pupil and a left hemiparesis. There was extensive fracturing of the skull. A right carotid angiogram demonstrated a large acute subdural haematoma on the right, as well as a small traumatic aneurysm of a peripheral cortical branch of the left anterior cerebral artery (Fig. 12 and 13). The latter was not diagnosed initially. Bilateral acute subdural haematomas were evacuated, and the patient showed early signs of improvement.

Three days later he suddenly lapsed into a de-

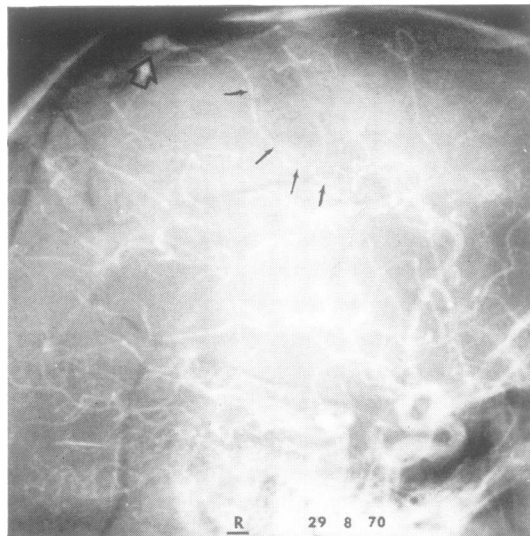


FIG. 12. Case 6. Lateral views show the multiple fractures of the vault. The open arrow points to a peripheral right anterior cerebral aneurysm. The small arrows are on the course of the vessel from which the aneurysm arises.

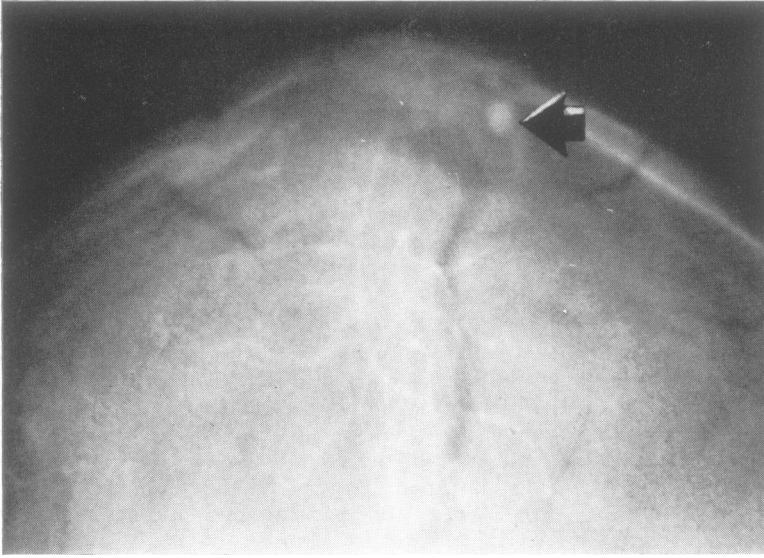


FIG. 13. Case 6. AP views of the upper vertex show the aneurysm to be just to the left of the midline (large closed arrow). The multiple fractures are again visualized.

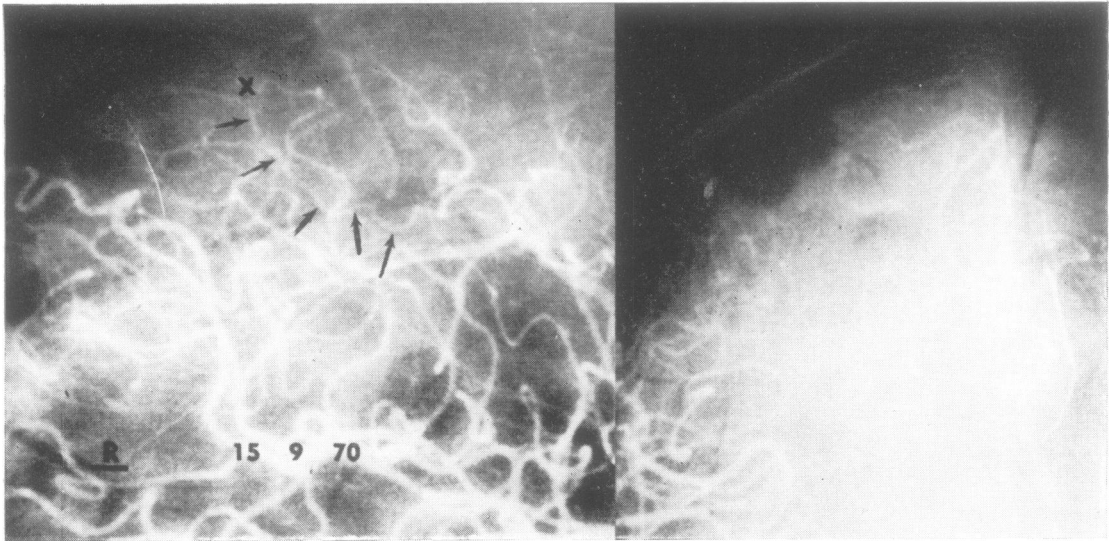


FIG. 14. Case 6. AP and lateral views done at angiography 17 days later. The arrows point to the same feeding vessel seen in Fig. 12. The X is at the point of thrombosis of this vessel. The aneurysm does not opacify and must be thrombosed.

cerebrate state. The patient's condition was deemed irreversible, and angiography was deferred for two weeks, at which time marked spasm of the proximal anterior and middle cerebral arteries was shown, but the traumatic aneurysm was no longer present (Fig. 14). At necropsy, no aneurysm could be demonstrated.

DISCUSSION

INCIDENCE Traumatic aneurysms of cerebral arteries have been recognized for many years; Bollinger (1891) suggested that one of the mechanisms of 'delayed apoplexy' was focal brain softening, local arteriolar damage with weakening of vessel wall, and later haemorrhage. The first description of a case of traumatic aneurysm was that of Birley and Trotter in 1928; thereafter little appeared in the literature until Krauland's report of a false aneurysm of the anterior cerebral artery in 1949. Despite a spate of recent reports, the lesion is rare. The Co-operative Study (Locksley, 1966) did not incriminate trauma directly in aneurysm formation. Araki *et al.* (1965) found only 10 cases of traumatic aneurysm of the intracranial extradural carotid artery in the literature and Burton *et al.* (1968) describe only 11 documented cases of traumatic aneurysm of a peripheral cerebral artery. To this have been added the nine cases of Rumbaugh *et al.* (1970) and a few isolated reports (Martinez, Bertrand, and Thierry 1966; Sedzimir, Occleshaw, and Buxton, 1968; Smith and Bardenheier, 1968; Handa, Shimizu, Matsuda, and Handa, 1970; Schneider, 1970; Smith and Kempe, 1970; Umebayashi, Kuwayama, Handa, Mori, and Handa, 1970).

SITE Traumatic aneurysms are located either on large basal arteries or on distal peripheral branches. The former group consists almost exclusively of aneurysms of the internal carotid artery, either on its extradural or supraclinoid portions. The association of blindness and severe epistaxis, due to rupture of an aneurysm into the sphenoidal sinus after basal skull fracture, is well known (Araki *et al.*, 1965). Supraclinoid aneurysms also occur with basal skull fractures (Brihaye *et al.*, 1954; Hirsch *et al.*, 1962; Salmon and Blatt, 1968) as in case 1 where the fracture extended along the orbital roof, and in

case 4 where it also involved the anterior clinoid process.

Peripheral traumatic aneurysms have been described at a variety of sites, a cortical branch of the middle cerebral artery being by far the commonest location (Courville, 1960; Hirsch *et al.*, 1962; Martinez *et al.*, 1966; Burton *et al.*, 1968; Sedzimir *et al.*, 1968; Chaddock, 1969; Courson, Dumas, and Collomb, 1970; Handa *et al.*, 1970; Rumbaugh *et al.*, 1970; Schneider, 1970; Smith and Kempe, 1970). The anterior cerebral (Krauland, 1949), pericallosal (Brenner, 1962; Smith and Bardenheier, 1968), anterior choroidal (Cressman and Hayes, 1966), and posterior cerebral (Burton *et al.*, 1968) arteries have also been the sites of traumatic aneurysms.

PATHOGENESIS Burton *et al.* (1968) have classified trauma to cerebral blood vessels as being direct or indirect.

Direct injury usually results from a penetrating wound due to indriven bone fragments or to a wide variety of missiles and weapons (Chaddock, 1969). Aneurysms arising after surgical procedures such as trephination (Overton and Calvin, 1966; Eichler, Story, Bennett, and Callo, 1969) and tumour removal (Taylor, 1961) have been described.

Indirect arterial trauma can occur with serious closed brain injuries; vessels may be damaged by striking the falx, tentorium (Smith and Bardenheier, 1968), or bony prominences (Handa *et al.*, 1970) during major brain shifts, or they may be involved in an area of focal brain necrosis with softening (Bollinger, 1891). Surface arterioles, either those accompanying bridging veins or those densely adherent to dura mater, may be injured during the sliding rotary movements of the brain during trauma (Drake, 1961). This mechanism is postulated in case 3, where a peripheral middle cerebral aneurysm occurred in the absence of skull fracture. Surface vessels may also become momentarily trapped in fracture lines, and thus sustain injury, as undoubtedly occurred in case 6.

'True' aneurysms usually develop when the chief arterial injury has been to the internal elastic lamina, allowing for later slow aneurysmal dilatation. The much commoner lesion, however, is the 'false' aneurysm; haemorrhage from a small, full-thickness arterial rent is adequately

contained by the buttressing effect of local brain tissue, and fibrous sac is formed. Mixed varieties, with rupture of a 'true' aneurysm giving rise to a secondary 'false' aneurysm (Burton *et al.*, 1968), and 'dissecting' traumatic aneurysms of cerebral arteries (Dratz and Woodhall, 1947; Wolman, 1959; Shaw and Foltz, 1968) have been reported.

ASSOCIATED LESIONS Traumatic aneurysms are invariably associated with other evidence of severe brain injury such as acute subdural haematoma (Hirsch *et al.*, 1962; Martinez *et al.*, 1966; Smith and Bardenheier, 1968; Handa *et al.*, 1970; Rumbaugh *et al.*, 1970; Schneider, 1970; Smith and Kempe, 1970; Umabayashi *et al.*, 1970) epidural haematoma, (Salmon and Blatt, 1968; Rumbaugh *et al.*, 1970) intracerebral clot (Sedzimir *et al.*, 1968; Chaddock, 1969; Handa *et al.*, 1970; Rumbaugh *et al.*, 1970), or cerebral laceration (Courville, 1960; Cressman *et al.*, 1966). This association was borne out in this series; subdural haematomas were evacuated in cases 2, 3, 4, and 6, and the brain was severely lacerated in cases 1 and 4.

DIAGNOSIS Traumatic aneurysms at the base present few diagnostic difficulties after angiography. Peripheral cortical aneurysms, however, must be distinguished from an aneurysm of the middle meningeal artery, which normally is adjacent to the inner table of the skull, and frequently is displaced inwards by an epidural haematoma (Wortzman, 1963b). Aneurysms of scalp vessels such as the superficial temporal artery (Wortzman, 1963a; Lau and Knutson, 1969) are seen outside the skull on the antero-posterior views. The lack of a history of trauma or skull fracture distinguishes cortical mycotic aneurysm, and 'congenital' aneurysms are typically situated at bifurcations. Angiographically, 'false' aneurysms usually fill late in the arterial phase, opacify less, and empty more slowly than the berry aneurysm. Initial normal angiography after trauma and the subsequent appearance of an aneurysm, unquestionably implicates trauma in the aetiology of the lesion. This fortuitous sequence is rarely documented (Hirsch *et al.*, 1962; Smith and Bardenheier, 1968) but did occur once in this series in case 5.

There are numerous cases reported where the angiographic features of the aneurysm were not fully appreciated initially (Taylor, 1961; Cressman and Hayes, 1966; Burton *et al.*, 1968; Smith and Bardenheier, 1968; Rumbaugh *et al.*, 1970). In cases 3 and 6 the diagnosis of traumatic aneurysm was not made until the films were reviewed at a later date, with the acute subdural haematomas distracting attention from the associated aneurysms.

NATURAL HISTORY Traumatic cerebral aneurysms run an unpredictable course; catastrophic rupture is the usual late event. Burton *et al.* (1968) found a mortality of 54% in the literature on peripheral traumatic aneurysms to 1968; since then, however, mortality has dropped to an estimated 28% of published cases. Only one of our cases died, but in most of the others the residual morbidity, whether due to the associated lesions or to aneurysmal rupture, was great. There are relatively few reports of uneventful recovery from rupture of a traumatic aneurysm, a fact suggesting that early diagnosis and treatment are important.

The reported time between trauma and diagnosis of the aneurysm is a few hours to as long as 10 years (Chaddock, 1969). The lesion may be seen on the first arteriogram after injury or only on a study done during later clinical deterioration. The average interval between injury and delayed haemorrhage in cortical traumatic aneurysms reported in the literature seems to be about 14 days. In this series, deterioration suddenly occurred after 13 days in case 1 when a bruit was heard, and 11 days in case 4, at which time the aneurysm ruptured into the cavernous sinus creating a fistula. In case 6, haemorrhage probably occurred three days after injury when the aneurysm, in rupturing, destroyed itself.

STRUCTURAL CHANGES Very few of the case reports in the literature describe changes in the angiographic appearance of traumatic cerebral aneurysms. In all these five cases in which serial radiography was obtained, marked change in the lesion is shown. In case 3, the middle cerebral aneurysm spontaneously disappeared, an event reported only twice previously (Brenner, 1962; Rumbaugh *et al.*, 1970). In both reported cases and in case 3, the aneurysm was seen on initial

angiography, but there was no clinical evidence of late rupture. These patients ran a relatively benign course, as did case 2 in which delayed thrombosis with calcification occurred in a large basal aneurysm. Congenital intracranial aneurysms have occasionally been shown to enlarge after trauma (Björkesten and Troupp, 1962), and there have been infrequent reports of peripheral (Burton *et al.*, 1968; Umebayashi *et al.*, 1970) and basal (Hirsch *et al.*, 1962) traumatic aneurysms increasing in size. Likewise the aneurysms at the base markedly increased in size with this change demonstrated in cases 4 and 5.

CONCLUSIONS

A traumatic cerebral aneurysm is a dangerous lesion with rupture or increase in size probable and spontaneous thrombosis rare. During the treatment of associated injuries, the lesion may be overlooked. When surgery for the aneurysm is deferred the aneurysm may change in size and shape as demonstrated angiographically. Angiography therefore should be repeated immediately before surgical treatment of this condition.

The authors are indebted to Dr. H. Hoffman and Dr. D. Harwood-Nash of the Hospital for Sick Children, Toronto, for permission to publish case 2 and to Dr. M. T. Richard, of the Ottawa General Hospital, Ottawa, for case 5. The remaining four patients were admitted to the Toronto General Hospital under the care of Dr. T. P. Morley, Dr. W. M. Lougheed, and Dr. R. R. Tasker. Our thanks to Mrs. Marilyn Reid, Research Editor, Division of Neurosurgery, Toronto General Hospital, for editorial assistance and to Mrs. Gwen Yetman for secretarial assistance.

REFERENCES

- Araki, C., Handa, H., Handa, J., and Yoshida, K. (1965). Traumatic aneurysm of the intracranial extradural portion of the internal carotid artery. Report of a case. *Journal of Neurosurgery*, **23**, 64-67.
- Birley, J. L., and Trotter, W. (1928). Traumatic aneurysm of the intracranial portion of the internal carotid artery. *Brain*, **51**, 184-208.
- Björkesten, G. af, and Troupp, H. (1962). Changes in the size of intracranial arterial aneurysms. *Journal of Neurosurgery*, **19**, 583-588.
- Bollinger, O. (1891). Ueber traumatische Spät-Apoplexie; ein Beitrag zur Lehre von der Hirnerschütterung. In *Internationale Beiträge zur Wissenschaftlichen Medicin, Festschrift, Rudolf Virchow*, Bd. 2, 457-470. Hirschwald: Berlin.
- Brenner, H. (1962). Frontale Schädelspaltung mit traumatischem Aneurysma der Arteria pericallosa. *Acta Neurochirurgia (Wien)*, **10**, 145-152.
- Brihaye, J., Mage, J., and Verriest, G. (1954). Anévrysme traumatique de la carotide interne dans sa portion supra-clinoïdienne. *Acta Neurologica et Psychiatrica Belgica*, **54**, 411-438.
- Burton, C., Velasco, F., and Dorman, J. (1968). Traumatic aneurysm of a peripheral cerebral artery. Review and case report. *Journal of Neurosurgery*, **28**, 468-474.
- Chadduck, W. M. (1969). Traumatic cerebral aneurysm due to speargun injury. Case report. *Journal of Neurosurgery*, **31**, 77-79.
- Courson, B., Dumas, M., and Collomb, H. (1970). Les anévrysmes artériels distaux ou des branches périphériques de l'artère cérébrale moyenne. *Neuro-chirurgie*, **16**, 15-24.
- Courville, C. B. (1960). Traumatic aneurysm of an intracranial artery. Description of lesion incident to a shotgun wound of the skull and brain. *Bulletin of the Los Angeles Neurological Society*, **25**, 48-54.
- Cressman, M. R., and Hayes, G. J. (1966). Traumatic aneurysm of the anterior choroidal artery. Case report. *Neurosurgery*, **24**, 102-104.
- Drake, C. G. (1961). Subdural haematoma from arterial rupture. *Journal of Neurosurgery*, **18**, 597-601.
- Dratz, H. M., and Woodhall, B. (1947). Traumatic dissecting aneurysm of left internal carotid, anterior cerebral and middle cerebral arteries. *Journal of Neuropathology and Experimental Neurology*, **6**, 286-291.
- Eichler, A., Story, J. L., Bennett, D. E., and Callo, M. V. (1969). Traumatic aneurysm of a cerebral artery. Case report. *Journal of Neurosurgery*, **31**, 72-76.
- Handa, J., Shimizu, Y., Matsuda, M., and Handa, H. (1970). Traumatic aneurysm of the middle cerebral artery. *American Journal of Roentgenology*, **109**, 127-129.
- Hirsch, J. F., David, M., and Sachs, M. (1962). Les anévrysmes artériels traumatiques intracraniens. *Neuro-chirurgie*, **8**, 189-201.
- Krauland, W. (1949). Zur Entstehung traumatischer Aneurysmen der Schlagadern am Hirngrund. *Schweizerische Zeitschrift für Pathologie und Bakteriologie*, **12**, 113-127.
- Kuhn, R. A., and Kugler, H. (1964). False aneurysms of the middle meningeal artery. *Journal of Neurosurgery*, **21**, 92-96.
- Lau, C., and Knutson, G. H. (1969). Traumatic aneurysm of the temporal artery: a report of two cases. *Canadian Journal of Surgery*, **12**, 432-434.
- Locksley, H. B. (1966). Natural history of subarachnoid hemorrhage, intracranial aneurysms and arteriovenous malformations. Based on 6368 cases in the cooperative study. *Journal of Neurosurgery*, **25**, 219-239.
- Martinez, S. N., Bertrand, C., and Thierry, A. (1966). Les faux anévrysmes post-traumatiques. *Canadian Journal of Surgery*, **9**, 397-402.
- Morley, T. P., and Barr, H. W. K. (1969). Giant intracranial aneurysms: diagnosis, course, and management. *Clinical Neurosurgery*, **16**, 73-94.
- Overton, M. C., III, and Calvin, T. H., Jr. (1966). Iatrogenic cerebral cortical aneurysm. Case report. *Journal of Neurosurgery*, **24**, 672-675.
- Pouyanne, H., Leman, P., Got, M., and Gouaze, A. (1959). Anévrysme artériel traumatique de la méningée moyenne gauche. *Neuro-chirurgie*, **5**, 311-315.
- Rumbaugh, C. L., Bergeron, R. T., Talalla, A., and Kurze, T. (1970). Traumatic aneurysms of the cortical cerebral arteries. Radiographic aspects. *Radiology*, **96**, 49-54.
- Salmon, J. H., and Blatt, E. S. (1968). Aneurysm of the internal carotid artery due to closed trauma. *Journal of Thoracic and Cardiovascular Surgery*, **56**, 28-32.

- Schneider, V. (1970). Traumatische Aneurysmen der Schlagadern an der Mantelfläche des Grosshirns und ihre Beziehungen zu subduralen Blutungen. *Monatsschrift für Unfallheilkunde und Versicherungsmedizin*, **73**, 63-69.
- Sedzimir, C. B., Occlshaw, J. V., and Buxton, P. H. (1968). False cerebral aneurysm. Case report. *Journal of Neurosurgery*, **29**, 636-639.
- Seftel, D. M., Kolson, H., and Gordon, B. S. (1959). Ruptured intracranial carotid artery aneurysm with fatal epistaxis. *Archives of Otolaryngology*, **70**, 52-60.
- Shaw, C.-M., and Foltz, E. L. (1968). Traumatic dissecting aneurysm of middle cerebral artery and carotid-cavernous fistula with massive intracerebral hemorrhage. Case report. *Journal of Neurosurgery*, **28**, 475-479.
- Smith, D. R., and Kempe, L. G. (1970). Cerebral false aneurysm formation in closed head trauma. Case report. *Journal of Neurosurgery*, **32**, 357-359.
- Smith, K. R., Jr., and Bardenheier, J. A., III (1968). Aneurysm of the pericallosal artery caused by closed cranial trauma. Case report. *Journal of Neurosurgery*, **29**, 551-554.
- Taveras, J. M., and Wood, E. H. (1964). *Diagnostic Neuro-radiology*. Williams and Wilkins: Baltimore.
- Taylor, P. E. (1961). Delayed postoperative hemorrhage from intracranial aneurysm after craniotomy for tumor. *Neurology (Minneapolis)*, **11**, 225-231.
- Umebayashi, Y., Kuwayama, M., Handa, J., Mori, K., and Handa, H. (1970). Traumatic aneurysm of a peripheral cerebral artery; case report. *Clinical Radiology*, **21**, 36-38.
- Wolman, L. (1959). Cerebral dissecting aneurysms. *Brain*, **82**, 276-291.
- Wortzman, G. (1963a). Traumatic pseudo-aneurysm of the superficial temporal artery; a case report. *Radiology*, **80**, 444-446.
- Wortzman, G. (1963b). Roentgenologic aspects of extradural hematoma. *American Journal of Roentgenology*, **90**, 462-471.