

## Strümpell's familial spastic paraplegia : genetics and neuropathology

WILHELMINA M. H. BEHAN<sup>1</sup> AND MARIA MAIA<sup>2</sup>

*From the Department of Neuropathology, Radcliffe Infirmary,  
and the M.R.C. Population Genetics Unit, Oxford*

**SUMMARY** Uncomplicated Strümpell's disease (Strümpell's familial spastic paraplegia) with a dominant mode of inheritance is recorded in six families. The neuropathological findings in two cases from these families are given, bringing the total of similar histologically documented reports in the literature to 11. It is concluded that, although exact classification and identification of the many different hereditary neurological degenerative diseases is not yet practicable, cases conforming to the picture described by Strümpell can be separated from the larger general group of familial spastic paraplegias, show a consistent clinical picture, and have a standard pathology. It is suggested that, since the lesions are confined to the longest fibre tracts in the central nervous system, the pathological process may be different from that found in the 'system' degenerations.

Strümpell's familial spastic paraplegia (SFSP) is a rare hereditary disorder, characterized by progressive weakness and spasticity affecting predominantly the lower limbs. Although most neurologists in large centres have seen one or two cases, the life span of the patients tends not to be shortened, nor do they usually die in hospital, thus neuropathological reports are very few. The lack of detailed pathological knowledge has created many difficulties in classification, particularly in establishing the relationship of this disease to other familial degenerative disorders. We were able to study six families with uncomplicated familial spastic paraplegia (FSP) to determine their phenotypic relationship, and to examine neuropathological material from single patients from two of these families. This report is concerned mainly with the neuropathological findings, with a brief description of the clinical findings, and a note on the genetics. From our studies it is concluded that SFSP should be regarded as a circumscribed clinical and pathological entity, characterized by distal

axonal degeneration of the long ascending and descending tracts in the spinal cord.

### METHODS

**GENETIC STUDIES** The six families studied consisted of four families with members who had been referred to the Population Genetics Unit in Oxford for genetic advice, and two additional families, in each of which one affected member had died and been the subject of a neuropathological examination at the Neuropathology Department, Radcliffe Infirmary, Oxford. With two exceptions (noted below) all living affected members of these families were visited, as were family members suspected of having a disability, and as far as possible those apparently at risk by reason of age or relationship to known affected individuals. A detailed history was taken and clinical examinations carried out on all the individuals by one of us (M.M.).

The findings are recorded as diagrammatic pedigrees (Figs 1–6) and all clinical data are summarized in the Table. It was decided to classify the disorder into stages I–IV, with subgroups (a) and (b), on the following basis:

- I Pyramidal tract signs in the legs, but no complaints of symptoms.
- II Spastic gait, but the patients could walk unaided.
- III Patients could walk with the aid of sticks.

<sup>1</sup> Present address: 6 Ledlameroch Crescent, Bearsden, Glasgow. G614AA.

<sup>2</sup> Present address: Department of Neurology, Sto. Antonio Hospital, Oporto, Portugal.

Family A

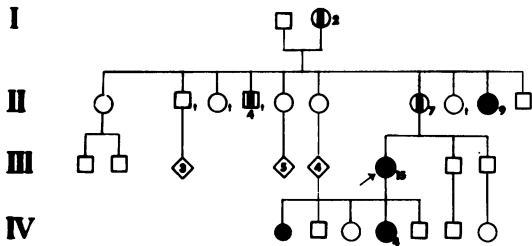


FIG. 1.

Family B

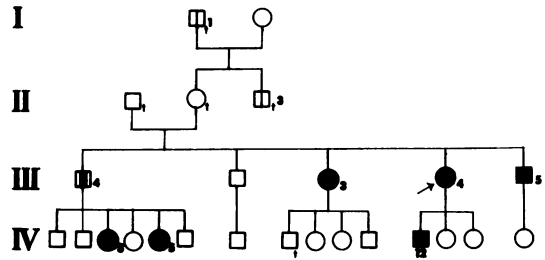


FIG. 2.

Family C

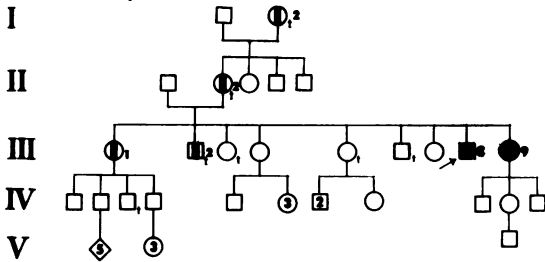


FIG. 3.

Family D

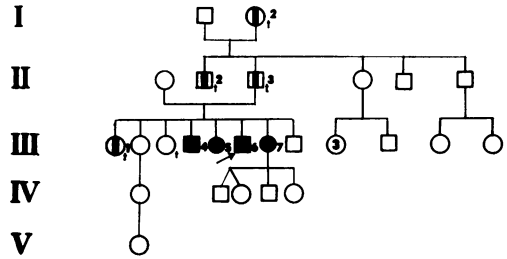


FIG. 4.

Family E

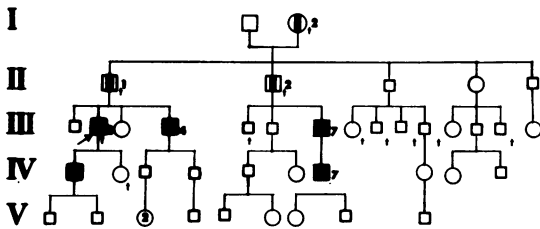


FIG. 5.

Family F

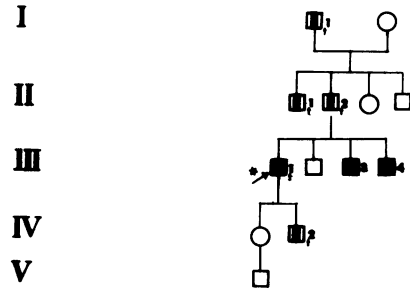


FIG. 6.

FIGS 1 to 6. Family trees of six families. Key: □ males, ○ females, ◇ sex unknown, ↗ propositus,

■ examined and affected, ▨ said to be affected, □ doubtful, \* neuropathological report, ● still born.

IV Patients were, for practical purposes, confined to a chair or bed.

Each group is subclassified as (a) when deep sensation is normal, and (b) when deep sensation is impaired.

NEUROPATHOLOGICAL STUDIES Detailed macroscopic and microscopic examinations were made of the brain and spinal cord in both cases, and of peripheral nerves and muscles in case 1.

## CASE I

Family E (III<sub>2</sub>). Age at death, 62 years. General necropsy: no significant findings.

**CENTRAL NERVOUS SYSTEM** *Macroscopic* The brain (1,650 g) was swollen. There was a small recent haemorrhage in the corpus callosum. The cause of death was a haemorrhage in the right cerebellar hemisphere, which had ruptured into the fourth ventricle. The spinal cord, roots, and meninges appeared normal apart from some greyness of the posterolateral columns in transverse sections. The fixed spine revealed a small, midline protrusion

associated with C 4-5 intervertebral disc. The protrusion was 0.5 cm laterally, 0.5 cm from above downwards, and projected 0.3 cm anteriorly. Smaller lateral protrusions were associated with this disc and the two below. This degree of cervical spondylosis was not considered significant.

*Microscopic* Blocks were taken from the corpus callosum, Rolandic cortex, cerebellum, three levels of brain-stem, and all segments of the spinal cord; cervical and lumbar nerve roots; and nerves and muscles from all four limbs. Customary staining was carried out for nerve cells, axons, myelin, and neuroglia.

TABLE  
CLINICAL DETAILS OF FAMILIES A TO F

| Pedigree No.                       | Age in 1970 (yr)   | Age at onset (yr) | Pyramidal signs |      | Impairment of deep sensation | Clinical stage | Additional information  |
|------------------------------------|--|-------------------|-----------------|------|------------------------------|----------------|---|
|                                    |  |                   | legs            | arms |                              |                |   |
| <i>Family A</i>                    |  |                   |                 |      |                              |                |   |
| II <sub>9</sub>                    | 54   | 7                 | +               | +    | +                            | IVb            | Condition said not to have progressed since first recognized at 7 yr until about 29 yr of age. Confined to a chair for 14 years   |
| III <sub>15</sub>                  | 41   | 31                | +               | +    | +                            | IIIb           | Sensory disturbance to touch and pin prick on R arm below elbow and in leg below the middle of thighs. EMG showed normal sensory evoked potentials in the median nerve proximal to the wrist. Reflex activity (stretch reflex, H reflex and C reflex) was similar to that found in other spastic patients |
| IV <sub>4</sub>                    | 13   | 12                | +               | -    | -                            | I              | First noticed to swing L leg outwards when walking at about 12 yr of age. Obvious spasticity of L leg. R flexor plantar response but left neutral response  |
| II <sub>7</sub>                    | Refused to be visited. Is confined to a chair. Her sister, II <sub>9</sub> , says that her trouble with walking started at age 17  |                   |                 |      |                              |                |   |
| II <sub>1</sub>                    | Died in 1917 in New Zealand. Described in a doctor's letter as having 'spastic paraplegia without sensory loss'  |                   |                 |      |                              |                |   |
| I <sub>2</sub>                     | Said to have been affected similarly to other members of the family from the age of about 30 yr  |                   |                 |      |                              |                |   |
| <i>Family B</i>                    |  |                   |                 |      |                              |                |   |
| III <sub>3</sub>                   | 45   | 30                | +               | +    | -                            | IIIa           | Leg weakness first noticed after her first child. Stationary until second child was born 5 yr later when her condition deteriorated. Slight impairment to touch and pin prick in the outer aspects of the L leg   |
| III <sub>4</sub>                   | 41   | 24                | +               | +    | -                            | IIa            | Weakness began after first child—cleared in a few weeks. Weakness recurred after successive pregnancies but from age 35 condition deteriorated. Left pupil larger than right but consensual and accommodation reflexes present  |
| III <sub>5</sub>                   | 37   | 21                | +               | +    | +                            | IIIb           | Used caliper on R leg after fracture of the femur and pelvic girdle at 7 yr but unable to play games in 'teens. Slow progression of weakness, now walking only on crutches. Bilateral slight rotatory nystagmus. No ataxia  |
| IV <sub>3</sub>                    | 23   | 3                 | +               | +    | -                            | IIIa           | First walked at 3 yr—on toes. Several orthopaedic operations in childhood. Attended school for physically handicapped   |
| IV <sub>5</sub>                    | 21   | 2                 | +               | +    | +                            | IIIb           | Walked at 18 mth but always dragged her legs; at school for physically handicapped  |
| IV <sub>12</sub>                   | 17   | 1                 | +               | -    | -                            | IIa            | Walked on toes from infancy. Marked spasticity of legs: clonus of R ankle and bilaterally extensor plantar responses  |
| III <sub>1</sub>                   | Not examined as <i>in extremis</i> in hospital with pelvic sarcoma. Hospital notes say onset at 25 yr. Spasticity of legs with exaggerated reflexes  |                   |                 |      |                              |                |   |
| I <sub>1</sub>                     | Was said to use sticks in old age after being injured by bull  |                   |                 |      |                              |                |   |
| II <sub>3</sub>                    | Also used sticks, but probably due to accident   |                   |                 |      |                              |                |   |
| <i>Family C</i>                    |  |                   |                 |      |                              |                |   |
| III <sub>8</sub>                   | 64   | 44                | +               | +    | -                            | IIa            | Myelogram in 1967 showed free flow. Relatively slow progression: can still drive car  |
| III <sub>9</sub>                   | 62   | 48                | +               | +    | -                            | IIa            | Similar to her brother  |
| I <sub>2</sub> and II <sub>2</sub> | Said to have been affected like rest of family but no details available  |                   |                 |      |                              |                |   |
| III <sub>2</sub>                   | Hospital records confirmed spastic paraplegia with no impairment of sensation. L pupillary reaction was said to be brisker than R. Beginning of weakness about 40. Died age 60 (cause unknown) |                   |                 |      |                              |                |   |

The haemorrhages in the brain showed no peculiar features, and were considered to be related to the patient's arterial hypertension. No abnormality was found in motor cortex, internal capsule, thalamus, and upper brain-stem. Myelin pallor was just detectable in the medullary pyramids; otherwise there was no sign of tract degeneration in the brain-stem.

In the cord, there was degeneration of the cortico-spinal tracts at all levels, including the uncrossed tracts in the cervical and upper thoracic segments (Figs 7 and 8). Myelin and axon stains showed that

the degeneration involved mainly the thicker fibres, and became progressively more severe at lower levels. There was an associated astrocytic and fibroglial reaction. No lipid degeneration products or PAS-positive material, were seen. There was also degeneration of the posterior columns, mild at sacral levels, and becoming more severe on ascending the cord (Figs 7, 8, and 9). At lower cervical levels the cuneate fasciculi were only mildly affected, whereas the gracile fasciculi were grossly degenerate and reduced in size; while at C-1 segment and in the lower medulla the cuneate fasciculi were severely affected. At all levels

TABLE—continued

| Pedigree No.                        | Age in 1970 (yr)   | Age at onset (yr) | Pyramidal signs |      | Impairment of deep sensation | Clinical stage | Additional information   |
|-------------------------------------|--|-------------------|-----------------|------|------------------------------|----------------|--|
|                                     |  |                   | legs            | arms |                              |                |  |
| <i>Family D</i>                     |  |                   |                 |      |                              |                |  |
| III <sub>4</sub>                    | 68   | 35                | +               | +    | +                            | IVb            | Was able to work as radio mechanic until 45. Now repairs radio sets in bed. Very marked spasticity with knee clonus  |
| III <sub>5</sub>                    | 65   | 40                | +               | +    | +                            | IVb            | Steady progression since onset   |
| III <sub>6</sub>                    | 62   | 39                | +               | +    | +                            | IIIb           | Walking with a stick for 20 yr. Investigation in 1968 revealed no spinal abnormality and normal CSF  |
| III <sub>7</sub>                    | 60   | 50                | +               | +    | -                            | IIa            | Steady progression since onset   |
| III <sub>1</sub>                    | Died aged 49 of cancer. Only information available is that walked with stiff gait with great difficulty for 6 yr before death  |                   |                 |      |                              |                |  |
| II <sub>2</sub> and II <sub>3</sub> | Both walked with sticks for many years   |                   |                 |      |                              |                |  |
| I <sub>2</sub>                      | Remembered by III <sub>6</sub> walking with sticks   |                   |                 |      |                              |                |  |
| <i>Family E</i>                     |  |                   |                 |      |                              |                |  |
| III <sub>2</sub>                    | died at 63   | 35                | +               | ?    | +                            | ?              | Neurological report (Dr. Worster-Drought) in 1943 when aged 42 stated 'upper neurone paraplegia with impairment of deep forms of sensation in lower limbs and retention of superficial sensation'. Neuropathology: case 1  |
| III <sub>4</sub>                    | 62   | 35                | +               | +    | +                            | IIIb           | Only had to use sticks for walking 3 yr before seen  |
| III <sub>7</sub>                    | 64   | 35                | +               | +    | +                            | IIIb           | Said never to have run as well as other boys because R side was always weak. Very brisk and symmetrical tendon-jerks knee and ankle clonus   |
| IV <sub>1</sub>                     | 40   | ?                 | +               | -    | +                            | IIb            | Said he was perfectly normal but on questioning admitted some difficulty with cricket over the last year. Walks with circumduction of hips and has brisk reflexes with extensor plantar responses  |
| IV <sub>7</sub>                     | 42   | ?                 | +               | -    | -                            | I              | Not aware of his condition. Has difficulty in walking on heels and spasticity of legs with polyclonic reflexes and extensor plantar responses. No neurological signs could be elicited in his children V <sub>8</sub> who are respectively 17 and 9 yr old   |
| II <sub>1</sub>                     | Dr. Worster-Drought's report in 1944: 'straightforward spastic paraplegia which had been present for 30 yr'  |                   |                 |      |                              |                |  |
| II <sub>2</sub>                     | III <sub>7</sub> remembers he had walked on sticks from age of 35 and committed suicide from depression due to his increasing disability. Died about 59 yr of age  |                   |                 |      |                              |                |  |
| I <sub>2</sub>                      | Said to have been spastic and remembered by III <sub>7</sub> 'always to have walked with sticks'   |                   |                 |      |                              |                |  |
| <i>Family F</i>                     |  |                   |                 |      |                              |                |  |
| III <sub>1</sub>                    | died at 66   | 55                | +               | ?    | ?                            | ?              | Hospital notes say he began to have difficulty in walking at 55. One year before death, Dr. Samtain observed spastic paraplegia with objectively little hypertony of the legs, brisk reflexes, extensor plantar responses and no impairment of sensation. Died of embolism after prostatectomy operation. Neuropathology: case 2 |
| III <sub>3</sub>                    | 64   | 31                | +               | -    | +                            | IIIb           | Had Achilles tenotomies when aged 44. L pupil smaller than R but accommodation and consensual responses normal. Not worked for last 25 yr. It takes him several minutes to walk couple of feet   |
| III <sub>4</sub>                    | 61   | 1                 | +               | -    | -                            | IIIa           | Walked on toes since childhood but at only about aged 50 did walking begin to be difficult. Slow progression since   |
| IV <sub>2</sub>                     | Died when age 39 in heart failure (mitral stenosis developed after rheumatic fever when he was 10 years old). Little information, as mother too ill in hospital to be questioned. Hospital notes about his motor condition said, 'severe spastic congenital diplegia'. Necropsy not done |                   |                 |      |                              |                |  |
| II <sub>1</sub> and II <sub>2</sub> | Remembered by their sons and nephews to have walked with sticks for many years   |                   |                 |      |                              |                |  |
| I <sub>1</sub>                      | Said to have been stiff and walked with two sticks for 'many years'  |                   |                 |      |                              |                |  |

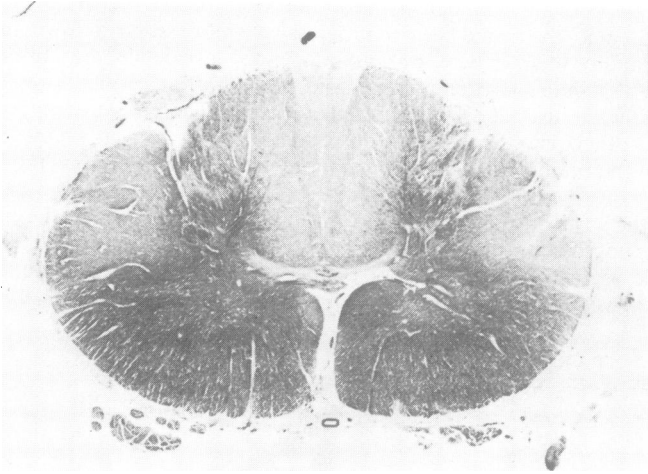

FIG. 7. Case 1. C6 Level. Moderate myelin pallor of lateral corticospinal tracts; severe pallor of gracile and cuneate fasciculi. Weil,  $\times 5$ .

there was relative sparing of the more lateral fibres in the posterior columns—that is, those portions closest to their point of entry—and entering posterior root fibres appeared entirely normal. As in the corticospinal tracts there was a fibrillar gliosis proportional to the degree of degeneration. No lipid degeneration products were seen.

Anterior horn cells appeared intact and no fibre

loss was detectable in anterior or posterior roots. Spinal arteries, veins, and meninges appeared normal throughout. There was no sign, in brain or cord, of any disease specifically affecting myelin sheaths.

Peripheral nerves (ulnar, median, femoral) and muscles (diaphragm, deltoid, vastus, gastrocnemius) all appeared normal.

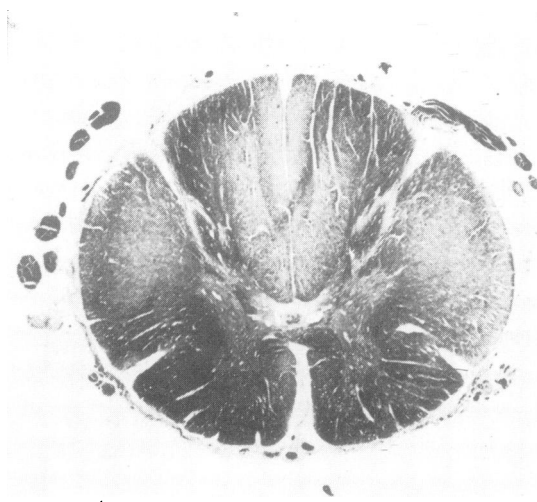


FIG. 8. Case 1. T1 Level. More severe myelin pallor of lateral corticospinal tracts; severe degeneration of gracile fasciculus, less involvement of cuneate fasciculus. Weil,  $\times 5$ .

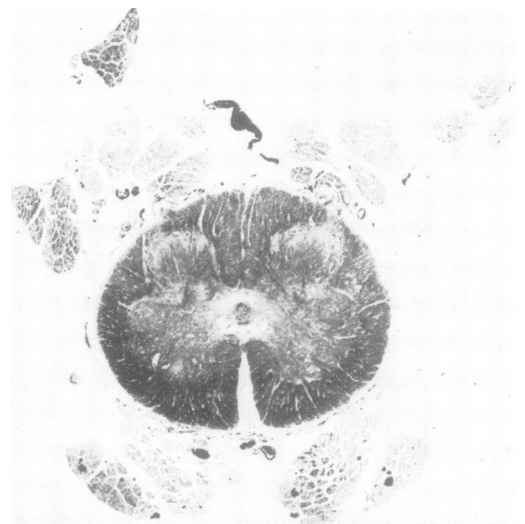
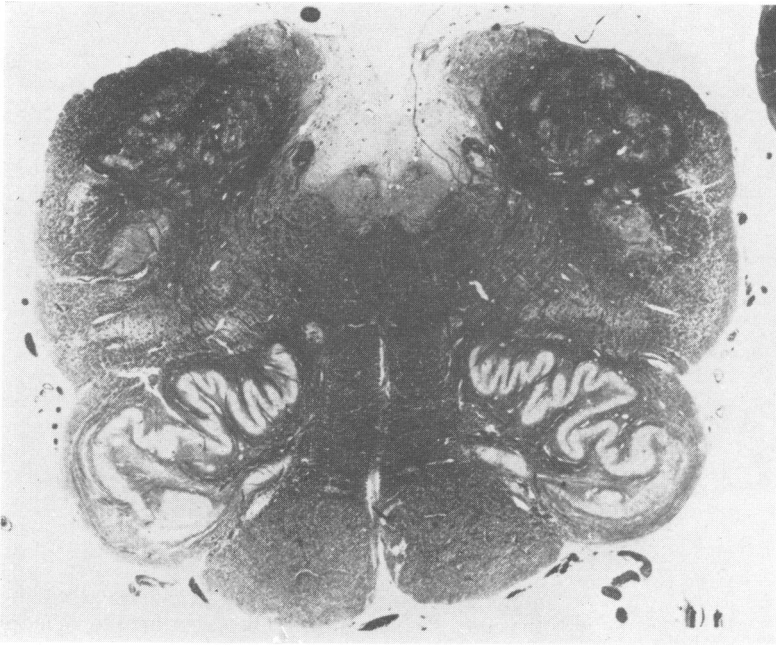
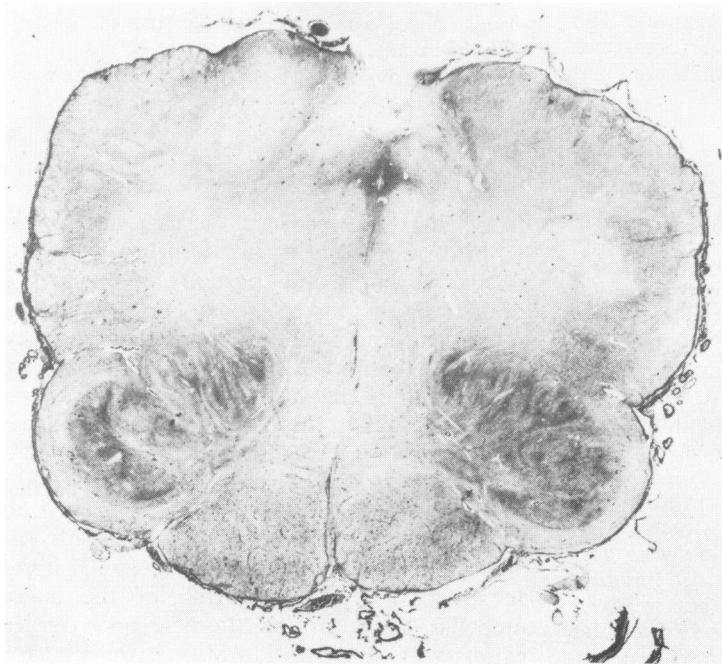


FIG. 9. Case 1. S1 Level. Lateral corticospinal and posterior columns just identifiable as areas of myelin pallor. Weil,  $\times 5$ .



**FIG. 10.** *Case 2. Medulla. Mild myelin pallor of pyramids. Weil, × 10.*



**FIG. 11.** *Case 2. Medulla. Mild gliosis of pyramids. Holzer, × 10.*

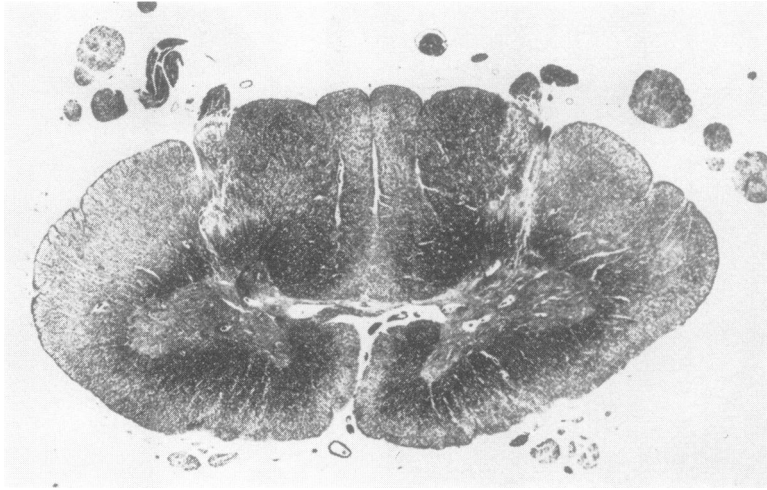


FIG. 12. Case 2. C8 Level. Moderate myelin pallor of lateral and anterior corticospinal tracts, and of fasciculus gracilis. Weil,  $\times 5$ .

#### CASE 2

Family F (III<sub>1</sub>). Died of pulmonary embolism after prostatectomy, aged 66 years.

**CENTRAL NERVOUS SYSTEM** *Macroscopic* The brain (1,250 g) was normal externally, with healthy vessels. On slicing, there was an infarct, 1 cm in diameter, involving the right lentiform and caudate nuclei, with part of the anterior limb of the internal capsule. The rest of the brain, spinal cord, nerve roots, and meninges appeared normal. Peripheral nerves and muscles were not available.

*Microscopic* Blocks were taken from the right basal ganglia, five levels of brain-stem, five levels of spinal cord, and anterior and posterior nerve roots. Customary stains were used.

The striatal infarct was of several months' standing, and could be related to a clinical episode of left hemiparesis a few months before death. It had not interrupted fibres passing through the cerebral peduncle, which appeared normal on both sides. Otherwise, no significant changes were seen in the brain apart from the medullary pyramids, which appeared somewhat pale in myelin stains (Figs 10 and 11).

In the cord there was degeneration of the corticospinal tracts (including the uncrossed tracts) at all levels. As in case 1, this became progressively more severe at lower levels (Figs 12 and 14). Posterior column degeneration was less severe than in case 1 but showed the same pattern, being barely detectable at sacral level and in the cuneate fasciculi, but pro-

gressively worse in the gracile fasciculi on ascending the cord. As before, thick fibres appeared to be more affected than thin ones, and there was a fine fibrillar gliosis in the degenerate tracts (Fig. 13) without visible lipid breakdown products. In the upper levels there was also a mild diffuse myelin loss in the lateral columns, without specific involvement of spinocerebellar tracts. Nerve cells in the anterior horns and thoracic nuclei (Clarke's columns) appear normal. There was no detectable loss of fibres in posterior or anterior nerve roots.

There was no sign of specific myelin disease in brain or cord.

#### DISCUSSION

Strümpell (1880) recorded the case histories of two brothers presenting in middle age with progressive weakness and spasticity involving predominantly the lower limbs. He was able to report the pathological findings on one of these cases later (Strümpell, 1886) and then the post-mortem findings in an unrelated but similar case (Strümpell, 1904). In both pathological specimens, the lesions were almost entirely confined to the spinal cord and consisted of degeneration of the lateral pyramidal tracts, increasing from cervical to lumbar region; there was less obvious involvement of the anterior corticospinal fibres. He noted slight degeneration of the lateral cerebellar tracts in the thoracic and cervical regions with degeneration also of the tracts of

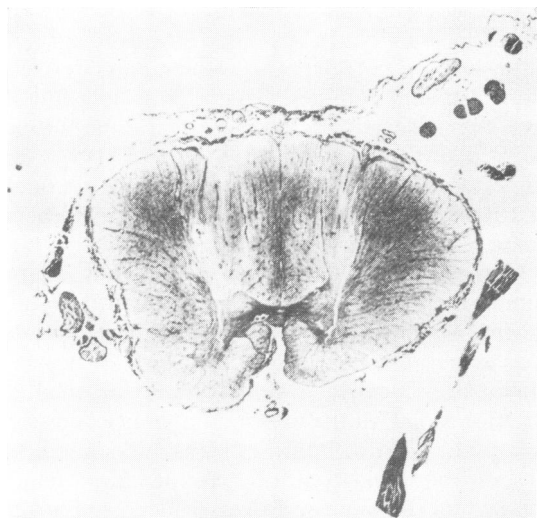

FIG. 13. Case 2. Upper thoracic level. Moderate gliosis of lateral and anterior corticospinal tracts, and of fasciculus gracilis. Holzer,  $\times 5$ .

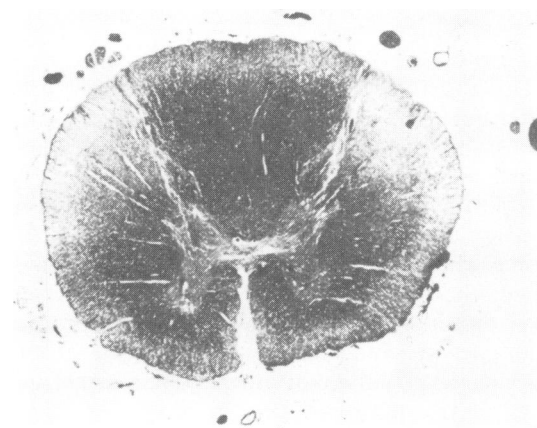


FIG. 14. Case 2. Lower thoracic level. Severe myelin pallor of lateral corticospinal tracts. Weil,  $\times 5$ .

ganglia, and medulla were not noted to be abnormal in either case.

The disease is sometimes classed along with the hereditary spinocerebellar degenerations (Greenfield, 1954). The pathogenesis in these diseases is thought to be that of simple neuronal atrophy or 'abiotrophy' as defined by Gowers (Greenfield, 1954)—namely, 'Slow decay of the nerve elements which have a common function, decay limited to these but extending throughout their entire extent'. Classification of the spinocerebellar degenerations and their related disorders has proved very difficult for two reasons. First, there is the difficulty of correctly allocating the site of the lesion to spinal cord or brain-stem on clinical examination alone. It is interesting in this context to note that several of the cases described by Marie as suffering from hereditary cerebellar ataxia were shown at postmortem examination to have lesions involving spinal cord alone (Greenfield, 1954). Secondly, patients are reported with combined forms of the diseases such as both Friedreich's ataxia and peroneal muscular atrophy, or as having transitional types of degeneration—for example, the Roussy-Lévy syndrome (hereditary areflexic dystasia) (Greenfield, 1954). Histological examinations, however, have sometimes shown that very different clinical pictures in the same family may be produced by similar pathological lesions which have a different intensity of damage at various points (Schut and Haymaker, 1951).

As first described, Strümpell's familial spastic paraplegia (SFSP) seemed to be a relatively circumscribed disease with a characteristic clinical and pathological picture, but since that time there have been numerous reports of SFSP associated in the same patient with spinocerebellar atrophies such as Friedreich's ataxia (Schut, 1950), hereditary spastic ataxia (Greenfield, 1963), or as in the Roussy-Lévy syndrome. Rhein (1916) first drew attention to the remarkable heterogeneity of signs and symptoms associated with the disease. Families are recorded in which spasticity is associated with dementia (Van Bogaert, 1952), mental deficiency (Johnston and McKusick, 1962), retinal degeneration (Jéquier and Streiff, 1947), retrobulbar neuritis (Bickerstaff, 1950), dysarthria, extrapyramidal disturbances (Dick and Stevenson, 1953), or pes cavus and amyotrophy (Garland and Astley,

Goll, present in one case (Strümpell, 1886) from lumbar region to medullary nuclei and in the other (Strümpell, 1904) from upper thoracic region to the medulla. There was also marginal degeneration of the cord, probably of no significance. The motor cortex, internal capsule, basal



1950). Rarely, the illness has also been described as occurring with the leucodystrophies, an interesting association in view of the inherited metabolic defects known to produce the latter (Poser *et al.*, 1957).

Strümpell's familial spastic paraplegia occurs far less frequently than spastic paraplegia associated with other defects. Indeed, Bell (1939) could find only one such family, after searching the records over 20 years in two London hospitals with large neurological departments. They cited 74 families published in the world literature up to 1939, but scrutiny of their clinical and family summaries indicates that in only 28 of these families was pure SFSP segregating in the members. Only one further family with SFSP has been reported from Great Britain since 1949 (Bickerstaff, 1950). However, Ozsváth (1968) was able to derive, from the literature and his own experience, 142 families with the disease. Since Ozsváth's review, a family of nine cases has been reported from Japan with members affected in four generations (Kirikae *et al.*, 1968) and Fontaine *et al.* (1969) have described another family with 10 cases in four generations.

With regard to the mode of inheritance, there appears to be general agreement that SFSP may be inherited as an autosomal dominant (probably in rather more than half of the families) or as an autosomal recessive gene. Two families with spastic paraplegia (Johnston and McKusick, 1962; Baar and Gabriel, 1966) where the pedigrees were compatible with X-linked recessive inheritance were not of pure spastic paraplegia. In both families the affected members showed early signs of brain-stem and cortical lesions.

Autosomal recessive forms tend to have an earlier onset and a more rapid progression, as pointed out by Bell (1939) and by subsequent reviewers. In almost all these cases the onset is under the age of 10 years, although occasional cases appearing up to 14 years of age have been reported. In contrast, the age of onset of those affected families where the inheritance appeared to be autosomal dominant is much higher—on the average over 20 years of age, and often not until early middle age. There is, however, an overlap between the ages of onset in the dominant and recessive forms, since in some cases with the dominant mode the onset may be in early childhood: in these latter cases it is interesting to note

that progression is usually very slow. Bell (1939) points to the high sib/pair correlations of ages of onset but low correlations between pairs derived from different families. That this is in general true seems clear from the published data but, as pointed out a long time ago (Rhein, 1916), in some families there is a very marked bimodal distribution of ages of onset—some members being affected much earlier than others.

Clinically, all the patients recorded here are similar to those described by other authors as having Strümpell's FSP. They presented with spastic paraplegia without any signs of ataxia, amyotrophy, extrapyramidal signs, or mental deterioration. All the affected patients examined by us had positive Babinski signs and some had absent abdominal reflexes. As the duration of the symptoms increased, loss of deep sensation in the lower limbs and pyramidal tract signs in the arms became increasingly common. All the patients seen were able to work until middle age, and only seven of them had been admitted to hospital for investigation. This could explain why Bell (1939) found so few records of patients in London hospitals and why only one family (Bickerstaff, 1950) has been reported from the United Kingdom in the last 20 years.

In most of our six families, the neurological signs and the rates of progression varied very little in the members. Typically, the first symptoms and signs were in the legs, spreading upwards much later to the arms. In a considerable proportion there was an impairment of deep sensation after the disorder had persisted for some time. Clinical findings suggested that sometimes the posterior columns were first affected and that in some cases the pathological process most severely affected pyramidal tracts at the cervical level with involvement of both arms and legs. It is noteworthy that in the two patients worst disabled from childhood (BIV<sub>3</sub> and BIV<sub>5</sub>), pyramidal tract signs in the upper limbs were present in both, by 23 and 21 years respectively, and that one of them (BIV<sub>5</sub>) already had impaired deep sensation.

With regard to the age of onset, two different patterns of disease emerge. In families C, D, and E, the history suggests that no members were affected below the age of 30 years and that on the whole the ages of onset, as judged by the account of patients and relatives, are highly correlated

within families. However, there is always considerable doubt as to the actual age of onset, so that sib/pair correlations within and between the families, or analysis of variance, hardly seemed justified.

The picture is different in families A, B, and F. In family A, three affected members first had trouble after 30 years of age, but in the other three the onset seems to have been much earlier. Perhaps not much reliance can be placed on the age of 17 years given for II<sub>7</sub>, but both II<sub>9</sub> and IV<sub>4</sub> were seen and had obvious disabilities in walking, as well as definite neurological signs. In four of the affected members of family B, the age when symptoms were first noted ranged from 21 to 30 years, but in the three others who were affected, and who were examined at 17, 21, and 23 years, it is impossible not to conclude that they walked late as children, and that when they first walked, they had talipes equinus and spastic paresis. Similarly, in family F, two members (II<sub>1</sub> and III<sub>3</sub>) had first symptoms at 55 and 30 years respectively, but III<sub>4</sub> and IV<sub>2</sub> both had obvious signs when they first walked in childhood.

Thus, there seem to be two groups of families as regards onset: in the first group the disease process starts in middle life and has a slowly progressive course (families C, D, and E); and in the second group, there is bimodal distribution: some members are affected in the second decade but others in childhood. The latter, however, show no increase in severity of the disease until about 30 years of age. There does not seem to be an adequate hypothesis to explain this bimodal distribution of age of onset.

Examination of the data in the Table does not suggest a strong correlation between clinical stage, age of onset, or duration of disability. However, no patients appeared to reach stage IV until at least 18 years after the symptoms had appeared. No stage IV patients and only one of the stage III patients examined still had no neurological signs in their arms, or unimpaired deep sensation.

The most plausible explanation of the inheritance of pure spastic paraplegia in all of these families, except family B, is that the trait is a regularly expressed autosomal dominant. Family B presents some problems. If I<sub>1</sub> and I<sub>2</sub> were indeed affected, and II<sub>1</sub> was not, then we have to postulate complete failure of penetrance in II<sub>1</sub>,

who must have been heterozygous. It is, of course, possible that II<sub>2</sub> had minimal signs or even symptoms but the history certainly did not suggest that he had any symptoms. If none of I<sub>1</sub>, I<sub>2</sub>, or II<sub>1</sub> was affected, then we have an example of a moderately common phenomenon whereby the characteristic has appeared all in one sibship for the first time but the trait is thereafter transmitted in a manner compatible with its being an autosomal dominant. Various explanations have been offered for this phenomenon, but whatever the explanation, the basic mechanism appears to be autosomal dominance in family B also.

It will be noted that of all those who are probably affected, even ignoring BI<sub>2</sub> and BII<sub>2</sub>, there is an excess of affected males. This seems to be a common feature in reported families. However, in the pedigrees here presented, it can be observed that there were, in fact, many fewer females 'at risk' than males, in the sense that they had a presumptive heterozygote parent. It is therefore not surprising that more males than females were affected in our six families.

In summary, the clinical picture of these patients is of a slowly progressive spastic paraplegia with impairment of deep sensation and spastic paresis of upper limbs in the late stages; there are no cerebellar signs, amyotrophy, or mental deterioration. Over the years, severe handicap develops.

As to the pathology, Schwarz (1952) provided an extensive review of the pathological literature (amounting to 24 cases), discarded several reports as being not relevant or not informative enough, and stated that he considered all neuropathological knowledge of the condition rested on the descriptions of seven cases—six described before 1912 and one in 1937. The cases were Strümpell's original two cases (Strümpell, 1886, 1904), Newmark's three (1904, 1906, 1911), and the single reports of Jakob (1909) and Kahlstorf (1937). In addition, he thought that possibly four others—two cases of Bischoff (1902) and the one described by Raymond and Rose (1909) and the case of Farago (1947)—might have been of the same condition. Reducing the descriptions of the disease to this small number, he found a uniformity in the lesions noted (*vide infra*). He added the pathological description of a typical case from a family which had been studied by Bayley

in 1897 and Spiller in 1902. Schwarz and Liu (1956) then reported the clinical findings in a further family with the necropsy study from a case in a different family, thus bringing the number of necropsies on acceptable cases of SFSP recorded in the literature to a total of nine.

In his first paper, Schwarz attempted to summarize the pathological features of all the seven previously reported cases thus: first, in all there was bilateral degeneration of the crossed corticospinal tracts, with involvement of the uncrossed tracts in four. The Betz cells were judged to be atrophic in three cases and the motor horn cells were reduced in number in one of these three specimens. With regard to the ascending fibres, there was invariably symmetrical degeneration of the fasciculus gracilis, visible at thoracic level and increasing at cervical regions up to the medullary nuclei. The spinocerebellar tracts were involved in four cases, with bilateral loss of fibres. No lipid degeneration products were found. Atrophy of the basal ganglia was mentioned in one case.

Having reviewed the literature up to 1950, Schwarz and Liu (1956) went on to discuss the 16 families which were reported between 1950 and 1955, with five neuropathological reports. Most of the reports dealt with patients showing Strümpell's FSP among other neurological deficits. Of the cases that came to necropsy, the two described by Appel and Van Bogaert (1952) were most similar to those previously characterized (the other three cases were of quadriplegic idiots). The first case was reasonably typical clinically. Pathologically, there was degeneration and gliosis of crossed pyramidal tracts in the spinal cord, with minor involvement of the uncrossed tracts. In the cervical levels of cord only there was slight degeneration of the gracile and cuneate fasciculi. There was, however, degeneration throughout the cord of anterior horn cells: an atypical finding in SFSP. On clinical examination the second case had a spastic quadriparesis, slight atrophy of the muscles of the calves, thighs, thenar eminences, and the backs of the hands, but the pathological examination was more characteristic of SFSP as previously described, with degeneration and gliosis of pyramidal tracts extending from the cerebral peduncle to the sacral levels, and similar changes in the posterior columns from the second thoracic

level to the medulla. There were no anterior horn cell changes. It has to be admitted that neither of these cases is typical of uncomplicated SFSP.

The two new cases that Schwarz reported showed findings similar to those expected. In the first case (1952), the brain-stem and cord only were examined. The major findings were of bilateral fibre loss in both crossed and uncrossed corticospinal tracts, worse at lower levels, with possible thinning of the medullary pyramids. The fasciculus gracilis showed slight loss of fibres at lower cervical level. Possible degeneration in the spinocerebellar tracts was commented on. The second case (Schwarz and Liu, 1956) was interesting in that all changes were so much more severe at thoracic level that the authors postulated that this was the original site of damage. Again, bilateral loss of fibres in the lateral corticospinal tracts was found, increasing caudally and most severe at thoracic level, and mild myelin pallor was recorded at the level of the pyramidal tract decussation. There was degeneration of the fasciculus gracilis from the lowest thoracic level upwards with a loss of neurones from Clarke's columns, but no involvement of the fasciculus cuneatus. The dorsal spinocerebellar tracts showed a fibre loss which could be traced into the medulla. Schwarz and Liu concluded also in this case, on the basis of counting procedures, that there was a reduction in the Betz cell population, and a loss of fibres in the medullary pyramids.

The two cases which we have examined histologically show the same pattern, with clear-cut lesions: corticospinal tract degeneration from the medullary pyramids downwards, increasing caudally, and posterior column degeneration, without loss of posterior root fibres, increasing rostrally. These findings are almost identical with those in Strümpell's original descriptions and those of Schwarz (1952) and Schwarz and Liu (1956). Thus a strong case can be made for regarding FSP, as originally described by Strümpell, as a well-defined clinical and pathological entity. Inheritance is autosomal, and usually dominant. It is rare, but not as uncommon as the paucity of reports would suggest, since many affected patients do not attend hospital. For the same reason, neuropathological reports have been very few. Accepting, as Schwarz does, Newmark's three cases and the

single cases of Jakob and Kahlstorf in addition to those of Strümpell, Schwarz, and Liu, the two cases reported here bring the total up to 11.

The nature of the disease, as with other primary neuronal degenerations, is obscure. At first sight, it appears to show, in common with other degenerations, the phenomenon of 'dying-back'—that is, a progressive withering of axons beginning at their terminations and proceeding towards the cell body, which eventually disappears. This 'dying-back' is a recognized feature of the corticospinal tracts in motor neurone disease, of the pontocerebellar fibres in olivopontocerebellar atrophy, and of the posterior spinocerebellar tracts in Friedreich's ataxia. On the other hand, there is no evidence, in SFSP, of the phenomenon of trans-synaptic, or 'chain' degeneration, seen in olivopontocerebellar degeneration and Friedreich's ataxia. It is worth noting, too, that the two tracts which are constantly affected in SFSP contain the longest fibres in the central nervous system: and that, in spite of the long duration of the disease, the cells of origin of these tracts—in the cerebral cortex and posterior root ganglia respectively—show little, if any, depletion at the time of death. It may well be that the mechanism of distal fibre degeneration in SFSP is different from that in the so-called 'system' degenerations, in which collections of neurones are affected regardless of the length of their axons. The findings, in fact, could be explained as the result of a generalized failure of nerve cells to maintain the vitality of axons of more than a certain length, rather than as a specific disease of particular types, or systems, of neurones. This conjectured difference may or may not be real; in any case, it cannot be assumed that the basic cause is the same in all kinds of primary neuronal degeneration.

Greenfield (1954) commented on Gower's abiotrophy theory in the pathogenesis of the spinocerebellar degenerations and suggested that the lesion would ultimately be found to be an enzyme deficiency. It has been shown that accidental organic phosphate poisoning in man has resulted in degeneration of long tract fibres—corticospinal and gracile—especially at the distal ends (Aring, 1942); and experimentally Cavanagh (1954), using tri-ortho-cresyl phosphate, and Fenton (1955) with di-iso-propyl-fluorophosphate, were able to reproduce similar but

more acute changes in chickens. The organic phosphates destroy pseudocholinesterase, an enzyme which has no known function in the central nervous system; but affection of other enzymes as well is a possibility. A premature ageing process has been suggested as the pathogenesis of various spinocerebellar disorders, a concept proposed by Raymond (1908) and then expanded to include a wide variety of familial or hereditary disorders which show distal axonal atrophy. In SFSP, no excess of the signs commonly associated with ageing in the central nervous system has been reported in the literature, nor did we see any in our cases.

One of the puzzling features of these disorders is the age of onset. It is difficult to understand how a system which has functioned well from birth to 30 years should then fail. In the case of metachromatic leukodystrophy we can understand why the disorder is not seen in infants before 2½ or 3 years of age, because it is known that aryl sulphatase-A deficiency will not produce an effect until myelin formation has occurred (Jatzkewitz, 1968). There is no explanation, however, for similar cases of this disorder starting in adulthood. Whether or not what is inherited in SFSP is a tendency to 'switch-over' enzyme production from normal to abnormal at a certain age, cannot be determined. Since the flow of nutrients is from perikaryon to axonal termination, it is understandable that the distal parts of the long axons would be affected first if there were any derangement in cell nourishment.

In conclusion, we consider that uncomplicated FSP is a well-defined clinical and pathological entity, and recommend the use of the eponymic term 'Strümpell's familial spastic paraplegia' to distinguish it from the bewildering array of familial system degenerations in which spastic weakness of the legs is only one feature in a complex or variable neurological picture.

#### ADDENDUM

Since the preparation of this paper, we have studied an additional case, with necropsy material. The patient was a man with a strong family history (mother, brother, two sisters) of difficulty in walking, who died at age 74 years, having been weak in the legs for an unknown

period. The findings in the brain and cord were almost identical with those in case 2 (above).

Our thanks are due to Dr. D. R. Oppenheimer, Dr. J. Trevor Hughes, and Professor A. C. Stevenson for their encouragement and help and to Dr. G. Rushworth for the EMG study. Dr. Peter Andrews kindly provided pathological material. We wish to acknowledge also the interest of the late Dr. C. Worster-Drought, who looked after case 1 and directed the material to us. M.M. is very thankful for the help she received from the various families. W.M.B. gratefully records financial support from the United Oxford Hospitals.

## REFERENCES

- Appel, L., and Van Bogaert, L. (1952). Études sur la paraplégie spasmodique familiale. 4. *Acta Neurologica et Psychiatrica Belgica*, **52**, 129–140.
- Aring, C. D. (1942). The systemic nervous affinity of tri-orthocresyl phosphate (Jamaica ginger palsy). *Brain*, **65**, 34–47.
- Baar, H. S., and Gabriel, A. M. (1966). Sex-linked spastic paraplegia. *American Journal of Mental Deficiency*, **71**, 13–18.
- Bell, J. (1939). On hereditary ataxia and spastic paraplegia. In *Treasury of Human Inheritance*. Vol. 4, pp. 141–281. Cambridge University Press: London.
- Bickerstaff, E. R. (1950). Hereditary spastic paraplegia. *Journal of Neurology, Neurosurgery, and Psychiatry*, **13**, 134–145.
- Bischoff, E. (1902). Pathologisch-anatomischer Befund bei familiärer infantiler spastischer Spinalparalyse. *Jahrbücher für Psychiatrie und Neurologie*, **22**, 109–127.
- Cavanagh, J. B. (1954). The toxic effects of tri-ortho-cresyl phosphate on the nervous system. An experimental study in hens. *Journal of Neurology, Neurosurgery, and Psychiatry*, **17**, 163–172.
- Dick, A. P., and Stevenson, C. J. (1953). Hereditary spastic paraplegia. Report of a family with associated extrapyramidal signs. *Lancet*, **1**, 921–923.
- Farago, I. (1947). Beitrag zur Vererbung und Pathohistologie der spastischen Spinalparalyse. *Monatsschrift für Psychiatrie und Neurologie*, **114**, 161–178.
- Fenton, J. C. B. (1955). The nature of the paralysis in chickens following organo-phosphorus poisoning. *Journal of Pathology and Bacteriology*, **69**, 181–189.
- Fontaine, G., Dubois, B., Farriaux, J. P., and Maillard, E. (1969). Une observation familiale de maladie de Strümpell-Lorrain. *Journal of Neurological Science*, **8**, 183–187.
- Garland, H. G., and Astley, C. E. (1950). Hereditary spastic paraplegia with amyotrophy and pes cavus. *Journal of Neurology, Neurosurgery, and Psychiatry*, **13**, 130–133.
- Greenfield, J. G. (1954). *The Spino-cerebellar Degenerations*. Blackwell: Oxford.
- Greenfield, J. G. (1963). System degeneration of the cerebellum, brain stem and spinal cord. In *Neuropathology*, 2nd edn, pp. 585–595. Edited by W. Blackwood, W. H. McMenemy, A. Meyer, R. M. Norman, and D. S. Russell, Arnold: London.
- Jakob, C. (1909). Sobre un caso de paraplegia espasmódica familiar progresiva con examen histopatológico completo. *Revista de la Sociedad Méd. Argentina*, **17**, 665–703.
- Jatzkewitz, H. (1968). Cerebral sphingolipidoses. In *Some Recent Advances in Inborn Errors of Metabolism*. Edited by K. S. Holt and V. P. Coffey. Livingstone: Edinburgh.
- Jéquier, M., and Streiff, E. B. (1947). Paraplégie, dystrophie squelettique et dégénérescence tapéto-rétinienne familiales. *Archiv der Julius Klaus-Stiftung für Vererbungsforschung, Sozialanthropologie und Rassenhygiene*, **22**, 129–167.
- Johnston, A. W., and McKusick, V. A. (1962). A sex-linked recessive form of spastic paraplegia. *American Journal of Human Genetics*, **14**, 83–94.
- Kahlstorf, A. (1937). Klinischer und histopathologischer Beitrag zur hereditären spastischen Spinalparalyse. *Zeitschrift für die gesamte Neurologie und Psychiatrie*, **159**, 774–780.
- Kirikae, T., Kashimura, H., Koizumi, A., Endô, G., and Fukase, K. (1968). A case of familial spastic paraplegia and his family. (Japanese.) *Clinical Neurology (Tokyo)*, **8**, 589–593.
- Newmark, L. (1904). Über die familiäre spastische Paraplegie. *Deutsche Zeitschrift für Nervenheilkunde*, **27**, 1–23.
- Newmark, L. (1906). Pathologisch-anatomischer Befund in einem weiteren Falle von familiärer spastischer Paraplegie. *Deutsche Zeitschrift für Nervenheilkunde*, **31**, 224–230.
- Newmark, L. (1911). Klinischer Bericht über den siebenten Fall von spastischer Paraplegie in einer Familie und Ergebnis der dritten Autopsie aus derselben Familie. *Deutsche Zeitschrift für Nervenheilkunde*, **42**, 419–431.
- Ozsváth, K. (1968). Paralysis spinalis spastica familiaris. *Deutsche Zeitschrift für Nervenheilkunde*, **193**, 287–323.
- Poser, C. M., Dewulf, A., and Van Bogaert, L. (1957). Atypical cerebellar degeneration associated with leucodystrophy. *Journal of Neuropathology and Experimental Neurology*, **16**, 209–237.
- Raymond, F. (1908). The relationship of the so-called family diseases to a premature physiological senescence localised to certain organic systems. *Lancet*, **1**, 1859–1862.
- Raymond, F., and Rose, F. (1909). Autopsie d'une maladie atteinte de paraplégie spastique familiale. *Revue Neurologique*, **17**, 781–785.
- Rhein, J. H. W. (1916). Family spastic paralysis. *Journal of Nervous and Mental Disease*, **44**, 115–144 and 224–242.
- Schut, J. W. (1950). Hereditary ataxia. Clinical study through six generations. *Archives of Neurology and Psychiatry*, **63**, 535–568.
- Schut, J. W., and Haymaker, W. (1951). Hereditary ataxia: a pathologic study of five cases of common ancestry. *Journal of Neuropathology and Clinical Neurology*, **1**, 183–213.
- Schwarz, G. A. (1952). Hereditary (familial) spastic paraplegia. *Archives of Neurology and Psychiatry*, **68**, 655–682.
- Schwarz, G. A., and Liu, C.-N. (1956). Hereditary (familial) spastic paraplegia. *Archives of Neurology and Psychiatry*, **75**, 144–162.
- Silver, J. R. (1966). Familial spastic paraplegia with amyotrophy of the hands. *Journal of Neurology, Neurosurgery, and Psychiatry*, **29**, 135–143.
- Strümpell, A. (1880). Beiträge zur Pathologie des Rückenmarks. *Archiv für Psychiatrie und Nervenkrankheiten*, **10**, 676–717.
- Strümpell, A. (1886). Ueber eine bestimmte Form der primären kombinierten Systemerkrankung des Rückenmarks. *Archiv für Psychiatrie und Nervenkrankheiten*, **17**, 227–238.
- Strümpell, A. (1904). Die primäre Seitenstrangklerose (spastische Spinalparalyse). *Deutsche Zeitschrift für Nervenheilkunde*, **27**, 291–339.
- Van Bogaert, L. (1952). Études sur la paraplégie spasmodique familiale. 5. *Acta Neurologica et Psychiatrica Belgica*, **52**, 795–807.