

Carcinomatous neuromyopathy:

1. Electrophysiological studies

An electrophysiological and immunological study of patients with carcinoma of the lung

M. J. CAMPBELL¹ AND D. W. PATY²

From the Muscular Dystrophy Group Research Laboratories, and the M.R.C. Unit on Demyelinating Diseases, Newcastle General Hospital, Newcastle upon Tyne

SYNOPSIS A high incidence of asymptomatic neuromuscular disease was found. More than half showed EMG evidence of a 'myopathy' and of denervation. The commonest syndrome was a neuromyopathy with myopathic units and spontaneous muscle activity, especially fasciculations and nerve fibre loss but with normal or near normal nerve conduction. This is thought to be the result of a neuronal or axonal disorder.

Since the detailed description of a pure sensory neuropathy or ganglioradiculopathy in two patients with small bronchial cancers (Denny-Brown, 1948), several specific neuromuscular syndromes have been recognized as non-metastatic complications of neoplastic disease (Brain and Norris, 1965). These include peripheral neuropathy (Heathfield and Williams, 1954; Henson *et al.*, 1954), dermatomyositis or polymyositis (Schuermann, 1951), and myopathy with myasthenic weakness (Anderson *et al.*, 1953; Lambert *et al.*, 1956). However, considerable controversy has persisted over the nature and frequency of a particular carcinomatous neuromuscular syndrome or neuromyopathy (Henson *et al.*, 1954; Brain and Henson, 1958), in which a symmetrical proximal limb weakness occurs in association with muscle wasting, depressed tendon reflexes and variably with other neuropathic features. Largely because of the frequent clinical diagnosis of neuromyopathy, the overall incidence of neuromuscular disease with cancer has been reported as 6% (Croft and Wilkinson, 1965); and was highest at 16% in males with carcinoma of the lung.

The purpose of our studies was: (1) To exam-

ine the various neuromuscular syndromes associated with cancer and to delineate them more fully in electrophysiological terms. With the exception of the myasthenic syndrome (Lambert *et al.*, 1956), the electrophysiological features have been poorly documented. Recognition of a specific clinical and electrophysiological pattern would be a considerable indirect aid in the detection of an occult neoplasm in those cases where the neuromuscular syndrome occurred first. (2) To study the incidence of neuromuscular disease in early lung cancer at the time of initial investigation. (3) To examine whether an immune mechanism was involved in the neuromuscular complications. The immunological studies are reported in the companion paper (Paty *et al.*, 1973).

METHODS

Three groups of patients have been studied—namely, 30 patients suspected of having lung cancer but in whom neurological complications had not been recognized or suspected; secondly, 11 patients with established carcinoma and well-recognized neurological complications who had been referred for a neurological opinion because of the latter; and thirdly, 13 patients with non-specific neuropathy but without any evidence of neoplastic disease.

¹ Present address: Frenchay Hospital, Bristol BS16 1LE.

² Present address: Department of Clinical Neurological Sciences, University of Western Ontario, London, Canada.

LUNG CANCER GROUP All patients admitted to two wards of a general hospital for bronchoscopy as possible cases of lung cancer were surveyed over a six month period. At the time of the clinical, electrophysiological, and immunological testing, the final diagnosis was not known. Patients over 70 years of age were immediately discarded from the electrophysiological study because of the known degenerative neuromuscular changes affecting normal subjects in this age group (Campbell *et al.*, 1973).

Patients were interviewed and a full clinical and neurological examination was made by one of us. Patients with other disease states or recent drug exposure liable to be complicated by neurological disease—for example, diabetes, alcoholism, or anti-tuberculous therapy—were not investigated further. Several blood estimations were made routinely, but no patient had to be removed subsequently from the survey because of undiscovered disease—for example, uraemia or vitamin B₁₂ deficiency. Of the 30 patients with lung cancer who were fully studied, the diagnosis was established histologically in 23. A presumptive diagnosis in the remainder was made on one or more criteria: radiographic mass lesion, bronchoscopy, or thoracotomy.

CARCINOMATOUS NEUROPATHY GROUP Eleven patients with known cancer and symptoms of peripheral nervous system disease were referred to us over the same period for a neuromuscular opinion and electrophysiological studies, and were subjected to the same studies. Six patients had received treatment for their carcinoma between three months and four years previously.

NON-CANCER GROUP Thirteen patients of similar mean age with chronic neurogenic disease, including eight with a sensorimotor polyneuritis of unknown aetiology, were also studied. The possibility of an associated neoplastic disease in these cases had been fully investigated.

ELECTROPHYSIOLOGICAL STUDIES Unipolar concentric needle electrode studies (Medelec) were made on a minimum of six muscles in each patient. The muscles generally sampled were deltoid, biceps, abductor pollicis brevis, vastus lateralis, tibialis anterior, and extensor digitorum brevis in the foot. The signals were examined with a low noise amplifier at 5 kHz to 2 Hz pass bandwidth and displayed on a Tektronix 564 storage oscilloscope. Records of any spontaneous electrical activity at rest, interference pattern on maximal volitional activity, and pattern of individual motor unit potentials on weak volitional activity were made for each muscle sampled.

Systematic measurement of individual motor unit parameters was not attempted.

An estimate of the number of functional motor units (motor unit index or MUI) of the extensor digitorum brevis (EDB) muscle of the foot was made, using graded electrical stimuli above threshold, and surface recording of the evoked muscle response (McComas *et al.*, 1971). Normal values for adults below 60 years of age have been estimated as 194 ± 56 (N=70) with a 95% range of 81–306 units.

The fastest motor conduction velocities in the median and peroneal nerves were estimated by standard techniques (Hodes *et al.*, 1948). Normal values for this laboratory are taken as 56.0 ± 3.1 and 48.1 ± 3.9 m/sec respectively. The distal motor latency to the end-plate zone was also recorded. Sensory nerve studies were made orthodromically on the median nerve by surface stimulation of the digital nerves in the index finger using silver strip ring electrodes (after Dawson, 1956). Square wave electric stimuli of 100 μ sec duration were delivered by an isolated constant voltage stimulator (Devices) triggered by an external time signal (Digitimer). Stimuli studied were supramaximal and at least two to three times threshold voltage. Nerve action potentials were recorded with saline-padded 0.5 cm diameter silver electrodes placed over the nerve at the wrist. Potentials were amplified by a low noise amplifier, having a 2–3 μ V noise level, and superimposed on a storage oscilloscope (Tektronix 564) together with an external time signal on a separate channel. The peak to peak potential size, and the latency to the initial positive peak, were recorded and the sensory conduction velocity was estimated over the studied distance. The lower limit of normal amplitude for the median nerve was taken as 10 μ V. All conduction studies were performed in a thermostatically controlled warm room, and the skin temperature was recorded with a surface thermistor. The temperature was adjusted to $36 \pm 1^\circ$ C with an infra-red lamp if necessary.

Neuromuscular transmission studies were performed on a number of patients and where clinically indicated. Supramaximal surface stimuli were delivered over the ulnar nerve at the wrist and an isometric muscle belly/tendon surface recording over the hypothenar muscles was made with the fingers clamped in a lead hand prosthesis. Repetitive stimuli 1, 3, 10, and 30/sec were usually studied over 50 stimuli. In three patients the 3/sec tests were supplemented by regional curarization studies to examine for curare hypersensitivity (Foldes *et al.*, 1968).

RESULTS

CLINICAL FINDINGS *Lung cancer group* The

diagnosis of lung cancer was eventually established in 28 of the 30 patients analysed. In one patient with a bloodstained pleural effusion who was treated by cytotoxic drugs, and in one man with recurrent haemoptysis, the diagnosis remains unproven. The subjects consisted of 24 males and six females with a mean age of 59 years (range 42–74). The histological diagnosis in 23 patients consisted of squamous cell (10), oat cell (six), totally undifferentiated (six), and adenocarcinoma (one).

By the very nature of the selection and referral of the patients for bronchoscopy, few had other than respiratory symptoms. Several were referred as a result of a routine radiographic demonstration of a mass lesion. However, eight patients had fairly advanced disease with considerable muscle wasting at the time of investigation. Fifteen patients (50%) are known to have died within six months of these studies. Only two patients (WT and HR) had significant neurological symptoms as one of the presenting features. This consisted of marked aching and

tenderness of muscle together with severe proximal limb weakness. One (HR) showed marked fatigue and developed variable diplopia in the last few days before he died. The tendon reflexes were found to be depressed or absent in both patients, but no sensory loss was demonstrated. On systematic inquiry, several patients gave vague complaints of weakness and fatigue, one described general muscle aching and cramps in the fingers, and three described mild fluctuating distal paraesthesiae, one together with unsteadiness. No sensory deficit could be demonstrated in these cases.

On clinical examination a total of 16 patients had demonstrable muscle weakness, always affecting the proximal muscles predominantly, especially the hip flexors. This was marked in seven patients and roughly correlated with the degree of muscle wasting and weight loss. Tendon reflexes were sluggish in 10 patients, but were only absent in the two patients described earlier. Some patients with muscle weakness showed very brisk reflexes, but other evidence of

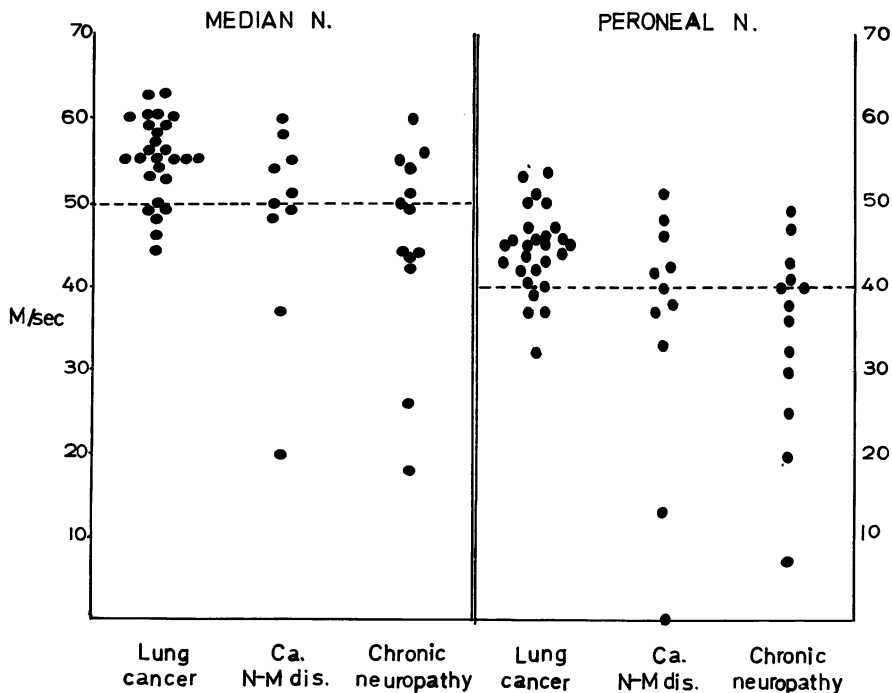


FIG. 1. Motor nerve conduction velocity studies. Normal values: median nerve (elbow to wrist) 56.0 ± 3.1 m/sec. Peroneal nerve (knee to ankle) 48.1 ± 3.9 m/sec.

a corticospinal lesion was not found. Only two of the oldest patients showed any sensory abnormality, consisting of distal impairment of vibratory sensibility in the legs, with some position sense impairment in one. One other patient (J.A.) was ataxic in excess of his muscular weakness, without obvious sensory loss, possibly due to cerebellar defect.

Carcinomatous neuropathy group This group consisted of seven males and four females with a mean age of 59 years (range 41–70). Seven patients had lung cancer, confirmed histologically in four (undifferentiated (two), oat cell type (one), and adenocarcinoma (one)). The remainder consisted of single cases of breast, colon, stomach, and disseminated anaplastic cancer, possibly arising from lung. One patient presented subacutely with the features of a severe distal sensorimotor polyneuropathy and tendon areflexia, coming on over a five week period and

three months after removal of a carcinoma of the colon. Four patients presented with symptoms of progressive weakness and wasting associated with a loss of weight over a three to 12 month period. Only one complained of mild paraesthesiae, but three had a demonstrable mild sensory deficit. In three, the weakness was mainly proximal, markedly in one with associated muscle tenderness, and two had depressed tendon reflexes. Two of these patients had brisk reflexes and extensor plantar responses, but in addition had recent symptoms referable to cerebral metastases. Four patients presented with progressive severe proximal limb weakness and wasting over a three to 14 month period, affecting walking, climbing stairs, and later lifting and dressing. Three of these patients had recently experienced fluctuant mild diplopia, and one (I.W.) had more serious bulbar symptoms with mild dysphagia and dysarthria. They also had total loss of tendon reflexes and were subsequently confirmed as

TABLE 1
LUNG CANCER STUDY

Patient	Age (yr)	Sex	Histology	Electromyography	Motor unit* index	Nerve† conduction
1 R.R.	49	M	Oat cell	Myopathic, fasciculations	58	ABN
2 W.T.	64	M	Oat cell	Myopathic, fibrillations, fasciculations	92	ABN
3a T.T.	49	M	Squamous	Normal	125	N
3b T.T.	49	M	Squamous	Myopathic, fasciculations	55	ABN
4 G.B.	63	M	Undifferentiated	Myopathic, chronic denervation, fasciculations	220	N
5 N.F.	47	M	Squamous	Myopathic, fibrillations and fasciculations	112	N
6 J.M.	64	M	No biopsy	Myopathic, chronic denervation, fasciculations	32	N
7 D.R.	48	M	Undifferentiated	Myopathic (mild)	104	N
8 W.S.	61	M	Squamous	Myopathic, fibrillations, ?fasciculations	248	N
9 J.T.	44	M	Squamous	Myopathic	95	N
10 G.Mc.	60	M	No biopsy	Myopathic	114	?N
11 T.J.	64	M	Unproven	Myopathic, chronic denervation, fasciculations	43	?N
12 J.A.	62	M	Squamous	Myopathic	164	N
13 M.E.	69	M	Squamous	Myopathic	256	N
14 F.M.	69	M	No biopsy	Myopathic	182	N
15 O.Mc.	42	F	Undifferentiated	Myopathic	330	N
16 H.R.	49	M	Squamous	Myopathic	—	L-E syn
17 S.B.	66	M	Squamous	Chronic denervation	76	ABN
18 F.F.	70	M	Adenocarcinoma	Active denervation, fasciculations	124	ABN
19 J.H.	52	F	Squamous	Chronic denervation (mild)	178	N
20 J.P.	66	M	Squamous	Chronic denervation (mild)	10	ABN
21 L.T.	63	M	Undifferentiated	Chronic denervation	167	N
22 G.C.	48	F	Oat cell	?Normal	312	N
23 A.F.	49	M	Undifferentiated	Normal	177	N
24 W.N.	57	M	Oat cell	Normal	190	N
25 C.S.	67	F	Undifferentiated	Normal	172	N
26 T.W.	52	M	No biopsy	?Normal	220	N
27 W.C.	74	M	Oat cell	—	—	—
28 W.J.	50	M	No biopsy	—	—	—
29 M.N.	43	F	Oat cell	—	—	—
30 M.P.	57	F	Undiagnosed effusion	—	—	—

* Normal motor unit index of extensor digitorum brevis muscle = 194 ± 56 .

† ABN = subnormal fastest velocity (median nerve = 56.0 ± 3.1 m/sec, peroneal nerve = 48.1 ± 3.9 m/sec). L-E syn = myasthenic (Lambert-Eaton syndrome). N = Normal.

having the myasthenic syndrome of the Lambert-Eaton type. The non-myasthenic patient (E.K.) with proximal muscle atrophy together with brisk reflexes had had a partial gastrectomy for a gastric neoplasm four years previously. Investigations failed to disclose another cause—for example, malabsorption—for her symptoms. Of the two remaining patients, one had progressive ascending paraesthesiae, weakness, clumsiness, and sphincter disturbance commencing one year after radiotherapy for carcinoma of the bronchus, and was thought to have a radiation myelopathy. The other patient (M.B.), aged 70 years, had mild distal paraesthesiae and numbness only, without obvious signs on neurological testing.

Non-cancer group These 13 patients with chronic neuropathic disease consisted of nine males and four females with a mean age of 62.5 years. The clinical diagnosis and other features

are shown below in Table 3. Most patients had pronounced distal limb weakness with depressed reflexes and some sensory loss. One man had tabes dorsalis with distal wasting and weakness in his legs, and a second had signs of a peripheral neuropathy and a subnormal serum vitamin B₁₂ level (63 µg/ml.). One elderly woman is included who had gross ataxia and proximal limb weakness with minimum sensory deficit of unknown cause. An underlying neoplasm was strongly suspected but repeated investigations were negative.

ELECTROPHYSIOLOGICAL FINDINGS *Lung cancer group* The results are summarized in Table 1 together with the histological diagnosis, where known. Twenty-six patients only were studied but the results in one man (T.T.) are given twice because of a marked change in the physiological and other findings three months later. Several other patients were restudied after an interval,

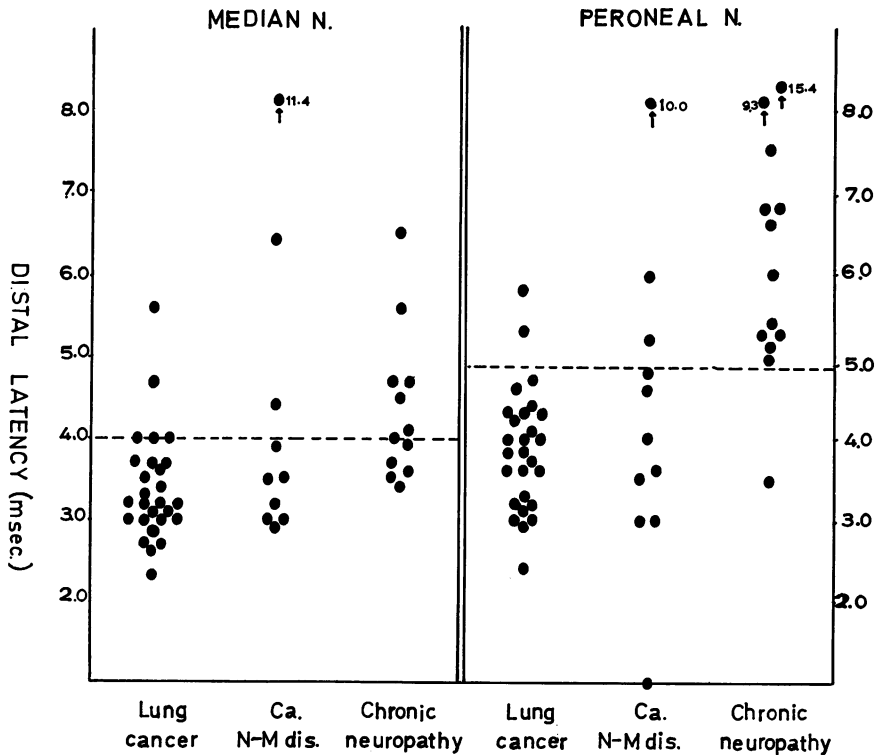


FIG. 2. Motor nerve conduction distal latencies. Median nerve (wrist to APB)—normal < 4.0 msec. Peroneal nerve (ankle to EDB)—normal < 5.0 msec.

TABLE 2
CARCINOMATOUS NEUROPATHY GROUP

Patient	Age (yr)	Sex	Histology	Electromyography	Motor unit* index	Nerve* conduction
1 J.R.	70	M	Adenocarcinoma colon	Active denervation, fasciculations	0	ABN
2 W.R.	56	M	Undifferentiated	Chronic denervation, fasciculations	102	ABN
3 M.B.	70	F	Breast	Active denervation	—	N
4 G.H.	62	M	Adenocarcinoma lung	Active denervation, myopathic units, fasciculations	3	ABN
5 M.C.	68	F	Lung (no biopsy)	Chronic denervation, myopathic units	73	N
6 E.K.	41	F	Stomach (undifferentiated)	Myopathic	—	?N
7 D.H.	52	M	Lung (undifferentiated)	Myopathic	—	L-E syn
8 S.H.	55	M	Lung (undifferentiated)	Chronic denervation, fibrillations	70	ABN
9 J.L.	66	M	Lung	Chronic denervation, myopathic, fasciculations	—	ABN
10 J.R.	55	M	Lung	Myopathic	53	L-E syn
11 I.W.	56	F	Lung (oat cell)	Myopathic	82	L-E syn

* See footnotes to Table 1.

but no significant change either way was found.

The striking finding in the electromyographic studies was the presence of small amplitude short duration motor unit potentials, some polyphasic, in 16 (53%) of the patients. This 'myopathic' change was always present, or most severe, in the proximal muscles (deltoid, biceps,

or quadriceps) and roughly correlated with the degree of muscle wasting. It also correlated with the advanced state of the tumour, since nine of the 16 patients are known to have died within six months of the study. Eleven of these patients had coexistent features of denervation. Spontaneous activity in the shape of fibrillation or fasciculation potentials was present in eight subjects. A number of patients showed spontaneous potentials at rest which were difficult to characterize by accepted criteria for fibrillations or fasciculations (Buchthal and Rosenfalck, 1966; Trojaborg and Buchthal, 1968). They were 200–500 μ V in amplitude and briefer than normal unit potentials in duration (being 3–6 msec), and were sometimes of abnormal wave form or polyphasic. They have been included here as fasciculation potentials. One additional patient (F.F.) with severe denervation also showed fibrillation and fasciculation potentials, hence spontaneous activity was present in nine (30%) patients. The changes of chronic denervation alone were seen in four patients—that is, a reduced interference pattern with an excess of large amplitude, prolonged duration, and commonly polyphasic motor unit potentials. In only five patients were the electromyographic (EMG) findings considered within normal limits. The motor unit index in extensor digitorum brevis muscle, as a measure of the number of functional motor fibres, was significantly reduced below the 95% limit in six patients, and below the normal range in a further five. Except in two patients with EMG changes of chronic denervation only, the

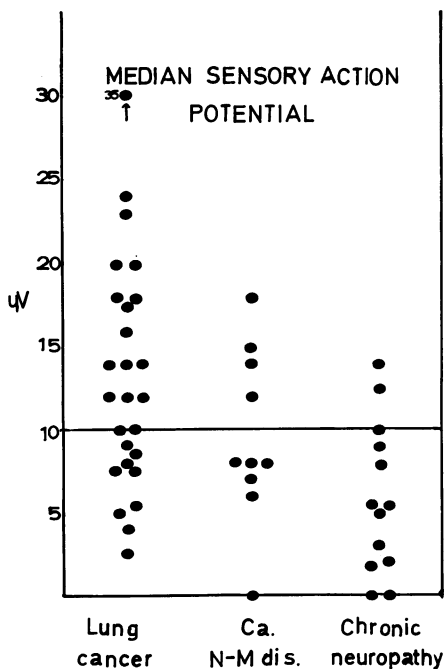


FIG. 3. Median nerve sensory action potentials. Index finger to wrist—normal > 10 μ V.

low MUI correlated with the more severe 'myopathic' changes and with spontaneous fasciculation activity.

The nerve conduction studies revealed mild abnormalities in six patients, but in only four was this confirmed in two separate nerves (Fig. 1). The distal motor latency was prolonged in the peroneal nerves of two patients and in the median nerves of two others, one of whom almost certainly had a coexistent carpal tunnel syndrome (Fig. 2). The sensory nerve action potential in the median nerve, as an indication of the number of large diameter sensory fibres, was significantly reduced in nine patients (Fig. 3) but the conduction velocity was slowed below 40 m/sec in only three cases. Taken together, the nerve conduction studies indicate a mild peripheral neuropathy of non-demyelinative type in four patients only, but evidence of significant loss of motor and sensory nerve fibres was present in nine cases. Repetitive nerve stimulation studies were performed on 13 patients. One (H.R.) demonstrated a mild form of the myasthenic (Lambert-Eaton) syndrome with a small initial evoked muscle response decreasing further on 1 and 3/sec stimulation but showing progressive facilitation on tetanic stimulation at 30/sec, increasing by 66% over 50 stimuli. Three other patients showed significant fatigue on fast tetanic stimulation at 50/sec, with the muscle response decreasing by 47-51% over 50 stimuli. Two of these patients (W.T. and N.F.)

were acutely ill and had clinical evidence of muscle weakness; the other had a mild sub-clinical peripheral neuropathy.

Carcinomatous neuropathy group The EMG studies were abnormal in all 11 patients with neuromuscular disease and known cancer (Table 2). A 'myopathic' picture was seen in seven patients, and was combined with changes of denervation in three subjects, two of whom showed spontaneous fasciculations. Fasciculations were seen together with evidence of denervation in two other patients. Low motor unit counts gave evidence of denervation in seven patients. The motor nerve conduction studies in the patient with a severe sensorimotor polyneuropathy showed moderate slowing in surviving fibres, being 37 m/sec in the median and 46 m/sec in the ulnar nerves. This is in keeping with an axonal neuropathy. Conduction in surviving sensory fibres was normal. The diagnosis of the Lambert-Eaton myasthenic syndrome was made clinically in no less than three patients and confirmed on repetitive nerve stimulation by a 66-600% increase in the evoked response on tetanization, and by prolonged paralysis to d-tubocurarine at 1/16 or 1/8 of a normal curarizing dose. The proximal nerve conduction studies in these cases were normal (Fig. 1). Nerve conduction studies in the other four patients with clinical evidence of proximal muscle weakness and wasting showed marked

TABLE 3
NON-CANCER CHRONIC NEUROPATHY GROUP

Patient	Age (yr)	Sex	Histology	Electromyography	Motor unit* index	Nerve* conduction
1 R.K.	69	M	Idiopathic polyneuritis	Chronic denervation	11	ABN
2 A.B.	63	M	Idiopathic polyneuritis	Chronic denervation, fibrillations, fasciculations	—	ABN
3 C.W.	68	M	Idiopathic polyneuritis	Chronic denervation	14	ABN
4 N.T.	56	M	Idiopathic polyneuritis	Chronic denervation, fasciculations	0	ABN
5 J.E.	68	M	Idiopathic polyneuritis	Chronic denervation, fibrillations, fasciculations	3	ABN
6 M.E.	67	F	Idiopathic polyneuritis	Myopathic, fibrillations, fasciculations	12	ABN
7 R.R.	68	M	Idiopathic polyneuritis	Chronic denervation, fasciculations	8	ABN
8 G.R.	58	M	Idiopathic polyneuritis	Chronic denervation, fasciculations	15	ABN
9 C.P.	63	M	Vitamin B ₁₂ deficiency	Chronic denervation, myopathic, fasciculations	—	?N
10 S.P.	60	F	Bilateral carpal tunnel syndrome ?myxoedema	Chronic denervation, fibrillations	215	N
11 W.W.	59	M	Tabes dorsalis	Chronic denervation, fibrillations, fasciculations	125	N
12 L.P.	14	F	Peroneal muscular atrophy	Chronic denervation	2	N
13 J.B.	67	F	Cerebellar degeneration + proximal myopathy ?aetiology	Myopathic	—	N

* See footnotes to Table 1.

slowing of conduction in one severe case (G.H.) in keeping with segmental demyelination, mild slowing in the peroneal nerves only in two, and normal findings in one (M.C.). Normal conduction was found in the remaining three patients. Sensory nerve potentials were studied in the 10 patients and subnormal potential was found in eight, but was unobtainable in one patient (G.H.) only (Fig. 3).

Non-cancer group The physiological studies in this group are summarized in Table 3. An abnormal motor unit index in eight of 10 patients studied, and a reduced sensory potential in 10 patients demonstrated widespread nerve fibre loss. Slowing of nerve conduction was found in seven patients, but was severe due to presumed demyelination in two patients only (Fig. 1). Of some interest was the finding of spontaneous fasciculations in eight patients, and combined myopathic and denervation changes with fasciculations in two patients, including a patient with a subnormal serum B₁₂ level (63 µg/ml.).

DISCUSSION

The incidence of symptomatic neuromuscular disease in this small series of patients with lung cancer was 7%. This figure compares with 5% in a series by Trojaborg *et al.* (1969) and up to 16% by Croft and Wilkinson (1965). However, half our patients showed clinical weakness of proximal limb muscles, and one-third had depressed tendon reflexes. Aching and muscle tenderness were present in two patients, but sensory symptoms were otherwise generally absent. Of the total of 13 patients studied with significant symptomatic neuromuscular disease related to cancer, one had a subacute sensorimotor polyneuropathy, four had a myopathic-myasthenic (Lambert-Eaton) syndrome, one had a proximal myopathic picture alone, and five patients had a neuromyopathic syndrome (Brain and Henson, 1958). Neuromyopathy as understood here consists of symmetrical proximal muscle weakness and wasting, together with depressed tendon reflexes and minimal distal sensory disturbance in some patients. Nine of our patients had primary lung cancer, of various histological cell types. Unfortunately, we did not

have the opportunity to study cases of primary sensory neuropathy or dermatomyositis.

The clinical presentation in the four patients with the myasthenic syndrome was remarkably similar and resembled that described by Eaton and Lambert (1957). Contrary to the concept of many people in differentiating this disease from myasthenia gravis, all the patients had cranial nerve involvement and complained of variable diplopia. One patient had more severe bulbar symptoms with dysphagia and dysarthria in addition to ptosis and extraocular muscle weakness. All patients showed absent tendon reflexes.

The electrophysiological studies in the prospective group of patients with lung cancer revealed a surprisingly high incidence of subclinical abnormality. Of the 26 patients studied, these were normal in only five. The overall picture was of a frequent combination of 'myopathic' disorder in proximal muscles together with evidence of denervation in approximately half the patients. The severity of these changes corresponded roughly with the degree of muscle wasting and weakness. A similar high incidence of EMG abnormality in bronchial carcinoma was found by Thage *et al.* (1963) at 50%, and Trojaborg *et al.* (1969) at 44%. Although small amplitude, short duration muscle potentials are commonly regarded as indicating primary muscle disease, they undoubtedly may be seen in neurogenic disorders—for example, in more acute forms of the Guillain-Barré syndrome or motor neurone disease, and during nerve regeneration after traumatic injury. Of the 16 patients with such a 'myopathic' disorder, 11 also showed EMG features of denervation, including nine with low motor unit counts in a distal muscle.

Spontaneous muscular activity as further evidence suggestive of neurogenic disease was found in nine patients. This included fasciculation potentials, some smaller and briefer in duration than normal units, suggesting anterior horn cell dysfunction. Shy and Silverstein (1968), in a study of 36 patients with muscular weakness and cancer, found myopathic potentials in 15 of 27 patients, studied physiologically, five of whom also showed evidence of neurogenic disorder. Seven of these patients had spontaneous fasciculation potentials. Trojaborg *et al.* (1969), in an EMG study of lung cancer patients, found 'spon-

taneous discharges of short duration' in 17 of 47 clinically normal patients, and in two of four patients with areflexia. However, they analysed 20 individual motor unit potentials in a muscle from each patient and found evidence of myopathy—that is, a shortened average mean duration (MAPD) together with excessive polyphasia—in only one case. In our study, a subnormal sensory nerve action potential was found in nine patients as further evidence of significant loss of nerve fibres. However, conduction studies on asymptomatic cancer patients were normal in the surviving fibres in all except for two patients. The latter, as in two patients with symptoms of neuromyopathy, showed very mild slowing of motor conduction only.

An overall analysis of these physiological findings in patients with significant neuromuscular disease related to cancer, revealed certain distinct patterns for the specific clinical syndromes. In the four patients with the myopathic-myasthenic syndrome similar electrophysiological features to those described in the literature were found (Lambert *et al.*, 1956). The EMG pattern consisted of mainly small amplitude, short duration motor unit action potentials in the proximal muscles without spontaneous activity or other evidence of reinnervation secondary to chronic denervation. Conduction in the myelinated segment of motor and sensory nerves was entirely normal, but the characteristic abnormality of neuromuscular transmission was found in each case. This consisted of a subnormal evoked single muscle response, showing further rapid fatigue at slow rates of stimulation (1–5/sec), but progressive facilitation on tetanic stimulation (30–50/sec) to greater than 66% above the initial amplitude. An abnormal sensitivity to curare was also demonstrated in these patients (Anderson *et al.*, 1953) with prolonged paralysis to 1/8 of a normal dose or less.

The largest group comprised five patients with neuromyopathy. Myopathic units, together with evidence of chronic denervation, were found in four of these patients, and spontaneous activity including fasciculation potentials was also present in four. Motor unit estimation (MUI) and sensory or mixed nerve action potential measurements indicated significant nerve fibre loss in three of the patients. Nerve conduction

was delayed in four of the five patients, but showed severe slowing in one patient only. This man (G.H.) was acutely ill and died a few days later. Indeed, with this one exception, it would appear that those cases with evidence of a mild peripheral neuropathy are indistinguishable clinically from other cases of neuromyopathy with normal conduction. Also these cases of neuromyopathy appear identical with those called 'mild terminal peripheral neuropathy' by Croft *et al.* (1967). In the one case studied here of a subacute sensory and motor polyneuropathy, the nerve conduction studies again showed moderate slowing only in surviving fibres to a degree not normally associated with segmental demyelination (Gilliatt, 1968).

A search of the literature has shown remarkably few cases where the degree of slowing is consistent with primary demyelination. Hence we would suggest that neoplasia, by its as yet unknown mechanism, commonly results in progressive neuronal and axonal disease with minimal slowing of conduction in nerve fibres until at a late stage in the survival of the nerve fibre, when secondary segmental demyelination may occur. Evidence for a similar mechanism of interrelationship between axonal and Schwann cell function has been reported in chronic uraemia (Dyck *et al.* 1971) and in experimental acrylamide neuropathy (Hopkins, 1970), and probably occurs in amyotrophic lateral sclerosis (Lambert, 1968).

Similar electrophysiological findings to those in carcinomatous neuromyopathy were found in over half of the elderly patients with chronic neuropathy of unknown aetiology. It will be of considerable interest to follow these patients for evidence of subsequent malignancy or, alternatively, to establish any other specific pathogenesis. The combination of 'myopathic' units and spontaneous fasciculation activity in neuromuscular disease is most unusual in our experience.

Histological studies of muscle biopsy material obtained from random patients with malignant disease (Hildebrand and Cöers, 1967) showed a high incidence of abnormalities and were normal in only three of 20 cases of carcinoma of the bronchus. Scattered atrophic muscle fibres were found in biopsies from 50% of patients and a diffuse atrophy occurred in a further three cases.

Terminal nerve fibre sprouting, suggestive of re-innervation activity after denervation, was seen in nine (45%) cases. These changes correlated with the degree of weight loss and muscle wasting in the patients. The authors suggested that the changes were the result of malnutrition, but this would appear most unlikely. Full electrophysiological studies in young subjects with anorexia nervosa (Buchthal, 1970) and cachexia secondary to neglected simple schizophrenia (Campbell and McComas, 1969) have been entirely normal. Shy and Silverstein (1965) also examined muscle biopsy material from 36 patients with neuromuscular disease related to cancer. In 22 instances the neurological disorder preceded diagnosis of the malignancy by up to four years. The histological appearances in material from all 27 patients with neuromyopathy were abnormal. Architectural changes in individual muscle fibres suggestive of a myopathy were present in all, and combined features of myopathy and neurogenic atrophy were found in 80% of the cases.

Croft *et al.* (1967) have described the pathological changes in peripheral nerves of patients with peripheral neuropathy associated with cancer. They described abnormalities of both the axons and myelin sheaths, but suggested that the latter were more severe and may occur alone. These studies were largely made on post-mortem material, with its attendant artefactual changes. Teased fibre preparations from a single sural nerve biopsy of a 68 year old woman with oat cell carcinoma of the bronchus showed no direct evidence of demyelination but a few internodes were of reduced length and diameter suggestive of remyelination. However, electrophysiological studies on that patient revealed mild to moderate slowing of motor conduction only, suggestive of an axonal neuropathy. We do not exclude the possibility, however, that a number of the cases of subacute carcinomatous polyneuropathy with severe sensory loss may be due to direct disease of the Schwann cell and myelin sheath. We do not have comprehensive pathological material from our cases of neuromyopathy, but we conclude that the physiological studies suggest a primary neuronal or axonal disorder. Despite the proximal distribution to the muscle weakness and the presence of 'myopathic' potentials in EMG studies, there was no other evidence of a primary muscle disorder in these cases.

SUMMARY

Quantitative electrophysiological studies have been performed in a prospective group of 30 patients with lung cancer, in 11 patients with known cancer and symptomatic neuromuscular disease, and in 13 age-matched patients with chronic non-specific neuropathy.

Only two (7%) of the lung cancer group presented with significant neurological symptoms, but clinical examination revealed proximal limb weakness of variable severity in 16 patients (53%) and depressed tendon reflexes in 10 cases. The two symptomatic patients had the clinical picture of a neuromyopathy—that is, symmetrical proximal muscle weakness, together with depressed tendon reflexes and mild sensory disturbance. One later developed double vision and blurring and was shown to have a myasthenic-myopathic (Lambert-Eaton) syndrome.

A high incidence of EMG abnormalities was also found in these lung cancer patients as evidence of subclinical neuromuscular disease. Sixteen patients showed numbers of small amplitude, short duration (myopathic) motor unit action potentials in proximal muscles, 11 of whom also had features of chronic denervation, including eight with spontaneous fasciculations. Signs of chronic denervation were evident in four other patients. Quantitative physiological studies, including motor unit estimations and measurements of sensory nerve action potentials, confirmed significant loss of nerve fibres in nine patients. Nerve conduction studies were generally normal but occasionally showed mild slowing, as evidence of a mild peripheral neuropathy, in four patients. The electrophysiological and clinical findings appeared to correlate with the degree of weight loss and muscle wasting, and also with the advanced state of the neoplastic disease. However, no close correlation between the neuromuscular disorder and the tumour cell could be made.

The detailed clinical and electrophysiological findings in four patients with the myopathic-myasthenic (Lambert-Eaton) syndrome, one patient with a subacute sensorimotor polyneuropathy, and five patients with the neuromyopathy syndrome are described. It is concluded that the neuromyopathic syndrome is associated with unusual and characteristic EMG

findings of prominent 'myopathic' abnormalities in proximal muscles together with scattered spontaneous activity, especially fasciculations. Evidence of loss of motor and sensory nerve fibres is commonly present but nerve conduction is usually normal or only mildly delayed except in the later stages. Evidence is given to suggest that the pathological basis of the neuromyopathy is a neuronal and axonal disorder, and that segmental demyelination is uncommon and likely to be an end-stage secondary phenomenon in most cases.

We should like to thank our many colleagues for their help and encouragement in studying patients under their care. Our special thanks are gratefully given to Dr. J. R. Lauckner, Dr. P. O. Leggatt, and Dr. E. A. Spriggs, and other members of the staff of the Department of Chest Medicine for the ready co-operation and helpful criticism of this study through its formative stages. One of us (M.J.C.) was supported by the Medical Research Council during his study; the other (D.W.P.) was in receipt of a travelling fellowship from the University of Western Ontario, London, Canada. Additional financial and technical support was provided by the Muscular Dystrophy Group of Great Britain. Secretarial assistance was provided by Miss P. Arthur.

REFERENCES

- Anderson, H. J., Churchill-Davidson, H. C., and Richardson, A. T. (1953). Bronchial neoplasm with myasthenia. Prolonged apnoea after administration of succinylcholine. *Lancet*, **2**, 1291-1293.
- Brain, Lord, and Norris, F. H., Jr. (1965) (Eds). *The Remote Effects of Cancer on the Nervous System*. Grune and Stratton: New York.
- Brain, Sir R., and Henson, R. A. (1958). Neurological syndromes associated with carcinoma. *Lancet*, **2**, 971-975.
- Buchthal, F. (1970). Electrophysiological abnormalities in metabolic myopathies and neuropathies. *Acta Neurologica Scandinavica*, **46**, Suppl. 43, 129-176.
- Buchthal, F., and Rosenfalck, P. (1966). Spontaneous electrical activity of human muscle. *Electroencephalography and Clinical Neurophysiology*, **20**, 321-336.
- Campbell, M. J., and McComas, A. J. (1969). Unpublished observations.
- Campbell, M. J., McComas, A. J., and Petito, F. (1973). Physiological changes in ageing muscle. *Journal of Neurology, Neurosurgery, and Psychiatry*, **36**, 174-182.
- Croft, P. B., Urich, H., and Wilkinson, M. (1967). Peripheral neuropathy of sensorimotor type associated with malignant disease. *Brain*, **90**, 31-66.
- Croft, P. B., and Wilkinson, M. (1965). The incidence of carcinomatous neuromyopathy in patients with various types of carcinoma. *Brain*, **88**, 427-434.
- Dawson, G. D. (1956). The relative excitability and conduction velocity of sensory and motor nerve fibres in man. *Journal of Physiology*, **131**, 436-451.
- Denny-Brown, D. (1948). Primary sensory neuropathy with muscular changes associated with carcinoma. *Journal of Neurology, Neurosurgery, and Psychiatry*, **11**, 73-87.
- Dyck, P. J., Johnson, W. J., Lambert, E. H., and O'Brien, P. C. (1971). Segmental demyelination secondary to axonal degeneration in uremic neuropathy. *Mayo Clinic Proceedings*, **46**, 400-431.
- Eaton, L. M., and Lambert, E. H. (1957). Electromyography and electric stimulation of nerves in diseases of the motor unit. *Journal of the American Medical Association*, **163**, 1117-1124.
- Foldes, F. F., Klonymus, D. H., Maisel, W., and Osserman, K. E. (1968). A new curare test for the diagnosis of myasthenia gravis. *Journal of the American Medical Association*, **203**, 649-653.
- Gilliatt, R. W. (1966). Nerve conduction in human and experimental neuropathies. *Proceedings of the Royal Society of Medicine*, **59**, 989-993.
- Heathfield, K. W. G., and Williams, J. R. B. (1954). Peripheral neuropathy and myopathy associated with bronchogenic carcinoma. *Brain*, **77**, 122-137.
- Henson, R. A., Russell, D. S., and Wilkinson, M. (1954). Carcinomatous neuropathy and myopathy. A clinical and pathological study. *Brain*, **77**, 82-121.
- Hildebrand, J., and Coërs, C. (1967). The neuromuscular function in patients with malignant tumours. Electromyographic and histological study. *Brain*, **90**, 67-82.
- Hodes, R., Larrabee, M. G., and German, W. J. (1948). The human electromyogram in response to nerve stimulation and the conduction velocity of motor axons. *Archives of Neurology and Psychiatry*, **60**, 340-365.
- Hopkins, A. (1970). The effect of acrylamide on the peripheral nervous system of the baboon. *Journal of Neurology, Neurosurgery, and Psychiatry*, **33**, 805-816.
- Lambert, E. H. (1968). Electromyography in amyotrophic lateral sclerosis. In *Motor Neuron Diseases*, pp. 135-153. Edited by H. Norris Jr., and L. T. Kurland. Grune and Stratton: New York.
- Lambert, E. H., Eaton, L. M., and Rooke, E. D. (1956). Defect of neuromuscular conduction associated with malignant neoplasms. (Abstract.) *American Journal of Physiology*, **187**, 612-613.
- McComas, A. J., Fawcett, P. R. W., Campbell, M. J., and Sica, R. E. P. (1971). Electrophysiological estimation of the number of motor units within a human muscle. *Journal of Neurology, Neurosurgery, and Psychiatry*, **34**, 121-131.
- Paty, D. W., Campbell, M. J., and Hughes, D. (1973). An immunological and electrophysiological study of carcinomatous neuromyopathy. 2. Immunological studies. *Journal of Neurology, Neurosurgery, and Psychiatry*. (In press.)
- Schuermann, H. (1951). Maligne Tumoren bei Dermatomyositis und progressiver Sklerodermie. *Archiv für Dermatologie und Syphilis (Berlin)*, **192**, 575-582.
- Shy, G. M., and Silverstein, I. (1965). A study of the effects upon the motor unit by remote malignancy. *Brain*, **88**, 512-528.
- Thage, O., Trojaborg, W., and Buchthal, F. (1963). Electromyographic findings in polyneuropathy. *Neurology (Minneapolis)*, **13**, 273-278.
- Trojaborg, W., and Buchthal, F. (1965). Malignant and benign fasciculations. *Acta Neurologica Scandinavica*, **41**, Suppl. 13, 251-254.
- Trojaborg, W., Frantzen, E., and Andersen, I. (1969). Peripheral neuropathy and myopathy associated with carcinoma of the lung. *Brain*, **92**, 71-82.