

# Anterior Segment Optical Coherence Tomography for Tear Meniscus Evaluation and its Correlation with other Tear Variables in Healthy Individuals

ANURADHA RAJ<sup>1</sup>, RENU DHASMANA<sup>2</sup>, RAMESH CHANDER NAGPAL<sup>3</sup>

## ABSTRACT

**Introduction:** Dry eye is one of the most common ocular diseases in this cyber era. Despite availability of multiple tests, no single test is accurate for the diagnosis of dry eye. Anterior segment optical coherence tomography is the recent tool which can be added in the armamentarium of dry eye tests.

**Aim:** To evaluate tear meniscus with anterior segment optical coherence tomography and its correlation with other tear variables in normal healthy individuals.

**Materials and Methods:** In this prospective cross-sectional observational study, right eye of 203 consecutive patients were studied. All the patients were divided into three groups Group 1, 2 and 3 according to their age  $\leq 20$  years, 21-40 years and  $>40$  years respectively. All patients underwent routine ophthalmologic examinations along with slit-lamp biomicroscopy for tear meniscus height measurement, tear film break up time, Schirmer's I test (with anaesthesia) and optical coherence tomography imaging of inferior tear meniscus height.

After focusing of the instrument with a Cross Line (CL) centered on lower tear meniscus at 6'o clock of cornea, a 6 mm long scan was obtained. The tear meniscus height ( $\mu\text{m}$ ) and tear meniscus area ( $\text{mm}^2$ ) were measured manually with help of callipers by joining upper corneo-meniscus junction to the lower lid-meniscus junction and tear meniscus height and area

within the plotted line respectively and calculated by using the integrated analysis available in the custom software.

**Results:** There was significant decrease in the all tear variables with the increase in the age. According to age groups in group 1, the mean Schirmer's ( $24.0 \pm 4.9$ )mm, tear film break up time ( $11.1 \pm 1.9$ ) sec, tear meniscus height on slit lamp ( $600.2 \pm 167.3$ )mm were higher but decreased in group 2 ( $21.5 \pm 5.4$ ,  $10.8 \pm 1.4$ ,  $597.5 \pm 186.3$ ) and group 3 ( $19.8 \pm 5.1$ ,  $10.2 \pm 1.6$ ,  $485.6 \pm 157.7$ ) respectively. Schirmer's test values and tear film break up time were similar in both sexes ( $p=0.1$  and  $p=0.9$ ). Tear meniscus height on slit lamp and Optical coherence based tear meniscus area were similar in both sexes ( $p=0.5$  and  $p=0.1$ ). However, tear meniscus height on optical coherence tomography was significantly higher in females ( $p=0.04$ ).

Value of Schirmer's and tear film break up time ( $r=0.2$ ;  $p=0.001$ ) and Schirmer's and tear meniscus height on slit lamp ( $r=0.6$ ;  $p<0.001$ ) had positive correlation. Tear meniscus height and tear meniscus area on optical coherence tomography had positive correlation ( $r=.9$ ;  $p<0.001$ ).

**Conclusion:** On optical coherence tomography tear meniscus height and area significantly correlated. Despite higher values of Schirmer's, tear film break up time, Slit lamp based tear meniscus height in younger age group the tear meniscus height and tear meniscus area with optical coherence tomography were lower.

**Keywords:** Tear film break up time, Tear meniscus height, Tear meniscus area

## INTRODUCTION

The three layered tear film creates a smooth ocular surface for passage of light through the eye, nourishes and provides protection from infection. Blinking initiates renewal of tear film to maintain the ocular surface integrity, clear vision and comfort [1]. The balance of the system is affected by components such as tear secretion, spreading, evaporation and drainage [2]. Tear meniscus refers to the tears lying at the junction of the bulbar conjunctiva and both lid margins and it act as indicator of tear volume because it forms 75-90% of it [3].

Tear meniscus has a concave air-tear interface due to hydrophobic corneal surface and lower eyelid. Various techniques like micrometry, strip meniscometry, photography and videography have been used to measure tear meniscus height (TMH) and volume [4]. The disadvantages of these techniques are of using visible light and fluorescein. Few other newer tests like tear interferometry, corneal topography and tear evaporimetry can be used for examination of tear meniscus [5]. Optical Coherence Tomography (OCT) employs low coherence interferometry to produce detailed cross sectional images of the anterior and posterior segment. OCT is noninvasive, real time and promising method to evaluate the tear meniscus. Tear menisci examination may be helpful in diagnosis of dry eye, as they decrease in dry eye.

TMH can be considered as the measurement of tear volume. The good repeatability of measurements of tear meniscus variables using OCT had been verified previously by Wang and Shen et al., [6,7]. It provides in vivo technique for quantitative measurement of tear film and tear meniscus without ocular surface contact or dye instillation. Cui et al., reported the decline in tear meniscus parameters with age [8]. Tear volume decreases in normal subjects with advancing age [9].

Dry eye is one of the most common disease of the eye. In the modern cyber era dry eye is getting more common due to the influx of air-conditioners, computer usage, traffic pollution and extreme weather hazards. There are limitations to diagnose early stages of dry eye in asymptomatic patients. The tests for dry eye includes Schirmer's, Tear Film Break Up Time (TBUT), rose bengal staining, etc which confound the results by disrupting the natural tear film. Rose bengal and fluorescein staining are conclusive only in advanced cases of dry eye [10]. Earliest diagnosis of dry eye require minimally invasive objective and reliable tool. Normal patients can undergo Anterior Segment Optical Coherence Tomography (ASOCT) to measure tear meniscus parameters without any discomfort. ASOCT provides objective, noninvasive, fast, reliable and quantitative method to diagnose dry eye at the earliest. Fourier-domain Optical Coherence Tomography (FD-OCT)

system, RTVue (Optovue, Inc, Fremont, CA, USA) was used for the present study. FD-OCT has much greater speed than conventional time-domain OCT. The resolution of FD-OCT system is higher than other commercially available ASOCT systems, which gives more precise measurements [11]. The OCT has depth resolution of 5µm due to shorter wavelength 830nm. This study was done to correlate the various quantitative tear variables with the tear meniscus dimensions on OCT. This is the first study to compare the slit lamp based TMH with the OCT based TMH.

## MATERIALS AND METHODS

This was a prospective observational case series in a tertiary care centre Himalayan Institute of Medical Sciences, Swami Rama Himalayan University, Dehradun, Uttarakhand, India over a period of six months from June 2014 to December 2014. After obtaining the formal written approval from ethical committee, the study was conducted as per declaration of Helsinki.

Written and informed consent was obtained from all the subjects before including them in the study. A total of 203 patients were included in the study. Sample size was calculated by formula as  $1.962(0.05)^2/.012$  which came out to be 96. In this study more than 96 required patients were taken to justify the data.

### Inclusion criteria

Patients with minor ocular ailments like foreign body sensation or burning sensation and with any kind of refractive error were included in the study.

### Exclusion criteria

Established cases of dry eye TBUT of <5 seconds or Schirmer's test reading of <5 mm, with known ocular diseases, history of intraocular, refractive surgeries or contact lens use, eyelid pathologies, conjunctival disorders (e.g. symblepharon and conjunctivochalasis) and those with prosthetic eyes were excluded. Cases with dacryocystitis, permanent or temporary occlusion of lacrimal puncta and with history of systemic illness like diabetes, hypertension, collagen vascular disorders or any use of systemic medications were also excluded.

All the patients were further divided into three groups according to their age (Group 1) ≤ 20 years, (Group 2) 21-40 years and (Group 3) >40 years.

All patients underwent routine ophthalmologic examinations including visual acuity testing, slit-lamp bio-microscopy along with TMH measurement, intraocular pressure measurement, TBUT and posterior segment evaluation. In addition, all patients underwent Schirmer's test II (with anaesthesia 0.5% proparacaine (Proparacaine hydrochloride ophthalmic solution, 0.5%, Alcon Laboratories) to rule out reflex tearing and OCT imaging.

OCT imaging of tear meniscus was done before Schirmer's and TBUT to avoid their influences on imaging.

The TBUT was recorded in seconds, from the time of eyelid opening to the appearance of the first dry spot formation on the cornea. Schirmer's test II was performed by placing a Schirmer's strip (Whatman no.41 filter paper 5mm x35mm) at the junction of the mid and lateral thirds of the lower eyelid after instillation of one drop of proparacaine and removal of the excess fluid with a dry cotton-tipped applicator. Subsequently, the patient was instructed to look forward for five minutes with normal blinking. After 5 minutes, the Schirmer's strip was removed, and wet strip was measured.

### OCT imaging procedure

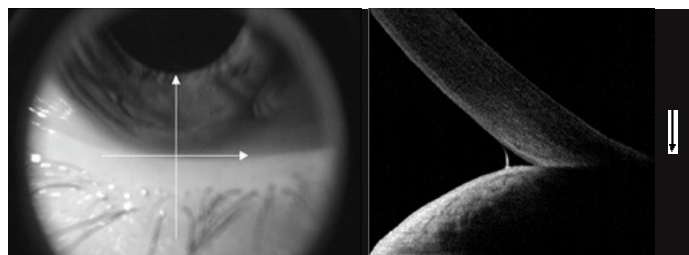
The imaging of inferior tear meniscus was done at the lower cornea-lid junction with a 6mm vertical × 2.8mm depth scan using a Fourier-domain OCT system (RTVue, Optovue, Inc., Fremont, CA). For each patient, only measurements from the right eye were included for analysis.

An FD-OCT system with a Corneal Adaptor Module (CAM) was used which produces telecentric scanning for anterior segment imaging using either a wide-angle or high-magnification adaptor lens which was placed in front of the retinal objective lens of RTVue to focus the OCT beam on the anterior segment. We used the wide-angle lens, which provides a scan of up to 6mm and a transverse resolution of 15 µm. A set of gooseneck lights were used to illuminate the anterior segment for concurrent video imaging and for fixation of the contralateral eye. All tests were performed in a dim lit room between 21-25°C with regulated humidity to avoid reflex tearing. All patients were instructed not to use any topical eye drops at least 2 hours before testing to negate the effect of medication on tear film. Patients were asked to look straight ahead at the fixating target within the OCT system. Subjects were instructed to blink and OCT measurements were taken immediately after blinking to avoid the effects of delayed blinking. The OCT pattern used to scan the lower tear meniscus was CL-cross line with its two lines, horizontal on lower lid margin and vertical on inferior cornea at 6'0 clock hour [Table/Fig-1]. One or more images were taken until a good quality scan, showing the concave profile of the tear meniscus from the inferior lid margin to the corneo-conjunctival surface, were captured [Table/Fig-2].

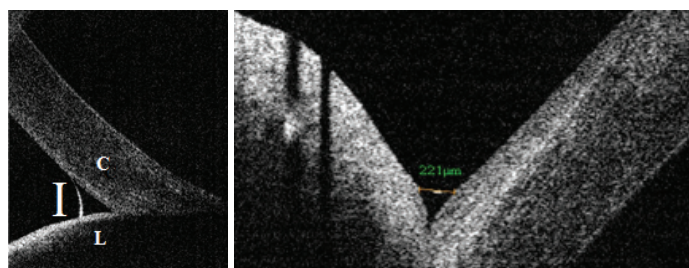
All measurements were taken from the inferior tear meniscus because of the fact of less visualisation and less retention of upper tear meniscus due to presence of eye lashes.

Tear Meniscus cross-section Area (TMA) and TMH were measured from the inferior tear meniscus in mm<sup>2</sup> and µm. The analysis included 90°clockwise canvas rotation, to obtain a vertical visualization of the anterior segment section and a change in the image size, so that the height of each image measured 40 mm (10x magnification in comparison to the original 4-mm long vertical scan obtained by the instrument).

The OCT images were exported for computer callipers using RTVue software (version 4.0, Optovue) for measurements of lower TMH and TMA. The TMH was manually calculated by joining the points corresponding to the upper corneo-meniscus junction to the lower eyelid-meniscus junction with the "measure tool" [Table/Fig-3a,b]. Area was measured by plotting the two lines joining the TMH and area within the plotted line was TMA [Table/Fig-4a,b]. Cross-sectional OCT images of lower TMA and TMH were processed and calculated with integrated analysis custom software in their respective units.



**[Table/Fig-1]:** A CL-cross line on with horizontal line on lower lid margin and vertical line on inferior cornea at 6'0 clock hour. **[Table/Fig-2]:** The whole tear meniscus as visualised by optical coherence tomography.



**[Table/Fig-3]:** (a) Shows the tear meniscus height can be calculated by a line joining the point where upper extremity merges with corneo-conjunctival surface(C) and the point where lower extremity merges with the eyelid(L). (b) Tear meniscus height(TM-H) on OCT.

## STATISTICAL ANALYSIS

Data were initially entered into an excel spreadsheet and then transferred to SPSS software (Statistical Package for Social Sciences, version 22, SPSS Inc, Chicago, IL). To avoid statistical complications from correlation between the right and left eyes, measurements from only the right eye of each patient were analysed. Data were expressed in terms of means±standard deviations. The change in tear variables in different groups was compared by using Independent t-test. When data was not normally distributed Mann-Whitney U-test was used to compare the values. Kruskal-Wallis test was used to compare the age related changes among tear variables. A p-value less than 0.05 were considered statistically significant. Pearson correlation test was used to correlate various tear variables with OCT based tear meniscus dimensions.

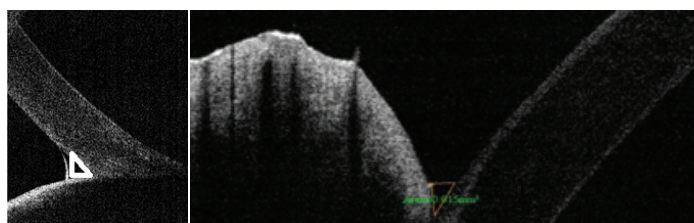
## RESULTS

Normal healthy eyes of 203 patients were included in the study with 116 (57%) males and 87(43%) females with age in range of 16-88 years (mean±standard deviation 44.7±16.7). Group 1 and 2 comprised of 11 and 81 patients respectively. Maximum patients 111(54.67%) were in group 3 [Table/Fig-5].

It was observed that the mean Schirmer's (21.2±5.2)mm and TBUT (10.5±1.5)sec were higher in males as compared to mean schirmer's (20.2±5.4)mm and TBUT (10.5±1.7)sec in females, however this difference was not statistically significant (p=0.11 and p= 0.98). Values of TMH on slit lamp and TMA on OCT were higher in females as compared to males but were statistically non-significant (p=0.5 and p=0.1). Mean TMH on OCT in females (262.2±122.3)µm was higher than males (233.8±70.8)µm which was statistically significant (p=0.04) [Table/Fig-6].

According to age groups in group 1 the mean Schirmer's (24.0±4.9) mm, TBUT (11.1±1.9)sec, TMH on slit lamp (600.2±167.3) µm were higher but decreased in group 2 (21.5±5.4,10.8±1.4, 597.5±186.3) µm and group 3(19.8±5.1,10.2±1.6,485.6±157.7) µm respectively. Value of OCT based TMH was significantly lower in group 1 (214.7±19.7) µm as compared to significantly highest in group 3 (254.3±102.5) µm. It was found that in group 1 value of OCT based TMH had small SD (±19.6) in comparison to group 3 (±102.5) which indicate that in higher age group so much variability can be seen. Value of OCT based TMA in group 1 was lower (0.02±0.001)mm<sup>2</sup> as compared to group 2 and 3 which was statistically non-significant (p= 0.2) [Table/Fig-7].

There was a positive correlation between value of Schirmer's and TBUT (r =.225;p= 0.001). Schirmer's and Slit lamp based TMH values also showed positive correlation(r =.562; p<0001). OCT based TMH and TMA also showed significantly positive correlation (r =.908; p< 0.001) but no correlation with Schirmer's test and slit lamp based TMH [Table/Fig-8].



**[Table/Fig-4]:** (a) Graphic representation of tear meniscus area (TMA) by plotting two lines joining tear meniscus height and area within plotted lines. (b) Shows tear meniscus area (TMA).

Age in Years	Number of patients
Group 1(<20 Yrs)	11
Group 2(21-40 Yrs)	81
Group 3(>40 Yrs)	111
Total	203

**[Table/Fig-5]:** Distribution of patients in different age groups.

## DISCUSSION

Age shows its impact on the tear film which can be studied by various tests like Schirmer's and TBUT [12]. In the present study the tear variables like Schirmer's, TBUT and TMH on slit lamp were higher in younger age group as compared to older age group which showed consistency with Mathers et al., [9].

Blinking spreads the tear film on ocular surface and maintains the balance between tear secretion and loss. Inferior tear meniscus correlates well with the tear volume. For precise and accurate measurement of tear volume, 3-4 seconds are required prior to image the tear meniscus [13].

Schirmer's test is reliable test in severe dry eye as suction effect of the meniscus opposes the entry of tears on to the Schirmer's strip [14]. OCT appears to be a promising tool for estimating tear film production [15]. The first OCT device to measure the tear film

Tear variables	Male	Female	95% Confidence interval of the difference		p-value*
			Lower	Upper	
Schirmer's(mm)	21.2±5.2	20.2±5.3	-0.2	2.7	0.11
TBUT(sec)	10.5±1.5	10.5±1.7	-0.4	0.4	0.98
TMH Slit(µm)	528.4±184.0	546.5±171.9	-68.2	32.1	0.48
TMH OCT(µm)	233.8±70.7	262.1±122.2	-55.3	-1.3	0.04
TMA OCT(mm <sup>2</sup> )	0.02±0.001	0.02±0.03	-0.01	0.001	0.11

**[Table/Fig-6]:** Gender related changes in tear variables.

TBUT: tear film break up time  
TMH Slit: tear meniscus height by slit lamp  
TMH OCT: tear meniscus height by optical coherence tomography  
TMA OCT: tear meniscus area by optical coherence tomography  
p-value\* - p-value estimated by independent t-test

Tear variables	Group I	Group II	Group III	p-value <sup>†</sup>
Schirmer's(mm)	24.0±4.9	21.4±5.3	19.8±5.1	0.007
TBUT(sec)	11.0±1.8	10.8±1.4	10.2±1.6	0.005
TMH Slit(µm)	600.2±167.3	597.5±186.3	485.5±157.7	0.00001
TMH OCT(µm)	214.7±19.6	237.9±93.8	254.2±102.5	0.02
TMA OCT(mm <sup>2</sup> )	0.01±0.001	0.02±0.02	0.02±0.03	0.18

**[Table/Fig-7]:** Age related changes in tear variables.

TBUT: tear film break up time  
TMH Slit: tear meniscus height by slit lamp  
TMH OCT: tear meniscus height by optical coherence tomography  
TMA OCT: tear meniscus area by optical coherence tomography  
p-value<sup>†</sup> - p-value estimated by Kruskal-Wallis test

		Schirmer (mm) OD	TBUT (sec) OD	TMH slit (µm) OD	TMH OCT (µm) OD	TMA OCT (mm <sup>2</sup> ) OD
Schirmer (mm) OD	Pearson Correlation	1	.225**	.562**	0.133	0.117
	Sig. (2-tailed)		0.001	0.000	0.059	0.096
	N	203	203	203	203	203
TBUT (sec) OD	Pearson Correlation	0.225**	1	0.138*	-0.018	0.007
	Sig. (2-tailed)	0.001		0.050	0.801	0.921
	N	203	203	203	203	203
TMH slit (µm) OD	Pearson Correlation	0.562**	0.138*	1	0.130	0.085
	Sig. (2-tailed)	0.000	0.050		0.065	0.229
	N	203	203	203	203	203
TMHOCT (µm) OD	Pearson Correlation	0.133	-0.018	0.130	1	0.908**
	Sig. (2-tailed)	0.059	0.801	0.065		0.000
	N	203	203	203	203	203
TMA OCT(mm <sup>2</sup> ) OD	Pearson Correlation	0.117	0.007	0.085	0.908**	1
	Sig. (2-tailed)	0.096	0.921	0.229	0.000	
	N	203	203	203	203	203

**[Table/Fig-8]:** Showing correlations between various tear variables and OCT based tear meniscus dimensions.

\*\* Correlation is significant at the 0.01 level (2-tailed).  
\* Correlation is significant at the 0.05 level (2-tailed).



was TD-OCT which was designed for retinal imaging [16]. FD-OCT measures the tear parameters in more accurate state [11]. Furthermore, RTVue-CAM has a telecentric geometry, thereby reducing the image distortion that results from differences in air-tissue indices [17]. In the present study OCT based TMH was higher in older patients as compared to young patients which was quite unusual. The factors such as impairment of nasolacrimal drainage patency [18] or flaccid muscle around lacrimal passage [19] may cause increased TMH and volume. No difference in tear meniscus was noticed between younger and elderly subjects which can be attributed to limited age range or less sensitive methodology leading to reflex tearing [20]. A significant positive correlation was observed between Schirmer's and TBUT which is in concordance with reports by Altan et al., [21]. No relationship was observed in between the Schirmer's and tear meniscus variables on OCT in this study which may be due to the use of topical anaesthetic during the test which is in agreement with the observations by Wang et al., [22].

A positive correlation between Schirmer's and TMH on slit lamp was observed in the present study which is consistent with the findings by Ibrahim et al., [23]. TMH and TMA on OCT showed significantly positive correlation in the present study which is in concordance with the observations of Fukuda et al., [24]. Despite higher values of Schirmer's, TBUT, TMH on slit in younger age group the TMH and TMA with OCT were low which shows that Schirmer's measurements and TMH on slit may produce biased results due to reflex tearing and TBUT is more of qualitative test not quantitative test.

TBUT and tear meniscus variables on OCT showed no significant correlation in the present study which shows agreement with the findings of Savini et al., as they observed that neither TMH nor tear meniscus depth was correlated significantly with TBUT [10]. Wang and Ibrahim et al., reported a positive correlation between TBUT and lower TMH [22,23]. The contradictory relationship between TBUT and tear meniscus results could be explained by the fact that TBUT reflects stability of the tear film not the quantity of tear fluid and fluorescein use may alter the condition of the tear film. In contrast, OCT can visualize the tear meniscus in its natural real time state. Slit lamp based TMH and the OCT based TMH were compared for first time showed no significant correlation.

## LIMITATIONS

Processing of images could be biased depending on operator's judgement for detecting the junctions which can be reduced by introduction of automated image processing software in OCT. The inter-observer and intra-observer repeatability of TMH measurement by OCT can be further assessed in future. Various factors like ocular surface, corneal curvature, lower lid length affecting the TMH could not be ruled out in this study.

## CONCLUSION

Tear meniscus variables along with other measurements can diagnose or treat dry eye. No single test can evaluate the complex tear system. Despite higher values of Schirmer's, TBUT, TMH on slit in younger age group the OCT based TMH and TMA were lower. TMH and TMA on OCT give reliable results. TMH measurement on slit lamp and on OCT could not be correlated. OCT can measure the tear meniscus quantitatively in non-biased, non-invasive and

non-contact methods. Tear meniscus evaluation using OCT may overcome the drawbacks of this traditional test to quantify tear film.

## ACKNOWLEDGEMENTS

We acknowledge Mr. Hem Chander Sati for his help in statistical analysis and Mr. Surendra Singh Bhandari for photographic documentation and his technical support.

## REFERENCES

- [1] Nelson JD. A clinician looks at the tear film. *Adv Exp Med Biol.* 1998;438:1-9.
- [2] Tsubota K, Nakamori K. Effects of ocular surface area and blink rate on tear dynamics. *Arch Ophthalmol.* 1995;113:155-58.
- [3] Holly FJ. Physical chemistry of the normal and disordered tear film. *Trans Ophthalmol Soc UK.* 1985;374-80.
- [4] Doughty MJ, Laiquazzaman M, Button E. Video-assessment of tear meniscus height in elderly Caucasians and its relationship to the exposed ocular surface. *Curr Eye Res.* 2001;22:420-26.
- [5] Goto E, Tseng SC. Kinetic analysis of tear interference images in aqueous tear deficiency dry eye before and after punctal occlusion. *Invest Ophthalmol Vis Sci.* 2003;44:1897-905.
- [6] Wang J, Aquavella J, Palakuru J, Chung S. Repeated measurements of dynamic tear distribution on the ocular surface after instillation of artificial tears. *Invest Ophthalmol Vis Sci.* 2006;47:3325-29.
- [7] Shen M, Wang J, Tao A, et al. Diurnal variation of upper and lower tear menisci. *Am J Ophthalmol.* 2008;145:801-06.
- [8] Cui L, Shen M, Wang J, et al. Age related changes in tear menisci imaged by optical coherence tomography. *Optom Vis Sci.* 2011;88(10):1214-19.
- [9] Mathers WD, Lane JA, Zimmerman MB. Tear film changes associated with normal aging. *Cornea.* 1996;15:229-34.
- [10] Savini G, Barboni P, Zanini M. Tear meniscus evaluation by optical coherence tomography. *Ophthalmic Surg Las Imaging.* 2006;37:112-18.
- [11] Izatt JA, Yasuno Y, et al. Future direction of anterior segment optical coherence tomography. In: Steinert RF, Huang D, editors. *Anterior segment optical coherence tomography.* SLACK Inc.; Thorofare, NJ: 2008. pp. 165-73
- [12] Cho P, Yap M. Age, gender, and tear break-up time. *Optom Vis Sci.* 1993;70:828-31.
- [13] Zhou S, Li Y, Lu ATZ, et al. Reproducibility of tear meniscus measurement by Fourier-domain optical coherence tomography: a pilot study. *Ophthalmic Surg Las Imaging.* 2009;40:442-47.
- [14] Keech A, Flanagan J, Simpson T, Jones L. Tear meniscus height determination using the OCT2 and the RTVue-100. *Optom Vis Sci.* 2009;86:1154-59.
- [15] Khurana AK, Chaudhary R, Ahluwalia BK, Gupta S. Tear film profile in dry eye. *Acta Ophthalmol (Copenh).* 1991;69:79-86.
- [16] Kawai M, Yamada M, Kawashima M, et al. Quantitative evaluation of tear meniscus height from fluorescein photographs. *Cornea.* 2007;26:403-06.
- [17] McCulley JP, Aronowicz JD, Uchiyama E, et al. Correlations in a change in aqueous tear evaporation with a change in relative humidity and the impact. *Am J Ophthalmol.* 2006;141:758-60.
- [18] Doughty MJ, Laiquazzaman M, Oblak E, Button N. The tear (lacrima) meniscus height in human eyes: a useful clinical measure or an unusable variable sign? *Cont Lens Anterior Eye.* 2002;25:57-65.
- [19] Doane MG. Blinking and the mechanics of the lacrimal drainage system. *Ophthalmology.* 1981;88:844-51.
- [20] Patel S, Wallace I. Tear meniscus height, lower punctum lacrimale, and the tear lipid layer in normal aging. *Optom Vis Sci.* 2006;83:731-39.
- [21] Altan-Yaycioglu R, Sizmaz S, Canan H, Coban-Karatas M. Optical coherence tomography for measuring the tear film meniscus: Correlation with schirmer test and tear-film breakup time. *Curr Eye Res.* 2013;38(7):736-42.
- [22] Wang J, Palakuru JR, Aquavella JV. Correlations among upper and lower tear menisci, non-invasive tear break-up time and Schirmer's test. *Am J Ophthalmol.* 2008;145(5):795-800.
- [23] Ibrahim OMA, Dogru M, Takano Y, et al. Application of Visante optical coherence tomography tear meniscus height measurement in the diagnosis of dry disease. *Ophthalmology.* 2010;117:1923-29.
- [24] Fukuda R, Usui T, Miyai T, et al. Tear Meniscus Evaluation by Anterior Segment Swept-Source Optical Coherence Tomography. *Am J Ophthalmol.* 2013;155(4):620-24.

### PARTICULARS OF CONTRIBUTORS:

1. Assistant Professor, Department of Ophthalmology, HIMS, Swami Rama Himalayan University, Swami Ram Nagar, Jolly Grant, Dehradun, Uttarakhand, India.
2. Professor, Department of Ophthalmology, HIMS, Swami Rama Himalayan University, Swami Ram Nagar, Jolly Grant, Dehradun, Uttarakhand, India.
3. Professor, Department of Ophthalmology, HIMS, Swami Rama Himalayan University, Swami Ram Nagar, Jolly Grant, Dehradun, Uttarakhand, India.

### NAME, ADDRESS, E-MAIL ID OF THE CORRESPONDING AUTHOR:

Dr. Anuradha Raj,  
Assistant Professor, Department of Ophthalmology, HIMS, Swami Rama Himalayan University, Swami Ram Nagar,  
Jolly Grant, Dehradun, Uttarakhand-248140, India.  
E-mail: anuradharaj@srhu.edu.in, dranuradha\_sagar@yahoo.com

FINANCIAL OR OTHER COMPETING INTERESTS: None.

Date of Submission: **Jan 05, 2016**

Date of Peer Review: **Feb 19, 2016**

Date of Acceptance: **Mar 01, 2016**

Date of Publishing: **May 01, 2016**