

Outcome Analysis of Hemiarthroplasty vs. Total Hip Replacement in Displaced Femoral Neck Fractures in the Elderly

VIPIN SHARMA¹, BHANU AWASTHI², KRISHNA KUMAR³, NAVNEET KOHLI⁴, PUNIT KATOCH⁵

ABSTRACT

Introduction: Management of displaced fracture neck femur in the elderly population is frequently done by Hemiarthroplasty or Total Hip Replacement (THR). It avoids high rates of nonunion and avascular necrosis which usually occur after internal fixation of neck femur fractures in this age group.

Aim: The present study aimed to evaluate patient function and complications following hemiarthroplasty and total hip replacement in elderly population with displaced femoral neck fractures.

Materials and Methods: Patients above 60 years of age with displaced fracture neck femur were studied over the period of four years. All the clinical parameters and co-morbid conditions were noted at the time of presentation. The patients associated with co-morbid conditions and underlying pathology were excluded from study. Garden's classification was used for classification of neck femur fractures. After due informed consent patients of displaced fracture neck femur were randomized by simple randomization and allocated for hemiarthroplasty or THR. Antibiotics were given preoperatively at the time of induction and postoperatively for 5-7 days. Surgery was carried

out by Modified Gibson approach. Any complications during pre and postoperative period were noted. Follow-up of patients was done 1 month, 3 months, 6 months and 1 year interval with the help of Harris hip score.

Results: Total 80 patients were enrolled in the study group, with 40 patients in each group. The mean age of patients was 73 years in hemiarthroplasty group and 78 years in THR group. Female to male ratio was 55:45. Mean operative time was 35 minutes in hemiarthroplasty group and 45 minutes in THR. Average intraoperative blood loss was 200cc and 300cc in hemiarthroplasty and THR respectively. The mean hospital stay was 14 days in both the groups. Superficial wound infection was noted in hemiarthroplasty group while in THR group deep wound infection (n=1) and prolonged ICU stay (n=1) were noted. The mean Harris hip score was better in THR group as compared to Hemiarthroplasty group at one year follow-up.

Conclusion: In elderly patients with fracture neck femur hemiarthroplasty takes less operative time, less blood loss per operatively and few complications postoperatively as compared to THR. The functional outcome at one year is better with THR as compared to hemiarthroplasty.

Keywords: Fracture neck femur, Garden's classification

INTRODUCTION

Femoral neck fractures are a major cause of morbidity and mortality in elderly age group and require immediate and appropriate management [1]. Factors like life style, bone quality and potential complications like non-union, AVN dictate the type of treatment in a particular age group. Hence, while in younger population Closed Reduction and Internal Fixation (CRIF) is the method of choice, arthroplasty (hemiarthroplasty or total hip replacement (THR)) is a preferred treatment modality in elderly population (>60 years) [2]. In the elderly with displaced fracture neck femur, choice between hemiarthroplasty and THR has always been a difficult one, both the treatment modalities having their own proponents. The study was on the prospective analysis of a series of 80 cases of displaced femoral neck fractures in elderly population (age >60 years) who were managed either by hemiarthroplasty or THR and evaluated in terms of functional outcome and complications.

AIM

This study aimed to evaluate patient function and complications following hemiarthroplasty and total hip replacement in elderly population with displaced femoral neck fractures.

MATERIALS AND METHODS

A prospective hospital based study was conducted over a four year period (2010-2014). Eighty patients >60 years with displaced neck femur fractures were enrolled in the study after taking informed written consent. Garden classification was used to classify the

fractures (Garden 3 and 4) [3]. Random allocation of all the patients was done in two groups for selection of operative method i.e., Group 1 for hemiarthroplasty and Group 2 for THR group with the help of simple randomisation technique (cards in a box) [Table/Fig-1]. Patients with associated osteoarthritis, avascular necrosis, rheumatoid arthritis, pathological fractures due to any other cause and patients with significant co-morbidities were excluded from study. All surgeries were performed by either of the two senior arthroplasty surgeons using modified Gibson approach [4]. Per operative and postoperative events were recorded in terms of time, blood loss, complications and duration of hospital stay. Postoperatively patients were allowed weight bearing as soon as their pain threshold permitted. After discharge patients were followed up clinico-radiologically. Functional outcome was studied using Harris hip score at 1 month, 3 months, 6 months and 1 year after surgery.

RESULTS

Total 80 patients of displaced fracture neck femur were randomly allocated into two groups with 40 patients in each group. The mean age of patients was 73 years (62-67 years) in Group 1 (Hemiarthroplasty Group) and 78 (65-79) in Group 2 (THR Group). A 55% of fracture neck femur occurred in females. A total of 32 patients were Garden 3 and 48 were Garden 4 fractures. On history, fall followed by trivial trauma was the mode of injury in majority of the patients (80%) [Table/Fig-1]. The average delay between injury and surgery was of three days. Mean operative

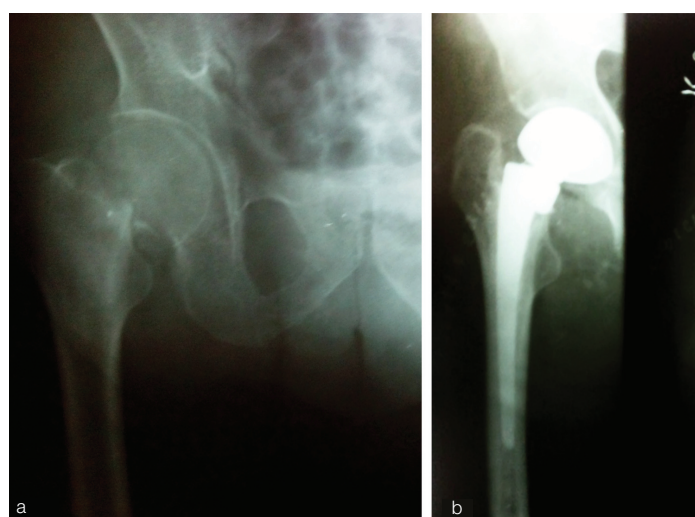
time was 35 minutes (25-35min) in Hemiarthroplasty group and 45 minutes (35-50min) in THR. Average intraoperative blood loss was 200cc and 300cc in hemiarthroplasty and THR respectively. The mean hospital stay was 14 days (12-16) in both the groups. Mean blood transfusion required in hemiarthroplasty group was 1 unit (1-3 units) while in THR group 2 units (1-4) were required pre and postoperatively. Superficial wound infection in two patients was noted in Hemiarthroplasty group while in THR group deep wound infection was noted in one patient on day 7th of surgery while another patient developed cardiac akinesia for which he was shifted to ICU postoperatively. Patient did not respond to resuscitative measures and expired one week after the surgery [Table/Fig-2,3].

Patients in both groups were made ambulatory on third post-operative day which on average was third postoperative day. Preinjury ambulatory status could be achieved at 8 weeks in both the groups. No instance of hip dislocation was noted in either the group though abductor laxity was noted in one patient in THR group.

One patient from Group 1 was lost to follow up at 3 months while in Group 2 one patient died of cardiac akinesia on day 7th of surgery. At one year follow up 39 patients from either the group were available for evaluation. The mean Harris hip score at one year follow-up in hemiarthroplasty group was 80 (range 67-85) and in THR group was 90 (range 87-95) (Chi square test p-value <0.05).

	Group 1 (Hemiarthroplasty)	Group 2 (Total Hip Replacement)
Patients no.	40	40
Age (Mean)	73 (62-77)	78 (65-79)
M/F	11/29	14/26
Garden classification, No		
3	14	18
4	26	22
Mean time from injury to surgery (days)	3	3

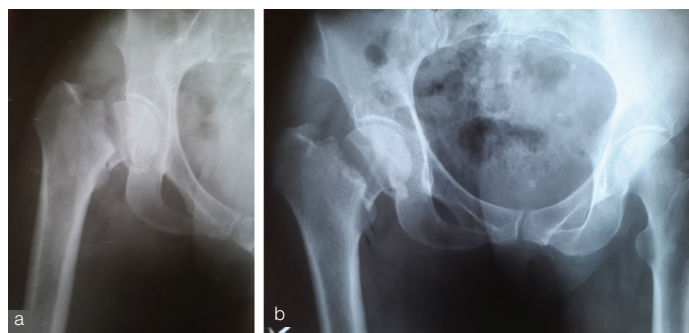
[Table/Fig-1]: Patient Demographics



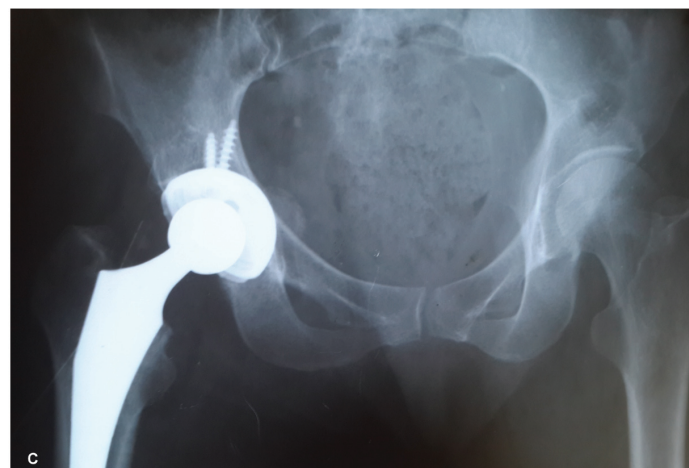
[Table/Fig-2a&b]: (a) Preop X Rays Hemiarthroplasty for fracture neck femur. (b) One year Follow-up X Ray Hemiarthroplasty.

DISCUSSION

Arthroplasty as a management option is widely supported in patients with displaced fracture neck femur in elderly but the type of arthroplasty whether hemiarthroplasty or THR is a debatable issue. Factors that need to be considered for choosing treatment modality in an elderly patient with fracture neck femur are age, medical condition and co-morbidities, life style, ambulatory and cognitive status, availability of facilities for surgery and socio-economic status [5].



[Table/Fig-3a&b]: Preop X Rays THR for fracture neck femur.



[Table/Fig-3c]: One year follow up X Ray THR.

Although hemiarthroplasty has the advantage of lesser operative time and blood loss, but complications like dislocation of poly liner and acetabular erosion may require conversion to THR [5,6]. In the present study also patients in hemiarthroplasty group were associated with lesser surgical time, less blood loss and need for lesser blood transfusions with minor complications like superficial wound infection in two patients.

Evaluation of hip function at follow-up in patients with bipolar hemiarthroplasty is another point that needs due consideration. Mean Harris Hip score in hemiarthroplasty group was lower as compared to THR group in our study. Acetabular erosion following hemiarthroplasty could be a possible reason for relatively poor hip function in hemiarthroplasty patients.

On the other hand, THR in elderly age group with fracture neck femur also has many proponents as it provides better function and better ambulation as compared to patients treated by hemiarthroplasty. It is a useful option in elderly with intact cognitive function, community ambulators and an active life style [7]. This was reflected in present study also as group of patients treated by THR had better functional outcome which was reflected in better Harris hip score than the hemiarthroplasty group. On the other hand, those patients who are greater than 80 years of age, who live in a nursing home, who require ambulatory assistance and are mentally subnormal are the ones best treated with hemiarthroplasty. Other studies on management of displaced neck fractures in elderly also support the fact of better functional outcome with THR [7,8]. Many other randomized controlled trials also support this fact [9,10].

Management with THR incurs greater cost, has reported greater operation time and greater blood loss as mentioned in literature and also corroborated in our study. Other complications like postoperative posterior dislocation with a mean rate of dislocation upto 6.9% have been reported [11] which could well be due to almost normal surrounding tissues leading to tissue laxity.

Although THR may initially look less cost effective as compared to unipolar or bipolar hemiarthroplasty, but overall costs, including those for revision surgery are lower [2].

In our series in patients managed with THR no dislocation was noted. Placing acetabular component in about 20-25 degree anteversion, meticulous repair of capsule and short external rotators, choosing a large head size (28 & 32mm) circumvented this problem. We had one death in early postoperative period due to cardiac akinesia which was unrelated to surgery.

Studies have suggested that patients between 70-80years, who live in their own home, are community ambulators, do not require any walking aids and are mentally alert represent the ideal candidates for THR. Patients more than 80 years who live in a nursing home, require ambulatory assistance and are cognitively impaired are best treated with hemiarthroplasty. Further, randomized controlled trials are required to validate this hypothesis [5,7]. There is evidence of better results with THR in the subpopulation of fit patients with little co-morbidity [12].

LIMITATIONS

Although study was conducted as a randomised trial, blinding of surgeon and patients to the modality of treatment could have strengthened the study.

CONCLUSION

This randomized study suggests that in elderly patients with fracture neck femur THR provides a better functional outcome than hemiarthroplasty with complications almost comparable to Hemiarthroplasty.

REFERENCES

- [1] Moon A, Gray A, Deehan D. Neck of Femur Fractures in Patient's Aged More Than 85 Years—are They a Unique Subset? *Geriatric Orthopaedic Surgery & Rehabilitation*. 2011;12 (4):123-27.

- [2] Ossendorf C, Scheyerer MJ, Wanner GA, Simmen HP, Werner CML. Werner. Treatment of femoral neck fractures in elderly patients over 60 years of age - which is the ideal modality of primary joint replacement? *Patient Saf Surg*. 2010;20;4(1):16.
- [3] Mears SC. Classification and surgical approaches to hip fractures for nonsurgeons. *Clin. Geriatr Med*. 2014;30(2):229-41.
- [4] Gibson A. Posterior exposure of the hip joint. *J Bone Joint Surg Br*. 1950;32: 183-86.
- [5] Marya SKS, Thukral R, Singh C. Prosthetic replacement in femoral neck fracture in the elderly: Results and review of the literature. *Indian J Orthop*. 2008;42(1):61-67.
- [6] Keating JF, Grant A, Masson M, Scott NW, Forbes JF. Displaced intracapsular hip fractures in fit, older people: a randomised comparison of reduction and fixation, bipolar hemi arthroplasty and total hip arthroplasty. *Health Technol Assess*. 2005;9:1-65.48.
- [7] Rogmark C, Carlsson Å, Johnell O, Sernbo I. A prospective randomized trial of internal fixation versus arthroplasty for displaced fractures of the neck of the femur: Functional outcome for 450 patients at two years. *J Bone Joint Surg Br*. 2002;84:183-88.
- [8] Parker MJ, Khan RJ, Crawford J, Pryor GA. Hemiarthroplasty versus internal fixation for displaced intracapsular hip fractures in the elderly : A randomized trial of 455 patients. *J Bone Joint Surg Br*. 2002;84:1150-55.
- [9] Tidemark J, Ponzer S, Svensson O, Soderqvist A, Tornkvist H. Internal fixation compared with total hip replacement for displaced femoral neck fractures in the elderly: A randomized, controlled trial. *J Bone Joint Surg Br*. 2003;85:380-8. 17.
- [10] Blomfeldt R, Tornkvist H, Ponzer S, Soderqvist A, Tidemark J. Displaced femoral neck fracture: comparison of primary total hip replacement with secondary replacement after failed internal fixation: a 2-year follow-up of 84 patients. *Acta Orthop*. 2006;77:638-43.
- [11] Parker MJ. The management of intracapsular fractures of the proximal femur. *JBJs [Br]*. 2000;82:937-41.
- [12] Rogmark C, Johnell O. Primary arthroplasty is better than internal fixation of displaced femoral neck fractures : a meta-analysis of 14 randomized studies with 2,289 patients. *Acta Orthop*. 2006;77:359-67.

PARTICULARS OF CONTRIBUTORS:

1. Associate Professor, Department of Orthopaedics, Dr. Rajendra Prasad Government Medical College, Himachal Pradesh, India.
2. Professor and Head, Department of Orthopaedics, Dr. Rajendra Prasad Government Medical College, Himachal Pradesh, India.
3. Student, Department of Orthopaedics, Dr. Rajendra Prasad Government Medical College, Himachal Pradesh, India.
4. Student, Department of Orthopaedics, Dr. Rajendra Prasad Government Medical College, Himachal Pradesh, India.
5. Student, Department of Orthopaedics, Dr. Rajendra Prasad Government Medical College, Himachal Pradesh, India.

NAME, ADDRESS, E-MAIL ID OF THE CORRESPONDING AUTHOR:

Dr. Vipin Sharma,
H No. 23, Type 5, Block B, Dr RPGMC, Tanda.
E-mail: vipinsh_hp@rediffmail.com

FINANCIAL OR OTHER COMPETING INTERESTS: None.

Date of Submission: **Dec 31, 2015**

Date of Peer Review: **Feb 01, 2016**

Date of Acceptance: **Apr 02, 2016**

Date of Publishing: **May 01, 2016**