

# Gastric giardiasis

C Doglioni, M De Boni, R Cielo, L Laurino, P Pelosio, P Braidotti, G Viale

## Abstract

**Aims:** To assess the prevalence of gastric giardiasis in patients undergoing upper gastrointestinal endoscopy, and to define the clinicopathological correlates of gastric *Giardia lamblia* infection.

**Methods:** Consecutive gastric biopsy specimens (n = 15 023) from 11 085 patients, taken at Feltre City Hospital (north eastern Italy) from January 1986 to December 1991, were histologically and immunocytochemically examined for the occurrence of *G lamblia* trophozoites. Three gastric biopsy specimens from patients harbouring *G lamblia* infection, who repeated endoscopy before treatment, were also examined electron microscopically.

**Results:** Forty one patients (0.37% of the population study) harboured gastric giardiasis. All patients underwent upper gastrointestinal endoscopy because of dyspepsia, epigastric pain, or abdominal distension. Only two patients had diarrhoea at the time of investigation. Giardiasis was clinically unsuspected in all cases, although the nine patients who also had duodenal biopsies performed had concomitant intestinal giardiasis. Gastric giardiasis was invariably associated with chronic atrophic gastritis. Intestinal metaplasia of the gastric mucosa and *Helicobacter pylori* infection were found in 32 and 37 of the 41 patients with gastric giardiasis, respectively.

**Conclusions:** The invariable association of gastric giardiasis with chronic atrophic gastritis, most often showing intestinal metaplasia and *H pylori* infection, indicates that a decreased gastric acidity is a prerequisite for localisation of *G lamblia* to the gastric mucosa. Though its possible role as a gastric pathogen remains to be elucidated, these findings suggest that trophozoites should be carefully searched for when examining gastric biopsy specimens showing chronic atrophic gastritis.

(J Clin Pathol 1992;45:964-967)

*Giardia lamblia* was the first intestinal protozoa to be observed and described by Leeuwenhoek in 1681, although it derives its name from Vilem Lambl, a Czech physician who identified it in faeces in 1859, and was formally considered its discoverer.

The pathogenicity of *G lamblia* has been controversial for a long time, but it is now

accepted that it causes disease in man.<sup>1</sup> Infection is usually followed by an acute diarrhoeal illness, after an incubation period of 12 to 19 days; chronic giardiasis can also be accompanied by ill defined gastrointestinal symptoms.<sup>2</sup> Diagnosis of infection relies on the identification of trophozoites in duodenal aspirates or cysts in stool. Immunological and genotypic assays have been introduced in clinical practice over the past few years.<sup>3,4</sup> Histological examination of duodenal and jejunal biopsy specimens from patients with a clinical history of malabsorption permits direct visualisation of the trophozoites.

In infected patients *G lamblia* characteristically localises in the proximal small intestine, but localisation in extraintestinal sites, including gall bladder,<sup>5</sup> has also been reported. However, no mention is made that the organism could possibly be identified in gastric biopsy specimens.

Following the first observation of *G lamblia* trophozoites in a gastric biopsy specimen, we undertook a prospective and retrospective analysis for the presence of the organism in routine gastric biopsy specimens taken at the endoscopic unit, Feltre City Hospital.

## Methods

The first patient harbouring *G lamblia* trophozoites in the gastric mucosa was observed in December 1988. All subsequent gastric biopsy specimens were routinely evaluated for the presence of this parasite, and a retrospective analysis was performed on all gastric biopsy specimens dating back to 1986. Thus a total of 15 023 specimens taken from 1986 to 1991 from 11 095 patients were included in the current investigation.

When *G lamblia* was morphologically identified, additional sections were cut from paraffin wax blocks and immunostained with a 1 in 10 000 dilution of anti-*Giardia* polyclonal antiserum (Chemicon, Temecula, California, USA) and a standard avidin-biotin complex-peroxidase technique (reagents from Dako, Glostrup, Denmark), as previously reported.<sup>6</sup> All cases were also morphologically investigated for *Helicobacter pylori* infection. Histopathological changes in the gastric mucosa were recorded according to the Sydney system.<sup>7</sup>

Nine patients found to harbour gastric *G lamblia* on initial examination, had a repeat endoscopy before treatment; at that time both gastric and duodenal biopsy specimens were taken from each patient. In three of these cases

Department of  
Surgical Pathology,  
Ospedale Civile, Feltre  
C Doglioni  
L Laurino  
P Pelosio

Endoscopy Unit  
M De Boni  
R Cielo

Second Department of  
Pathology, University  
of Milan School of  
Medicine, Milan, Italy  
P Braidotti  
G Viale

Correspondence to:  
Dr C Doglioni, Department  
of Pathology, Ospedale  
Civile, 32032 Feltre (BL),  
Italy

Accepted for publication  
6 May 1992

part of the gastric samples were fixed in 2.5% glutaraldehyde in Millonig's phosphate buffer for four hours and processed for electron microscopic examination. Seven patients had a third control endoscopy one to two months after treatment.

Symptoms leading to endoscopy, other pertinent clinical data, and the effects of treatment (metronidazole 250 mg three times a day for 10 days often associated with antacid drugs) in 24 patients who had been treated (patients seen after December 1988) were retrieved from the clinical records of each patient.

Twenty seven small bowel biopsy specimens, taken from patients investigated for malabsorption during the same period were also reviewed: 10 of these patients also had antral and fundic gastric biopsy specimens taken at the same time.

Finally, to evaluate the prevalence of *G lamblia* in the population, we analysed duodenal biopsy specimens and cytological brushings of a consecutive series of 110 patients undergoing routine upper gastrointestinal tract endoscopic examination.

## Results

### IDENTIFICATION AND LOCALISATION OF TROPHOZOITES

Forty one (0.37%) of the 11 085 patients under study harboured gastric *G lamblia* infection. The trophozoites were identified at light microscopy as pear-shaped structures with two small paired nuclei, or as concave disks with thick outline (fig 1); thin flagella were occasionally seen. In all cases the immunocytochemical investigation provided confirmatory evidence for the identity of the trophozoites, which were strongly immunoreactive to the anti-*Giardia* antiserum (fig 2).

In the three cases submitted for electron microscopic examination the trophozoites,

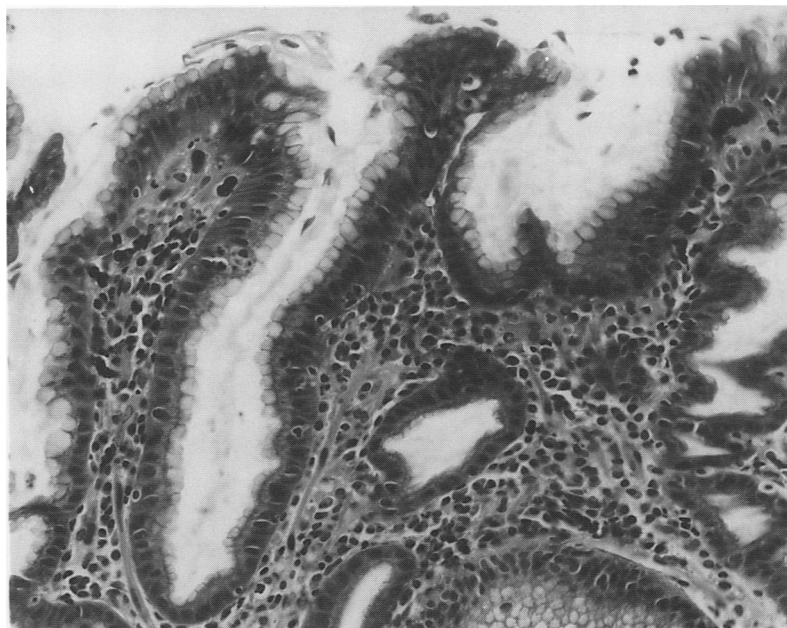


Figure 1 Light microscopic appearance of *G lamblia* trophozoites overlying the superficial and foveolar epithelium of the gastric mucosa.

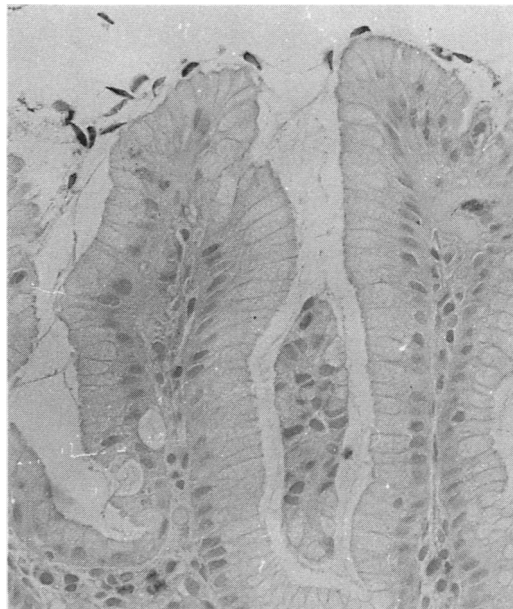


Figure 2 Trophozoites are immunoreactive to the anti-*Giardia* polyclonal antiserum.

measuring 12–15  $\mu\text{m}$  in maximum diameter, showed the typical ultrastructural features of *G lamblia*,<sup>8,9</sup> with a pair of ventral sucking disks and axostyles crossed by two parabasal bodies (fig 3). Four blepharoplasts and eight flagella were clearly evident in step sections of the same parasite.

Trophozoites were localised at the surface and at the base of foveolar pits, overlying the superficial and foveolar epithelium, and also in the intestinal metaplastic epithelium. Their number varied, ranging from five to more than 100 in each biopsy specimen. In specimens taken from gastric stumps, and including jejunal mucosa, *G lamblia* was localised on both gastric and intestinal epithelia. *G lamblia* was never observed over fundic-type gastric mucosa.

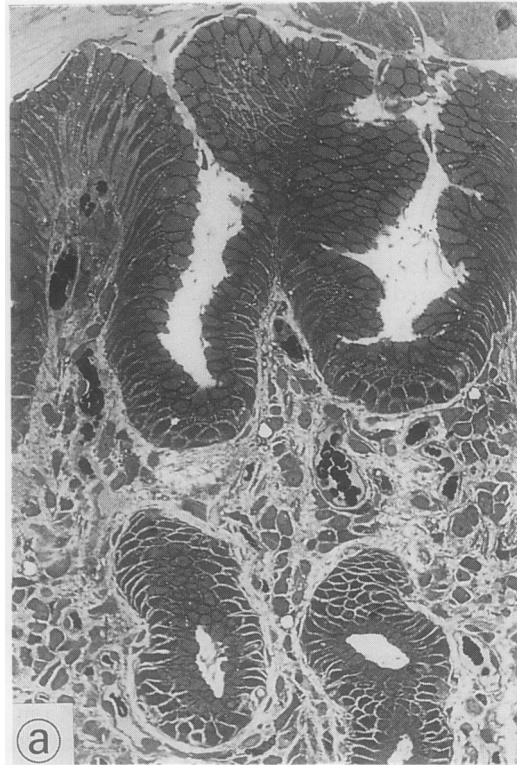
### CLINICOPATHOLOGICAL DATA

Dyspepsia, epigastric pain, and abdominal distension were the symptoms leading to endoscopic examination of the upper gastrointestinal tract in the 41 patients with gastric giardiasis. Only two patients had diarrhoea at the time of endoscopy. Four patients had recently travelled abroad (Mexico, Turkey, former Yugoslavia, Greece). None had detectable human immunodeficiency virus (HIV) serum antibodies; serological data available for 13 patients did not indicate any abnormality in serum immunoglobulins.

Cases of gastric giardiasis were diagnosed sporadically all year long, without any apparent seasonal exacerbation of the infection. Furthermore, there did not seem to be any clustering of the affected patients within specific regional areas.

The most relevant clinicopathological data of the 41 patients with gastric giardiasis are summarised in the table. All patients showed moderate to severe chronic atrophic gastritis with mild to severe activity, often associated with focal to extensive intestinal metaplasia. Concomitant *H pylori* infection was identified

Figure 3A Semithin section of a plastic embedded gastric biopsy specimen showing *G lamblia* colonisation of the gastric mucosa.



in 37 patients. Other associated gastric diseases included peptic ulcer (n = 2) and intestinal-type adenocarcinoma (n = 2). Eleven patients had previous partial gastrectomy (Billroth II) for peptic ulcer (n = 9) or gastric adenocarcinoma (n = 2). Five patients with previous histologically confirmed gastric peptic ulcer, not associated with *G lamblia* infection showed gastric giardiasis in biopsy specimens taken 40

Relevant clinicopathological data of 41 patients with gastric giardiasis

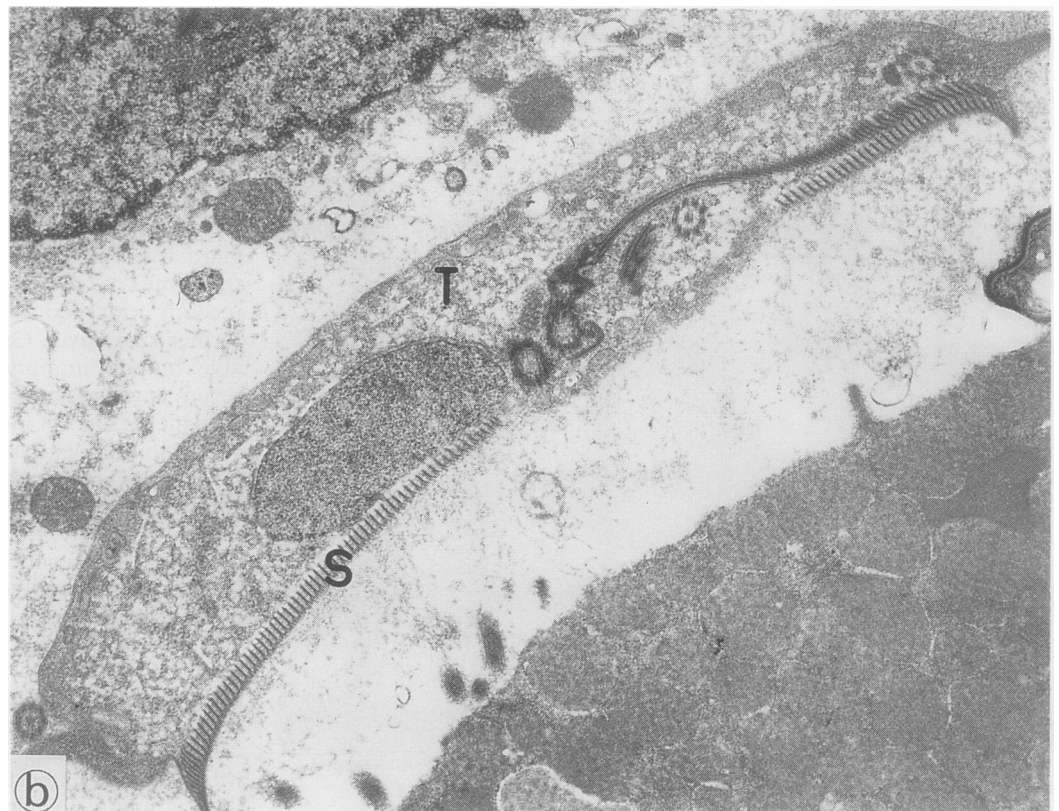
Age range	30-93 (mean 60 years)
Male/female	27/14
Chronic atrophic gastritis	41/41
Intestinal metaplasia	32/41
<i>Helicobacter pylori</i> infection	37/41
Gastric ulcer	2/41
Gastric adenocarcinoma	2/41
Previous partial gastrectomy	11/41
Previous antacid treatment	5/41
Concomitant intestinal giardiasis	9/9
Chronic infection (3-6 years' duration)	8/8

days later, after treatment with omeprazole (n = 2), ranitidine (n = 2), and nizatidine (n = 1). Trophozoites were identified both on the gastric and on the duodenal mucosa of the nine patients who repeated endoscopy and who also had gastric and duodenal biopsies performed before treatment. *G lamblia* infection had been eradicated in the seven patients who repeated endoscopy after treatment. *H pylori* infection persisted. Treatment resulted in at least partial relief of symptoms in all 24 treated patients. Four patients with gastric giardiasis had concomitant colorectal (n = 2), pancreatic, and laryngeal carcinoma.

Previous gastric biopsy specimens from eight patients with newly diagnosed gastric giardiasis were available for review. In all these cases *G lamblia* infection was already present (albeit originally unrecognised) in the previous specimens, dating back three to six years.

Twelve of the 27 patients evaluated for malabsorption were shown to harbour *G lamblia* infection of the duodenal and jejunal mucosa; five of them also had concomitant gastric biopsy specimens showing histolog-

Figure 3B Ultrathin section of the same tissue sample as in figure 3a. *G lamblia* trophozoite (T) with ventral sucking disk(s).



ically normal mucosa ( $n = 2$ ) or *H pylori* associated chronic gastritis with mild atrophy ( $n = 3$ ). Gastric giardiasis was absent in these patients.

Finally, only one of the 110 consecutive patients undergoing upper gastrointestinal tract endoscopy showed evidence of *G lamblia* infection in the duodenal mucosa.

### Discussion

To the best of our knowledge, this is the first report on the localisation of *G lamblia* trophozoites to the gastric mucosa. The parasites have previously been identified in gastric lavage fluids,<sup>10</sup> but contamination with duodenal juice of these specimens cannot be precluded. The current study is based on a population of almost 80 000 inhabitants living in a restricted area of north eastern Italy, with a low prevalence of giardiasis (less than 1% of the patients undergoing upper gastrointestinal tract endoscopy, as documented in the present series). Therefore, although our results do not come from a multicentre investigation, the reported prevalence of *G lamblia* trophozoites in 0.37% of gastric biopsy specimens may well be considered applicable to other areas with medium to high socioeconomic standards.

The small bowel mucosa is the expected area of colonisation of *G lamblia* in infected patients; in this alkaline environment the organism can complete its life cycle and exert its pathogenic effects.<sup>11</sup> A significantly decreased gastric acidity and modifications of the normal microenvironmental conditions of the gastric mucosa (becoming like those of the small bowel) may be essential prerequisites for *G lamblia* colonisation of the stomach. Indeed, we were unable to find any gastric infection in patients with duodenal giardiasis and normal or slightly modified gastric mucosa. Conversely, we identified *G lamblia* trophozoites only in the gastric biopsy specimens of patients with chronic atrophic gastritis, most often associated with *H pylori* infection and showing intestinal metaplasia, and in gastric stumps. Both these conditions are known to reduce significantly or completely abolish gastric acidity. Furthermore, five patients showed gastric colonisation only after treatment with antacid secreting drugs for peptic ulcer.

Gastric giardiasis may be chronic: eight patients in our series had previous gastric biopsy specimens (dating back three to six years) which already harboured *G lamblia* infection. At that time, however, we were unaware of the possible occurrence of gastric giardiasis and the presence of the trophozoites was therefore overlooked.

The pathogenic effects of *G lamblia* on gastric mucosa are difficult to evaluate, especially because the histopathological changes we observed were probably attributable to concomitant *H pylori* infection. Specific morphological changes due to *G lamblia* colonisation, however, have not been identified even in the small bowel mucosa.<sup>12</sup> Furthermore, *G lamblia* infection was clinically unsuspected in all the 41 patients with gastric giardiasis. They

mostly complained of dyspepsia, epigastric pain, or abdominal distension, although a recent study refuted *G lamblia* as a cause of non-ulcer dyspepsia. In any case the above symptoms are not specific and may well be due to the underlying chronic atrophic gastritis and to *H pylori* infection.<sup>13</sup>

Treatment with metronidazole and antacid drugs resulted in at least partial relief of the symptoms, but it was impossible to evaluate separately the effects of these medications. Metronidazole in the doses used, however, was ineffective at eradicating *H pylori* infection.

Although the possible role of *G lamblia* as a gastric pathogen remains to be clarified, we believe that a careful search for trophozoites should become part of the routine histopathological examination of gastric biopsy specimens, with particular care given to those showing chronic atrophic gastritis, and of gastric stumps. Because gastric giardiasis is invariably associated with intestinal giardiasis, the identification of *G lamblia* in gastric biopsy specimens allows the infection to be diagnosed even if clinically unsuspected (symptoms related to *G lamblia* infection are often atypical, as pointed out in recent studies,<sup>14</sup> and diverse strains of this parasite may exert different pathogenic effects<sup>15</sup>) and for appropriate treatment to be given.

The demonstration of the actual capability of *G lamblia* to colonise chronically the gastric mucosa might well stimulate further investigations aimed at better defining the interactions between man and this most common parasite.

- WHO Expert Committee. Intestinal protozoan and helminthic infections. *WHO Technical Report Series 666*. Geneva: World Health Organization, 1981.
- Chester AC, MacMurray FG, Restifo MD, Mann O. Giardiasis as a chronic disease. *Dig Dis Sci* 1985;30:215-8.
- Green EL, Miles MA, Warhurst DC. Immunodiagnostic detection of *Giardia* antigen in faeces by a rapid visual enzyme-linked immunosorbent assay. *Lancet* 1985;ii: 691-3.
- Butcher PD, Farthing MJG. DNA probes for the faecal diagnosis of *Giardia lamblia* infections in man. *Biochem Soc Trans* 1989;17:363-4.
- Goldstein F, Thornton JJ, Szydowski T. Biliary tract dysfunction in giardiasis. *Am J Dig Dis* 1978;23:559-60.
- Dogliani C, Dell'Orto P, Coggi G, Iuzzolino P, Bontempini L, Viale G. Choroid plexus tumors. An immunocytochemical study with particular reference to the coexpression of intermediate filaments. *Am J Pathol* 1987;127:519-29.
- Misiewicz JJ, Tytgat GNJ, Goodwin CS, et al. The Sydney system: a new classification of gastritis. In: *Working Party Report*. Melbourne: Blackwell Scientific Publications, 1990:1-10.
- Morecki R, Parker JG. Ultrastructural studies of the human *Giardia lamblia* and subjacent jejunal mucosa in a subject with steatorrhea. *Gastroenterology* 1967;52:151-64.
- Brookes SEH, Audretsch J, Muller CG, Sparke B. Electron microscopy of *Giardia lamblia* in human jejunal biopsies. *J Med Microbiol* 1970;3:196-9.
- Koss LG. The gastrointestinal tract. In: *Diagnostic cytology and its histopathological bases*. Philadelphia: JB Lippincott, 1979:834-5.
- Ferguson A, Gillon J, Munro G. Pathology and pathogenesis of the intestinal mucosal damage in the giardiasis. In: Meyer EA, ed. *Giardiasis*. Amsterdam: Elsevier, 1990:155-95.
- Oberhuber G, Stolte M. Giardiasis: analysis of histological changes in biopsy specimens of 80 patients. *J Clin Pathol* 1990;43:641-3.
- Carr MF, Ma J, Green PHR. *Giardia lamblia* in patients undergoing endoscopy: Lack of evidence for a role in non-ulcer dyspepsia. *Gastroenterology* 1988;95:972-4.
- Gillon J. Clinical studies in adults presenting with giardiasis to a gastro-intestinal unit. *Scot Med J* 1985;30:89-95.
- Nash TE, Herrington DA, Losonsky GA, Levine MM. Experimental human infections with *Giardia lamblia*. *J Infect Dis* 1987;156:974-84.