

# Demonstration of HIV-1 infected cells in human placenta by in situ hybridisation and immunostaining

E Backé, E Jimenez, M Unger, A Schäfer, E Jauniaux, M Vogel

## Abstract

**Aims:** To show the presence of HIV infected cells in the placentas and membranes exposed to HIV during pregnancy, and to trace the possible transmission routes from mother to fetus.

**Methods:** Twenty three therapeutic abortions and 11 term placentas were investigated for the presence of HIV antigen by immunostaining with HIV core protein specific antibodies and HIV nucleic acids by in situ hybridisation (ISH) with a <sup>35</sup>S-labelled HIV specific RNA probe.

**Results:** HIV antigen as well as HIV RNA positive cells were rarely found in placental tissue and membranes. In therapeutic abortions HIV antigen was shown in 10 out of 23 placentas, HIV RNA in two. HIV antigen was detected in five out of 11 term placentas and HIV RNA in two. Infected cell types comprised syncytiotrophoblasts, Hofbauer cells, amnionic epithelium, chorionic macrophages as well as maternal lymphocytes in the intervillous space and decidua.

**Conclusion:** These data suggest that the transmission routes are: (1) a haematogenous route from the maternal intervillous space to villous stromal cells; (2) from chorion laeve to amnionic fluid and vice versa. Two additional transmission routes are partly suggested by the data: (1) in early gestation by direct extension from basal decidua to budding trophoblastic cells; (2) from the capsular decidua to chorion laeve and chorionic plate, entering the fetal circulation via the small veins.

(J Clin Pathol 1992;45:871-874)

Most cases of paediatric HIV infection are the result of vertical transmission from mother to fetus.<sup>1</sup> The transmission rate varies from 13%–40%.<sup>2,3</sup> HIV was detected in the fetal tissues of second trimester pregnancies<sup>4-8</sup> as early as the 15th week of gestation.<sup>9</sup> This suggests early transplacental passage of the virus. Principally, the virus can cross the placenta and, or, membranes with or without infecting placental cells. Both possibilities have been discussed.<sup>10</sup> This study was undertaken to investigate the placental cell types which can be infected by HIV, thereby tracing possible transmission routes, and to determine the earliest occurrence and prevalence of placental infection.

## Methods

Eleven (10 African, one Belgian) term placentas and 23 placentas obtained after therapeutic abortions (Berlin) from mothers exposed to HIV were collected. The gestational age of the fetuses ranged from six to 40 weeks. Tissue was fixed immediately after birth or abortion in 10% phosphate buffered formalin. Routine macroscopic and microscopic examination according to the method of Kloos and Vogel<sup>11</sup> was performed on all placentas. Positive control tissue consisted of lymph node from an adult with HIV associated lymphadenopathy and human T cell lymphoma cell line H9 infected with HIV (Professor Pauli, Robert-Koch Institut, Berlin).

Negative controls comprised (a) for the African/Belgian term placentas, two placentas of HIV negative Belgian intravenous drug abusers and five of HIV negative African women; (b) for therapeutic abortions, the next placenta of an uneventful pregnancy of the same gestational age (matched pairs); and (c) an HIV negative cell line. Multiple slides of each tissue section were prepared for investigation by immunostaining and in situ hybridisation (at least three slides for each method).

Formalin fixed, paraffin wax embedded tissue was immunostained with two p24 (HIV core protein) specific monoclonal antibodies (anti-p24, M 847 Dako, Denmark; anti-p24 Du Pont, Dreeich, Germany) by the alkaline phosphatase-antialkaline phosphatase (APAAP) method, as described by Cordell *et al*,<sup>12</sup> with the following modifications: slides were incubated with normal rabbit serum prior to the primary antibody and washing was generally performed with high ionic strength TRIS-buffer (2.5% NaCl) to reduce background staining. Incubation with the primary antibody was for one hour. Slides were developed with Fast Red or Neufuchsin substrate.

In situ hybridisation was performed according to the method of Spiegel *et al*,<sup>13</sup> A <sup>35</sup>S labelled probe (NEP 200, Du Pont) with a specific activity of more than 10<sup>9</sup> decays a minute (dpm)/μl, and recognising over 2000 nucleotides, including the *env* (envelope) and *tat* (transcriptional activator transacting) genes, was used. For formalin fixed sections, about 10<sup>6</sup> dpm were applied per slide. As a specificity control the <sup>35</sup>S labelled control *env* sense probe (P4045, Dianova, Hamburg, Germany) was used. After hybridisation and extensive washing, slides were dipped in Ilford G5 solution, exposed for 10 days and developed. Each staining/hybridisation step included positive and negative controls.

Institute of Pathology,  
Department of  
Paediatric Pathology,  
Free University of  
Berlin,  
Universitätsklinikum  
Rudolf-Virchow,  
Spandauer Damm 130,  
1000 Berlin 19,  
Germany  
E Backé  
E Jimenez  
M Unger  
M Vogel

Clinic of Obstetrics  
A Schäfer

Cliniques  
Universitaire de  
Bruxelles, Hôpital  
Erasmus, Belgium  
E Jauniaux

Correspondence to:  
Professor Vogel

Accepted for publication  
20 March 1992

Table 1 Demonstration of HIV antigen and HIV RNA in placentas

	Week																			
	6	8	10	12	15	16	18	19	20	21	23	25	26	37	38	39	30			
Number of placentas	1	1	3	3	3	3	1	1	2	2	1	1	1	1	3	4	3			
HIV RNA positive	0	0	1	1	0	0	0	0	0	0	0	0	0	0	2	0	0			
HIV antigen positive	0	0	1	3	1	2	0	0	1	1	0	1	0	1	2	0	2			

### Results

Routine morphological placental examination showed no differences between the HIV exposed placentas and controls; the rate of chorioamnionitis and villitis was no different. HIV antigen as well as HIV RNA positive cells were rarely found in placental tissue and membranes. In therapeutic abortions HIV antigen was shown in 10 out of 23 placentas, HIV RNA in two out of 23 placentas (table 1). In those two cases we also detected p24 antigen positive Hofbauer cells. In term placentas we found HIV antigen in five out of 11 and HIV RNA in two out of 11 cases. HIV antigen and HIV RNA were most often found in placental macrophages (Hofbauer cells; figs 1-3). HIV RNA was also found in cells near the villous surface, corresponding to the syncytiotrophoblastic layer (fig 4). Two p24 positive birth placentas also contained HIV RNA positive cells in amnionic epithelium and chorion laeve, respectively (table 2) (figs 5 and 6). Additionally to the HIV RNA positive cells in the fetal compartment two placentas contained HIV RNA positive maternal lymphocytes in the intervillous space or a decidual lymphocyte (figs 7 and 8). HIV antigen and HIV RNA were detected as early as the 10th week of gestation.

None of the negative control specimens showed labelling with <sup>35</sup>S labelled HIV *env* specific probe, nor did the HIV positive tissue react with the <sup>35</sup>S labelled sense probe. In HIV negative placentas no unspecific APAAP staining reaction was shown on stromal cells or intravascular cells with the p24 antibodies, but in some cases weak staining occurred in trophoblast and decidual cells.

### Discussion

In our study HIV antigen as well as HIV RNA positive cells were very rarely found in placental tissue. Our findings confirm that HIV can infect placental cells and infection can occur early in pregnancy. Sites of infection included villi (Hofbauer cells, trophoblasts), amnionic epithelium, chorion laeve, as well as

intervillous space and decidua (lymphocytes).

Immunostaining detected higher numbers of positive Hofbauer cells than in situ hybridisation. This agrees with published findings which describe a greater number of p24 antigen positive cells compared with HIV RNA positive cells in the intestinal epithelium of HIV positive adult.<sup>14</sup> There may be several reasons for this. On the one hand, the discrepancy may be caused by methodological problems—loss of RNA because of its extreme lability. On the other hand, not all p24 antigens demonstrated in placental macrophages may be part of replicating virus.

There are discrepancies among authors concerning the cell types infected with HIV: placental macrophages, trophoblasts, endothelial cells, and decidual cells. Positive Hofbauer cells were found by Brady *et al.*,<sup>15</sup> by immunostaining and by Lewis *et al.*<sup>16</sup> by immunostaining and in situ hybridisation as in this study. HIV infection of macrophages can occur via CD4 or Fc-receptors.<sup>17</sup> Both receptors were found on Hofbauer cells.<sup>18,19</sup> HIV positive trophoblastic cells were found by these authors as well as Chandwani *et al.*<sup>20</sup> Syncytiotrophoblasts may be infected by several mechanisms. They are known as Fc-receptor bearing cells able to phagocytose.<sup>21</sup> Epithelial cells of rectum and thyroid were also CD4 positive.<sup>22</sup> Unlike Lewis *et al* we could not find HIV infected endothelial cells which could have an important role in the transportation of virus to the fetal circulation.

An interesting new finding in our study was the presence of HIV positive cells in the amnionic epithelium and chorion laeve. The HIV positive cell in the chorion laeve was not clearly identifiable but was probably a macrophage. Thus the most likely mechanisms of entry of the virus into the amnionic epithelium is by phagocytosis of infected amnionic fluid. Infection of amnionic fluid was described by Mundy *et al.*<sup>23</sup> This route of infection is indirectly supported by the well known fact that meconium in amnionic fluid can be phagocytosed by the amnionic epithelium and later transported to deeper layers of the membranes by macrophages. Less likely, but theoretically possible, is a transport of virus in the opposite direction, as known from infections where bacteria and granulocytes reach the amnionic fluid via decidua and fetal membranes. In this context it seems remarkable that two cases of our African collection (n = 10) had HIV infected cells in the membranes while there were none in the Berlin fetal collective. This corresponds to the finding of Kreiss *et al.*,<sup>24</sup> who showed the presence of HIV in the genital ulcers of seropositive patients, which might be one of the causes of heterosexual transmission in Africa. On the maternal side we found an HIV infected lymphocyte in the intervillous space and one in an aggregate of decidual lymphocytes. This is well in line with the presence of HIV infected cells in the endometrium, as shown by Peuchmaur *et al.*<sup>25</sup> From this site the virus may enter the invading trophoblast as postulated by Werner *et al* to cause *Toxoplasma gondii* infection during the

Table 2 Localisation of HIV infected cells in the placenta

Localisation	Abortions		Term placentas	
	HIV antigen	HIV RNA	HIV antigen	HIV RNA
Hofbauer cells	10	0	5	0
Syncytiotrophoblasts	0	1	0	0
Chorion laeve	0	0	0	1
Amnionic epithelium	0	0	0	1
Decidua	0	1	0	0
Intervillous space	0	1	0	0

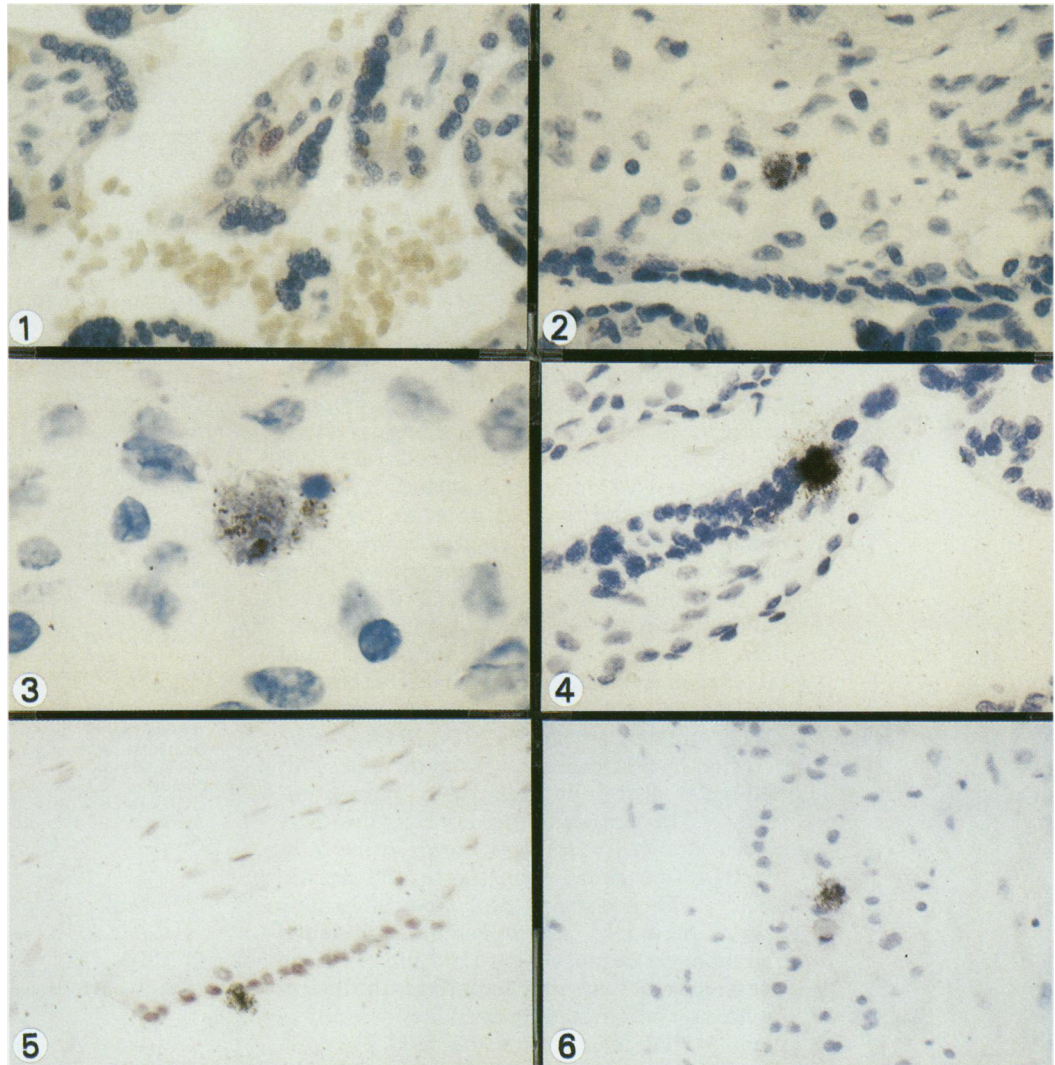


Figure 1 p24 antigen positive placental macrophage (Hofbauer cell) in a term placenta (APAAP).  
 Figures 2 and 3 HIV infected macrophage in a placenta of the 23rd week of gestation; in the adjacent cell a weak positive signal (ISH).  
 Figure 4 HIV infected cell near the villous surface in a placenta of the 10th week of gestation (ISH).  
 Figure 5 HIV infected cell in the amnionic epithelium of a term placenta (ISH).  
 Figure 6 HIV infected cell in the chorion laeve next to probably a phagocytic cell with single grains (ISH).

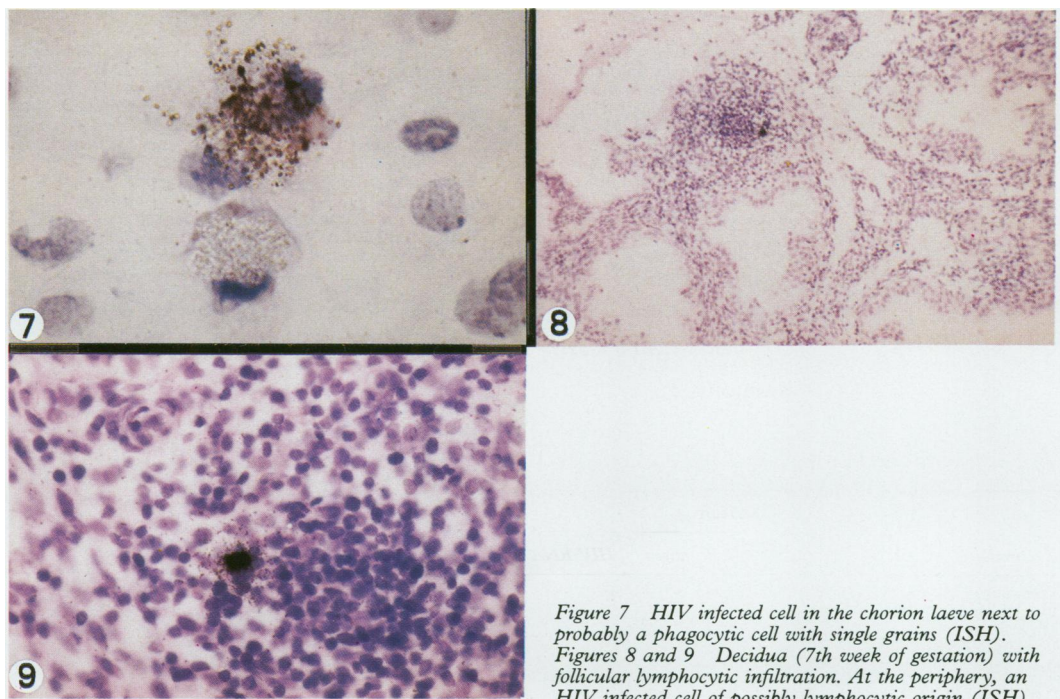


Figure 7 HIV infected cell in the chorion laeve next to probably a phagocytic cell with single grains (ISH).  
 Figures 8 and 9 Decidua (7th week of gestation) with follicular lymphocytic infiltration. At the periphery, an HIV infected cell of possibly lymphocytic origin (ISH).



first trimester.<sup>26</sup> Unlike Lewis *et al*, we did not find HIV infected cells in the fetal circulation. Our findings, however, agree with published findings as the prevalence of HIV infected peripheral blood lymphocytes is 1:1000 to 1:10000.<sup>27</sup> In contrast to all the other studies mentioned above, Peuchmaur *et al* could neither demonstrate HIV antigens in 30 term placentas and 45 induced abortions nor HIV RNA in the three cases he investigated by *in situ* hybridisation.<sup>28</sup>

As well as implicating the transplacental passage of HIV during a viraemic episode<sup>29</sup> without infecting placental cells our study also suggests two transmission routes: (1) the haematogenous route from the maternal intervillous space to villous stromal cells; (2) from chorion laeve to amniotic fluid and vice versa. Furthermore, our findings point to two additional transmission routes which are partly supported by our data: first, in early gestation, by direct extension from basal decidua to budding trophoblastic cells, and secondly, from the capsular decidua to chorion laeve and the chorionic plate, entering the fetal circulation via the small veins.

HIV antigen as well as HIV RNA can be detected in first trimester placental cells. This finding is also supported by *in vitro* studies.<sup>18 30 31</sup> In contrast to the very early positivity of placental cells, HIV was shown in the fetus by (PCR) no earlier than the second trimester.<sup>4 6 8 9</sup> This may be explained by a long latency period of HIV infection in placental macrophages because silent HIV infections can last for several years in macrophages until virus replication is activated by cytokines or coinfections.<sup>32</sup> HIV infection of the fetal placenta, therefore, does not necessarily result in infection of the fetus itself.

- 1 The European Collaborative Study. Children born to women with HIV-1 infection: natural history and risk of transmission. *Lancet* 1991;337:253-60.
- 2 Blanche S, Rouzioux C, Moscato M-LG, *et al*. A prospective study of infants born to women seropositive for human immunodeficiency virus type 1. *N Engl J Med* 1989;320:1643-8.
- 3 Ryder RW, Nsa W, Hassig SE, *et al*. Perinatal transmission of the human immunodeficiency virus type 1 to infants of seropositive woman in Zaire. *N Engl J Med* 1989;320:1637-42.
- 4 Jovaisas E, Koch MA, Schäfer A, Stauber M, Lowenthal D. LAV/HTLVIII in 20-week fetus. *Lancet* 1985;ii:1129.
- 5 Lyman W, Kress Y, Kure K, Rashbaum WK, Rubinstein A, Soeiro R. Detection of HIV in fetal nervous system tissue. *AIDS* 1990;4:917-20.
- 6 Siegel G, Schäfer A, Unger M, *et al*. HIV-1 in fetal organs and in embryonic placenta of HIV-1 positive mothers. 6th International Conference on AIDS. San Francisco, California June 1990. San Francisco: University of California, 189.
- 7 Mano H, Chermann JC. Fetal human immunodeficiency virus type 1 infection of different organs in the second trimester. *AIDS Res Hum Retroviruses* 1991;7:83-8.
- 8 Cournaud V, Laure F, Brossard A, *et al*. Frequent and early *in utero* HIV-1 infection. *AIDS Res Hum Retroviruses* 1991;7:337-41.
- 9 Sprecher S, Soumenkoff G, Puissant F, Degueudre M. Vertical transmission of HIV in 15-week fetus. *Lancet* 1985;ii:288-9.
- 10 Valente P, Main EK. Role of the placenta in prenatal transmission of HIV. *Obstet Gynecol Clin North Am* 1990;17:607-16.
- 11 Kloos K, Vogel M. *Pathologie der perinatalperiode*. Berlin: Georg Thieme Verlag, 1975.
- 12 Cordell J, Falini B, Erber ON, *et al*. Immunoenzymatic labelling of monoclonal antibodies using immune complexes of alkaline phosphatase and monoclonal anti-alkaline phosphatase (APAAP complexes). *J Histochem Cytochem* 1984;32:212-24.
- 13 Spiegel H, Herbst H, Niedobitek G, Voss HD, Stein H. CD4<sup>+</sup> follicular dendritic cells are a major reservoir for HIV-1 in lymphoid tissues facilitating infection of CD4<sup>+</sup> T-helper cells. *Am J Pathol* 1992;140:15-22.
- 14 Kotler DP, Reka S, Borcich A, Cronin WJ. Detection, localization, and quantitation of HIV associated antigens in intestinal biopsies from patients with HIV. *Am J Pathol* 1991;139:823-30.
- 15 Brady K, Martin A, Page D, Purdy S, Neimann RS. Localization of human immunodeficiency virus in placental tissue. *Lab Invest* 1989;60:69A.
- 16 Lewis SH, Reynolds-Kohler C, Fox HE, Nelson JA. HIV-1 in trophoblastic and villous Hofbauer cells, and haematological precursors in eight-week fetuses. *Lancet* 1989;335:565-8.
- 17 Green WC. The molecular biology of human immunodeficiency virus type 1 infection. *N Engl J Med* 1991;308-17.
- 18 Maury W, Potts BJ, Rabson AB. HIV-1 infection of first-trimester and term human placental tissue: a possible mode of maternal-fetal transmission. *J Infect Dis* 1989;160:583-8.
- 19 Goldstein J, Bravermann M, Salafia C, Buckley P. The phenotype of human placental macrophages and its variation with gestational age. *Am J Pathol* 1988;244:648-59.
- 20 Chandwani S, Greco MA, Mittal K, Antoine C, Krasinski K, Borkowsky W. Pathology and Human Immunodeficiency Virus Expression in Placentas of Seropositive Women. *J Infect Dis* 1991;163:1134-8.
- 21 Drake BL, Rodger JC. Phagocytic properties of cultured trophoblast. *Placenta* 1987;8:129-39.
- 22 Nelson JA, Wiley CA, Reynolds-Kohler C, Margaretten W, Reese CE, Levy JA. Human immunodeficiency virus detected in bowel epithelium from patients with gastrointestinal symptoms. *Lancet* 1988;ii:259-62.
- 23 Mundy DC, Schinazi RF, Gerber AR, Nahmias AJ, Randall HW. Human immunodeficiency virus isolated from amniotic fluid. *Lancet* 1987;459-60.
- 24 Kreiss JK, Coombs R, Plummer F, *et al*. Isolation of Human Immunodeficiency Virus from genital ulcers in Nairobi prostitutes. *J Infect Dis* 1989;160:380-4.
- 25 Peuchmaur M, Emilie D, Vazeux R, Pons JC, Delfraissy JF, Lemaigre G, Galanaud P. HIV associated endometritis. *AIDS* 1989;3:239-41.
- 26 Werner H, Schmidtke L, Thomaschek G. Toxoplasma Infektion und Schwangerschaft. Der histologische Nachweis des intrauterinen Infektionsweges. *Klin Wochenschr* 1963;41:96-101.
- 27 Harper M, Marselle LM, Gallo RC, Wong-Staal F. Detection of lymphocytes expressing human T-lymphotropic virus type III in lymph nodes and peripheral blood from infected individuals by *in situ* hybridization. *Proc Natl Acad Sci, USA* 1986;83:772-6.
- 28 Peuchmaur M, Delfraissy JF, Pons JC, *et al*. HIV proteins absent from placentas of 75 HIV-1-positive women studied by immunohistochemistry. *AIDS* 1991;5:741-5.
- 29 Ehrnst A, Lindgren S, Dictor M, *et al*. HIV in pregnant women and their offspring: evidence for late transmission. *Lancet* 1991;338:203-7.
- 30 Amirhessami-Aghili N, Spector SA. Human immunodeficiency virus type 1 infection of human placenta: potential route for fetal infection. *J Virol* 1991;65:2231-6.
- 31 Zachar V, Spire B, Hirsch I, Chermann JC, Ebbesen P. Human transformed trophoblast derived cells lacking CD4 receptor exhibit restricted permissiveness for human immunodeficiency virus type 1. *J Virol* 1991;65:2102-7.
- 32 Rosenberg ZF, Fauci AS. Activation of latent HIV infection. *J NIH Res* 1990;2:41-5.