

Risk factors and the clinical and surgical features of fungal prosthetic joint infections: A retrospective analysis of eight cases

LEI GENG^{1*}, MENG XU^{1*}, LIGANG YU¹, JIE LI², YONGGANG ZHOU¹, YAN WANG¹ and JIYING CHEN¹

Departments of ¹Orthopaedics and ²Pathology, The General Hospital of Chinese People's Liberation Army, Beijing 100853, P.R. China

Received December 30, 2014; Accepted March 1, 2016

DOI: 10.3892/etm.2016.3353

Abstract. Fungal prosthetic joint infections (PJI) and reports of their clinical investigation are rare. In addition, there has been little evidence regarding the outcome of the two-stage exchange protocol for the treatment of fungal PJI. In order to investigate the risk factors and clinical, microbiological and pathological features of fungal PJIs, as well as the effects of the two-stage exchange protocol on their outcome, the present study analyzed eight retrospective fungal PJI cases, involving four cases affecting the hips and four affecting the knees, between May 2000 and March 2012. In all cases, a cemented spacer saturated with antimicrobials was used during the two-stage exchange protocol, and systematic antifungal agents were administered during the interim period. The average follow-up duration was 4.4 years. Of the eight cases, six had undergone additional surgery on the infected joint prior to infection with the fungus. Following histological analyses, it was determined that the average number of polymorphonuclear cells in the three patients infected with a fungus was only <5/high power field (HPF; magnification, x400), and that of the five patients with a hybrid infection was >5/HPF. The average Harris Hip scores or Hospital for Special Surgery knee scores were 43.6 preoperatively and 86 at the last follow-up. The two-stage exchange protocol was performed eight times in seven cases, with a failure rate of 12.5%. The remaining case was successfully treated by resection arthroplasty. The average duration of antifungal agent administration during the interim period in five of the eight cases was 1.5 months. For three of the patients, the duration of antifungal agent administration was

prolonged until the c-reactive protein levels were decreased to normal. The average duration of spacer implantation into the joint was 4.3 months. The results of the present study suggested that undergoing surgery on a prosthetic joint may be a potential risk factor for the development of fungal PJI. In addition, infiltration of polymorphonuclear leukocytes into the site of the infection may not occur at the same rate as bacterial PJI. Therefore, a two-stage exchange protocol with implantation of a cement spacer saturated with antimicrobials may be considered an effective therapeutic strategy for the treatment of fungal PJI.

Introduction

Prosthetic joint infections (PJI) are a common complication of joint arthroplasty and may lead to a poor outcome. The incidence of PJI is 1.41% for knee prostheses and 0.92% for hip prostheses, according to the Finnish joint registry data involving 112,708 prostheses (1). PJI is one of the main reasons for the failure of joint arthroplasty (2). The most common pathogens causing PJI, according to the data from the General Hospital of Chinese People's Liberation Army (Beijing China), are gram-positive bacteria and, in particular, coagulase-negative staphylococci (3). PJI caused by fungal pathogens are rare; between 1966 and July 2012, Kuiper *et al* (4) reviewed 156 patients and reported eight cases of fungal PJI.

According to a previous study, the risk factors associated with the development of fungal PJI include antibiotic-overuse, diabetes, tuberculosis, the use of immunosuppressants and diseases associated with immunosuppression, such as cancer and acquired immunodeficiency syndrome (AIDS) (5). The potential association between the surgical history of a patient, infection phase and the development of fungal PJI has rarely been investigated (6). Therefore, the present study aimed to investigate the surgical history of patients with fungal PJI at the General Hospital of Chinese People's Liberation Army in order to establish whether surgical history may be a potential risk factor of fungal PJI.

The clinical manifestations of fungal PJI include local and physical symptoms, such as pain, swelling and dysfunction of the infected joint (4). Furthermore, a few of the present cases presented with systematic symptoms, including a fever, and the levels of c-reactive protein (CRP) and erythrocyte sedimentation rate (ESR) were elevated in the majority of patients. The

Correspondence to: Mr. Jiyong Chen or Mr. Yan Wang, Department of Orthopaedics, The General Hospital of Chinese People's Liberation Army, 28 Fuxing Road, Beijing 100853, P.R. China
E-mail: 301chenjiying@gmail.com
E-mail: yanwanglxm2010@163.com

*Contributed equally

Key words: fungi, joint arthroplasty, prosthetic joint infection, histopathology, risk factor

manifestations of an infected joint following an X-ray may include loosening, osteolysis and/or swelling of soft tissue, although some patients may have none of these features (7). The most common group and species of fungus associated with fungal PJI include *Candida* and *Candida albicans* (7). A PJI may be termed a hybrid infection when it is caused by multiple pathogens. A number of patients in the present study exhibited hybrid infections. According to Wimmer *et al.*, the proportion of hybrid infections in all PJI patients was 48% (37/77). Hybrid infections have been shown to reduce the cure rate of PJI, as compared with a PJI caused by a single pathogen, thus suggesting that more attention should be paid to these patients (8).

In the case of bacterial PJI, the number of polymorphonuclear leukocytes in frozen and permanent histological sections of the infected soft tissue has been shown to increase (9). Mirra *et al.* (10) reported a strong correlation between the identification of five polymorphonuclear leukocytes in at least five separate microscopic fields and infection. However, there have been no reports regarding the histopathological features of fungal PJI; thus, it is unclear whether the association between active infection and an increased number of polymorphonuclear leukocytes in histological sections also applies to fungal PJI. Therefore, the present study investigated the histopathological features of fungal PJI.

At present, there are no guidelines regarding the protocol for the treatment of fungal PJI. In the case of bacterial PJI, the standard therapeutic strategy, which has received a high consensus, is the two stage-exchange protocol (11). The first stage involves removing the prosthesis, performing débridement and implanting a cement spacer saturated with antimicrobials, while the second stage involves removing the spacer and reimplanting the prosthesis (12). The two-stage exchange has shown good efficacy for the treatment of bacterial PJI. However, there are few examples in the literature regarding whether this protocol may also be successfully applied to fungal PJI (4).

The present retrospective study aimed to identify the risk factors associated with fungal PJI in patients at The General Hospital of Chinese People's Liberation Army, as well as to investigate the association between the surgical history of these patients and the development of fungal PJI. In addition, the clinical manifestations, in particular the pathological features, were described, in order to document the characteristics of fungal PJI. Furthermore, the effectiveness of the two-stage exchange protocol for the treatment of fungal PJI was evaluated.

Materials and methods

Patients and diagnosis. A total of eight patients (Table I) with fungal PJI, including four cases of the hip and four of the knee, who were admitted to the Department of Orthopaedics at The General Hospital of Chinese People's Liberation Army between May 2000 and March 2012, were retrospectively analyzed in the present study. Written informed consent was obtained from all patients for the publication of this study.

Venous blood samples (2 ml) from all patients were sent to the Biochemical Laboratory for the detection of plasma albumin and serum creatinine, urea, alanine transaminase (ALT) and aspartate aminotransferase (AST) levels using an automated biochemical analyzer (Olympus AU2700;

Olympus Corporation, Tokyo, Japan). The soft tissue samples, synovial fluid, drainage fluid or sinus fluid were sent to the Microbiology Department for culture of the pathogen. Cultured fungi were identified into genus and species by matrix-assisted laser desorption/ionization-time of flight mass spectrometry (VITEK® MS; bioMérieux, Marcy l'Etoile, France). The patients were diagnosed with fungal PJI if the same fungus was cultured from ≥ 2 specimens obtained from preoperative aspirate, a sinus, postoperative drainage fluid, wound exudate and/or intraoperative tissue or synovial fluid. Culture was performed preoperatively using fluid from the aspiration in three cases and fluid from a sinus in two cases. A fungal pathogen was detected for the two cases in which the fluid from a sinus was cultured (Table I). The remaining six cases were diagnosed with PJI via analysis of frozen tissue sections obtained intraoperatively or by the presence of a sinus. PJI could not be excluded if the frozen tissue section was negative due to the high false negative rate of frozen tissue sections with regard to the diagnosis of PJI (13,14). The pathogen was confirmed as a fungi post-operatively according to the intraoperative culture and postoperative drainage culture (Table I).

Treatment protocol. The two-stage exchange protocol involved the removal of the primary prosthesis and implantation of the cemented spacer saturated with antimicrobials in the first stage, and the implantation of the prosthesis in the second stage. The therapeutic strategy for the eight patients included two-stage exchange and resection arthroplasty (Fig. 1). A cemented spacer saturated with antimicrobials was made according to our previous study (15), and was used when both the two-stage exchange protocol and resection arthroplasty were performed. Since five of the eight cases were diagnosed with hybrid infections, the antimicrobials saturated in the cemented spacer included vancomycin (Eli Lilly Suzhou Pharmaceutical Group Co., Ltd., Suzhou, China), meropenem (Sumitomo Dainippon Pharma Co., Ltd., Osaka, Japan) and/or amphotericin B (Ben Venue Laboratories, Inc., Bedford, OH, USA). The types and doses of the antimicrobials are presented in Table II.

Following implantation of the cemented spacer, systematic antifungal agents, including fluconazol (400 mg once daily; intravenous for 7 days and then orally; Shandong Luoxin Pharmaceutical Group Stock Co., Ltd., Shandong, China), voriconazole (5 mg/kg intravenously twice daily for 7 days, then 200 mg orally twice daily; Livzon Pharmaceutical Group Inc., Zhuhai, China) amphotericin B (initially 5 mg/day, then gradually increased to 40 mg/day, once daily) and/or caspofungin (70 mg on the first day, then 50 mg intravenously once daily; Merck Sharp & Dohme, Clermont-Ferrand, France), were administered for 6 weeks.

Venous blood samples (2 ml) from all patients were sent to the Clinical Laboratory Department for the detection of CRP levels using the immune scatter turbidimetry method (16), on a MicroScan Turbidity Meter with CRP detecting reagents (Siemens AG, Munich, Germany). In addition, white blood cell (WBC) levels were detected using the ADVIA 2120i Hematology System with Autoslide (Siemens AG). The levels of CRP were examined prior to removal of the cemented spacer and reimplantation of the prosthesis.

Table I. Information regarding the basic condition, chronic disease history, infection phase and microbiological features of the eight patients with a fungal prosthetic joint infection.

Case no.	Age/gender	Chronic disease history	Site/phase	Fungal species	Other pathogen	Sinus	Positive culture site
1	42/M	No	Right hip/delayed phase (9 Mon)	Candida albicans	Acinetobacter Iwoffii,	Absence CNS	6x post-op drainage Intra-op culture
2	53/F	Diabetes	Left hip/early phase (1 W)	Candida albicans	SA	Presence	Intra-op culture, Post-op exudate
3	43/F	Gallbladder excision	Left hip/late phase (7 Y)	Candida albicans	Enterococcus faecalis	Presence	Sinus intra-op culture
4	78/M	No	Left hip/delayed phase (11 Mon)	Candida glabrata	Gram negative bacilli, SA	Presence	Sinus intra-op culture, post-op drainage
5	76/F	Hypertension	Right knee/delayed phase (8 Mon)	Mould	CNS	Absence	Intra-op culture
6	58/F	No	Left knee/early phase (<1 W)	Candida freyschussii	No	Presence	Intra-op culture
7	63/F	No	Left knee/delayed phase (2 Y)	Aspergillus spp.	No	Absence	Intra-op culture
8	67/M	Hypertension	Left knee/early phase (3 Mon)	Candida parapsilosis	No	Presence	Post-op exudate

M, male; F, female; Post-op, postoperative; Intra-op, intraoperative; Mon, month; W, week; Y, year; CNS, coagulase-negative staphylococcus; SA, Staphylococcus aureus.

Histopathological analysis. Samples of the soft tissue surrounding the prosthesis, which was highly suspected as the infected tissue, were obtained intraoperatively from all patients, frozen and sent to the Pathology Department for histopathological analyses and to determine whether the pathogen had been completely eradicated. Briefly, the tissue samples were made into a permanent paraffin-embedded block (Huayong Paraffin Co., Ltd., Shanghai, China), sliced into sections (5 μ m) using a microtome (RM2235; Leica Microsystems GmbH, Wetzlar, Germany) and stained with hematoxylin & eosin (Leica Microsystems GmbH). Subsequently, the permanent sections were observed under a microscope (CX31; Olympus Corporation). Five high power fields (HPF; 400x magnification) of vision for each section were observed to calculate the average number of polymorphonuclear cells. If the average number of polymorphonuclear cells was >10, infection persistence was assumed and another cemented spacer was implanted.

Outcome evaluation. The treatment was considered a success if the infection was successfully eradicated without persistence or recurrence during the ≥ 2 years follow-up period. Conversely, the treatment was considered a failure in the case of recurrence or persistence of fungal PJI, as supported by clinical examination, signs or symptoms within 2 years post-operatively. The pain and function of the hip or knee joint were evaluated pre-operatively and at the final follow-up using the Harris Hip Score (17) or Hospital for Special Surgery (HSS) score (18). The pain and function of the joints of patients evaluated by the HHS or HSS scores are considered good if the scores are between 80-89, and are considered excellent if the scores are between 90-100 (17,18). Prior to and following surgery, the patients were sent to the Medical Image Department for X-ray examination (Discovery XR656; GE Healthcare Bio-Sciences, Pittsburgh, PA, USA) of the affected joint.

Statistical analysis. Data are expressed as the mean \pm standard deviation, which was calculated using SPSS software, version 17.0 (SPSS, Inc., Chicago, IL, USA).

Results

Demography and risk factors. The age, gender, places of residence, history of chronic diseases and nutritional information were collected for all patients. The average follow-up duration was 4.4 years (range, 2.9-6.6 years). The potential risk factors for fungal PJI, including immunosuppression-associated diseases or factors, duration from primary arthroplasty to the onset of symptoms of infection, the frequency at which the patient had undergone surgical procedures prior to the diagnosis of fungal PJI and the presence of hybrid infection with/without sinus are presented in Table I. The average age of the patient was 60 years, of which four patients were older than 60 years. Of the patients, five were female and three were male. Of the eight cases, seven were residents of urban areas and the remaining patient was from a rural area. Two of the patients had hypertension, one had diabetes mellitus and one had undergone a cholecystectomy. There was no evidence of immunosuppression-associated diseases in any of the patients. The average body mass index of the patient's was

Table II. Treatment and outcome information for the eight patients with a fungal prosthetic joint infection.

Case No.	Surgery/outcome	Antimicrobial saturated in cement/duration in joint	Antimicrobials/duration	Pre/post-op Harris or HSS	Follow-up duration/results
1	Two-stage revision/success	4 g Van/40 g/3 Mon	After spacer, Flu/1.5 Mon after revision, Flu/1 Mon	48/92	3.3 Y/No recurrence
2	Two-stage revision/failure two-stage revision/success	2nd spacer 4.8 g Van/40 g/3.6 Mon	After 2nd spacer, Flu/1.5 Mon after 2nd revision, Flu/1 Mon	45/87	6.6 Y/No recurrence
3	Two-stage revision/success	4 g Van+2 g Mer/40 g/4.5 Mon	Pre-op Flu, Vor/1 Mon after spacer, Flu/4 Mon after revision, Flu/1 Mon	43/86	5.1 Y/No recurrence
4	Spacer implantation/failure resection arthroplasty/success	4.8 g Van/40 g/6 Mon	After spacer, Flu/3 Mon, Amp/2 Mon after resection arthroplasty Cas/46 days	37/62	2.9 Y/No recurrence before death
5	Two-stage revision/success	3 g Van+1 g Mer/40 g/3 Mon	After spacer, Flu/1.5 Mon after revision, Flu/1 Mon	46/89	3.7 Y/No recurrence
6	Two-stage revision/success	4 g Van/40 g/3 Mon	After spacer, Flu/1.5 Mon after revision, Cas/1 Mon	35/91	4.7 Y/No recurrence
7	Two-stage revision/success	3 g Van+1 g Mer/40 g/7 Mon	After spacer, Flu/6 Mon after revision, Flu/1 Mon	40/91	5.2 Y/No recurrence
8	Two-stage revision/success	2 g Van+200 mg Amp/40 g/4 Mon	After spacer, Flu/1.5 Mon after revision, Flu/1 Mon	55/90	4 Y/No recurrence

Pre-op, preoperative; Post-op, postoperative; Mon, months; W, week; Y, year; Flu, fluconazol; Vor, voriconazole; Amp, Amphotericin B; Cas, caspofungin; Van, vancomycin; Mer, Meropenem; HSS, Hospital for Special Surgery.

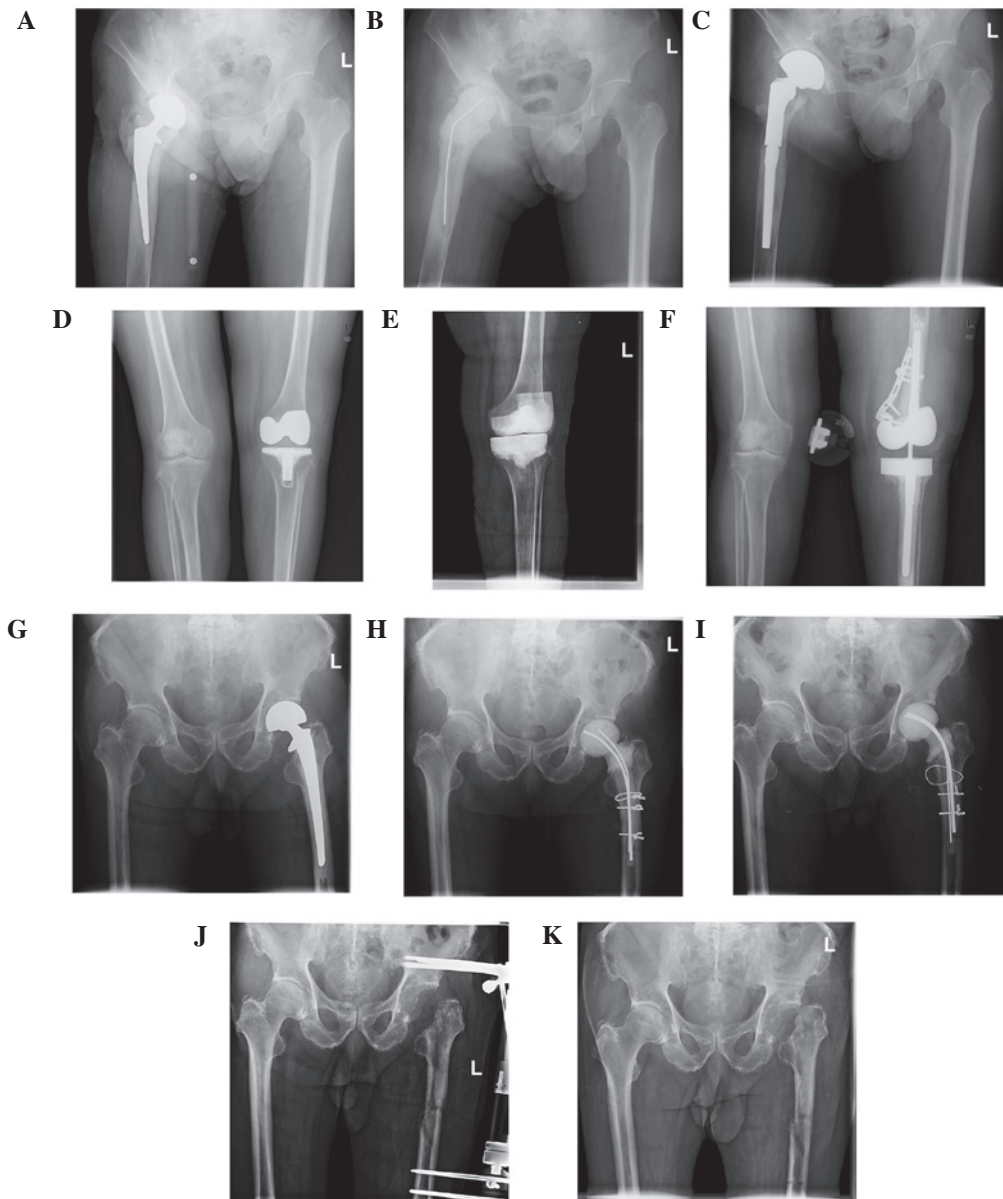


Figure 1. Preoperative and postoperative X-rays of three cases of a fungal PJI. The X-ray images present the two-stage exchange protocol method for knee and hip joints and the method of resection arthroplasty. (A) Case 1 suffered from fungal PJI of the hip; (B) the prosthesis was removed and the cement joint spacer was implanted. (C) Following treatment with antifungal agents in the interim period, the cement spacer was removed and the prosthesis was reimplanted. (D-F) Case 6 underwent a similar therapeutic program, although the patient suffered from fungal PJI of the knee. (G-I) Case 4 was treated with the cement spacer, but then refused to receive reimplantation of the prosthesis; therefore, (J and K) resection arthroplasty was performed. PJI, prosthetic joint infection.

$22.89 \pm 5.33 \text{ kg/m}^2$ (normal range, $18.5\text{-}23.9 \text{ kg/m}^2$). One patient had plasma albumin levels of 33 g/l (normal range, $35\text{-}50 \text{ g/l}$). There were no evidence indicating that any of the patients had abnormal nutrition conditions. Of the eight cases, six had previously undergone additional surgery on the infected joint. This surgery had been conducted following the primary total joint arthroplasty and prior to the diagnosis of fungal PJI (Fig. 2).

The duration from primary arthroplasty to the onset of symptoms of infection in the eight patients are presented in Table I. Three cases were defined as early infections (<3 months), four cases were delayed infections (3 months to 2 years) and one case was of a late infection (>2 years) (7). Typically, early and delayed phase infections were considered to be associated with factors of the surgery, whereas the late phase infection was considered to be associated with

a predisposing factor in the patient. Five cases were hybrid infections, of which three had a sinus simultaneously.

Clinical manifestation. The symptoms experienced by the eight patients included swelling, pain, dysfunction and limited mobility of the infected joint. Five of the eight cases had sinus and effusion of the infected limb. The temperature of one patient was 37.5°C , which was around the upper limit of the normal range. All other cases had a normal body temperature.

Laboratory examination. The CRP levels were elevated above the normal range ($0\text{-}0.8 \text{ mg/dl}$) in six patients, but were normal in the remaining two patients, and the values were 11.8, 6.23, 6.3, 6.02, 0.65, 0.95, 4.99 and 0.48 mg/dl . ESR were higher

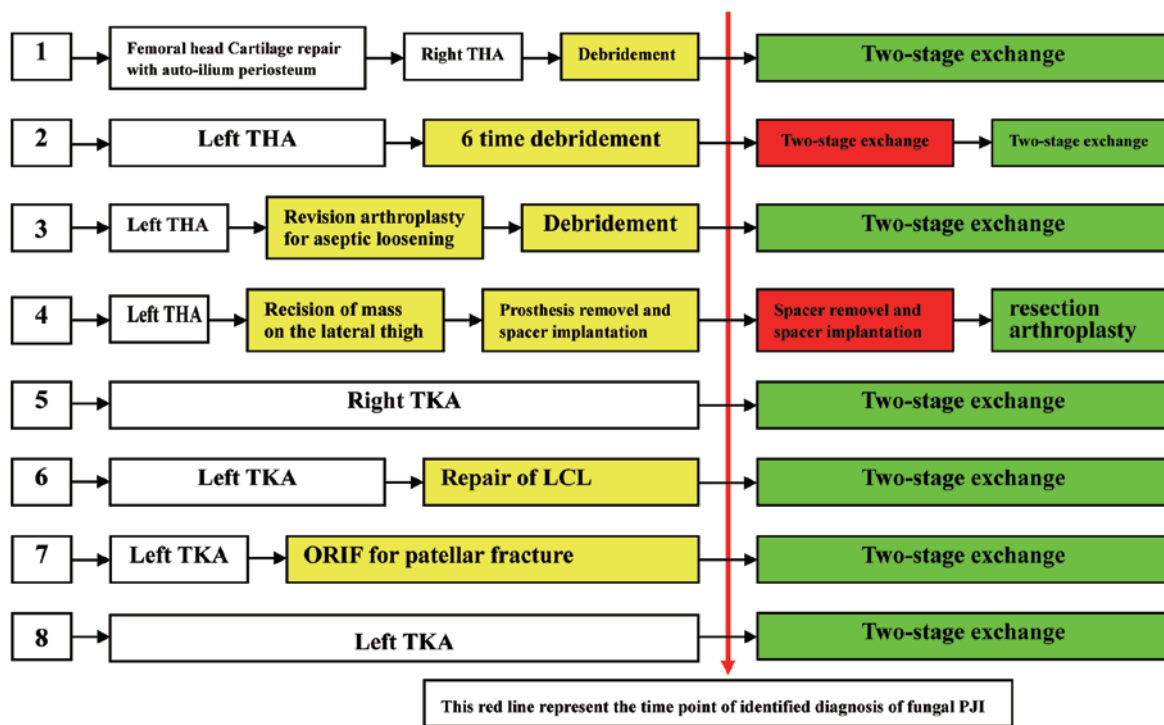


Figure 2. Treatment regimes of eight cases of fungal PJI. The yellow boxes represent the surgical procedures undergone by the patients following the primary joint arthroplasty and prior to the diagnosis of fungal PJI, and this was deemed a risk factor of fungal PJI. Red indicates the persistence or recurrence of infection on the joint, whereas green indicates eradication of the infection at ≥ 2 years follow-up. PJI, prosthetic joint infection; ORIF, open reduction and internal fixation; THA, total hip arthroplasty; TKA, total knee arthroplasty; LCL, lateral collateral ligament.

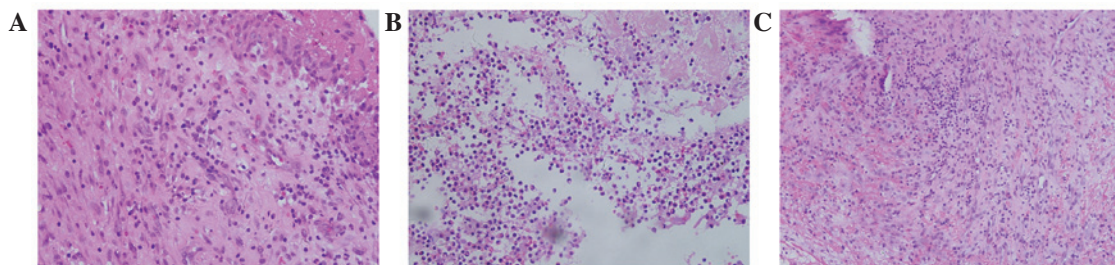


Figure 3. Histopathological features (hematoxylin and eosin staining; magnification, x200 in A and B, x100 in C). Histopathological features of the soft tissue from the infected prosthetic joint of (A) patient 8 who was infected with *Candida parapsilosis* only, (B) patient 4 who had a hybrid infection with *Candida glabrata*, gram negative bacilli and *Staphylococcus aureus*, and (C) patient 5 who was infected with a mould and a coagulase-negative staphylococcus.

than normal (normal range, 0-20 mm/h) in seven patients and were on the threshold value in one patient, and the values were 130, 61, 86, 67, 80, 75, 25 and 20 mm/h. The WBC counts of the eight patients were 12.43, 6.12, 6.95, 9.42, 3.31, 4.87, 5.92 and $4.42 \times 10^9/l$ (normal range, $3.5-10 \times 10^9/l$). The WBC count was higher than normal in one patient, but was normal in seven patients. The plasma albumin levels were assessed in order to evaluate the nutritional condition of the patients and were 45.6, 47.8, 43.5, 33.0, 49.8, 44.2, 39.8 and 37.6 g/l (normal range, 35-50 g/l) for the eight patients. The serum creatinine and urea levels were normal in all patients. The ALT levels of the eight patients were 10.3, 9.5, 11.3, 50.9, 15.7, 17.4, 12.9 and 15.8 U/l (normal range, 0-40 U/l) and the AST levels were 24.9, 27.1, 21.6, 58.2, 20.8, 19.1, 18.6 and 21.8 U/l (normal range, 0-40 U/l). The levels of ALT and AST were slightly elevated in one patient and were normal in the other seven patients.

X-ray. The eight cases had no features specific to fungal PJI. Soft tissue swelling, a lucent line between the prosthesis and bone, and osteolysis were observed in some of the patients (Fig. 1).

Histopathological features. The permanent tissue sections obtained intraoperatively from the infected joints were analyzed under a microscope. Five high-power fields of vision for each section were used to calculate the average number of polymorphonuclear cells. The average values of the three patients infected with a single fungus were 0/HPF, 2/HPF and 3/HPF, corresponding to cases 6, 7 and 8, respectively. The average values of the other five patients infected with a fungus as well as bacteria were 12/HPF, 4/HPF, 90/HPF, 130/HPF and 12/HPF, corresponding to cases 1, 2, 3, 4 and 5, respectively. Fungal hyphae were observed in the tissue section of case 5; fungal spores were not observed in any of the cases (Fig. 3).

Microbiological features. The positively cultured tissue specimens included eight intraoperative synovia and/or soft tissue, two preoperative fluid samples from sinuses, two postoperative drainage fluid samples from the infected joints and two postoperative fluid samples from wound exudate (Table I). Of the eight patients, six harbored *Candida* species and two harbored moulds. The *Candida* isolates included three *Candida albicans*, one *Candida freyschussii*, one *Candida glabrata* and one *Candida parapsilosis*. Of the two molds, one was of the *Aspergillus* genus. To the best of our knowledge, no previous cases of PJI have been caused by *C. freyschussii*. *C. freyschussii* and *C. glabrata* were susceptible to treatment with fluconazol at the initiation of antifungal therapy; however, due to the lack of effectiveness of the fluconazol treatment, the pathogen were once again cultured and antimicrobial susceptibility testing demonstrated that resistance to fluconazol was emerging. However, the pathogens remained susceptible to caspofungin.

Evaluation of treatment. The average preoperative Harris or HSS score was 43.6 and the average postoperative Harris or HSS score was 86. Case 4 was treated by resection arthroplasty without prosthesis implantation, so the Harris score of this patient was 62 following the surgical procedure. The remaining seven cases had good or excellent Harris or HSS scores. The scores for the eight cases are presented in Table II.

The treatment regimes for the eight cases is presented in Fig. 2. Case 2 was initially treated with the two-stage exchange protocol; however, the infection persisted and so a second two-stage exchange was performed. Case 4 was initially treated by two time of implantation of cemented spacer and latest time by resection arthroplasty without any spacer or prosthesis because the patient refuse to receive implantation of prosthesis. The remaining six cases were successfully treated by two-stage exchange. In total, the two-stage exchange protocol was performed eight times in seven cases, in which the protocol was successful seven times. The failure rate of two-stage exchange protocol was 12.5%.

The average duration of antifungal agent usage in the cases who had undergone two-stage exchange following implantation of the cement spacer and prior to the implantation of prosthesis was 2.8 months; in five of the cases, the duration was 1.5 months. In cases 3, 4 and 7, the duration of systematic antifungal agent administration was prolonged following implantation of the cement spacer to prevent the persistence of infection until the CRP levels had decreased to within the normal range.

Following reimplantation of the prosthesis, the average duration of antifungal usage was 1 month. The antimicrobials saturated into the cement implant included vancomycin, meropenem and amphotericin B. The average duration of spacer implantation in the infected joint was 4.3 months (Table II). Case 4 was infected with *C. glabrata*, which was primarily susceptible to fluconazol and amphotericin B. However, following administration of fluconazol and amphotericin B for ~5 months, the infection had not been eradicated and the treatment was considered a failure. Therefore, this patient underwent resection arthroplasty without a spacer or prosthesis. The intraoperative tissue of this patient was cultured again, which demonstrated that the pathogen was resistant to fluconazol and amphotericin B, although it was susceptible to caspofungin.

Thus, the patient underwent treatment with caspofungin for 46 days, permitting eradication of the infection.

Discussion

Fungal PJI are rare; Kuiper *et al* (4) reviewed 164 cases of fungal PJI between 1966 and July 2012, and Azzam *et al* (7) conducted a multicentre analysis on fungal PJI, which included 31 cases between 1999 and 2006. Of the 31 cases reported by Azzam *et al* (7), 27 had experienced at least one chronic disease, including renal disease, a malignancy, rheumatoid arthritis, diabetes mellitus or hepatic and cardiac diseases, and some cases had a history of prolonged treatment with antibiotics or chronic steroids. In addition, two patients had undergone multiple revision surgeries prior to the development of a fungal PJI. Kao *et al* (5) reviewed 837 cases of candidemia and determined that ~24.8% cases had previously been diagnosed with an immunodeficiency-associated condition, including lymphoma, leukemia, rheumatic diseases or AIDS, or had undergone an organ transplantation or extensive treatment with steroids. In the present study, none of the eight cases were diagnosed with an immunodeficiency-associated condition. Seven of the eight cases presented with early or delayed phase infections, which were considered to be due to factors associated with the surgical procedure. Conversely, the late phase infection was associated with a predisposing disease in the patient, such as chronic diseases and an immunodeficiency-associated condition. Of the eight cases, six had undergone additional surgery on the infected joint following the primary total joint arthroplasty and preceding the diagnosis of fungal PJI. The additional surgery may have increased the possibility of exposure to the pathogenic fungus.

Case 6 was infected with *C. freyschussii*, which, to the best of our knowledge, is the first report of a fungal PJI caused by this species. The most common pathogenic fungal group and species in these eight cases were *Candida* and *C. albicans*, which is consistent with previous reports (7,19). The diagnosis of fungal PJI remains challenging, due to the difficulty of culturing the pathogen from the aspiration of the infected joint preoperatively. Three cases in the present study underwent preoperative aspiration; however, none of them had a positive culture. In addition, when both fungal and bacterial pathogens are detected upon culturing, it is difficult to identify the cause of the infection. Therefore, it may be necessary to obtain and culture multiple intraoperative specimens, including both synovial fluid and granulation tissue, from various sites of the joint. In the present study, the fluid from a sinus was extracted and cultured in order to identify the causative pathogen.

To the best of our knowledge, there have been no previous reports regarding the histopathological features of fungal PJI, although the histopathological features of general fungal infections include acute inflammation and chronic granuloma formation (20). Ritter *et al* (21) reported 40 cases of *Exserohilum* infections caused by contaminated steroid injections. The infection site included meninges, epidural, peripheral joint and injection site and the histopathological features included suppurative and granulomatous meningitis and vasculitis. Ayhan *et al* (22) reported the incidence of chronic granulomatous *Aspergillus* synovitis in a 5-year-old girl with acute lymphoblastic leukemia undergoing chemotherapy, in which

the main histopathological characteristic was a chronic granuloma. Typically, in the chronic phase of a fungal infection, the number of polymorphonuclear leukocytes do not increase and the granuloma is the main histopathological manifestation (23). In the present study, the polymorphonuclear leukocyte count was normal in three of the cases in which the pathogen was a fungus only, which is consistent with previous reports (21,22). Therefore, it is not possible to exclude the diagnosis of fungal PJI if the histological frozen tissue section or permanent tissue section has a normal polymorphonuclear leukocyte count. Instead, if a fungus PJI is suspected, Grocott's methenamine silver stain, Periodic acid-Schiff stain or Fontana-Masson stain may be used, since these are able to detect most forms of fungi, including hyphae and spores (21).

Kuiper *et al* (4) reviewed 164 cases of fungal PJI from 1966 to July 2012 and reported a success rate for the two-stage exchange protocol of 84.8% (67/79). In the 31 cases of fungal PJI reported by Azzam *et al* (7), 19 had undergone the two-stage exchange protocol, of which 10 had recurrence of infection, and so the success rate was 47.4%. Phelan *et al* (24) reported four cases and reviewed six cases of Candidal PJI that were treated by the two-stage exchange protocol, and reported a success rate of 80%. In addition, Anagnostakos *et al* (19) reported seven cases of fungal PJI treated by the two-stage exchange protocol without recurrence in 2012, and Ueng *et al* (25) reported 16 patients who had undergone the two-stage exchange protocol, of which eight relapsed or the infection was not controlled, and the success rate was 50%. The present study demonstrated a success rate of 87.5% for the seven cases (a total of eight times) who had undergone the two-stage exchange protocol. Sia *et al* (26) reviewed 1,077 cases of PJI treated by the two-stage exchange protocol in 30 studies, and reported an average success rate of 87% (range, 57-100%). A pattern that emerged from the literature review was that patients with fungal PJI that were treated by the two-stage exchange protocol were more likely to relapse, as compared with patients with bacterial PJI that underwent the same treatment (7,25,26). However, at present this remains a hypothesis with no definitive evidence. There has been only one report of a patient with fungal PJI who was successfully treated by the one-stage exchange protocol (27), and the strategy of débridement with prosthesis retention has had few successful reports (28-30). Therefore, the two-stage exchange protocol may be considered the most effective strategy for the treatment of fungal PJI (4).

At present, the antifungal agents that are used to saturate the cement spacer are amphotericin B and voriconazole. Although the elution concentration of amphotericin B surrounding the cement spacer was undetectable when it was combined with cement *in vivo* (31) and *in vitro* (32), a poragen, such as cephalosporin, may be added to the cement, together with amphotericin B, in order to facilitate the elution of amphotericin B. A previous study reported that 200 mg amphotericin B and 10 g cephalosporin may be added together in 40 g cement (33). Voriconazole was reported to have an excellent elution concentration and bioactivity both *in vivo* (34) and *in vitro* (35,36). Deelstra *et al* (37) reported a case of a *C. albicans* prosthetic hip infection successfully treated by staged exchange with a cement spacer saturated with voriconazole, amphotericin B and vancomycin. However, at the time of the present study, there was no evidence to support the use of amphotericin B

and so it was only added to the cement spacer for one of the eight cases. Nevertheless, the effect of a cement spacer loaded with voriconazole and amphotericin B on the eradication of a fungal PJI requires further clinical investigation.

At present, the duration for which the antifungal agent should be used following the implantation of the spacer and prior to reimplantation of the prosthesis is unknown, and there are no guidelines to address this issue. A previous study recommended that an antifungal agent should be administered for ≥ 1 year, in order to eradicate a fungal infection (30), and the Infectious Diseases Society of America guidelines recommend between 6 and 12 months (38). However, Anagnostakos *et al* (19) suggested that 6 weeks of administration of an antifungal agent following the implantation of a spacer was sufficient. Furthermore, Kuiper *et al* (4) demonstrated that the outcomes of patients who had received antifungal agent therapy for 0-6 weeks were no different, as compared with the outcomes of patients who had received the same therapy for 0-2 months, 0-3 months or 0-6 months. Although five of the eight cases in the present study were treated for 1.5 months, three underwent an elongated treatment regime as their CRP levels were higher than normal, which may be considered a prognostic marker for the persistence of an infection. Therefore, the duration of which the antifungal agent should be used following implantation of the spacer and prior to reimplantation of the prosthesis remains unclear and requires further analysis. It is important to note that antimicrobial resistance may lead to therapy failure. In the present study, the pathogens isolated from cases 4 and 6 were resistant to fluconazole, although they were susceptible to caspofungin. Therefore, the susceptibility profile of the pathogen causing the fungal PJI should be analyzed rapidly in order to ensure the effectiveness of the antifungal agent being used.

In conclusion, the present study demonstrated that undergoing surgery on a prosthesis is a potential risk factor for the development of fungal PJI. In addition, in the permanent histological sections from the infected tissue of a fungal PJI, the polymorphonuclear leukocyte count did not increase, as is typically observed for bacterial PJI; thus suggesting that the number of polymorphonuclear leukocytes in the joint may not be used for the diagnosis of fungal PJI. Finally, a two-stage exchange protocol with implantation of a cement spacer saturated with antimicrobials may be considered an efficient strategy for the treatment of fungal PJI.

References

1. Huotari K, Peltola M and Jämsen E: The incidence of late prosthetic joint infections: A registry-based study of 112,708 primary hip and knee replacements. *Acta Orthop* 86: 321-325, 2015.
2. Vessely MB, Whaley AL, Harmsen WS, Schleck CD and Berry DJ: The chitranjan ranawat award: Long-term survivorship and failure modes of 1000 cemented condylar total knee arthroplasties. *Clin Orthop Relat Res* 452: 28-34, 2006.
3. Yang Y, Yang F, Zhang Z, Li H and Chen J: Distribution and drug sensitivity of pathogens in patients with prosthetic joint infection after primary total knee arthroplasty. *Zhongguo Xiu Fu Chong Jian Wai Ke Za Zhi* 28: 848-852, 2014 (In Chinese).
4. Kuiper JW, van den Bekerom MP, van der Stappen J, Nolte PA and Colen S: 2-stage revision recommended for treatment of fungal hip and knee prosthetic joint infections. *Acta Orthop* 84: 517-523, 2013.
5. Kao AS, Brandt ME, Pruitt WR, Conn LA, Perkins BA, Stephens DS, Baughman WS, Reingold AL, Rothrock GA, Pfaller MA, *et al*: The epidemiology of candidemia in two United States cities: Results of a population-based active surveillance. *Clin Infect Dis* 29: 1164-1170, 1999.

6. Yilmaz M, Mete B, Ozaras R, Kaynak G, Tabak F, Tenekecioglu Y and Ozturk R: *Aspergillus fumigatus* infection as a delayed manifestation of prosthetic knee arthroplasty and a review of the literature. *Scand J Infect Dis* 43: 573-578, 2011.
7. Azzam K, Parvizi J, Jungkind D, Hanssen A, Fehring T, Springer B, Bozic K, Della Valle C, Pulido L and Barrack R: Microbiological, clinical, and surgical features of fungal prosthetic joint infections: A multi-institutional experience. *J Bone Joint Surg Am* 91 (Suppl 6): S142-S149, 2009.
8. Wimmer MD, Friedrich MJ, Randau TM, Ploeger MM, Schmolders J, Strauss AA, Hischebeth GT, Pennekamp PH, Vavken P and Gravius S: Polymicrobial infections reduce the cure rate in prosthetic joint infections: Outcome analysis with two-stage exchange and follow-up \geq two years. *Int Orthop*: Jul 17, 2015 (Epub ahead of print).
9. Nuñez LV, Buttarro MA, Morandi A, Pusso R and Piccaluga F: Frozen sections of samples taken intraoperatively for diagnosis of infection in revision hip surgery. *Acta Orthop* 78: 226-230, 2007.
10. Mirra JM, Amstutz HC, Matos M and Gold R: The pathology of the joint tissues and its clinical relevance in prosthesis failure. *Clin Orthop Relat Res* 221-240, 1976.
11. Leone JM and Hanssen AD: Management of infection at the site of a total knee arthroplasty. *Instr Course Lect* 55: 449-461, 2006.
12. Zimmerli W, Trampuz A and Ochsner PE: Prosthetic-joint infections. *N Engl J Med* 351: 1645-1654, 2004.
13. Musso A, Mohanty K and Spencer-Jones R: Role of frozen section histology in diagnosis of infection during revision arthroplasty. *Postgrad Med J* 79: 590-593, 2003.
14. Tohtz SW, Müller M, Morawietz L, Winkler T and Perka C: Validity of frozen sections for analysis of periprosthetic loosening membranes. *Clin Orthop Relat Res* 468: 762-768, 2010.
15. Zhang Q, Zhou YG, Chen JY, Liu M, Zhang GQ, Chai W, Fu YM, Wang XL, Dong XY and Wang Y: Treatment of infected total knee arthroplasty with a self-made, antibiotic-loaded cement articulating spacer. *Zhongguo Gu Shang* 26: 119-123, 2013 (In Chinese).
16. Dominici R, Luraschi P and Franzini C: Measurement of C-reactive protein: Two high sensitivity methods compared. *J Clin Lab Anal* 18: 280-284, 2004.
17. Harris WH: Traumatic arthritis of the hip after dislocation and acetabular fractures: Treatment by mold arthroplasty. An end-result study using a new method of result evaluation. *J Bone Joint Surg Am* 51: 737-755, 1969.
18. Insall JN, Ranawat CS, Aglietti P and Shine J: A comparison of four models of total knee-replacement prostheses. *J Bone Joint Surg Am* 58: 754-765, 1976.
19. Anagnostakos K, Kelm J, Schmitt E and Jung J: Fungal peri-prosthetic hip and knee joint infections clinical experience with a 2-stage treatment protocol. *J Arthroplasty* 27: 293-298, 2012.
20. Koehler P, Tacke D and Cornely OA: Bone and joint infections by *Mucorales*, *Scedosporium*, *Fusarium* and even rarer fungi. *Crit Rev Microbiol* 42: 158-171, 2016.
21. Ritter JM, Muehlenbachs A, Blau DM, Paddock CD, Shieh WJ, Drew CP, Batten BC, Bartlett JH, Metcalfe MG, Pham CD, *et al*: Exserohilum infections associated with contaminated steroid injections: A clinicopathologic review of 40 cases. *Am J Pathol* 183: 881-892, 2013.
22. Ayhan AC, Ozkan K, Timur C, Aktaş B and Ceyran AB: Chronic granulomatous *Aspergillus* synovitis: A case report. *Mediterr J Hematol Infect Dis* 5: e2013043, 2013.
23. Mukhopadhyay S: Role of histology in the diagnosis of infectious causes of granulomatous lung disease. *Curr Opin Pulm Med* 17: 189-196, 2011.
24. Phelan DM, Osmon DR, Keating MR and Hanssen AD: Delayed reimplantation arthroplasty for candidal prosthetic joint infection: A report of 4 cases and review of the literature. *Clin Infect Dis* 34: 930-938, 2002.
25. Ueng SW, Lee CY, Hu CC, Hsieh PH and Chang Y: What is the success of treatment of hip and knee candidal periprosthetic joint infection? *Clin Orthop Relat Res* 471: 3002-3009, 2013.
26. Sia IG, Berbari EF and Karchmer AW: Prosthetic joint infections. *Infect Dis Clin North Am* 19: 885-914, 2005.
27. Qin HJ, Feng QM, Fang Y and Shen L: Type-I interferon secretion in the acute phase promotes *Cryptococcus neoformans* infection-induced Th17 cell polarization in vitro. *Exp Ther Med* 7: 869-872, 2014.
28. Liu L, Ling J, Ma Z, Yuan Q, Pan J and Yang H: Changes in von Willebrand factor and ADAMTS-13 in patients following arthroplasty. *Mol Med Rep* 11: 3015-3020, 2015.
29. Vasquez JC, Hart M, Denney CF, Pedowitz R and Ziegler EJ: Fungal arthritis of the knee caused by *Candida parapsilosis* in a kidney transplant recipient. *J Clin Rheumatol* 8: 147-150, 2002.
30. Xia QF, Liu JB, Liu P, Qin X, Qian SY and Tu ZG: Development of a novel quantitative real-time assay using duplex mutation primers for rapid detection of *Candida* species. *Mol Med Rep* 5: 207-210, 2012.
31. Marra F, Robbins GM, Masri BA, Duncan C, Wasan KM, Kwong EH and Jewesson PJ: Amphotericin B-loaded bone cement to treat osteomyelitis caused by *Candida albicans*. *Can J Surg* 44: 383-386, 2001.
32. Goss B, Lutton C, Weinrauch P, Jabur M, Gillett G and Crawford R: Elution and mechanical properties of antifungal bone cement. *J Arthroplasty* 22: 902-908, 2007.
33. Kweon C, McLaren AC, Leon C and McLemore R: Amphotericin B delivery from bone cement increases with porosity but strength decreases. *Clin Orthop Relat Res* 469: 3002-3007, 2011.
34. Denes E, Fiorenza F, Saint-Marcoux F, Megherbi M, Dupon M and Weinbreck P: Voriconazole stability in cement spacers. *Med Mal Infect* 42: 567-568, 2012.
35. Miller RB, McLaren AC, Pauken C, Clarke HD and McLemore R: Voriconazole is delivered from antifungal-loaded bone cement. *Clin Orthop Relat Res* 471: 195-200, 2013.
36. Grimsrud C, Raven R, Fothergill AW and Kim HT: The *in vitro* elution characteristics of antifungal-loaded PMMA bone cement and calcium sulfate bone substitute. *Orthopedics* 34: e378-e381, 2011.
37. Deelstra JJ, Neut D and Jutte PC: Successful treatment of *Candida albicans*-infected total hip prosthesis with staged procedure using an antifungal-loaded cement spacer. *J Arthroplasty* 28: 374.e5-e8, 2013.
38. Pappas PG, Kauffman CA, Andes D, Benjamin DK Jr, Calandra TF, Edwards JE Jr, Filler SG, Fisher JF, Kullberg BJ, Ostrosky-Zeichner L, *et al*: Clinical practice guidelines for the management of candidiasis: 2009 update by the Infectious diseases society of America. *Clin Infect Dis* 48: 503-535, 2009.