

Lesley Fallowfield serves as a timely reminder which should be essential reading for clinicians. Algorithms are discussed, but we would question their usefulness. The way to learn to diagnose malignant melanomas is to see them and to be taught about them in a clinical setting.

E HIGGINS  
A DU VIVIER

**Systemic Pathology.** 3rd ed. Vol 7. **Thymus, Lymph Nodes, Spleen and Lymphatics.** Ed K Henry, W St C Symmers. (Pp 1042; £140.) Churchill Livingstone. 1992. ISBN 0-443-03429-X

The new Symmers volume on haematopathology is a brave attempt to encompass all you need to know about the subject in a little short of 1000 pages. The stage is set with a short introductory essay on basic immunology and this is followed by what is essentially a comprehensive textbook on the thymus. Three chapters are devoted to the normal lymph node and non-neoplastic lymphadenopathies and are followed by a chapter on the spleen which, curiously, hardly addresses lymphoma. The following chapter of some 350 pages, while entitled "neoplastic disorders of lymphoreticular tissue," deals essentially with lymph node neoplasms with only the occasional mention of extranodal lymphomas. A section on immunohistochemistry rounds off the haematopathology, but is followed by a quite irrelevant chapter on lymphatics which surely belongs elsewhere.

There is much to be commended in this book. With few exceptions, including the extranodal lymphomas referred to above, its coverage is encyclopaedic, it is comprehensively illustrated, and the index is unusually good. It is appropriately easy to use and, consequently, will be a useful bench book. The chapter on the thymus is especially valuable because there is no other comparable text on this subject. It is a pity, however, that the Müller-Hermelink classification of thymomas, although praised, is not used.

However, this book cannot be recommended to those seeking enlightenment about this difficult and sometimes controversial branch of pathology. The two short chapters at the beginning and end of the book, on basic immunology and immunohistochemistry, respectively, comprise the only gestures to "science". Molecular genetics, which has contributed so much to recent advances in our understanding of haematopathology, does not feature at all. It is, surely, inexcusable not to have mentioned immunoglobulin light chain restriction, CD10 positivity, immunoglobulin gene rearrangement and the t(14;18) translocation in the 25 pages and 42 illustrations devoted to follicular lymphoma. Pathologists are now much less exercised about the classification of non-Hodgkin's lymphomas than this book would suggest, having settled for either the working formulation or the updated Kiel classification. Developments in immunophenotyping and molecular genetics are beginning to stimulate new thoughts about lymphoma classification, but in this respect the book moves decisively backwards to the largely abandoned classification of the British National Lymphoma Investigation.

The publishers of this series have, for some reason, chosen to persist with the same dull

format as that of the first (1966) edition. The illustrations are also rather flat and grey. The aim seems to be to present British pathology as a dignified, conservative descriptive discipline; this accentuates the faults of this book and masks its strengths. The authors deserve better.

P G ISAACSON

**Biopsy Pathology of the Skin.** N Kirkham. **Biopsy Pathology Series 16.** (Pp 396; £59.50.) Chapman & Hall. 1991. ISBN 0 412 35080 7

I must admit to being a little sceptical when this compact volume of just under 400 pages arrived on my desk. This scepticism arose from my doubt that a book purporting to cover biopsy pathology of the skin could be easily carried in my overcoat pocket.

I had a pleasant surprise. Not only did I find this book easy to read (probably due to Dr Kirkham's rather anecdotal and idiosyncratic style) but also when put to the acid test of lying next to my microscope for a few weeks I found myself referring to it rather more often than some of the larger texts on my shelf. Obviously a book of this size cannot and does not claim to be comprehensive. I think that the balance of the various sections is about right and some of the more contentious areas of dermatopathology, such as the melanocytic lesions, are given ample consideration. Any shortfalls in the included material are to some extent compensated by the remarkably up to date references. The photomicrographs, both colour and black and white, are good and the index appears to work pretty well. All in all this book is good value and is yet another worthwhile addition to this series.

S HUMPHREYS

## NOTICES

### ACP Locum Bureau

The Association of Clinical Pathologists runs a locum bureau for consultant pathologists.

Applicants with the MRCPATH who would like to do locums and anyone requiring a locum should contact The General Secretary, 221 Preston Road, Brighton BN1 6SA. Tel (0273) 561188. Fax: (0273) 541227.

### Melanoma '93

A joint meeting of the Royal College of Pathologists and the Melanoma Study Group, sponsored by the South East Thames Regional Health Authority Quality Initiative.

6 and 7 May 1993,  
Brighton Conference Centre

This two day consensus conference will address problems in the biopsy diagnosis of melanocytic disorders. As well as formal presentations by Bernard Ackerman (New York) and David Elder (Philadelphia), the programme will include presentations and discussions of proffered cases and papers. Hotel accommodation and car parking will be available at discount rates. The conference takes place during the Brighton International Festival. A spouse programme will be available.

Further details are available from Dr N Kirkham, Dept. of Histopathology, Royal Sussex County Hospital, Brighton BN2 5BE, UK. Fax: 0273-600182.

### Corrections

An author's name was accidentally omitted from the list on a piece of correspondence: Current views on cervical neoplasia (*J Clin Pathol* 1992;45:643). We apologise to Dr R A Burnett.

In the same issue the legend of the following figure was incomplete (Misbah *et al*, *J Clin Pathol* 1992;45:624-7). The correct version is reproduced below:

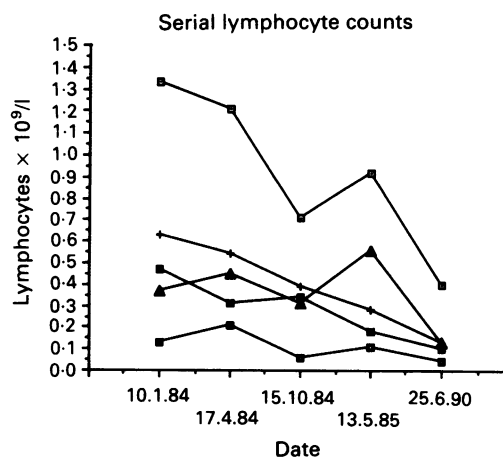


Figure 1 Serial lymphocyte counts. Normal ranges: —□— total lymphocytes (2.0-4.0) × 10<sup>9</sup>/l, —+— CD3 (0.6-1.5), —■— CD4 (0.4-1.0), —■— CD8 (0.2-0.7), —▲— B cells (0.1-0.5).