

Endobronchial ultrasound: what is it and when should it be used?

ARL Medford

ABSTRACT – Endobronchial ultrasound has become increasingly used in the UK as a lung cancer staging and diagnostic tool. It has many applications especially in the mediastinal lymph nodes but also the vascular structures as well as the airway wall itself. It is superior to conventional transbronchial needle aspiration in lung cancer staging and diagnosis of mediastinal lymphadenopathy. With time it may well replace mediastinoscopy completely for staging lung cancer. There are, however, training issues and revenue-based tariff systems have been slow to reflect this innovation. Future developments may include routine use in the assessment of central pulmonary vasculature and assessment of airway wall remodelling.

KEY WORDS: endobronchial ultrasound, lung cancer staging, mediastinal lymphadenopathy, mediastinoscopy, transbronchial needle aspiration

Introduction

Gas limits transthoracic ultrasound. Endoscopic ultrasound (EUS) was developed in the 1980s for evaluation of gastrointestinal malignancies but was also used to sample accessible lymph nodes in lung cancer. However, airway interference hampered vision of other lymph nodes and other nodes were not accessible from the oesophagus but nearer the airway. This prompted the development of endobronchial ultrasound (EBUS) in the 1990s. Subsequent improvements included smaller probes to allow adequate ventilation and instruments to be put down the working channel. Radial probe EBUS was first developed and then subsequently linear probe EBUS.

Current EBUS service provision remains centralised in many areas limited by the cost. Currently, EBUS is most commonly used for staging (and diagnosis) of lung cancer and evaluation of unexplained mediastinal lymphadenopathy although it has many other applications. This paper will detail the indications for EBUS as well as reviewing some of the training and financial issues before briefly discussing future applications.

What is endobronchial ultrasound?

EBUS combines an endoscopic image with an ultrasound probe giving a sonographic image through the airway wall (Fig 1). There are two probe types. Radial probe EBUS uses a high frequency probe (20–30 MHz) giving a high resolution of less than

1 mm but limited depth penetration of 5 cm with a 360-degree view (Fig 2).

The more commonly used linear probe EBUS (Fig 3) has a lower frequency (7.5 MHz) with lower resolution but better depth penetration (up to 9 cm) allowing a sonographic view of mediastinal structures. It is most commonly used to sample lymph nodes: endobronchial ultrasound-guided transbronchial needle aspiration (EBUS-TBNA). Unless specified, the term EBUS in this paper refers to linear probe EBUS.

Indications for endobronchial ultrasound

The indications for EBUS are as follows:

- staging of lung cancer
- mediastinal lymphadenopathy
- therapeutic applications
- assessment of airway wall infiltration and peripheral nodules
- future applications: pulmonary vascular disease, airway remodelling.

This paper will focus on the first two indications and briefly touch on the other indications before discussing training and financial issues.

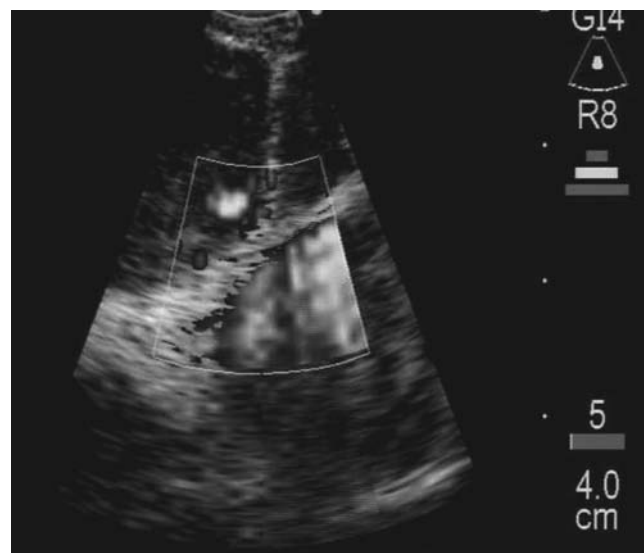

Fig 1. Typical linear probe endobronchial ultrasound-guided transbronchial needle aspiration image (prior to sampling) of lymph node demonstrating intra-nodal vessels and adjacent aorta (in power Doppler mode). Reproduced with permission from BMJ Publishing Group Ltd.⁴

ARL Medford, consultant respiratory physician, North Bristol Lung Centre, Southmead Hospital, Bristol

Staging of lung cancer

Accurate staging (and timely diagnosis) are pivotal for appropriate treatment in lung cancer. Staging algorithms and treatment are influenced by mediastinal lymph node metastases which determine outcome.¹ Radiological staging techniques (contrast-enhanced computed tomography (CT) of the chest and upper abdomen and positron emission tomography (PET)) have their limitations and therefore tissue confirmation is needed.²

Mediastinal lymph nodes are sampled when enlarged on CT short axis (greater than 1 cm) and/or metabolically active on PET or PET/CT. Mediastinal sampling techniques include

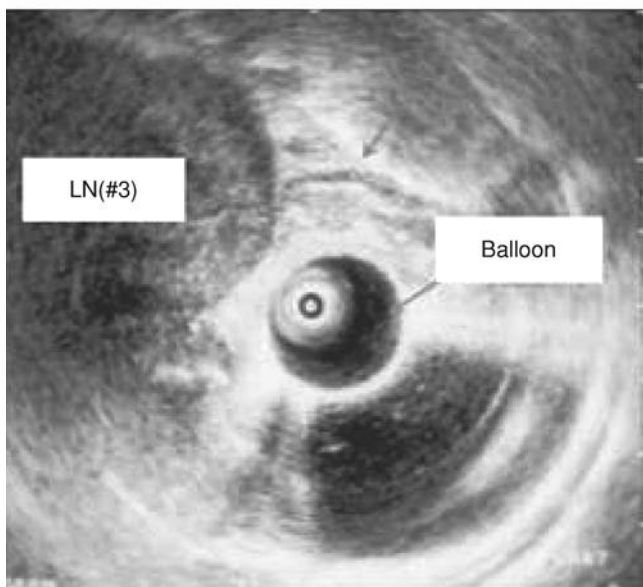
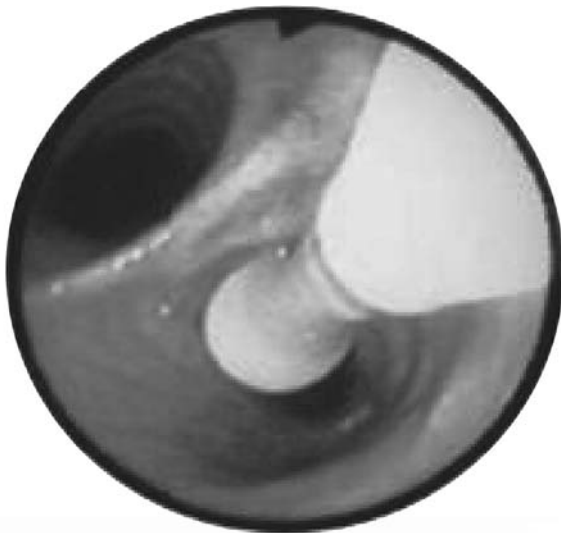

Fig 2. Left: Radial probe endobronchial ultrasound-guided transbronchial needle aspiration. Radial probe is placed in the endobronchial ultrasound (EBUS) bronchoscope working channel but must be removed prior to sampling. Right: the radial probe ultrasound image is 360 degrees to the long axis of the EBUS bronchoscope. LN#3: lymph node. Reproduced with permission of American College of Chest Physicians.⁵

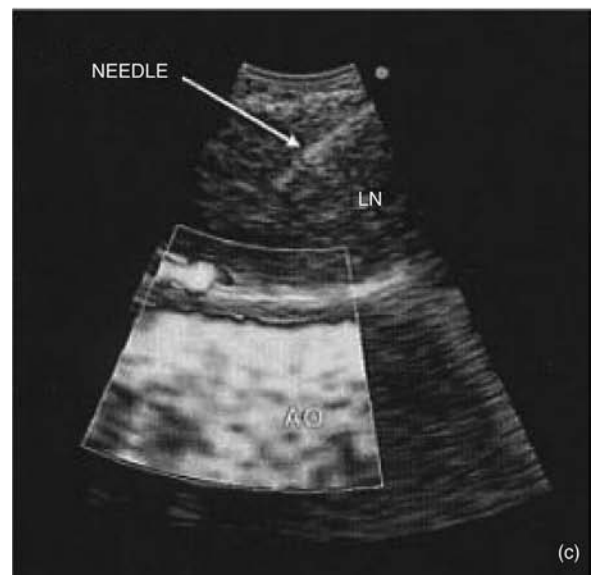
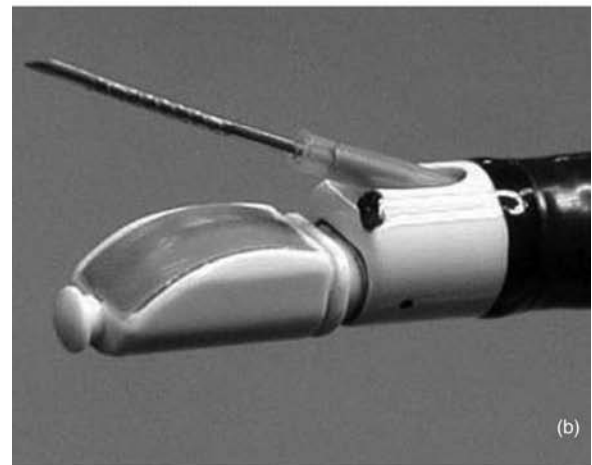
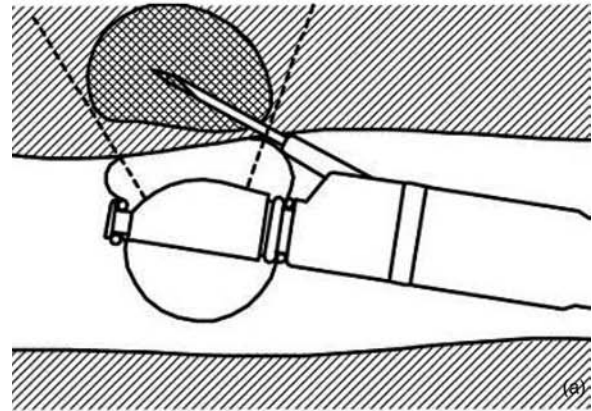


Fig 3. a and b: (Linear probe) endobronchial ultrasound (EBUS)-guided transbronchial needle aspiration has the ultrasound transducer at the distal end of the EBUS bronchoscope. The direct view is 30° to the horizontal. The biopsy needle is placed through the working channel, extending from the end of the bronchoscope at 20° to the direct view. c: The linear ultrasound image (needle in a node) is a 50° slice, in parallel to the long axis of the EBUS bronchoscope (power Doppler flow image shown in bottom half). AO = aorta; LN = lymph node. Reproduced with permission of American College of Chest Physicians.⁵

mediastinoscopy (accessing stations 1–4, 7, Fig 4), anterior mediastinotomy (accessing stations 5–6), EBUS-TBNA and conventional TBNA (both capable of accessing stations 1–4, 7, 10–11).

Endoscopic ultrasound guided-fine needle aspiration (EUS-FNA) can also be combined with EBUS-TBNA³ to sample stations 5, 6, 8 and 9 (the latter two stations normally only accessible by thoracoscopy, Fig 4) to provide access to most areas of the mediastinum (as well as the left adrenal and left lobe of the liver). A combined EBUS-TBNA/EUS-FNA procedure performed by pulmonologists is an attractive longer term objective if available in specialist centres.

EBUS-TBNA compared to other staging techniques

Recent studies have compared EBUS-TBNA to the ‘normal’ radiological mediastinum (CT and PET negative) with supe-

rior sensitivities for EBUS-TBNA and mediastinal metastases in 8% of patients (89–92%).^{6,7} Compared to staging techniques to obtain tissue, EBUS-TBNA has a sensitivity at least as good as mediastinoscopy (the apparent lower sensitivity in the studies reviewed reflects the low prevalence of disease in the mediastinoscopy studies) and is superior to conventional TBNA (Table 1).^{8–12} Moreover, expected results can be achieved with EBUS-TBNA in centres recently establishing a service, the learning curve is short.^{3,13} The negative predictive value of EBUS-TBNA, however, is inferior to mediastinoscopy.

There are few comparative studies of EBUS-TBNA with either technique. The mediastinoscopy studies are conflicting. One high prevalence (89%) study favoured EBUS-TBNA (87% versus 68% sensitivity).¹⁴ Another ongoing low prevalence (39%) study favoured mediastinoscopy on preliminary

Fig 4. Regional lymph node map. Reproduced with permission of American College of Chest Physicians.¹

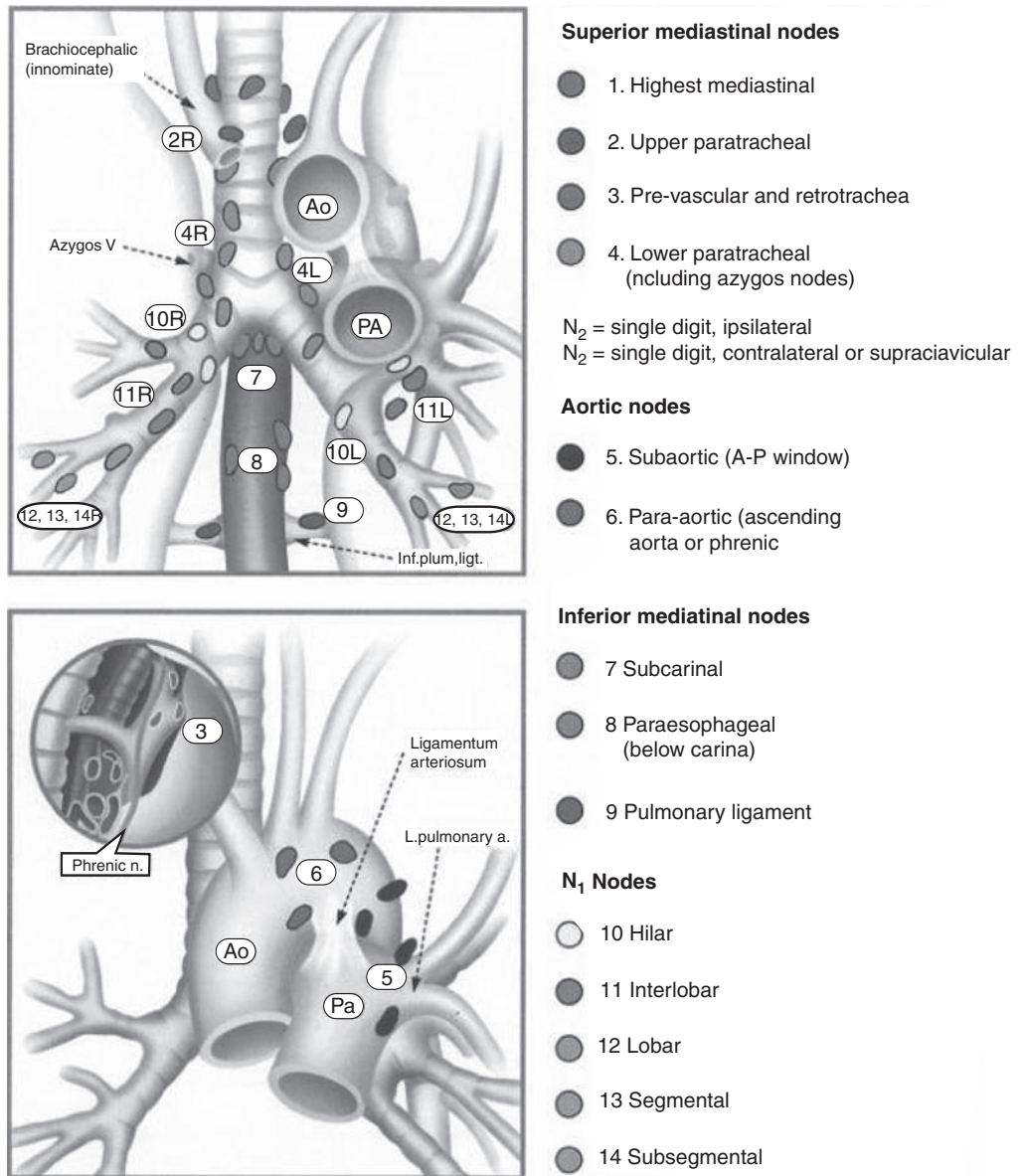


Table 1. Relative diagnostic utility of mediastinal staging investigations (endoscopic ultrasound not included) based on data from systematic reviews and meta-analyses.^{8–12}

| Technique | Sensitivity (%) | Negative predictive value (%) | Prevalence (%) (range) |
|--------------------------|-----------------|-------------------------------|------------------------|
| Cervical mediastinoscopy | 78–81 | 91 | 39 (15–71) |
| Conventional TBNA | 76–78 | 71–72 | 75 (30–100) |
| EBUS-TBNA | 88–93 | 76 | 68 (17–98) |

EBUS-TBNA = endobronchial ultrasound-guided transbronchial needle aspiration; TBNA = transbronchial needle aspiration.

analysis although the final results are still awaited (85% versus 77% sensitivity).¹⁵ The results of a further randomised multi-centre controlled trial (ASTER trial) of EBUS-TBNA and EUS versus mediastinoscopy should be available in 2012.¹⁶ In a comparative trial with conventional TBNA, EBUS-TBNA had a superior yield at all locations (84% versus 58%) except for the most central and accessible nodes to conventional TBNA.¹⁷

Table 2 summarises the key strengths and limitations of EBUS-TBNA compared to the other staging techniques to obtain tissue. EBUS-TBNA is safer, cheaper, quicker (2 hours 24 minutes in one tertiary UK centre versus an average of 30 minutes for EBUS-TBNA by experienced operators), access the hilar nodes¹⁸ and is less invasive than mediastinoscopy (the latter with a 1.4–2.3% risk of important complications, 0.5% risk of major complications, including death).¹⁹

Many centres use EBUS-TBNA to stage discrete or bulky mediastinal nodal disease, reserving mediastinoscopy for situations where radical treatment is intended although EBUS-TBNA may come to have a role in the radiologically ‘normal’ mediastinum. Currently, most centres corroborate negative EBUS-TBNA results with mediastinoscopy in cases where the probability of malignancy is high.²⁰

Mediastinal lymphadenopathy

EBUS-TBNA is commonly the sole method of obtaining tissue for diagnosis in lung cancer due to the lack of an endoluminal lesion (22% in a typical cohort of patients with a high pre-test probability, unpublished observations). It is therefore not uncommon to perform EBUS-TBNA after an initial non-diagnostic flexible bronchoscopy.²¹ In a proportion of cases, non-lung cancer metastases may be detected. EBUS-TBNA can also be used to diagnose lymphoma in certain settings with a sensitivity in 91% in one series using ROSE and flow cytometry.²²

EBUS-TBNA can be used to diagnose benign disease (commonly sarcoidosis and tuberculosis (TB)). Sensitivities of between 78–93% have been reported from various studies in sarcoidosis.²³ For TB, positive culture can be obtained from the lymph node (as well as corroboratory histology) which can be important for resistance profiling.

Therapeutic applications

EBUS can be used therapeutically in selected cases for aspiration of mediastinal and bronchogenic cysts.^{24,25} Radial probe EBUS can also guide or alter interventional bronchoscopic management either by changing stent dimensions, halting tumour debriement near vessels, or abandonment of endoscopic treatment and referral for surgical treatment.²⁶

Assessment of airway wall infiltration and peripheral nodules

Radial probe EBUS is ideal for assessment of airway tumour infiltration in lung cancer which may guide endobronchial therapy. A similar approach has been used to assess airway invasion in oesophageal and thyroid cancer.²⁷ Radial probe EBUS is also used to image peripheral pulmonary nodules for subsequent sampling.

Future applications

Measurements of airway wall thickness have been correlated with asthma severity with radial probe EBUS.²⁸ Linear probe

Table 2. Pros and cons of endobronchial ultrasound-guided transbronchial needle aspiration (EBUS-TBNA) compared to conventional transbronchial needle aspiration (TBNA) and mediastinoscopy.

| Advantages over conventional TBNA | Advantages over mediastinoscopy | Disadvantages |
|--|---|--|
| Direct visualisation of node | Minimally invasive | Inferior negative predictive value to mediastinoscopy |
| Superior sensitivity | Day case, no general anesthesia | Less core tissue than mediastinoscopy |
| Real-time sampling: less risk of major vessel puncture | Access to hilar nodes (also stations 5,6 and 8,9 if use EUS-FNA too, Fig 4) | Training and learning curve |
| More robust EBUS-TBNA needle: larger tissue size | Cost saving: not in theatre, outpatient | Equipment, needle, staff, repair costs: conventional TBNA cheaper |
| Image capture | Shorter procedure time than mediastinoscopy | Staff time and resource: longer procedure than conventional TBNA |
| Better access to remote nodal stations (stations 1–3, 11, Fig 4) | Can be performed by trained respiratory physicians | Vulnerable to tariff-based revenue systems: tariffs slow to evolve |

EBUS also allows visualisation of the central pulmonary vasculature including central pulmonary emboli.²⁹

Training and competency

There is variation in the statements from national bodies on training recommendations and they refer to radial EBUS. The European Respiratory Society/American Thoracic Society interventional pulmonology statement recommends 40 supervised procedures and 25 per year to maintain skills.³⁰ The American College of Chest Physicians guidelines advise a minimum of 50 supervised procedures and five to 10 procedures per year.³¹ Linear EBUS is likely to require 40–50 supervised procedures.¹⁷

Financial issues

The major costs of EBUS are the capital costs of the EBUS bronchoscope and ultrasound processor (£125,000 approximately). There are running costs mainly due to the disposable EBUS needles which are significantly more expensive than conventional TBNA needles (approximately £150–175 versus £40 respectively). Staff costs are higher as the procedure is longer and because an additional flexible bronchoscopy has to sometimes be performed. ROSE is a further cost consideration. Repair costs are also higher than for a conventional flexible bronchoscope.

The principal cost saving of EBUS-TBNA is by avoiding mediastinoscopy and thereby also increasing thoracic surgical capacity. Recent UK cost analyses calculated an EBUS-TBNA service would save the local NHS economy £32,631 to £107,824 per year (including capital costs), save the local primary care trusts £58,750 to £113,968 per annum, but would cost the NHS trust an additional £6,144 to £26,119 per annum.^{13,32}

For healthcare systems operating tariff-based revenue, two other factors contribute to further losses. Firstly, until recently in the UK there was no specific EBUS-TBNA tariff and it was not sufficiently distinguished from a standard flexible bronchoscopy tariff despite the increased cost, complexity and time of EBUS-TBNA.^{33,34} Secondly, aberrant coding is well described for interventional procedures and results in extra losses.^{13,35}

Summary

EBUS represents a technological advance in bronchoscopy. The primary indications for EBUS-TBNA are staging lung cancer and the diagnosis of malignant and benign mediastinal lymphadenopathy. It may in time also replace mediastinoscopy for evaluating the normal radiological mediastinum. Currently, the negative predictive value of EBUS-TBNA is still inferior to mediastinoscopy.

EBUS requires extra training beyond conventional bronchoscopy. The capital and running costs need to be considered before setting up a service although it will reduce costs by avoiding mediastinoscopies. In the future, EBUS will become more available and specialised centres may seek to develop a combined EBUS/EUS service giving access to the entire mediastinum. With time, the potential applications of EBUS are likely to increase.

References

- 1 Mountain CF, Dresler CM. Regional lymph node classification for lung cancer staging. *Chest* 1997;111:1718–23.
- 2 Silvestri GA, Gould MK, Margolis ML *et al.* Noninvasive staging of non-small cell lung cancer: ACCP evidenced-based clinical practice guidelines (2nd edn). *Chest* 2007;132(3 Suppl):178S–201S.
- 3 Rintoul RC, Skwarski KM, Murchison JT *et al.* Endobronchial and endoscopic ultrasound-guided real-time fine-needle aspiration for mediastinal staging. *Eur Respir J* 2005;25:416–21.
- 4 Medford AR, Bennett JA, Free CM, Agrawal S. Endobronchial ultrasound guided transbronchial needle aspiration. *Postgrad Med J* 2010; 86:106–15.
- 5 Sheski FD, Mathur PN. Endobronchial ultrasound. *Chest* 2008;133:264–70.
- 6 Herth FJ, Eberhardt R, Krasnik M, Ernst A. Endobronchial ultrasound-guided transbronchial needle aspiration of lymph nodes in the radiologically and positron emission tomography-normal mediastinum in patients with lung cancer. *Chest* 2008;133:887–91.
- 7 Yasufuku K, Nakajima T, Motoori K *et al.* Comparison of endobronchial ultrasound, positron emission tomography, and CT for lymph node staging of lung cancer. *Chest* 2006;130:710–8.
- 8 Toloza EM, Harpole L, Detterbeck F, McCrory DC. Invasive staging of non-small cell lung cancer: a review of the current evidence. *Chest* 2003;123(1 Suppl):157S–166S.
- 9 Detterbeck FC, Jantz MA, Wallace M, Vansteenkiste J, Silvestri GA. Invasive mediastinal staging of lung cancer: ACCP evidence-based clinical practice guidelines (2nd edn). *Chest* 2007;132(3 Suppl):202S–220S.
- 10 Gu P, Zhao YZ, Jiang LY *et al.* Endobronchial ultrasound-guided transbronchial needle aspiration for staging of lung cancer: A systematic review and meta-analysis. *Eur J Cancer* 2009;45: 1389–96.
- 11 Adams K, Shah P, Edmonds L, Lim E. Endobronchial ultrasound and transbronchial needle aspiration biopsy for mediastinal staging in patients with lung cancer: systematic review and meta-analysis. *Thorax* 2009;64:757–62.
- 12 Varela-Lema L, Fernandez-Villar A, Ruano-Ravina A. Effectiveness and safety of endobronchial ultrasound-transbronchial needle aspiration: a systematic review. *Eur Respir J* 2009;33:1156–64.
- 13 Medford AR, Agrawal S, Free CM, Bennett JA. A performance and theoretical cost analysis of endobronchial ultrasound-guided transbronchial needle aspiration in a UK tertiary respiratory centre. *QJM* 2009;102:859–64.
- 14 Ernst A, Anantham D, Eberhardt R, Krasnik M, Herth FJ. Diagnosis of mediastinal adenopathy-real-time endobronchial ultrasound guided needle aspiration versus mediastinoscopy. *J Thorac Oncol* 2008;3:577–82.
- 15 Yasufuku K, Quadri M, dePerrot M *et al.* A prospective controlled trial of endobronchial ultrasound guided transbronchial needle aspiration compared to mediastinoscopy for mediastinal lymph node staging of lung cancer. *Western Thoracic Surgical Association 33rd Annual Meeting (abstract)* 2007.
- 16 Assessment of Surgical sTaging versus Endobronchial and endoscopic ultrasound in lung cancer: a Randomised controlled trial (ASTER), www.nccta.org/project/1603.asp
- 17 Herth F, Becker HD, Ernst A. Conventional vs endobronchial ultrasound-guided transbronchial needle aspiration: a randomized trial. *Chest* 2004;125:322–5.
- 18 Ernst A, Eberhardt R, Krasnik M, Herth FJ. Efficacy of endobronchial ultrasound-guided transbronchial needle aspiration of hilar lymph nodes for diagnosing and staging cancer. *J Thorac Oncol* 2009;4:947–50.
- 19 Medford ARL, Agrawal S, Free CM, Bennett JA. Mediastinal staging procedures in lung cancer: EBUS, TBNA and mediastinoscopy. *Curr Opin Pulm Med* 2009;15:334–42.

- 20 Rintoul RC, Tournoy KG, El Daly H *et al.* EBUS-TBNA for the clarification of PET positive intra-thoracic lymph nodes—an international multi-centre experience. *J Thorac Oncol* 2009;4:44–8.
- 21 Tournoy KG, Rintoul RC, van Meerbeeck JP *et al.* EBUS-TBNA for the diagnosis of central parenchymal lung lesions not visible at routine bronchoscopy. *Lung Cancer* 2009;63:45–9.
- 22 Kennedy MP, Jimenez CA, Bruzzi JF *et al.* Endobronchial ultrasound-guided transbronchial needle aspiration in the diagnosis of lymphoma. *Thorax* 2008;63:360–5.
- 23 Medford AR, Agrawal S, Bennett JA. Sarcoidosis: EBUS-TBNA technique to enable diagnosis. *BMJ* 2009;339:766–7.
- 24 Nakajima T, Yasufuku K, Shibuya K, Fujisawa T. Endobronchial ultrasound-guided transbronchial needle aspiration for the treatment of central airway stenosis caused by a mediastinal cyst. *Eur J Cardiothorac Surg* 2007;32:538–40.
- 25 Galluccio G, Lucantoni G. Mediastinal bronchogenic cyst's recurrence treated with EBUS-FNA with a long-term follow-up. *Eur J Cardiothorac Surg* 2006;29:627–9.
- 26 Herth F, Becker HD, LoCicero J, 3rd, Ernst A. Endobronchial ultrasound in therapeutic bronchoscopy. *Eur Respir J* 2002;20:118–21.
- 27 Wakamatsu T, Tsushima K, Yasuo M *et al.* Usefulness of preoperative endobronchial ultrasound for airway invasion around the trachea: esophageal cancer and thyroid cancer. *Respiration* 2006;73:651–7.
- 28 Soja J, Grzanka P, Sladek K *et al.* The use of endobronchial ultrasonography in assessment of bronchial wall remodelling in patients with asthma. *Chest* 2009;136:797–804.
- 29 Aumiller J, Herth FJ, Krasnik M, Eberhardt R. Endobronchial ultrasound for detecting central pulmonary emboli: a pilot study. *Respiration* 2009;77:298–302.
- 30 Bolliger CT, Mathur PN, Beams JF *et al.* ERS/ATS statement on interventional pulmonology. European Respiratory Society/American Thoracic Society. *Eur Respir J* 2002;19:356–73.
- 31 Ernst A, Silvestri GA, Johnstone D. Interventional pulmonary procedures: Guidelines from the American College of Chest Physicians. *Chest* 2003;123:1693–717.
- 32 Callister ME, Gill A, Allott W, Plant PK. Endobronchial ultrasound guided transbronchial needle aspiration of mediastinal lymph nodes for lung cancer staging: a projected cost analysis. *Thorax* 2008;63:384.
- 33 Medford AR. Endobronchial ultrasound-transbronchial needle aspiration and lung cancer. *J R Coll Physicians Edinb* 2009;39:91.
- 34 Manaker S, Ernst A, Marcus L. Affording endobronchial ultrasound. *Chest* 2008;133:842–3.
- 35 Medford AR, Agrawal S, Free CM, Bennett JA. Retrospective analysis of Healthcare Resource Group coding allocation for local anaesthetic video-assisted 'medical' thoracoscopy in a UK tertiary respiratory centre. *QJM* 2009;102:329–33.

**Address for correspondence: Dr ARL Medford,
North Bristol Lung Centre, Southmead Hospital,
Westbury-on-Trym, Bristol BS10 5NB.
Email: andrewmedford@hotmail.com**

Ordering online

All new titles, plus a selection of our more popular publications, can be ordered online at <http://bookshop.rcplondon.ac.uk/>

A full range of College memorabilia can also be ordered at <http://bookshop.rcplondon.ac.uk/memorabilia.aspx>

Online ordering offers a quick and secure way of purchasing books and memorabilia from the RCP. Look out for the blue 'Buy Now' button. 10% discount on all RCP publications to fellows and members.



**Royal College
of Physicians**
Setting higher medical standards