



# Surgical Delay of the Nipple–Areolar Complex in High-risk Nipple-sparing Mastectomy Reconstruction

Maryann E. Martinovic, MD\*  
James V. Pellicane, MD,  
FACS†  
Nadia P. Blanchet, MD\*‡

**Summary:** As nipple-sparing mastectomy gains increasing popularity, minimizing the risk of nipple necrosis continues to be of critical importance to patients and surgeons. Patients with large or ptotic breasts, scars from previous cosmetic and/or oncologic breast surgery, or previous irradiation have often been denied nipple-sparing mastectomy (NSM) because of increased risk of nipple necrosis. A variety of interventions have been suggested to minimize the ischemic insult to the nipple–areolar complex (NAC). This article presents our experience in 26 high-risk patients with surgical delay of the NAC. (*Plast Reconstr Surg Glob Open* 2016;4:e760; doi: 10.1097/GOX.0000000000000716; Published online 28 June 2016.)

The NAC is the geometric and aesthetic focal point of the breast, and its presence has been linked to increased patient satisfaction in the reconstructive population.<sup>1–3</sup> The oncologic safety of NSM in specific circumstances has been established and expanded in recent years.<sup>4</sup> It is natural that its popularity continues to grow as women and their surgeons strive to obtain optimal aesthetic outcomes. In NSM, more of the inherently ischemic mastectomy skin envelope is preserved; therefore, a common and dreaded complication is necrosis of the NAC. The incidence of nipple necrosis in the literature varies from as high as 48% to as low as 4.4%.<sup>4–6</sup>

Beyond oncologic criteria, anatomic considerations have played a large role in patient selection. In the past, women with extensive breast scars from cosmetic and oncologic conservation procedures or concomitant radiation, as well as large or ptotic breasts, have often been discouraged from undergoing an NSM procedure because of ischemic considerations.<sup>3,7</sup>

More women are undergoing NSM today,<sup>8,9</sup> and a number of solutions have been proposed by various authors to minimize the risk of NAC necrosis. Spear et al<sup>10</sup> described a staged approach for patients with significant ptosis or macromastia in which a mastopexy or reduction was performed at least 4 weeks (average, 3.4 months) before the mastectomy. Folli et al<sup>11</sup> reported successful immediate reconstruction for ptotic breasts using a Wise pattern and bipedicle dermal flap to preserve the NAC. Other procedures include free nipple grafting at the time of NSM.<sup>12</sup> Some advocate intraoperative injection of indocyanine green and laser angiography to assess areas of jeopardized perfusion, so that ischemic tissue may be excised.<sup>13,14</sup> Zenn<sup>15</sup> described a staged immediate reconstruction for women with previous breast surgery, irradiation, or large-volume breasts in which

From the \*Division of Plastic Surgery, Virginia Commonwealth University Health System, Richmond, Va.; †Bon Secours Cancer Institute, Richmond, Va.; ‡Chippenham Johnston Willis Hospital, Richmond, Va.  
Received for publication February 18, 2016; accepted March 21, 2016.

Presented at the American Society of Plastic Surgeons Resident Conference, October 17, 2015, Boston, Mass.

Copyright © 2016 The Authors. Published by Wolters Kluwer Health, Inc. on behalf of The American Society of Plastic Surgeons. All rights reserved. This is an open-access article distributed under the terms of the Creative Commons Attribution-Non Commercial-No Derivatives License 4.0 (CCBY-NC-ND), where it is permissible to download and share the work provided it is properly cited. The work cannot be changed in any way or used commercially.

DOI: 10.1097/GOX.0000000000000716

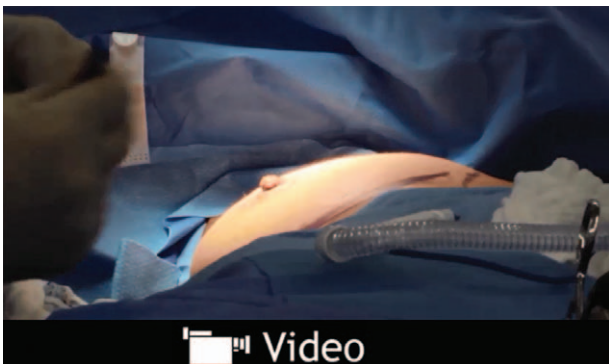
**Disclosure:** The authors have no financial interest to declare in relation to the content of this article. The Article Processing Charge was paid for by the authors.

Supplemental digital content is available for this article. Clickable URL citations appear in the text.

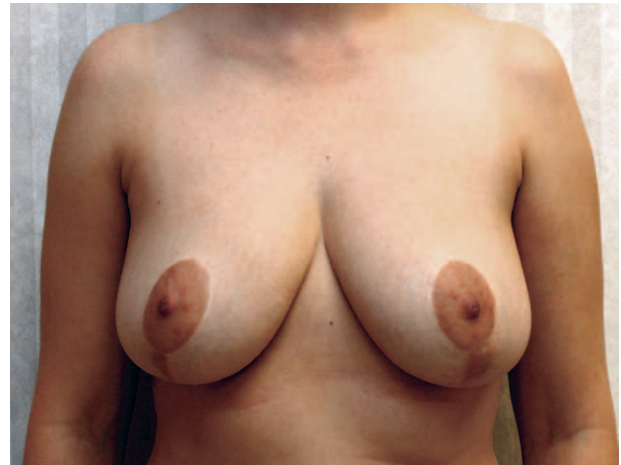patients underwent an NSM and then returned 2 weeks later to complete their reconstruction.

Surgical delay of the NAC was introduced in the Surgical Oncology literature in 2012. As described by Jensen et al,<sup>16</sup> it consists of radially undermining 5 cm from the nipple in a circumferential fashion using sharp dissection to dissect the skin and subcutaneous tissue from the underlying breast parenchyma. This was performed on average 21 days before NSM in 30 patients with no postoperative nipple loss noted. This intervention gained attention in the media as the “Angelina Jolie procedure.”<sup>17,18</sup> Recently, Martinez et al<sup>19</sup> described their experience with placement of a silicone sheet at the time of nipple delay in 20 patients. We would like to present our results with original technique described by Jensen et al<sup>16</sup> in high-risk NSM patients.

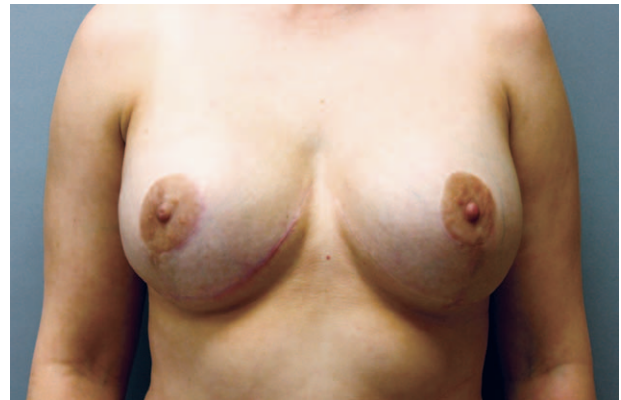A surgical delay was performed by 1 of the 5 oncologic surgeons on 51 breasts in 26 high-risk patients under sedation if no sentinel lymph node biopsy was indicated or general anesthesia. On average, the delay was performed 16.9 days before therapeutic or prophylactic mastectomy (**See video, Supplemental Digital Content 1**, which displays a surgical delay of the NAC. This video is available in the “Related Videos” section of the full-text article on PRSGlobalOpen.com or available at <http://links.lww.com/PRSGO/A223>). Patients were identified as high risk for nipple necrosis based on previous Wise pattern mastopexy or reduction (3), augmentation (1), or oncologic surgery (12, including 4 irradiated patients), significant ptosis (sternal notch to nipple distance greater than 26 cm), and/or macromastia (10) (Figs. 1 and 2). The access point for the delay was based on proposed future mastectomy incision. For patients with previous breast surgery, an incision was often made through



**Video Graphic 1.** See Supplemental Digital Content 1, which displays a surgical delay of the nipple-areolar complex. This video is available in the “Related Videos” section of the full-text article on PRSGlobalOpen.com or available at <http://links.lww.com/PRSGO/A223>.

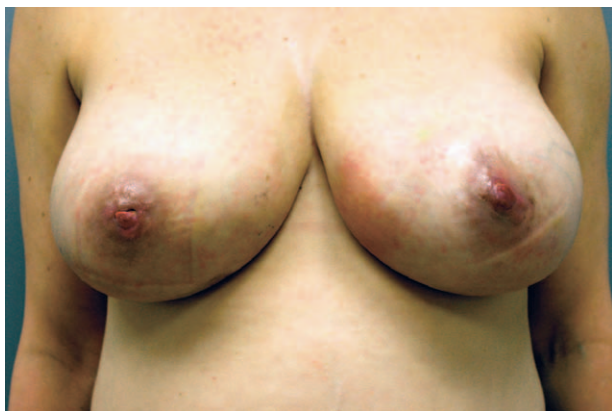

**Fig. 1.** A 43-year-old patient who was BRCA1 positive with previous bilateral breast reduction seeking prophylactic mastectomy.

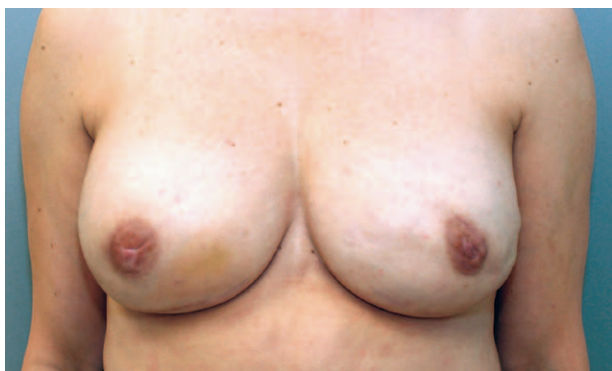

**Fig. 2.** Patient underwent a delay 15 days before nipple-sparing mastectomies and subsequent second stage reconstruction after 3 months.

an existing scar, such as the vertical limb of a Wise pattern mastopexy or reduction or lateral extension of a lumpectomy scar. Patients without existing breast scars but an extensive skin envelope had a variety of incisions: inframammary fold (IMF), lateral radial, and superolateral or inferolateral to the NAC to allow for tailoring of skin excess. An IMF incision was preferred when feasible to allow for the most concealed scar. Our patient population had 33 breast incisions placed at the IMF, 4 through an existing vertical limb, 8 lateral radial, 3 superolateral, and 3 inferolateral to the NAC. In addition, in all but 1 breast, efforts were made to undermine any previous lumpectomy scars. A retroareolar biopsy and/or sentinel lymph node biopsy was performed if indicated at the time of the delay procedure. Immediate breast reconstruction with placement of a tissue expander (25 patients) or direct implant (1 patient) and cadaveric acellu-



**Fig. 3.** A 45-year-old patient with macromastia and new diagnosis of right breast cancer who desired nipple-sparing mastectomies underwent a surgical delay of the NAC via IMF incisions. She developed a hematoma, which required drainage, and subsequently had superficial nipple epidermolysis.



**Fig. 4.** Patient had no significant nipple loss and negligible depigmentation. She successfully completed her NSM and second stage reconstruction.

lar dermal matrix was performed by a single plastic surgeon after mastectomy.

All patients underwent nipple-sparing mastectomies and immediate reconstruction after their delay procedures with no significant nipple loss. Six patients had minor superficial nipple epidermolysis without aesthetic sequelae. One patient experienced a hematoma after the delay, which required drainage. She went on to have the most significant epidermolysis of the series but no appreciable nipple loss and negligible depigmentation (Figs. 3 and 4). One irradiated patient had breakdown of a previous lumpectomy scar, which had not been undermined during her delay 1 month post NSM, resulting in cellulitis, periprosthetic infection, and subsequent expander explantation.

The obvious aesthetic advantages of NSM are offset by increased risk related to more ischemic mastectomy flaps. We would like to illustrate that the technique described by Jensen et al<sup>16</sup> of nipple delay is a powerful

tool to make NSM a viable option in patients who would not otherwise be considered candidates for NSM. The delay procedure is of low risk and includes subareolar tissue sampling to assure oncologic feasibility and simultaneous axillary node procedures. In our series, the delay procedure was performed by the oncologic surgeon, but theoretically, it could be performed by the plastic surgeon as well. We have found that placement of silicone sheeting is unnecessary. Our results suggest the importance of undermining previous lumpectomy scars at the time of the delay especially in irradiated patients. The advantages of a nipple delay over other interventions are simplicity, potentially shorter delay to definitive mastectomy, and less ischemic insult to the skin envelope. The nipple delay procedure improves mastectomy flap perfusion and reduces the risk of nipple necrosis in high-risk patients who may not have previously been considered candidates for NSM.

**Nadia P. Blanchet, MD**

9210 Forest Hill Avenue  
Richmond, VA 23235

E-mail: Nadia@nadiablanchet.com

#### ACKNOWLEDGMENTS

*The authors would like to thank Jamie Parkerson for her assistance with creating the video.*

#### REFERENCES

1. Djohan R, Gage E, Gatherwright J, et al. Patient satisfaction following nipple-sparing mastectomy and immediate breast reconstruction: an 8-year outcome study. *Plast Reconstr Surg.* 2010;125:818–829.
2. Wellisch DK, Schain WS, Noone RB, et al. The psychological contribution of nipple addition in breast reconstruction. *Plast Reconstr Surg.* 1987;80:699–704.
3. Salgarello M, Visconti G, Barone-Adesi L. Nipple-sparing mastectomy with immediate implant reconstruction: cosmetic outcomes and technical refinements. *Plast Reconstr Surg.* 2010;126:1460–1471.
4. Mallon P, Feron JG, Couturaud B, et al. The role of nipple-sparing mastectomy in breast cancer: a comprehensive review of the literature. *Plast Reconstr Surg.* 2013;131:969–984.
5. Endara M, Chen D, Verma K, et al. Breast reconstruction following nipple-sparing mastectomy: a systematic review of the literature with pooled analysis. *Plast Reconstr Surg.* 2013;132:1043–1054.
6. Rusby JE, Smith BL, Gui GP. Nipple-sparing mastectomy. *Br J Surg.* 2010;97:305–316.
7. Dent BL, Cordeiro CN, Small K, et al. Nipple-sparing mastectomy via an inframammary fold incision with implant-based reconstruction in patients with prior cosmetic breast surgery. *Aesthet Surg J.* 2015;35:548–557.
8. Frederick MJ, Lin AM, Neuman R, et al. Nipple-sparing mastectomy in patients with previous breast surgery: comparative analysis of 775 immediate breast reconstructions. *Plast Reconstr Surg.* 2015;135:954e–962e.
9. Coopey SB, Smith BL. The nipple is just another margin. *Ann Surg Oncol.* 2015;22:3764–3766.

10. Spear SL, Rottman SJ, Seiboth LA, et al. Breast reconstruction using a staged nipple-sparing mastectomy following mastopexy or reduction. *Plast Reconstr Surg.* 2012;129:572–581.
11. Folli S, Mingozi M, Curcio A, et al. Nipple-sparing mastectomy: an alternative technique for large ptotic breasts. *J Am Coll Surg.* 2015;220:e65–e69.
12. Doren EL, Van Eldik Kuykendall L, Lopez JJ, et al. Free nipple grafting: an alternative for patients ineligible for nipple-sparing mastectomy? *Ann Plast Surg.* 2014;72:S112–S115.
13. Alperovich M, Tanna N, Samra F, et al. Nipple-sparing mastectomy in patients with a history of reduction mammoplasty or mastopexy: how safe is it? *Plast Reconstr Surg.* 2013;131:962–967.
14. Rodriguez-Feliz J, Codner MA. Embrace the change: incorporating single-stage implant breast reconstruction into your practice. *Plast Reconstr Surg.* 2015;136:221–231.
15. Zenn MR. Staged immediate breast reconstruction. *Plast Reconstr Surg.* 2015;135:976–979.
16. Jensen JA, Lin JH, Kapoor N, et al. Surgical delay of the nipple-areolar complex: a powerful technique to maximize nipple viability following nipple-sparing mastectomy. *Ann Surg Oncol.* 2012;19:3171–3176.
17. Jolie A. *My Medical Choice.* New York, N.Y.: The New York Times; 2013.
18. Cowles C. *Angelina Jolie’s “Nipple Delay” Procedure, Explained.* New York, N.Y.: NYMag; 2013.
19. Martinez CA, Reis SM, Sato EA, et al. The nipple-areola preserving mastectomy: a multistage procedure aiming to improve reconstructive outcomes following mastectomy. *Plast Reconstr Surg Glob Open* 2015;3:e538.