

CORRESPONDENCE

Association between mast cells and myelomonocytes

The article by Horny *et al* regarding the relation between monoclonal antibody KP-1 and human mast cells is of particular interest in that it provides evidence for the derivation of mast cells. The authors indicate that mast cells are closely associated with myelomonocytes because the monoclonal antibody KP-1 shows strong immunoreactivity by light microscopy.

We have recently seen a 59 year old woman with acute myelocytic leukaemia (FAB, M2) who adds further evidence. On complete remission after chemotherapy, mast cells had appeared in the bone marrow and were easily visible on light microscopy. Interestingly, the mast cells disappeared a few weeks before her disease relapsed. The leukaemic cells were strongly positive for peroxidase, Sudan black B, naphthol-AS-D chloroacetate esterase and acid phosphatase stains and showed the 8:21 chromosomal translocation. Auer rods were also observed in some of the blast cells (fig 1A). At diagnosis and relapse no abnormalities in erythroid and megakaryocytic lineages were observed by light or electron microscopy.

Bone marrow particles taken during complete remission were embedded in Lowicryl K4M (Polysciences). Almost all the mast cell granules (fig 1B) were strongly stained (fig 1C) by polyclonal antibody against lactoferrin (Cappel) and weakly stained (fig 1D) by polyclonal antibody against lysozyme (Dakopatts) using the immunogold staining method.²

Lactoferrin and lysozyme exist in myelomonocytes.^{3,4} To prove, morphologically, that mast cells contain both lactoferrin and lysozyme, appropriate monoclonal antibodies must be used. Demonstration of m-RNA of lactoferrin and lysozyme in mast cells will indicate whether those cells synthesise such substances. However, taking into account that KP-1 (CD68) also stains myeloperoxidase positive granules of normal neutrophils and monocytes observed by electron microscopy (unpublished observation) and that the increase and decrease in mast cells in this case seemed to be related to myelocytic leukaemia, our findings support the proposal that mast cells closely relate to myelomonocytes in man.

NAGAHITO SAITO
N TAKEMORI
N TACHIBANA
K HIRAI
R ONODERA

433-40, Sjou-3chome, Fujino, Minami-ku,
Sapporo, Hokkaido, Japan

- 1 Horny H-P, Schaumburg-Lever G, Bolz S, Geerts ML, Kaiserling E. Use of monoclonal antibody KP1 for identifying normal and neoplastic human mast cells. *J Clin Pathol* 1990;43:719-22.
- 2 Saito N. Correlation between intracellular and extracellular lysozyme in acute (myelo-) monocytic leukemia. *Leuk Lymph* 1990; 2:347-50.
- 3 Cramer E, Pryzwansky KB, Villeval JL, Testa U, Breton-Gorius J. Ultra structural localization of lactoferrin and myeloperoxidase in human neutrophils by immunogold. *Blood* 1985;65:423-32.
- 4 Saito N, Takemori N, Tachibana N, Hayashishita N, Sakurada K, Miyazaki T. Localization of lysozyme in normal human blood cells: An ultrastructural immunogold study. *J Jpn Soc Res* 1987;27:307-15.

Drs Horny, Ruck, and Kaiserling comment:

The findings of Saito *et al* are of some interest in that they provide further evidence that human tissue mast cells are very closely related to the myelomonocytic system. However, it should be emphasised that the immunoreactivity of mast cells with the monoclonal antibody KP1 (CD68) is only one of the many strong arguments favouring the hypothesis that these cells derive from the bone marrow. We recently showed that mast cells also react with the very specific macrophage associated monoclonal antibody KiM1p.¹ Non-specific binding of KiM1p and KP1 to mast cells by ionic linkage could be ruled out according to previously published methods.² Immune accessory cells are also recognised by these two antibodies: KiM1p reacts with a few interdigitating reticulum cells and KP1 with follicular dendritic cells.¹ Moreover, the frequent coexistence of malignant mast cells and myelodysplastic/myeloproliferative disorders also strongly argues in favour of a close relation between mast cells and the myelomonocytic system.³ The definitive demonstration that human mast cells are derivatives of CD34 positive bone marrow progenitor cells was recently published by Kirshenbaum *et al*.⁴

Saito *et al* noted an increase in marrow mast cells after complete remission in a case of acute myeloid leukaemia had been achieved by chemotherapy. We recently observed a similar and very intriguing case in a 39 year old man in whom chemotherapy resulted in complete remission of acute myeloid leukaemia (FAB M2). Because prolonged bone marrow aplasia had developed, treatment with G-CSF was started and there was a subsequent increase in neutrophilic granulocytes. Nevertheless, the patient died of generalised septicemia. A post mortem bone marrow smear showed a diffuse increase in

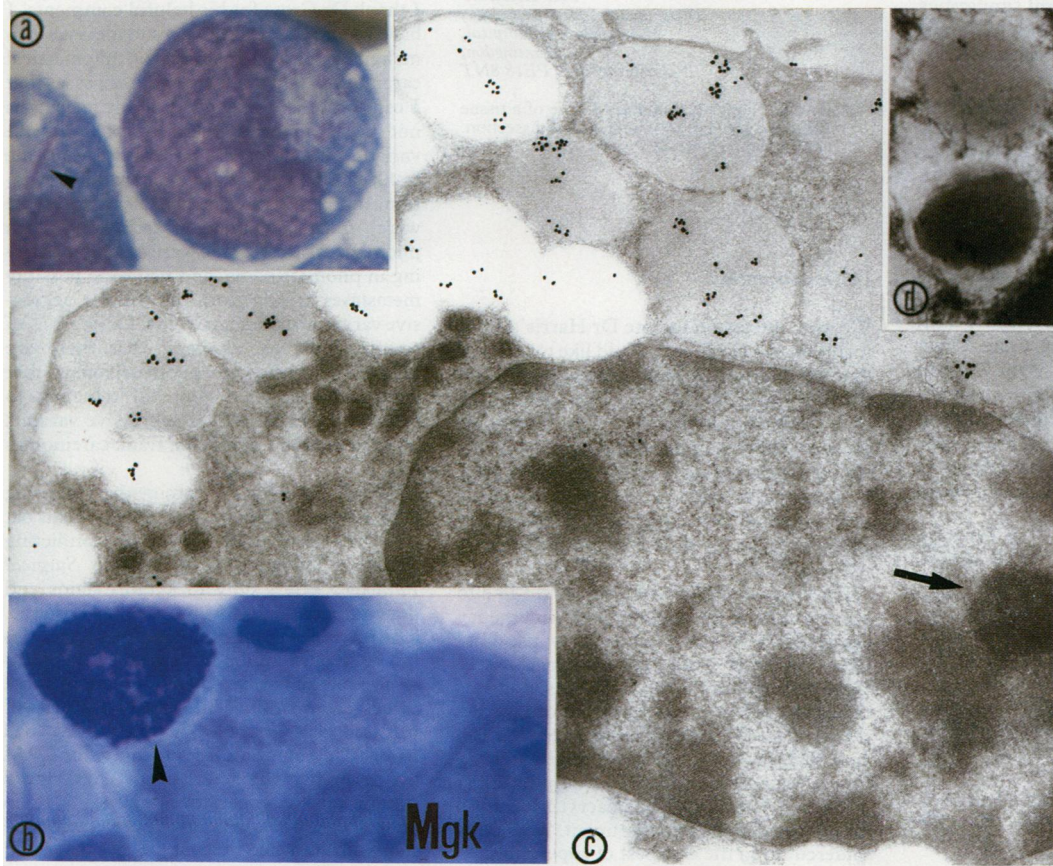


Figure 1A Leukaemia cells in bone marrow. Auer rod is visible (arrowhead). (May-Grünwald-Giemsa staining).

Figure 1B Mast cell (arrowhead) of bone marrow during complete remission. The granules of mast cell show metachromasia. (Mgk = megakaryocyte) (toluidine blue staining, thin section from a bloc by Lowicryl K4M).

Figure 1C Staining by antibody against human lactoferrin. The granules are strongly positive. A nucleolus (arrowhead) can be seen.

Figure 1D The granules are weakly stained by antibody against human lysozyme.

slightly pleomorphic mast cells, which made up 5% of all nucleated cells. However, focal mast cell infiltration was not found histologically, and malignant mastocytosis was thought unlikely. This reactive increase in mast cells was probably caused by the application of a particular haemopoietic growth factor (G-CSF) which would also strongly suggest a very close relation between mast cells and the myelomonocytic system.

- 1 Bolz S, Ruck P, Schaumburg-Lever G, Horny H-P, Radzun H-J, Kaiserling E. Use of monoclonal antibodies KP1 (CD68) and KiM1p for identification of cells of the mononuclear phagocyte system: immunohistological and immunoelectronmicroscopic findings (German). *Verh Dtsch Ges Pathol* (in press).
- 2 Ruck P, Horny H-P, Kaiserling E. Immunoreactivity of human tissue mast cells: nonspecific binding of primary antibodies against regulatory peptides by ionic linkage. *J Histochem Cytochem* 1990;38:859-67.
- 3 Horny H-P, Ruck M, Wehrmann M, Kaiserling E. Blood findings in generalized mastocytosis: evidence of frequent simultaneous occurrence of myeloproliferative disorders. *Br J Haematol* 1990;76:186-93.
- 4 Kirshenbaum AS, Kessler SW, Goff JP, Metcalfe DD. Demonstration of the origin of human mast cells from CD34+ bone marrow progenitor cells. *J Immunol* 1991;146:1410-15.

HPV genotypes in cervical neoplasia in South Africa

Our recent publication on the prevalence of human papillomavirus (HPV) DNA in cervical intraepithelial neoplasm (CIN) using non-isotopic *in situ* hybridisation (NISH) in archival biopsy material from South Africa stated that there were no previously published data from that country.¹ We have now become aware of a study from Cape Town on the prevalence of HPV DNA in CIN 3 using Southern analysis for HPV types 6, 11, 16, 18, 31, 33 and 35.² There are several similarities in these independent studies using different molecular techniques (but the same probes) in patients from South Africa. Comparing our CIN 3 group from Durban with that from Cape Town, it is evident that there is a low prevalence of HPV 16 in Durban 15/55 (27%) and Cape Town 16/98 (16%) compared with Oxford patients 24/49 (49%). Furthermore, none of these groups showed any evidence of HPV 6, 11, or 31 in CIN cases. Excluding the unclassified group in Williamson's series,² the prevalence of HPV 16, 18, and 31 in CIN 3 is less than 50% in Durban and Cape Town. The unclassified HPV's in the Cape Town series (36%), along with 59% of the Durban biopsy specimens of CIN 3 (with morphological evidence of wart virus infection) that did not contain HPV DNA by NISH,¹ confirms our suspicion of a high prevalence of minor or unclassified HPV types in South Africa.

K COOPER
JO'D McGEE
University of Oxford,
Nuffield Department of
Pathology and Bacteriology,
John Radcliffe Hospital,
Oxford OX3 9DU

- 1 Cooper K, Herrington CS, Graham AK, Evans MF, McGee JO'D. *In situ* HPV genotyping of cervical intraepithelial neoplasia in South Africa and British patients: Evidence for putative HPV integration. *J Clin Pathol* 1991;44:400-5.
- 2 Williamson A-L, Dehaeck CMC, Soeters R. Typing of human papillomavirus in cervical intraepithelial neoplasia grade 3 biopsies from Cape Town. *J Med Virol* 1989;28:146-9.

Reconstruction of fetuses after dissection

The paper by Gau, Napier, and Bhundia describes the use of the tissue adhesive Histoacryl Blue for the reconstruction of fetuses after dissection.¹ In Huntingdon we use a similar technique, but with ordinary Superglue (cyanoacrylate), which produces a very acceptable cosmetic result. Superglue is also very useful for closing small lacerations, particularly on the face or hands, which may be present in deaths associated with trauma, and also accidental cuts on visible areas of the neck which may occasionally occur in the course of necropsy. Persistent leakage of blood and fluid after removal of the calf muscles has also been remedied by running a line of superglue over the sutures.

The use of Superglue in this way is by no means new, in fact it is used by some anatomy departments to repair small nerves and vessels on demonstration specimens, which sometimes become severed by heavy handed prosectors or enthusiastic students. Superglue can be used by pathologists to reconstruct organs after dissection, for use as teaching specimens or "pots". I understand that some undertakers even use Superglue on the eyelids of cadavers if they will not stay closed.

Although not subjected to such a rigorous study as that by Gau *et al*, in my experience ordinary Superglue produces good tissue adhesion, as anyone who has ever stuck their fingers together while attempting to repair some household ornament, or child's toy, will testify. The glue line has a slightly firmer consistency than the adjacent tissue, but the glue is colourless. Any excess dries to a crust, presumably the coagulum described in Gau's paper, most of which can be removed with forceps or a scalpel blade. Superglue is much cheaper and more readily available than the specialised surgical adhesive described.

MD HARRIS
Department of Histopathology,
Hinchingsbrooke Hospital,
Huntingdon,
Cambridgeshire PE18 8NT

- 1 Gau GS, Napier K, Bhundia J. Use of a tissue adhesive to repair fetal bodies after dissection. *J Clin Pathol* 1991;44:759-60.

Dr Gau comments:

We were interested to note Dr Harris's comments on our paper and would like to indicate that we realise that many people have used modern "over the counter" superglues in their pathological practice. The reason we avoided this type of Superglue was the warning on the packaging that this glue should not be used where there is "wet service". As it was essential that these repairs remained aesthetic for many weeks we felt it unwise to use such glue.

On the question of cost, we would like to point out that all accident and emergency departments in this country now use Histoacryl Blue for the repair of lacerations. Generally little of the total glue is used and, as the open capsule is no longer deemed sterile, the remnant is frequently discarded. We feel sure that an encouraging word to sister-in-charge would easily ensure an ample supply of opened "unsterile" Histoacryl Blue at no cost to the pathology department. This must undercut even the cheapest of superglues.

Skin adnexal tumours

I must congratulate Dr Cotton on his paper which attempts to clear the minefield of skin adnexal tumours.¹ In my experience these benign lesions cause great problems with classification, often requiring serious "bench testing" and much thumbing of Lever.

Two points concern me. Dr Cotton states that "distant metastases have not been reported" for malignant pilomatricomas. Two case reports of histologically confirmed metastatic pilomatric carcinoma do exist: Gould *et al*² and Mir *et al*,³ both using the criteria of Lopransri and Mihm for diagnosis.⁴

He also states that Merkel cell carcinoma stains "with Cam 5.2 which oat cells do not". The product information sheet for Cam 5.2 contradicts this as both tumours can stain with Cam 5.2, usually with a paranuclear "dot" positivity.⁵

P CROSS
Department of Histopathology,
Bury General Hospital,
Walmersley Road, Bury,
Lancashire BL9 6PG

- 1 Cotton D. Troublesome tumours I: Adnexal tumours of the skin. *J Clin Pathol* 1991;44:543-8.
- 2 Gould E, Kurzon R, Kowalczyk AP, Saldana M. Pilomatric carcinoma with pulmonary metastasis. *Cancer* 1984;54:370-2.
- 3 Mir R, Cortes E, Panagiotis A, *et al*. Metastatic trichomatrical carcinoma. *Arch Pathol Lab Med* 1986;110:660-3.
- 4 Lopransri S, Mihm MC. Pilomatric carcinoma or calcifying epitheliocarcinoma of malherbe. *Cancer* 1980;45:2386-73.
- 5 Rosai J. *Ackerman's Surgical Pathology*. Seventh Edition. New York: CV Mosby Company, 1989.

Dr Cotton comments:

I thank Dr Cross for his helpful comments. I have looked up the references to metastasis in malignant pilomatricomas (or pilomatrical carcinomas) and there are about six cases that I can locate. My comment about metastasis not being reported referred to aggressive variants of pilomatricomas rather than the frank carcinomas with pilomatric differentiation. In the case reports that I have read some were frank squamous carcinomas with pilomatrical areas, some were carcinoma arising in pilomatricoma, and two were possibly metastases arising from the cellular aggressive variants of pilomatricoma. Dr Cross is, of course, right to comment that there are reports of malignant pilomatricomas that have metastasised. I am still reluctant to believe that even cellular aggressive variants do so, although I agree that frank carcinomas do.

As to Dr Cross's comments regarding cytokeratin staining of Merkel cell versus oat cell tumours, there is some conflicting evidence. Dr Rosai in *Ackerman's Surgical Pathology* refers only to keratin stains and does not mention CAM 5.2 as far as I can see. The reference that he quotes refers to a series of cytokeratin antibodies raised in the author's own laboratories and which are not directly comparable with CAM 5.2 as far as I can ascertain. On the whole, the typical "ball in a fist" cytoplasmic dot positivity for CAM 5.2 is highly characteristic of Merkel cell tumours in my experience, and positivity in oat cell carcinomas is much less frequent and more diffuse when it occurs.