

Two cases of localized hypertrophic neurofibrosis

D. A. SIMPSON AND M. FOWLER

From the Adelaide Children's Hospital, South Australia

We have recently seen two children complaining of progressive paralysis in the territory of a single peripheral nerve. Biopsy of the affected nerves showed an intense interstitial fibrosis, resembling the state found in progressive hypertrophic polyneuritis. This well-known disease, usually designated with the names of Déjerine and Sottas, is of course typically a familial state, characterized by diffuse symmetrical lesions of many peripheral nerves. In our cases, there was no familial history, and the disease process has so far been localized to an isolated portion of a single nerve. It would be premature to identify these cases as variants of the generalized condition, but the remarkable histological appearances justify the noncommittal name of localized hypertrophic neurofibrosis. Review of the literature and personal enquiries suggest that others have seen similar cases, but the cause, and indeed the pathological nature, of the condition is obscure. Because of this obscurity, and because of the considerable difficulties encountered in surgical management, a brief report seems justified.

CASE REPORTS

CASE 1 N.A. (Adelaide Children's Hospital no. AE.1905), a boy then aged 12 years, was referred to the Neurosurgical Outpatient Clinic of this hospital on 7 February 1963.

History He said, and his parents confirmed, that his right foot and leg had become weak in 1959. Orthopaedic examination at that time had demonstrated a severe foot-drop, and a below-knee iron had been fitted. The weakness steadily progressed, without any pain or subjective sensory loss. It had appeared after an attack of chickenpox, but no other antecedent cause could be recalled.

Examination There was paralysis of eversion and dorsiflexion of the right foot, with wasting of the tibialis anterior and of the peronei. The calf muscles were somewhat wasted, but contracted powerfully. Toe dorsiflexion was lost. No sensory loss was found. The knee and ankle jerks were brisk. A lesion of the right lateral popliteal nerve was diagnosed.

Electromyography indicated a total lesion of the lateral popliteal nerve, with no evidence of volitional activity, the innervation of the medial popliteal nerve being normal.

However, radiographs of the lumbar spines showed a lumbo-sacral spondylolisthesis, and the diagnosis was debated. While the propriety of operation was being dis-

cussed, the boy broke his left femur in a fall. He was re-examined after this, and the neurological findings were confirmed. On this occasion, sensory loss, not very well defined, was found in the territory of the right musculocutaneous nerve. No evidence of neurofibromatosis was found, and no swelling or tenderness along the course of the sciatic or popliteal nerves was detected.

Examination of the cerebrospinal fluid (including the Wassermann reaction) was also negative.

It was decided to explore the sciatic nerve and its main branches, chiefly to exclude a neoplasm.

Operation Under general anaesthesia, on 17 December 1963, a vertical incision was made in the popliteal fossa, being curved laterally to the level of the neck of the fibula. The lateral popliteal nerve was exposed and a small hard fusiform enlargement, 8 mm. in diameter and about 2 cm. long, was found in its substance. The sural communicating nerve, and several other filaments, presumably sensory, could be dissected away, but the bulk of the lateral popliteal nerve was involved in the mass (Fig. 1). The affected nerve was therefore resected, together with apparently normal nerve above and below it: the resection seemed to be complete. Although recov-

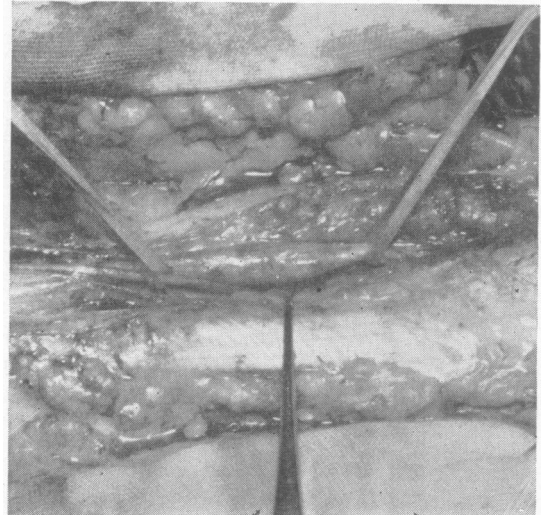


FIG. 1. Operative photograph, showing the lesion found in case 1. The fusiform expansion of the lateral popliteal nerve is lifted by tapes; a dissector retracts the sural communicating nerve.

ery of function seemed unlikely after so long a period of paralysis, a nerve anastomosis was performed, and the leg was then immobilized in a plaster cast, at 90° knee flexion. At this stage it was supposed that the lesion would prove to be some kind of neurofibroma, although its gross anatomy was not that of the ordinary schwannoma.

Histological examination (A.C.H. path. no. S557/63) Sections showed an intense isomorphic fibrosis, affecting chiefly the endoneurium, though the perineurium was also thickened. The characteristic unit of the process was an increase in endoneurial collagen, concurrently with a mild proliferation of fibroblasts, at first sparing the neurilemmal cell whose nucleus could often be seen within the ring of collagen in transverse sections. The most advanced stage of the lesion produced a much larger sheath of laminated or hyaline collagen in which nuclei, both neurilemmal and otherwise, had disappeared; at the periphery of this central area fibroblast nuclei were arranged concentrically, the whole giving an onion-skin appearance (Fig. 2). The intercellular material stained typically as collagen with van Gieson's mixture and Masson's trichrome stain, and gave no evidence of metachromasia with Nile blue sulphate in paraffin-embedded sections. With Congo red the material stained a mild to moderate brick colour, but showed no more birefringency than control collagen. Likewise, Schiff's periodic-acid method gave the pale pink colour similar to normal collagen.

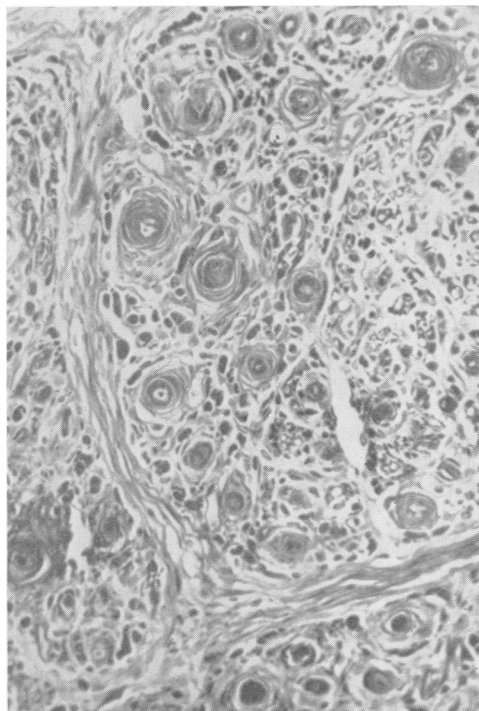


FIG. 2. Case 1: transverse section showing 'onion-skin' formation around individual axons and fibrosis in perineurium. van Gieson's mixture. $\times 270$.

In silver impregnations (Smith's silver-gelatin) the axons were reduced in number, being nearly always absent in the most advanced stage of the lesion. On the edge of the nerve evidence of active degeneration was found in the presence of occasional large vacuoles distending the axis cylinder or coarse thickening of the cylinder.

The only change possibly acceptable as evidence of regenerative activity was the presence of a few bundles of very fine fibrils enclosed within a common collagenous investment. It must be emphasized that there was no disarray of the nerve bundles or of remaining axons, each, although enlarged by its collagenous sheath, proceeding in a regular fashion through the lesion. The fibroblasts, although increased, were mature, with no anaplastic forms, nor was other evidence of disorderly growth seen.

The disease process appeared in the biopsy to extend beyond the apparent limits of the swelling, up to the lines of section proximally and perhaps also distally. It was therefore unlikely that a complete extirpation had been achieved. However, the appearances did not suggest a neoplasm, and after some hesitation, we decided against attempting a more radical resection. At this stage, no definite diagnosis was made.

Progress Convalescence was uneventful. The plaster cast was changed and the knee was progressively extended. After six weeks, immobilization was discontinued. The boy was kept under periodic observation during the next 10 months: no recovery of the paralysed muscles was demonstrated, and he was therefore referred for orthopaedic surgery. A Lambrinudi triple arthrodesis of the right foot and an anterior transposition of the tendon of tibialis posterior were performed, with considerable benefit.

He was last reviewed on 15 June 1965, 19 months after the resection of the nerve lesion. Examination then showed no change in the neurological state.

CASE 2 S.S. (Adelaide Children's Hospital no. A.E.5942), a boy then aged 11 years, was seen in consultation on 20 August 1964.

History His parents, who seemed intelligent, said that he first complained of weakness of the left wrist only eight weeks earlier, and he then exhibited a severe left wrist-drop. He himself said that his hand and arm had become weak four years earlier, a week after a mild injury, sustained in a fall from a tree. The weakness was at first slight, but had become progressively more severe, and had finally interfered with his performance in cricket. When asked why he had not mentioned the complaint earlier, he said: 'If anything happens to me, I don't usually tell people about it'. This stoical attitude seemed unnatural, and roused suspicion of some more recent injury, but none was ever disclosed. He denied any pain or dysaesthesiae. No familial history of relevance was given.

Examination There was a complete paralysis of the innervation of the left radial nerve, excluding the triceps but including the brachio-radialis. The affected muscles were wasted. There was definite sensory loss on the dorsum of the left hand around the second metacarpus.

phalangeal joint and on the proximal dorsal surfaces of the thumb, index, and middle fingers. No mass was palpable, but the left triceps seemed a little more bulky than the right. No other neurological abnormalities were found.

Electromyography This confirmed the clinical impression of a total paralysis of the left radial nerve, presumably at the level of the spiral groove. Radiographs of the arm were normal. It was thought that the likeliest diagnosis was a primary nerve tumour, and operation was advised.

Operation Under general anaesthesia on 6 October 1964, a curved incision was made in the posterior surface of the arm along the course of the radial nerve. It was deepened to expose that nerve as it pierced the lateral intermuscular septum. The nerve was grey, wasted, and inert to electrical stimulation. It was traced up in the spiral groove, between the medial and lateral heads of triceps, and in its upper extent, as it wound around the humerus, it was found to be enlarged into a hard fusiform tumour, about 1.5 cm. in diameter. The branches to the triceps muscle, which all responded to electrical stimulation, could be dissected (with difficulty) away from the tumour, but the main radial trunk could not. The lower pole of the tumour was well defined. The upper pole was almost outside the limits of the exposure, and could not be mobilized. The surgeon (D.A.S.) decided that a complete ablation would entail an axillary exposure, and resolved to defer this until the histology should be known. The tumour was therefore transected: it was seen to be composed of discrete bundles, separated by fibrous tissue, and the resemblance to case 1 was noted. The lower pole of the tumour was then mobilized, and a 3.5 cm. length of the lesion was excised.

Histological examination (A.C.H. path. no. S44/64) showed a striking increase in collagenous fibrous tissue similar to that in case 1, with similar tinctorial properties. The fibres could be seen to run longitudinally along the endoneurium and perineurium and in transverse section formed concentric lamellations as in case 1. The fibroblasts were increased in number and arranged concentrically on the outer part of the fibrous sheath as before, with no disproportionate increase or nuclear aberrations to suggest neoplasia. The axons, stained by Smith's silver-gelatin technique and Greenfield's silver impregnation of frozen sections, were attenuated and greatly reduced in number, some of the survivors being maintained in continuity and in good orientation one to the other.

In contrast to case 1 more groups of fine axons were found within single onion bulbs, and there was in these groups an increase in Schwann cells (Fig. 3). This was perhaps the early stage of the lesion; alternatively, the changes could be interpreted as evidence of regenerative activity. Further reasons to believe that this specimen was in an earlier stage of development than case 1 were the slightly sparser intercellular material and the slightly more numerous fibroblasts.

The similarity of the two biopsies was immediately noted, and the resemblance to progressive hypertrophic polyneuritis was seen. It seemed likely that a radical excision of the proximal portion of the radial nerve would compromise the still functioning triceps innerva-

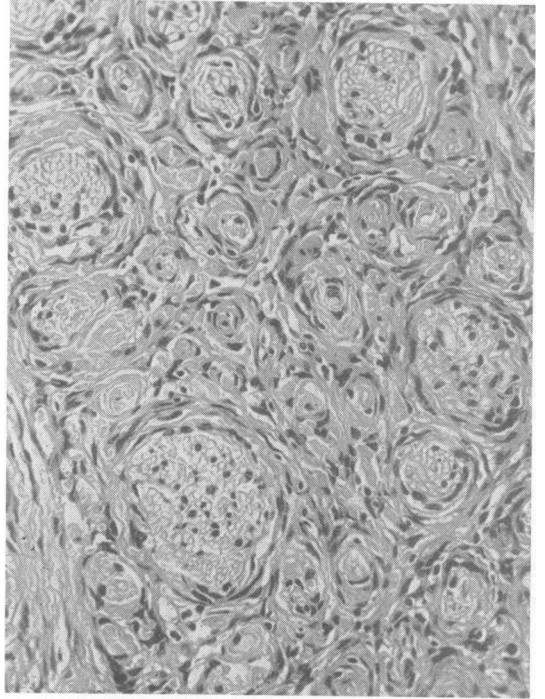


FIG. 3. Case 2: transverse section showing endoneurial fibrosis less advanced than in case 1, encasing individual fibres and bundles. Haematoxylin and eosin $\times 270$.

tion, and the experience of case 1 suggested that the disease might extend beyond its naked-eye limits. It was therefore decided to treat the boy expectantly. He made a good recovery. He was last examined on 17 February 1965. His neurological state was unchanged from the pre-operative condition; no evidence of involvement of any other nerve could be found. The wound had healed well with, however, some keloid formation. A tendon transplant, to correct the wrist drop, was performed on 2 June 1965, and it is understood that the result has been satisfactory.

DISCUSSION

In these two cases, the disease appeared to be a chronic hypertrophic fibrosis, mainly affecting the endoneurium, and restricted to a short segment of a single large peripheral nerve. Axons were reduced in number, and probably also in diameter, and their conductivity was abolished. No other neurological abnormalities were found, and there was no history of familial neurological disease.

The condition was unfamiliar to us. It was clearly not a schwannoma, nor indeed any other form of neoplasm known to us: the manifestations of neuro-

fibromatosis are of course very diverse, but our two patients showed no other stigmata, and their biopsies did not suggest any of the recorded types of neurofibroma. The possibility that the lesions represented the effect of acute or chronic trauma was considered, but the course of the disease seemed incompatible with this. On the other hand, the histology of the biopsies was recognized to conform with the standard descriptions of the progressive interstitial hypertrophic polyneuritis or neuropathy of Déjerine and Sottas, as described by Krücke (1955), Cammermeyer (1956), and Greenfield, Blackwood, McMenemy, Meyer, and Norman (1958). These authorities give as characteristic a longitudinal proliferation of collagen in the endoneurium, forming lamellated investments around the individual nerve fibres. These concentric lamellae appear, in cross section, as the well-known onion-bulb formations. In addition to this fibrosis, Greenfield *et al.* (1958) constantly found an abnormal interstitial fluid or ground substance staining metachromatically with toluidine blue and giving a positive reaction with leucofuchsin (Schiff's P.A.S. reagent). All writers note the paucity of axons and thinning or absence of myelin sheaths. This is usually attributed to strangulation of the axons by the fibrosis, or perhaps, as Greenfield *et al.* (1958) have suggested, by the interstitial fluid collection.

Our two cases showed all these features, with the possibly important exception that interstitial fluid was not prominent, and no metachromatic staining was demonstrated. (This may have been because frozen sections were not available.) However, the clinical manifestations in these cases were very different from the usual manifestations of progressive interstitial hypertrophic polyneuritis. That condition may, as Russell and Garland (1930) and others have observed, show a variable picture: it is not always familial, its course may be remittent rather than steadily progressive, and the degree of nerve involvement may be great or little. But none of the clinical reports known to us have identified as a manifestation of the generalized disease anything so sharply localized as the lesions reported here.

Nevertheless, Rubinstein (1965), who kindly examined the biopsies from our case 2, felt that the histological appearances justified classing the condition as a localized variant of Déjerine-Sottas disease. He mentioned two similar cases studied by him, and drew our attention to the report by Da Gama Imaginário, Coelho, Tomé, and Sales Luis (1964) of a progressive radial nerve palsy resulting from an apparently identical disease process. Their histological findings closely resemble those made in the cases reported here, with the addition that

plaques of P.A.S.-positive material between the nerve fibres were demonstrated. These writers described the condition as 'névrite interstitielle hypertrophique monosymptomatique', and discuss its possible relation to Déjerine-Sottas disease. They suggest that the seemingly specific histological appearances may represent a stereotyped reaction by the nerve sheaths to different noxious agents. This view seems plausible and may be accepted until the fundamental nature of the generalized disease is understood. We suggest the term 'localized hypertrophic neurofibrosis' as a provisional description of the cases described here: whether it is a disease entity, or an unusual manifestation of some other condition, is at present uncertain.

In our cases, and in that reported by Da Gama Imaginário *et al.* (1964), the disease presented as a painless progressive motor paralysis: sensory symptoms were almost entirely lacking. This may indicate a special vulnerability of the larger nerve fibres, or may only represent the predominantly motor function of the nerves affected (radial and lateral popliteal). Diagnosis was not easy: various conditions were considered, including primary nerve sheath tumour (schwannoma or neurogenic sarcoma), chronic trauma, and Hansen's disease (leprosy). Our small experience suggests that the condition here reported may enter into the differential diagnosis of these conditions.

Management was also difficult. In one case, the lesion was resected and an end-to-end anastomosis was carried out. This was also done by Da Gama Imaginário *et al.* (1964), with excellent recovery of nerve function. It seems the logical treatment, but no recovery took place in the case so treated by us. In the other case, technical difficulties deterred the surgeon from doing this, and the resection was incomplete. Time will show whether the residual mass will continue to grow and to destroy the still functioning parts of the affected nerve. If it does, a more radical resection will be urged. At present, however, believing that the disease is not neoplastic, we have preferred conservative measures.

SUMMARY

Two cases of a chronic progressive hypertrophic neurofibrosis or neuropathy are reported. The histological appearances resemble those of progressive hypertrophic polyneuritis, but the disease is not familial, and is confined to a short section of a large peripheral nerve. The condition appears to have been encountered by others, though it is clearly rare. Problems of diagnosis and management are discussed.

REFERENCES

- Cammermeyer, J. (1956). Neuropathological changes in hereditary neuropathies: manifestation of the syndrome heredopathia atactica polyneuritiformis in the presence of interstitial hypertrophic polyneuropathy. *J. Neurol. exp. Neurol.*, 15, 340-361.
- Da Gama Imaginário, J., Coelho, B., Tomé, F., and Sales Luis, M. L. (1964). Névrite interstitielle hypertrophique monosymptomatique. *J. neurol. Sci.*, 1, 340-347.
- Greenfield, J. G., Blackwood, W., McMenemy, W. H., Meyer, A., and Norman, R. M. (1958). *Neuropathology*. Arnold, London.
- Krücke, W. (1955). Progressive hypertropische Neuritis. In *Handbuch der speziellen pathologischen Anatomie und Histologie*, Band 13, Teil 5, pp. 84-100, edited by O. Lubarsch, F. Henke, and G. Rössle. Springer, Berlin.
- Rubinstein, L. J. (1965). Personal communication.
- Russell, W. R., and Garland, H. G. (1930). Progressive hypertrophic polyneuritis, with case reports. *Brain*, 53, 376-384.