

## Non-traumatic cerebrospinal fluid rhinorrhœa

AYUB K. OMMAYA, GIOVANNI DI CHIRO, MAITLAND BALDWIN, AND  
J. B. PENNYBACKER<sup>1</sup>

*From the Branches of Medical Neurology and of Surgical Neurology, National Institute of Neurological Diseases and Blindness, National Institutes of Health, Public Health Service, United States Department of Health, Education and Welfare, Bethesda, Maryland, U.S.A.*

There is a certain degree of confusion in the literature concerning nasal leakage of cerebrospinal fluid when trauma is not the cause. The term 'spontaneous cerebrospinal fluid rhinorrhœa' has been used more or less consistently to describe such cases since 1899. Although isolated observations had been made earlier, it was the monograph by St. Clair Thomson (1899) that first clearly described and attempted to define spontaneous cerebrospinal fluid rhinorrhœa as a clinical entity. Other authors have since essayed to subdivide this condition into 'primary spontaneous' or 'idiopathic' rhinorrhœa when a precipitating cause could not be found and 'secondary spontaneous' rhinorrhœa when a cause, usually a tumour, was discovered (O'Connell, 1964). Quite apart from the nosological adequacy of such a subdivision, the term 'spontaneous' cerebrospinal fluid rhinorrhœa itself would appear to be inexact, bearing no relationship to either the pathogenesis or natural history of the disease. The word 'spontaneous' means 'arising from natural impulse, without external stimulant, or having a self-contained cause or origin, or arising from or entirely determined by the internal operative or directive forces of the organism' (*Shorter Oxford English Dictionary*, 1962). It is our thesis that a careful study of the natural history of patients suffering such rhinorrhœa reveals no actual case which can fit such a definition—that is, in being truly 'spontaneous'. It would therefore be more accurate to describe all such cases, hitherto labelled spontaneous, by the more general term of non-traumatic cerebrospinal fluid rhinorrhœa. It is then possible to subdivide this category aetiologically on the basis of facts that emerge from a study of such patients, and assign each case according to the causative lesion. Quite apart from clarifying our understanding, this approach avoids what is essentially a 'waste-basket' category of 'primary spontaneous' rhinorrhœa, for those cases in which the true diagnosis has often not been discovered, as well as dispensing with the logic-

ally impossible phrase 'secondary spontaneous rhinorrhœa'.

In an earlier report by one of us (A.K.O.), an attempt was made to provide such a classification of cerebrospinal fluid rhinorrhœa on the basis of an analysis of the literature and the case histories of two patients (Ommaya, 1964). Since then we have been able to collect 18 patients with non-traumatic cerebrospinal fluid rhinorrhœa. Thirteen of these were seen at the Radcliffe Infirmary, Oxford, and five at the National Institute of Neurological Diseases and Blindness, National Institutes of Health, Bethesda, Maryland. For every patient we were able to obtain a report of the current status up to late 1967, constituting a minimum of one year and a maximum of 25 years follow-up. On the basis of this study a unitary hypothesis for non-traumatic rhinorrhœa would appear to be strengthened and the following classification, which is a modification of the one previously published (Ommaya, 1965), is recommended (Table I). It will be made apparent from this aetiological classification that the subdivisions of rhinorrhœa are closely related in terms of the mechanism of the leakage. The non-traumatic group is subdivided into 'high pressure' and 'normal pressure' categories. This reflects an important difference. In the high pressure category the leakage of cerebrospinal fluid is usually acting as a real safety valve, closure of which will invariably worsen the patient's condition if the causative lesion is not treated. Each of these categories is then subdivided into certain aetiological groups under which the mechanism of the rhinorrhœa may be better understood. The classification will be analysed in detail in the discussion of this paper where the concept of 'focal atrophy' will also be presented.

### METHODS

The eighteen patients we have studied are briefly described in the summary of case material shown in Tables II and III. They may be grouped according to their lesions into the two major subdivisions of non-traumatic cerebro-

<sup>1</sup>Present address: Department of Neurosurgery, Radcliffe Infirmary, Oxford.

spinal fluid rhinorrhœa as follows (the number of patients being given in parentheses):

I NORMAL PRESSURE LEAKS (Total 8) (1) fistulae in anterior cranial fossa—usually cribriform plate region (4); (2) Nasal encephalocele (1); (3) fistulae in sella turcica region (3).

II HIGH PRESSURE LEAKS (Total 10) (1) pituitary tumours (4); (2) acoustic neurinomas (2); (3) cerebellar gliomas (2); (4) nasopharyngeal carcinoma (1); (5) third ventricular tumour (1).

Table II lists the patients with normal pressure leaks in whom corrective surgery for the lesion and for the leak was usually conducted as one operation. Six out of eight cases (75%) were cured by surgery. Operative mortality was nil and morbidity was confined to one patient. In

Table III, the important clinical data of 10 patients with high pressure leaks are presented. In five of these patients, surgical treatment was aimed at the causative lesion and not at the fistula itself; this approach resulted in stoppage of the rhinorrhœa in four of these patients. In four out of 10 cases surgery was also directed at the leak, but in only one of these cases could the leak be stopped. In one case the surgical treatment was neither for the removal of the lesion nor the closure of the fistula but consisted of bypassing an obstruction in the ventricular system with a Torkildsen shunt. This cured the rhinorrhœa.

Illustrative histories of 10 patients selected to demonstrate important points of diagnosis and treatment will now be presented. This will be followed by a discussion of the mechanisms, diagnosis, and management of non-traumatic cerebrospinal fluid rhinorrhœa in the light of a critical review of the literature and our own experience.

TABLE I

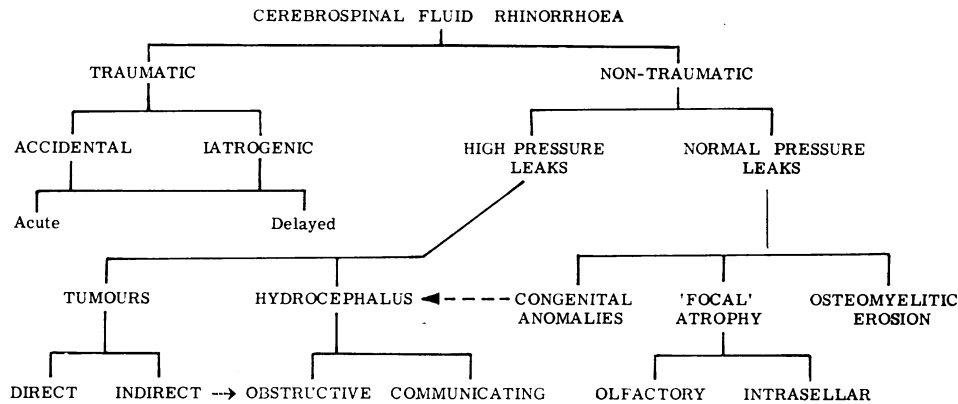


TABLE II

SUMMARY OF CASE MATERIAL  
A. NORMAL PRESSURE LEAKS

| No. | Lesion  | Surgery for lesion       | Surgery for rhinorrhœa | Result for lesion | Result for rhinorrhœa | Follow-up results  |
|-----|---|--------------------------|------------------------|-------------------|-----------------------|--|
| 1   | Hole in cribriform plate with arachnoid hernia<br>Age 54 C.S.           | Yes<br>(Same operation)  | Yes                    | Recurred          | Recurred              | Leak persists minimally 10 years after surgery with no attacks of meningitis                                   |
| 2   | Arachnoid hernia into enlarged 'empty sella'<br>Age 58 R.F.J.           | Yes<br>(Same operation)  | Yes                    | Cured             | Cured                 | No further leak 3 years after surgery. Patient well  |
| 3   | Hole in cribriform plate with meningeal hernia<br>Age 32 E.P.           | Yes<br>(Same operation)  | Yes                    | Cured             | Cured                 | No further leak 25 years after surgery. Patient well   |
| 4   | Nasal encephalocele<br>Age 4 B.D.                                       | Yes<br>(Same operation)  | Yes                    | Cured             | Cured                 | No further leak 13 years after surgery. Patient well   |
| 5   | Hole in cribriform plate with brain and meningeal hernia<br>Age 24 K.P. | Yes<br>(Same operation)  | Yes                    | Cured             | Cured                 | No further leak 10 years after surgery. Patient well   |
| 6   | Hole in anterior cranial fossa with meningeal hernia<br>Age 52 B.B.     | Yes<br>(Five operations) | Yes                    | Recurred          | Recurred              | Leaks persisted till death 11 years after 1st operation. P.M. confirmed congenital hole. No evidence of tumour |
| 7   | Hole in front of sella turcica<br>Age 50 J.Y.                           | Yes<br>(Same operation)  | Yes                    | Cured             | Cured                 | No further leak 6 months after surgery. Patient well   |
| 8   | Hole in floor of sella with arachnoid hernia into sella<br>Age 48 B.P.  | Yes<br>(Same operation)  | Yes                    | Cured             | Cured                 | No further leak 3 months after surgery. Patient well   |

## CASE REPORTS

CASE 1 (J.Y. (N.I.H.) No. 7 in Table II). A 48-year-old male physicist was quite well until the autumn of 1965 when a sudden onset of leakage of cerebrospinal fluid from the left nostril was noted. Initially scanty and intermittent, the rhinorrhœa soon became copious. Physical examination was negative. Plain radiographs of the skull and detailed tomograms of the sellar region showed that air and fluid were present in the sphenoidal sinus. With the patient in supine position and the x-ray beam horizontal (brow-up view) only a little amount of air was seen in the anterior part of the sphenoidal sinus with a clear air-fluid level also being demonstrated (Fig. 1a). When the patient was turned to the prone position, a large spurt of fluid came out from the left nostril and the lateral (brow-down) radiograph (Fig. 1b) showed that the sphenoidal sinus was almost in its entirety air filled. The air-fluid level was no longer present. Sellar tomograms demonstrated that a break of continuity—an actual hole—was present on the left of the midline immediately behind the planum sphenoidale (Fig. 2c). Pneumoencephalography revealed only slight enlargement of the ventricular system with no abnormalities in the sellar region; in particular, no air penetrated within the boundaries of the sella turcica. RISA-cisternography showed an abnormal collection of activity in the sphenoidal sinus with the patient supine, confirming that the leak was from the sella turcica region (Figs. 2a, b). When the patient was put in the prone position, a spurt of fluid—which proved

to be very 'hot' in the well counter—came out from the left nostril. Lateral scans with the patient replaced in the prone position now revealed that the abnormal sphenoidal collection of radioactivity could no longer be demonstrated (Fig. 2c). It appeared clear, therefore, that the site of the leak was into the sphenoidal sinus, probably from the 'hole' seen just in front of the sella turcica on the left side. Surgical exploration by a bi-frontal intradural approach was then conducted. The olfactory grooves were deeper than usual and the arachnoid covered olfactory bulbs did not fill the anterior part of the cribriform plate completely. This was a bilateral phenomena but there appeared to be no holes here. The planum sphenoidale and the remainder of the anterior cranial fossa were quite normal. However, just posterior to the limbus sphenoidalis, immediately on the left of the midline, a definite hole could be palpated. A blunt dissector could pass without effort through this hole leading into the region of the sphenoid sinus. Accordingly, a crushed muscle plug was made to fill this hole snugly and covered with a further plug of gelfoam. A patch of gelfoam was also left intradurally over the left cribriform plate where the left olfactory tract had been deliberately divided during the exposure. Post-operatively the patient made an uneventful recovery and had no leakage of cerebrospinal fluid. Repeated RISA cisternography one month after surgery showed no evidence of isotope leakage into the sphenoid sinus or nasal area. Six months after surgery, the patient is well and has had no further leakage of cerebrospinal fluid.

TABLE III

SUMMARY OF CASE MATERIAL  
B. HIGH PRESSURE LEAKS

| No. | Lesion   | Surgery for lesion | Surgery for rhinorrhœa | Result for lesion | Result for rhinorrhœa | Follow-up results  |
|-----|--|--------------------|------------------------|-------------------|-----------------------|--|
| 9   | Pituitary adenoma. Leak via sellar floor<br>N.W.         | Yes (1)            | Yes (2)                | Cured             | Recurred              | Leak persists 6 years after surgery.<br>On replacement therapy and penicillin<br>No leak for 6 years             |
| 10  | Acoustic neurinoma. Leak via eustachian tube?<br>E.K.    | Yes (1)            | No                     | Cured             | Cured                 | No leak for 6 years  |
| 11  | Acoustic neurinoma. Leak via eustachian tube?<br>J.D.    | Yes (2)            | No                     | Cured             | Cured                 | No leak for 9 years  |
| 12  | Nasopharyngeal carcinoma<br>A.H.                         | Yes (1)            | No                     | Persisted         | Stopped               | Died 1 year. No P.M.   |
| 13  | Pituitary adenoma<br>E.R.                                | Yes (1) + DXr      | No                     | Persists          | Stopped               | No leak 5 years later  |
| 14  | Pituitary tumour<br>Q.J.                                 | No DXr only        | No                     | ? Cured           | Persists              | Minimal leak persists.<br>Patient refuses surgery<br>6 years   |
| 15  | Pituitary adeno-carcinoma. Leak via sellar floor<br>F.K. | Yes (2) + DXr      | Yes                    | ? Cured           | Cured                 | Massive tumour regressed after radiation. No tumour recurrence for 3 years.<br>Leak arrested<br>No leak 11 years |
| 16  | 3rd ventricle tumour. Leak in cribriform plate<br>P.M.   | No                 | Yes (Shunt)            | Persists          | Cured                 | No leak or tumour recurrence 6 years   |
| 17  | Cerebellar glioma. Leak via cribriform plate<br>B.L.     | Yes (3)            | Yes (1)                | ? Cured           | Cured                 | No leak or tumour recurrence 6 years   |
| 18  | Cerebellar glioma. Leak via cribriform plate<br>N.L.     | Yes (3)            | Yes (2)                | ? Cured           | Persisted             | Died after 2nd leak surgery from pulmonary embolism  |

Numbers in parentheses refer to number of operations.  
DXr = Deep x-ray therapy.

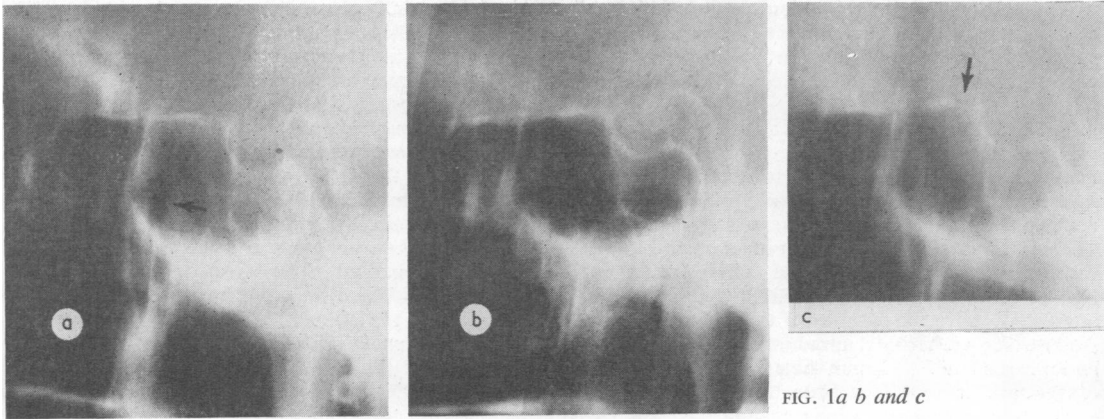


FIG. 1a b and c

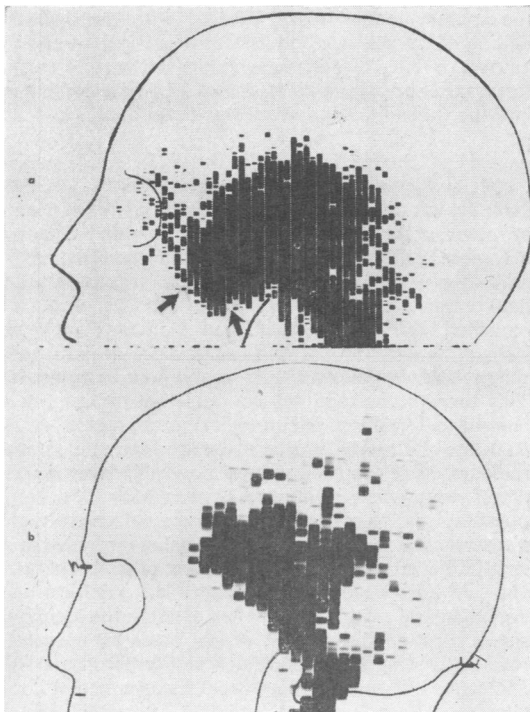


FIG. 2a and b




FIG. 2c



FIG. 3

FIG. 1. Plain skull tomograms. (a) 'Brow-up' view: air bubble in sphenoidal sinus with air-fluid level (arrow). (b) 'Brow-down' view: sphenoidal sinus almost completely air filled. (c) Bone defect (arrow). Patient No. 7 (Table II).

FIG. 2. (a) Leakage and accumulation of radioactive tracer in sphenoidal sinus (arrows) in two-hour RISA-cisternogram. Patient No. 7 (Table II). (b) Normal two-hour RISA-cisternogram in another patient for comparison.

FIG. 2c. Normal post-surgery RISA-cisternogram. Compare with pre-surgery in Figure 2a.

FIG. 3. Pneumoencephalography: autotomogram showing air-filled anterior half of sella turcica. Patient No. 2 (Table II).

*Comment* Surgical exploration confirmed the radiographic finding of a bony defect in front of the sella turcica. The nature of this lesion was such that either a congenital or an 'atrophic' aetiology was possible.

CASE 2. (K.P. (R.I.) No. 5 in Table II). A 24-year-old man had had intermittent leakage of cerebrospinal fluid from the left nostril for six years before his admission for investigation in 1956. Three attacks of meningitis (one meningococcal and two pneumococcal) had also occurred. There was no history of trauma or other obvious cause for the rhinorrhœa. Examination and radiological investigation gave entirely normal results. No contrast studies or attempts to trace the pathway of the leak were made. In August 1956 a left frontal intradural exploration was done and revealed a  $2 \times 3$  mm hole in the postero-lateral corner of the left cribriform plate, through which a slender cerebral and meningeal hernia entered the nasal cavity. There were no other abnormalities. The hernia was severed and the dural hole repaired with a pericranial patch placed intradurally. No attempt was made to close the bony defect. The patient made an uneventful recovery and had no further leakage. He was completely well at the end of 1965—that is, nine years after surgical treatment.

*Comment* This patient's course illustrates the ease with which a probable congenital anomaly responsible for a normal pressure cerebrospinal fluid leakage can be treated. That this is not always so is demonstrated by the next patient.

CASE 3 (B.B. (R.I.) No. 6 in Table II). A 52-year-old female was first seen in 1952 with a short history of the sudden onset of cerebrospinal fluid rhinorrhœa from the left nostril in October 1951. There was no history of trauma or other predisposing factors. In January 1952 she underwent a left frontal craniotomy by Mr. W. McKissock which revealed a small dural hole anterior to the left olfactory bulb in what seemed to be an excavated cribriform plate. This was plugged with muscle and oxycel. Post-operatively the leakage recurred and persisted. Three further operations were done, in February, March, and June of 1952, all being left frontal craniotomies, and attempts to plug the same hole with muscle, oxycel, and fascia were repeated on each occasion. The fourth craniotomy necessitated amputation of the left frontal pole. In spite of repeated surgery the cerebrospinal fluid rhinorrhœa persisted and indeed became very profuse in January 1953. During this year of continuing rhinorrhœa she also gained over 50 lb. in weight. At this time she was admitted to the Radcliffe Infirmary and examination revealed an obese woman with a continuous leakage of cerebrospinal fluid from the left nostril (10 to 14 drops/min). She was euphoric and lethargic. Radiographs of the skull and pneumoencephalograms were interpreted as being normal. In October 1963 she underwent bifrontal craniotomy and intradural exploration of both frontal fossae. The dura over the posterior part of the right olfactory groove had a  $2 \times 5$  mm hole to which the brain was adherent. On the left side, no abnormalities were seen but a probe placed in the dural hole on the right passed into the left posterior ethmoidal sinus. Accordingly, the hole on the right was plugged with muscle and an intradural

fascial repair of the dural defect was completed. Post-operatively she had immediate cessation of the rhinorrhœa. Ten days later the cerebrospinal leakage recurred and continued unremittingly thence onward. Ten years after surgery (February 1963), while in bed with asthma and bronchitis, she died quite suddenly having no remission of her rhinorrhœa. Necropsy revealed dense adhesions of the meninges to the base of the skull in the left anterior and middle fossae. Unfortunately, an extensive study of the skull and brain for the anatomy of the leakage was not made, but there appeared to be no evidence for an intracranial tumour or other precipitating cause for the rhinorrhœa. There was no fracture present and the adhesions in the left-middle fossa were thought to connect with the sphenoid sinus.

*Comment* This patient demonstrates the extreme difficulties which may arise in some cases when the exact pathway for the leakage is not precisely visualized at the very onset. The continuation of the leakage from the left nostril, in spite of extensive and thorough repair within the anterior cranial fossa, coupled with the operative finding of a track into the left ethmoidal region and the autopsy finding of adhesions in the left middle cranial fossa, raise the possibility of a sellar or parasellar channel into the sphenoid sinus which was never disclosed.

CASE 4 (C.S. (R.I.) No. 1 in Table II). A 54-year-old female suddenly developed a cerebrospinal fluid leakage from the left nostril; there was no prior history of trauma or other predisposing factors. Two months later she became very ill for one month with pneumococcal meningitis following which the rhinorrhœa slowly decreased and finally ceased altogether six months after its onset. She remained well for five years and then once more the leakage of cerebrospinal fluid began. This second siege of rhinorrhœa was followed by a second bout of meningitis. This time the leakage did not cease but persisted in an intermittent fashion. Neurological examination at the Radcliffe Infirmary was entirely normal and routine radiographs of the skull showed no visible bony defects. A left frontal craniotomy was done in May 1956. Intradural exploration of the left anterior cranial fossa revealed a vascularized sleeve of arachnoid passing through a small hole in the left cribriform plate. A piece of temporal fascia was laid intradurally over the entire left cribriform plate region to seal off the defect after dividing the arachnoid sleeve. Post-operatively the patient made an uneventful recovery and there was no evidence of cerebrospinal fluid rhinorrhœa. However, intermittent leakage recurred after a few months and persists to this date. The patient has not desired further surgery and has not had any meningitis.

*Comment* This was an apparently simple case of normal pressure cerebrospinal fluid leakage through the cribriform plate. Recurrence of the rhinorrhœa occurred after temporary post-operative cessation. Either the intradural fascial graft was inadequate to seal the fistula or there was another fistula which was not diagnosed.

CASE 5 (R.F.J. (N.I.H.) No. 2 in Table II). A 57-year-old male was quite well until 1958 when a transient episode of sudden loss of consciousness occurred at work. One year later a similar brief episode and nocturnal tongue biting

necessitated anti-convulsant therapy. No further tongue biting or unconsciousness was noted. In March of 1963 sudden leakage of clear fluid from the left nostril began. He was admitted to the National Institutes of Health, Branch of Surgical Neurology, in July 1963. Physical examination revealed no other abnormality of note. Several encephalograms confirmed a left fronto-temporal epileptogenic focus. Endocrinological investigations revealed mild hypopituitarism. Plain radiographs of the skull and detail tomograms showed an enlargement of the sella turcica. At pneumoencephalography, air filled the anterior half of the sella turcica (Fig. 3). The widened cisterna intrasellaris was thus causing an 'empty' sella turcica. Bilateral carotid angiography revealed no abnormality. RISA-cisternography showed that the leak of cerebrospinal fluid was from the antero-inferior part of the sella turcica exactly corresponding with the arachnoidal 'hernia' into the 'empty sella' seen at pneumoencephalography (Fig. 4a). A right frontal craniotomy was then performed and an intradural approach to the sella revealed the arachnoidal sleeve entering the sella. This was incised and with a dissector one could feel the empty anterior space plus tissue in the posterior sella. Several pieces of gelfoam were then placed into the empty anterior arachnoid pouch so as to plug it entirely. The patient made an uneventful recovery and, in spite of blowing his nose in the post-operative period (against firm instructions to the contrary), no further cerebrospinal fluid rhinorrhœa was noted. Six months after this operation he was re-admitted for a check RISA cisternography which now proved to be normal (Fig. 4b). Since that time the patient has continued to do well, and when last seen—that is, over three years after surgery—there was no recurrence of cerebrospinal fluid rhinorrhœa or other significant disorder.

*Comment* This is an example of normal pressure non-traumatic cerebrospinal fluid rhinorrhœa occurring in a patient presenting initially with epilepsy of late onset.

Suspicion of an intracranial tumour was increased when the rhinorrhœa began and the enlarged sella suggested a pituitary tumour. However, pneumoencephalography revealed the arachnoid 'hernia' into an empty sella. The fistula was clearly demonstrated by RISA cisternography and surgical treatment was successful after closure of the sellar hole with gelfoam only. A similar lesion was found and treated in patient No. 8 in Table II and an operative view of her sellar region can be seen in Fig. 5.

CASE 6 (N.W. (R.I.) No. 9 in Table III). A 44-year-old woman began to suffer episodes of psychomotor epilepsy with evidence of mild hypopituitary disturbance in 1957. Examination revealed a right homonymous hemianopsia and a left 3rd nerve palsy. A clinical diagnosis of pituitary adenoma was made and radiotherapy plus hormone replacement resulted in excellent recovery. Three years later she noted the sudden onset of cerebrospinal fluid rhinorrhœa from the left nostril. After 10 weeks and two mild attacks of meningitis she was admitted to hospital. Examination revealed a minimal right quadrantanopsia and left carotid angiogram showed extrasellar extension of the pituitary tumour. A left frontal craniotomy allowed total removal of the tumour, and a muscle plug was placed in the cavity created within the sella turcica. During this operation no fistula was found. Post-operatively the patient had no further rhinorrhœa for six months. In late 1960, the leakage recurred from the left nostril with no other evidence of tumour recurrence. A second frontal craniotomy showed the sella to be almost empty, and a probe passed easily into the sphenoid sinus. The sella was packed with muscle and a free pericranial graft covered this area as well as the left anterior cranial fossa. No further cerebrospinal fluid rhinorrhœa was noted until May 1963—that is, three years later. Her physicians elected on this occasion to place her on long-term antibiotics without further surgery. At the present time she continues to have cerebrospinal fluid rhinorrhœa but has

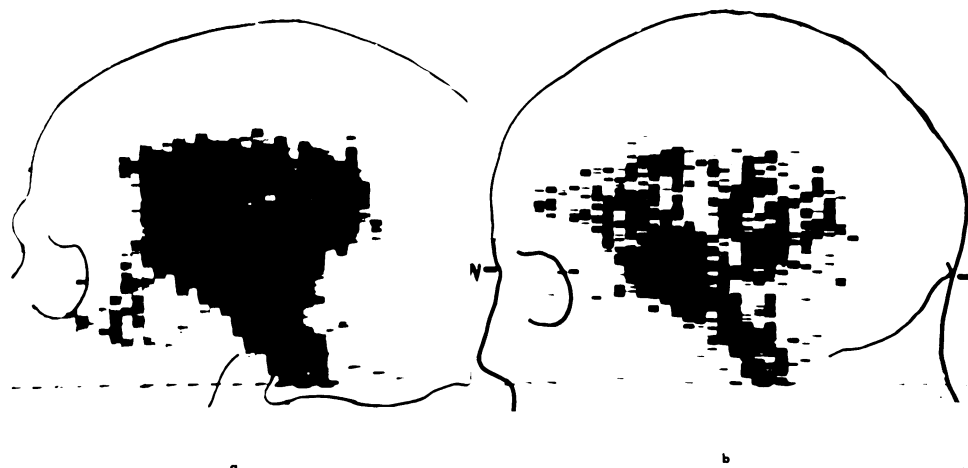


FIG. 4a, b. Same patient as Fig. 3. RISA-cisternogram showing leakage of tracer from sella region (a). Normal findings after surgical cure (b).

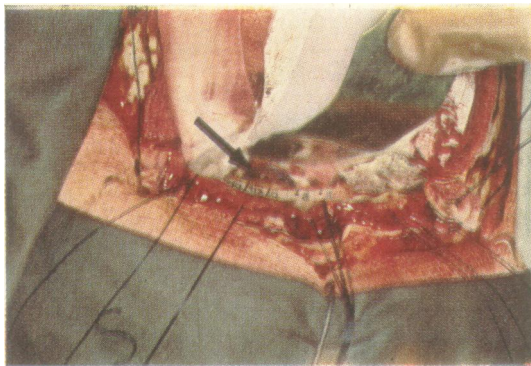


FIG. 5. 'Empty' sella at surgery. Patient No. 8 (Table II).

had no further attacks of meningitis while continuing on penicillin and hormone replacement therapy. The visual field defect has not increased.

*Comment* In this case the cerebrospinal fluid leakage followed a course of deep x-ray treatment directed at a large pituitary adenoma. It is possible that radiation-induced tumour atrophy resulted in a cystic intrasellar extension of the cerebrospinal fluid space which in turn produced the fistula through a portion of the sellar floor eroded by the tumour's growth.

**CASE 7** (J.D. (R.I.) No. 11 in Table III). A 34-year-old man was first seen in the E.N.T. Department in July 1955 with a history of deafness in the left ear since childhood, a left facial palsy of 11 years' duration that had improved partially, and profuse cerebrospinal fluid rhinorrhoea for one year. Examination revealed that in addition to the left 7th and 8th nerve lesions there was bilateral nystagmus. Radiographs of the skull revealed an eroded apex of the left petrous temporal bone. An E.N.T. surgeon explored the petrous area *via* a mastoid approach and was able to uncover and partially excise an acoustic neurinoma on this side. Post-operatively the cerebrospinal fluid rhinorrhoea continued unabated. In March 1957, after a severe attack of meningitis, he was admitted to the Neurosurgical Department. A posterior-fossa exploration revealed a large left acoustic neurinoma which was filling the cerebello-pontine angle as well as eroding into the petrous apex. This was removed subtotally. The patient made a good recovery and no further leakage was noted. Nine years after this surgery, the patient had no recurrence of either the tumour or the rhinorrhoea.

*Comment* This was a slowly growing intra- and extra-petrous acoustic neurinoma which precipitated a cerebrospinal fluid rhinorrhoea either by the high pressure producing a leak through the cribriform plate or by establishing a fistula into the Eustachian tube *via* the middle ear cavity. Unfortunately the exact fistula could not be demonstrated. An otological approach to the petrous apex revealed, and allowed biopsy of, the tumour, but the leakage was not reduced after this type of surgery. However after a posterior-fossa intracapsular removal of the tumour without attempting to repair the fistula, the rhinorrhoea stopped. Posterior fossa surgery cured the

rhinorrhoea either by pressure reduction, closure of the fistula by adhesions, or both of these factors.

**CASE 8** (B.L. (R.I.) No. 17 in Table III). A 28-year-old man presented in 1959 with bouts of cerebrospinal fluid rhinorrhoea and occasional bi-occipital headaches. The significant past history included three operations for a right cerebellar astrocytoma—an aspiration biopsy in 1936, a subtotal excision in 1937, and a total removal in 1948. From then on he had no complaints until the onset of the rhinorrhoea in 1959. This continued with varying intensity until 1960 when he was admitted for treatment. The leakage could be easily started by tipping his head forward. Examination revealed no bulge of the posterior fossa craniectomy site, no papilloedema, and minimal neurological deficits related to the cerebellar tumour which were unchanged from that noted in 1948. Radiographs of the skull showed marked osteoporosis of the walls of the sella and a large midline bony defect anterior to the tuberculum sellae. A lumbar puncture (while rhinorrhoea was present) showed cerebrospinal fluid at a pressure of 120 mm and with 160 mg of protein. Pantopaque ventriculography with 2.5 ml of dye was then carried out *via* the right frontal horn, and the dye flowed easily through the 3rd ventricle, aqueduct, and 4th ventricle into the basal cisterns. No evidence of a space occupying lesion in the posterior fossa was found. A bifrontal craniotomy was then performed and intradural exploration revealed multiple meningo-cerebral herniae into bony defects close to the midline in the anterior cranial fossae. Fascia lata grafts were used bilaterally to cover the holes after the herniae were excised. For a few days post-operatively there was a moderate amount of blood-stained rhinorrhoea but this rapidly decreased by the end of the first week. At discharge two weeks later, there was no rhinorrhoea. The latest follow-up in 1966 (six years after surgery for rhinorrhoea and 30 years after tumour diagnosis) revealed the patient to be in excellent health with no recurrence of either rhinorrhoea or cerebellar tumour.

*Comment* This patient's rhinorrhoea was a delayed consequence of the posterior fossa tumour. The bony abnormalities and brain + meningeal herniae were probably initiated by high pressure, but the leakage did not start for 11 years after radical removal of the tumour. The mechanism for delayed leakage in this case may be related to that suggested for Case 6 (N.W.).

**CASE 9** (P.M. (R.I.) No. 16 in Table III). A young girl began to suffer severe headaches and blurred vision in 1934. In 1936 a surgeon in London performed bitemporal decompressive craniectomies following which all her symptoms vanished. She remained quite well until 1939 when she developed a left hemiplegia and recurrence of the headaches. This was presumed to be due to a right cerebral hernia at the site of decompression. Three years later in 1942 she suddenly began to leak cerebrospinal fluid from her nose, and this rhinorrhoea was associated with a dramatic improvement in her headaches, hemiplegia, and general well being. She remained well but with the fistula leaking until 1945 when the leakage suddenly stopped. She immediately became hemiplegic once more on the left and the headaches recurred. Examination at

this time was made in the Neurosurgical Department of the Radcliffe Infirmary. This revealed bulging in both areas of subtemporal decompression, mild secondary optic atrophy, and a moderate left hemiparesis. Routine radiographs of the skull revealed a large suprasellar calcification forming an almost complete cast of the 3rd ventricle, including an extension into the right foramen of Monro. The diagnosis of a calcified craniopharyngioma was made and in May 1945 a Torkildsen shunt was carried out. The pressure in the right lateral ventricle at this time was 250 mm cerebrospinal fluid. Post-operatively she made an uneventful recovery and had no further rhinorrhœa although the left hemiparesis persisted. When last seen, almost 20 years after the Torkildsen shunt was placed, the patient was in good health with no headaches or rhinorrhœa, but with a persisting left hemiparesis.

*Comment* This unusual case is an excellent example of the 'safety-valve' nature of a high-pressure non-traumatic cerebrospinal fluid rhinorrhœa. After the tumour was bypassed by a Torkildsen shunt, the rhinorrhœa remained in abeyance and has not recurred over a period exceeding 20 years.

CASE 10 (N.L. (R.I.) No. 18 in Table III). A 10-year-old boy began to have episodes of headache, vomiting, and ataxia in 1933 leading to a posterior fossa decompression in 1939. Further deterioration in 1944 led to re-exploration and sub-total removal of a pilocytic cerebellar astrocytoma by Sir Hugh Cairns. He made an excellent recovery, being able to return to work on his farm and remained well until 1955. At this time the sudden onset of cerebrospinal fluid rhinorrhœa from the right nostril was noted. He was readmitted and a right frontal craniotomy revealed a cerebrospinal fluid fistula through the cribriform plate on the right side which was covered with a fascia lata graft placed intradurally. An uneventful recovery with no further rhinorrhœa after this operation ended one month later with signs of raised intracranial pressure. However, these signs subsided in a few weeks and the patient returned to work. He was fairly well for about two years with only one 10-day spell of cerebrospinal fluid rhinorrhœa in 1956. In 1957 the rhinorrhœa started again and was followed by a persistent low-grade meningitis. After this was controlled he underwent exploration of the posterior fossa. No evidence of tumour could be found. Post-operatively meningitis recurred and required further intensive therapy. Approximately two months after the latest operation his condition improved but rhinorrhœa persisted and accordingly the right frontal craniotomy was re-opened. About one large and three small brain and meningeal herniae were seen passing into holes in the right anterior cranial fossa just lateral to the cribriform plate. The herniae were sectioned and a fascial graft laid over the meningeal defects. In addition an anterior third ventriculostomy was performed. After this operation, however, the rhinorrhœa persisted and there was a considerable accumulation of intracranial air in the frontal region. Therefore, a further craniotomy was performed and a plug of acrylic placed in the largest of the bony defects external to the fascial graft which was found to be thoroughly adherent to the dura mater. Post-operatively his level of consciousness did not improve

and the posterior fossa defect was noted to be bulging. No further rhinorrhœa occurred but his general condition worsened as the chronic meningitis reasserted itself in spite of intensive systemic and intrathecal antibiotic therapy. About two months later, in January 1958, he suddenly collapsed and died. Necropsy revealed the cause of death to be thrombosis of the inferior vena cava as well as pulmonary emboli. There was no evidence of tumour recurrence and the frontal cerebrospinal fluid fistulae were well closed.

*Comment* This case is a further illustration of the 'safety valve' nature of some cerebrospinal fluid rhinorrhœas. The persistence of meningitis in this patient complicated the management severely and rendered repeated efforts to stop the leak ineffective until too late. It is interesting to note that 'pressure' phenomena recurred when the leak stopped, in spite of the absence of tumour recurrence. This may have been due to a degree of communicating hydrocephalus.

#### DISCUSSION

The case-histories presented were chosen to illustrate facets in the pathogenesis as well as diagnosis and treatment of non-traumatic cerebrospinal fluid rhinorrhœa. Before reviewing these aspects of the problem in detail, a clarification concerning our classification must be presented. The aetiological classes shown in Table I are not mutually exclusive in so far as the mechanics of the cerebrospinal fluid leakage itself are concerned. That is to say, these categories overlap at all levels including the first major subdivision into traumatic and non-traumatic rhinorrhœas. Thus it is possible that in certain cases of delayed traumatic cerebrospinal fluid leakage the actual precipitating cause for the rhinorrhœa may be analogous to mechanisms producing non-traumatic leaks. This would explain case reports of patients with delayed traumatic cerebrospinal rhinorrhœa in whom associated congenital anomalies related to the fistula are found—for example, persistence of the basi-occipital canal (Voena, 1959). Similarly the onset of cerebrospinal fluid rhinorrhœa in certain cases of pituitary tumour treated with x-ray alone suggests a similarity between post-radiation atrophy and the post-traumatic atrophy of cerebral tissues which may be responsible for the onset of delayed traumatic cerebrospinal fluid rhinorrhœa (Bateman, 1966).

*PATHOGENESIS* A previous paper by one of us (A.K.O.) contains a full review of earlier reports published up to 1964 (Ommaya, 1964). Accordingly, only more recent papers will be referred to in the following discussion. The category of cerebrospinal fluid rhinorrhœa caused by tumours is subdivided into 'direct' and 'indirect' in Table I. This indicates the two ways in which the fistula may be created by



the tumour—that is, either directly by erosion of meninges and bone (Cases 9 through 15 in Table III) or indirectly *via* pressure erosion of anatomically fragile areas of the skull base (Cases 16, 17, and 18 in Table III). It is significant that in all three of these indirect rhinorrhœas the fistula was in the cribiform plate; an indication of the fragility of this area. Previous reports on tumour-induced cerebrospinal fluid rhinorrhœa (Teng and Papatheodorou, 1965; Raskind, 1965; Gotham, Meyer, Gilroy, and Bauer, 1965) have emphasized that pituitary tumours are the commonest lesion and in our series of 10 patients with high pressure leaks there were four cases (Cases 9, 13, 14, and 15 in Table III). It should be stressed that cerebrospinal fluid rhinorrhœa is an extremely rare complication of such tumours.

*Hydrocephalus* This is a much rarer cause of cerebrospinal fluid rhinorrhœa. The earliest report of a case due to communicating hydrocephalus is by Miller and little can be added to that account (Miller, 1826). Occasionally hydrocephalus is associated with a congenital anomaly as the cause of a high pressure cerebrospinal fluid leak and such an association has been reported with Crouzon's disease and Albers-Schönberg disease (osteopetrosis). In the majority of cases, however, congenital anomalies are aetiologically more important for normal pressure leakages. Here nasal encephalocele is the usual lesion discovered (Case 4 in Table II) and such patients are the only examples of normal pressure leakages occurring in childhood.

*Focal atrophy* Congenital anomalies may also play a role in the next category of our classification, namely 'focal atrophy'. This is a speculative idea suggesting that the normal contents of the cribiform plate or sella turcica areas are reduced in bulk. This atrophy may be due to ischemia. The empty space thus created is filled with a cerebrospinal fluid laden arachnoidal pouch which is an enlargement of the normal arachnoidal space extensions. This pouch enables the normal cerebrospinal fluid pressure pulse to exert a focal and continually erosive effect analogous to the creation of cranial vault excavations by the arachnoidal granulations. This concept of focal atrophy was developed to explain the mechanism of cerebrospinal fluid rhinorrhœa in three of our patients with sellar leaks (Cases 2, 7 and 8 in Table II). But it may be invoked to explain normal pressure cerebrospinal fluid leakage from any site in adults. Thus it agrees quite well with the hypothesis advanced by O'Connell. He described in two patients a combination of an excavated lamina cribrosa plus a shrunken olfactory bulb enabling the development of a pulsating pocket of cerebrospinal fluid over the fistula (O'Connell, 1964). In our series, Case 1 in Table II appeared to have a similar lesion.

Minor degrees of congenital meningeal and meningo-cerebral herniae can also act as actual or potential pathways in the anterior skull base and present in adult life with cerebrospinal fluid rhinorrhœa—for example, Cases 3, 5, and 6 in Table II. The majority of case reports of 'primary spontaneous' rhinorrhœa are explicable by this aetiology. The genesis of such a leak, aside from the pole of focal atrophy, is probably related to the attainment of the maximum cerebrospinal fluid pressure in adults, which is almost three times that of infants, as well as with factors such as sneezing, coughing, or other causes of normal fluctuations in cerebrospinal fluid pressure (O'Connell, 1953).

*Osteomyelitic erosion* The final aetiological category is of osteomyelitic erosion. This is a very rare cause (Nori and Carteri, 1964) and we have not had a single patient with this condition.

*DIAGNOSIS* This includes identification of cerebrospinal fluid as the constituent of the rhinorrhœa, demonstration of the cause whenever possible, as well as localization of the fistula itself. Identification of cerebrospinal fluid is usually easy except in a few cases of 'vasomotor rhinorrhœa' or allergic rhinitis where a faulty initial diagnosis can be misleading. However, persistence of a clear non-sticky nasal discharge should immediately rouse suspicions and lead to further investigations. Biochemical tests on the collected fluid, particularly the often quoted use of glucose-oxidase test papers, are not fully reliable. The latter method has been shown to have a 45 to 75% chance of positive results with normal nasal secretions (Gadeholt, 1964). Positive identification of cerebrospinal fluid necessitates introduction of suitable tracers into the cerebrospinal fluid cavities and their recovery in the nasal discharge. These techniques are part of fistula localization and will be considered below.

Concerning demonstration of the cause of the leakage it should be remembered that over half the cases of non-traumatic rhinorrhœa are high pressure leaks due to tumours, and the diagnostic approach to such patients should therefore be the same as that to patients with epilepsy of late onset. However, it is not enough to display the causative space-taking lesion; the fistula must also be localized. Naturally such localization takes precedence when a normal pressure leak is present.

It cannot be sufficiently emphasized that the assessment of the location of the leakage is often a difficult and always a challenging diagnostic problem. This is due to the fact that the possible leaking sites are quite numerous and may occur in the anterior, middle, and posterior fossae. Most frequently the cerebrospinal fluid reaches the nasal cavity through

the frontal sinus, the lamina cribrosa, the sphenoidal roof, or the petrous bone *via* the middle ear and the Eustachian tube (Fig. 6). The fact that the leak may be found on the side opposite to the dripping nostril and the possible multiplicity of fistulae further complicate the matter. Considering that if the fistula does not heal spontaneously the patient is in serious danger of recurrent meningitis and that the mandatory corrective surgery will be successful only if the actual leaking site is exposed at operation, the importance of a diagnostic localizing method is obvious.

To localize the fistula responsible for the cerebrospinal fluid loss, one can use dyes, fluorescent substances, radiography, or radioactive tracers (Table IV). Dyes (methylene blue, phenolsulphophthalein, indigo carmine) have been introduced before or during surgery within the subarachnoidal spaces or intranasally for visual localization of the fistula. Fluorescein has also been used. Most of these dyes can, however, cause significant morbidity (Wolman, 1966). Tomography, pneumoencephalography, and subdural pneumography frequently provide help for the localization of the leaking break. Various attempts have been made to localize the fistula by Pantopaque injected into the subarachnoidal space (Rockett, Wittenborg, Shillito, and Matson, 1964), as well as the ventricular system, a pneumocephalic cavity, and intranasally (Teng and Edalatpour, 1963). After the injection of Pantopaque the passage of the opaque material is observed with fluoroscopy and radiography. However, this contrast medium causes meningeal irritation. In 1956 (Crow, Keogh, and Northfield, 1956), the use of radioactive sodium

(Na<sup>24</sup>) was suggested. This tracer was injected into the cisterna magna and cotton pledgets ('patties'), conveniently distributed in the walls and roof of the nose and nasopharynx and upon the openings of the Eustachian tubes, were afterwards examined with a counter. The cotton patty showing the highest radioactivity indicated the site of leakage. A similar isotope-counting technique has been reported employing RISA. Isotope-cisternography has been introduced by one of us (Di Chiro) and has been used successfully in many cases of traumatic and non-traumatic cerebrospinal fluid rhinorrhœa. The technique and results have been previously reported (Di Chiro, Reames, and Matthews, 1964; Di Chiro and Grove, 1966; Ommaya, 1966). In Table V the tracers used for isotope-cisternography and ventriculography are listed. Limiting ourselves to non-traumatic cerebrospinal fluid rhinorrhœa, we feel that a combination of accurate radiographic studies and isotope-cisternography give the best results. Plain radiographs may demonstrate air-fluid levels within the sphenoidal sinus (two of our cases) as well as reveal an enlarged sella turcica. With tomography a bone defect may be demonstrated (one of our cases). At pneumoencephalography a dilated intrasellar subarachnoid space may be put in evidence (two of our cases). The intrasellar subarachnoid pocket (Busch, 1951; Engels, 1958), acting as a tense pulsating cyst, is probably responsible for a break in the sellar floor. The pneumoencephalogram is essential to decide between such a cyst and a pituitary adenoma. In addition, air studies permitted us in one of our cases to make the tentative diagnosis of direct third ventricle-cisternal-sphenoidal sinus communi-

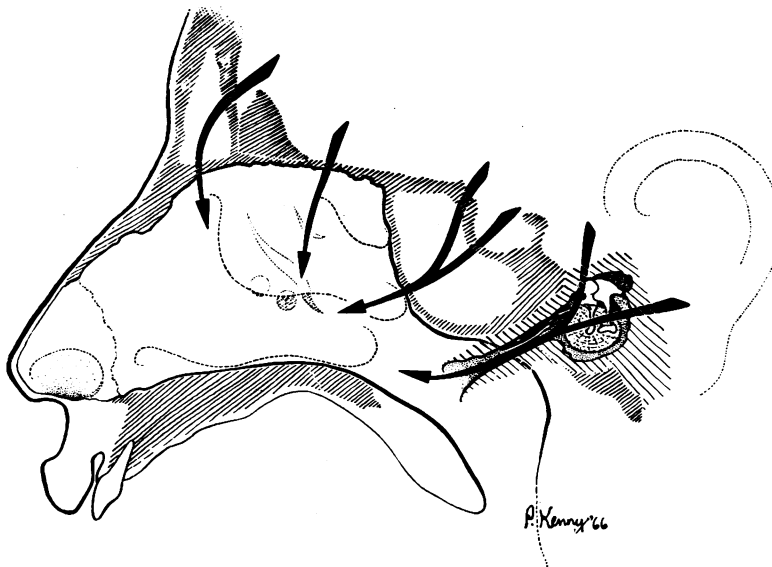


FIG. 6. Common pathways of cerebrospinal fluid leakage.

TABLE IV  
DIAGNOSTIC PROCEDURES FOR LOCALIZATION OF  
CEREBROSPINAL FLUID LEAKS

|   |  |
|---|--|
| I. Dyes                                 | methylene blue<br>phenolsulfonphthalein<br>indigo carmine<br>fluorescein         |
| II. Photoluminescent<br>substance       |  |
| III. X-rays                             | plain tomography<br>pneumoencephalography<br>subdural pneumography<br>Pantopaque |
| IV. Isotope-counting                    | Na <sup>24</sup><br>RISA   |
| V. Isotope-scanning<br>(Cisternography) | See Table V  |

TABLE V  
TRACERS FOR ISOTOPE-CISTERNOGRAPHY AND  
VENTRICULOGRAPHY

*Macaca Mulatta:*  
<sup>131</sup>I rose bengal (<sup>80</sup>).

*Homo Sapiens:*  
1) Colloidal <sup>199</sup>Au (<sup>25,26,80</sup>)  
2) Autologous <sup>131</sup>I-tagged CSF (<sup>27</sup>)  
3) Low protein RISA (<sup>26,27,29,32</sup>)  
(10 mg/ml. fresh—sp. act. 500 µc/ml.)

|   |                        |
|---|------------------------|
| Lumbar  | Intraventricular       |
| Within surgical shunts ( <sup>31</sup> )                        |                        |
| 4) <sup>99m</sup> Tc pertechnetate ( <sup>31</sup> )            |                        |
| Intraventricular  | Within surgical shunts |
| 5) <sup>99m</sup> Tc serum albumin ( <sup>49</sup> )            |                        |
| 6) <sup>99m</sup> Tc serum albumin with high specific activity* |                        |

\*Di Chiro: Unpublished data.

cation (Case 15 in Table III). RISA-cisternography gave, in our hands, the final diagnostic answer in all the cases (four) in which it was employed. Another great advantage of this technique is the ease with which it may be repeated to provide post-operative and follow-up verification of the efficacy of treatment with little or no discomfort to the patient.

**TREATMENT** This is primarily surgical, although non-surgical measures have resulted in successful management of such patients on rare occasions. Remission of leakage, rarely permanent, may follow lumbar puncture, meningitis, or dye injection. Long-term medical management with antibiotics has been reported to be possible (Anderson, Schwarz, and Gammon, 1961), but with the increasing number of resistant organisms this conservative therapy becomes hard to justify. Repeated lumbar punctures have been tried and recommended but may now be considered an obsolete method. Similarly x-ray therapy to the site of the fistula is of no value. Instillation of substances nasally to promote closure of the fistula from below—for example, silver nitrate—has not been successful, but a recent cure of

a cerebrospinal fluid rhinorrhoea has been reported following the application of Eastman 9-10 glue to the roof of the ethmoid sinus (Gotham *et al.*, 1965). It is often recommended that following the identification of cerebrospinal fluid in a rhinorrhoea, expectant treatment, including nursing in a semi-Fowler position, discouragement of nose blowing, sneezing and straining, and antibiotic administration, be tried for six to eight weeks before surgery is considered. While it is true that the majority of cases of cerebrospinal fluid rhinorrhoea, particularly the traumatic variety, will stop leaking, it would be risky to suggest that this conservative therapy be adopted routinely. Indeed, the occurrence of repeated attacks of meningitis after spontaneous closure of such fistulae, even in the absence of obvious leakage of fluid (Schneider and Thompson, 1957), would support a more active approach to some of these patients. Thus in non-traumatic cerebrospinal fluid rhinorrhoea a conservative attitude is probably justifiable only in those patients with high pressure leaks in whom the causal lesion cannot be removed. This was the initial management of our Case 15 in Table III. However, after apparently complete regression of her adenocarcinoma following deep x-ray therapy, her fistula was closed intracranially to prevent recurrent meningitis. In normal pressure leaks surgical repair of the fistula is usually easy and is to be recommended as soon as the diagnosis is established.

Surgical techniques to repair such fistulae are numerous but may be considered briefly under two heads. First, the extracranial, usually transnasal, approach, and, secondly, the intracranial approach. The extracranial, extra-nasal approach to fistulae through the frontal and ethmoidal sinuses has been recently recommended by Aboulker, Le Beau, Sterkers, and Elbaz (1966). Mennig (1964) has described a trans-ethmoidal trans-sphenoidal approach to repair a fistula through the floor of the sella turcica which was successful after an intracranial attempt at closing the leak had failed. A recent review of such extracranial techniques is by Vrabec and Hallberg (1964). In our opinion, such extracranial techniques should be reserved for the carefully selected patient in whom the aetiology of the leakage has been clearly understood, the fistula track demonstrated, and in whom the intracranial methods cannot be undertaken for definite reasons. The rationale for this opinion is that cerebrospinal fluid rhinorrhoea is not simply a matter of closure of the bony defect but, more importantly, necessitates repair of the meningeal defects. Such meningeal repairs are best conducted after adequate inspection intradurally, and rhinological procedures seldom provide an adequate view within the dura mater.

The intracranial procedures have been adequately

described (Dandy, 1944) and only a few comments are necessary. As stated before, the crucial factor in adequate surgical treatment is closure of the meningeal defect. This is often quite small in non-traumatic leaks and easy to overlook. Some neurosurgeons have resorted to filling the craniotomy site with saline and with the help of the anaesthesiologist obtain a visual demonstration of the hole by forcing air from the nasopharynx into the exposure area where the escape of bubbles may be seen. However, with accurate pre-operative diagnosis, this manoeuvre with its attendant risk of sepsis may be avoided. After demonstration of the meningeal defect, the patient's own fascia, pericranium, muscle, or strips of gelfoam may be used to provide the intradural repair, with fascia being the most satisfactory. It is not essential to strip the dura and display small bony defects and attempt to seal them with bone wax, acrylic cements, or other substances. This is necessary only where the bony defect is large enough to necessitate support of the intradural graft. In such cases methyl methacrylate is a satisfactory caulking material. In summary, the intracranial, intradural approach is recommended for all non-traumatic cerebrospinal fistulae with careful 'patching' of the fistula site, preferably using the patient's own tissues as free grafts. Sealing of subjacent bony defects is required only when the hole is of significant size—for example, greater than 2 mm in diameter. In high pressure leaks, removal or by-pass of the tumour or obstruction should always precede repair of the fistula, which should be carried out only where it is positively established that a 'safety-valve' function is no longer required. In normal pressure leaks, obliteration of the arachnoid hernia should accompany careful intradural repair of the fistula. It is hoped that optimum management for every case of non-traumatic cerebrospinal fluid rhinorrhœa may be achieved by consideration of these facts.

## SUMMARY

We have reviewed our experience with 18 cases of non-traumatic cerebrospinal fluid rhinorrhœa. A new classification eliminating the terms 'primary' and 'secondary spontaneous' rhinorrhœa is offered. Two main categories are recognized: high pressure leaks (10 patients), primarily due to tumours, and normal pressure leaks (eight patients) in which congenital anomalies and 'focal atrophy' are aetiologically significant. The latter concept is fully explained in the text. Details of the mechanics of fistula formation, diagnosis, and treatment of such patients are

presented. Particular emphasis is placed on the role of isotope cisternography in localization of such cerebrospinal fluid fistulae.

## REFERENCES

- Aboulker, P., Le Beau, J., Sterkers, J. M., and Elbaz, P. (1966). Traitement des fistules méningées ethmoïdo-frontales. *Ann. Oto-laryng. (Paris)*, **83**, 27-32.
- Anderson, W. M., Schwarz, G. A., and Gammon, G. D. (1961). Chronic spontaneous cerebrospinal rhinorrhœa. *Arch. intern. Med.*, **107**, 723-731.
- Bateman, G. H. (1966). Experiences with cerebrospinal fluid rhinorrhœa arising from the pituitary fossa. *Proc. roy. Soc. Med.*, **59**, 169-174.
- Busch, W. (1951). Die Morphologie der Sella turcica und ihre Beziehungen zur Hypophyse. *Virchows Arch. path. Anat.*, **320**, 437-458.
- Crow, H. J., Keogh, C., and Northfield, D. W. C. (1956). The localization of cerebrospinal-fluid fistulae. *Lancet*, **2**, 325-327.
- Dandy, W. E. (1944). Treatment of rhinorrhœa and otorrhœa. *Arch. Surg.*, **49**, 75-85.
- Di Chiro, G., and Grove, A. S., Jr. (1966). Evaluation of surgical and spontaneous cerebrospinal fluid shunts by isotope scanning. *J. Neurosurg.*, **24**, 743-748.
- , Reames, P. M., and Matthews, W. B., Jr. (1964). RISA-ventriculography and RISA-cisternography. *Neurology (Minneapolis)*, **14**, 185-191.
- Engels, E. P. (1958). Roentgenographic demonstration of a hypophysical subarachnoid space. *Amer. J. Roentgenol.*, **80**, 1001-1004.
- Gadeholt, H. (1964). The reaction of glucose-oxidase test paper in normal nasal secretion. *Acta oto-laryng. (Stockh.)*, **58**, 271-272.
- Gotham, J. E., Meyer, J. S., Gilroy, J., and Bauer, R. B. (1965). Observations on cerebrospinal fluid rhinorrhœa and pneumocephalus. *Ann. Otol. (St. Louis)*, **74**, 215-233.
- Mennig, H. (1964). Heilung einer schwierigen Liquoristel durch rhinochirurgisches Vorgehen. *Z. Laryng. Rhinol.*, **43**, 412-419.
- Nori, A., and Carteri, A. (1964). Rinoliquorrea: Trattamento e risultati a distanza. *Chir. ital.*, **16**, 161-165.
- O'Connell, J. E. A. (1953). The cerebrospinal fluid pressure as an aetiological factor in the development of lesions affecting the central nervous system. *Brain*, **76**, 279-298.
- (1964). Primary spontaneous cerebrospinal fluid rhinorrhœa. *J. Neurol. Neurosurg. Psychiat.*, **27**, 241-246.
- Ommaya, A. K. (1964). Cerebrospinal fluid rhinorrhœa. *Neurology (Minneapolis)*, **15**, 107-113.
- (1966). Trauma to the nervous system. Hunterian Lecture. *Ann. Roy. Coll. Surg. Eng.*, **39**, 317-347.
- Raskind, R. (1965). Cerebrospinal fluid rhinorrhœa and otorrhœa: Diagnosis and treatment in 35 cases. *J. int. Coll. Surg.*, **43**, 141-154.
- Rockett, F. X., Wittenborg, M. H., Shillito, J., Jr., and Matson, D. D. (1964). Pantopaque visualization of a congenital dural defect of the internal auditory meatus causing rhinorrhœa: Report of a case. *Amer. J. Roentgenol.*, **91**, 640-646.
- Schneider, R. C., and Thompson, J. M. (1957). Chronic and delayed traumatic cerebrospinal rhinorrhœa as a source of recurrent attacks of meningitis. *Ann. Surg.*, **145**, 517-529.
- Teng, P., and Edalatpour, N. (1963). Cerebrospinal fluid rhinorrhœa with demonstration of cranionasal fistula with Pantopaque. *Radiology*, **81**, 802-806.
- , and Papatheodorou, C. (1965). Cerebrospinal rhinorrhœa and otorrhœa. *Arch. Otolaryng.*, **82**, 56-61.
- Thomson, St. C. (1899). *The Cerebrospinal Fluid; Its Spontaneous Escape From the Nose*. Cassell, London.
- Voena, G. (1959). Considerazioni su un caso di grave cranio-rinoliquorrea da persistenza del canale basi-occipitale. *Arch. ital. Otol.*, **70**, 212-222.
- Vrabec, D. P., and Hallberg, O. E. (1964). Cerebrospinal fluid rhinorrhœa. *Arch. Otolaryng.*, **80**, 218-229.
- Wolman, L. (1966). The neuropathological effects resulting from the intrathecal injection of chemical substances. *Paraplegia*, **4**, 97-115.