

The Ultrasonographic Determination of the Position of the Mental Foramen and its Relation to the Mandibular Premolar Teeth

ABDULLAH EBRAHIM LAHER¹, FEROZA MOTARA², MUHAMMED MOOLLA³

ABSTRACT

Introduction: The position of the mental foramen has been well researched in cadaver specimens, radiographically as well as intraoperatively. To our knowledge, this landmark study is the first to make use of ultrasonography in a study population to determine the position of the mental foramen in relation to the mandibular premolar teeth. Ultrasonography has great potential to further revolutionize the practice of medicine and dento-maxillofacial surgery.

Aim: To make use of ultrasound to determine the position of the mental foramen and its relation to the mandibular premolar teeth.

Materials and Methods: One hundred Black and Caucasian subjects were enrolled. A high frequency (8MHz) transducer (PLF.805ST) of a diagnostic ultrasound system (model SSA-510A) was applied above the inferior border of the mandible, just lateral to the mentum. With the marker of the transducer pointing cranially, the position of the mental foramen in relation to the closest mandibular premolar tooth was determined. The position was compared across race, sex and age groups.

Results: All mental foramina (100%) were visualised. Overall the most frequent position of the mental foramen was in line

with the long axis of the second premolar on the right (44%) and between the first and second premolars on the left (44%). There were no statistical differences ($p > 0.05$) between race groups, sex and age groups with regard to the position of the mental foramen in relation to the mandibular premolars. However, in Blacks, the most frequent position of the mental foramen was in line with the long axis of the second premolar and in Caucasians the most common position was between the first and second premolars. The most frequent position of the mental foramen in females was in line with the long axis of the second premolar on the right and between the first and second premolars on the left. In males, the most frequent position of the mental foramen was in line with the long axis of the second premolar bilaterally. The most common position of the mental foramen in the age group category 18-30 years was between the first and second premolars. In patients aged 31-60 years the most frequent position was in line with the long axis of the second premolar.

Conclusion: Ultrasound is a sensitive modality to locate the mental foramen. There are differences in the most common position of the mental foramen with regard to the long axis of the premolar teeth. Ultrasonography has the potential to revolutionize the practice of dento-maxillofacial surgery.

Keywords: Mental nerve, Ultrasound, Emergency medicine, Dentistry

INTRODUCTION

The mental foramen is located on either side of the mandible just below the corners of the lips around the region of the root of the second premolar tooth. The mental nerve and associated blood vessels emerge from the mental foramen. The mental nerve provides sensation to the lower central portion of the face [1,2]. Dentists, oral maxillofacial surgeons, emergency physicians and plastic and reconstructive surgeons are required to be knowledgeable regarding the anatomy of the mental foramen and variations in its position for the purposes of achieving local anaesthesia as well as the planning of various surgical procedures [3].

The position of the mental foramen has been well researched in cadaver specimens, radiographically as well as intraoperatively [4-6]. Thus far panoramic radiographs, periapical radiographs, Magnetic Resonance Imaging (MRI), Conebeam Computed Tomography (CBCT), Spiral Computed Tomography (SCT) and Multi Slice Computed Tomography (MSCT) have all been studied by clinicians to determine the position of the mental foramina [7-12]. Limitations with these modalities include radiation exposure and resultant increased risk of malignancy, increased cost, increased time and the possibility of not detecting the mental foramen [13,14]. Many of these modalities are also not readily available in the developing country setting as well as in lower level of care facilities. The mental foramen and the various modalities

useful in locating the mental foramen have been reviewed in detail elsewhere [15].

Ultrasonography, regarded as the 21st century stethoscope in the Emergency Department (ED) [16], is a cost-effective, time saving, non-invasive, safe modality with no risk of radiation exposure [13]. It has many uses in the Emergency Department including regional nerve block anaesthesia and can be used as a diagnostic as well as an interventional tool [17]. Theoretically the use of ultrasonography for mental nerve blocks would decrease local anaesthetic requirements, increase first time success rates and decrease complication rates. To our knowledge, this study is the first to make use of ultrasonography in a study population to determine the position of the mental foramen in relation to the mandibular premolar teeth. Ultrasonography has great potential to further revolutionize the practice of medicine and dento-maxillofacial surgery.

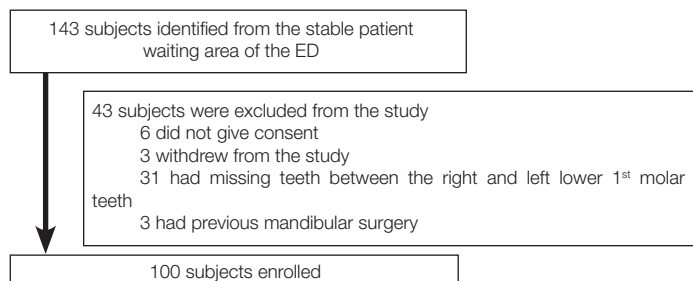
MATERIALS AND METHODS

Study design and patient assessment

This prospective, cross-sectional observational study was conducted in a single centre ED (Charlotte Maxeke Johannesburg Academic Hospital (CMJAH), Johannesburg, South Africa) between February 2012 and March 2013. CMJAH is a tertiary

care facility in a large urban environment and is affiliated with the University of the Witwatersrand.

We enrolled a convenience sample of 100 Adult Black and Caucasian (White and Asian) patients, older than 18 years that presented to the CMJAH ED. These patients had passed through the hospital's triage system and did not require urgent or emergent treatment. Patients did not present with pathology requiring a mental nerve block. Individuals with congenital/acquired facial distortion, a history of mandibular surgery and patients who had mandibular teeth missing between the right and left lower 1st molars



[Table/Fig-1]: Exclusions and final sample for analysis.

were excluded from the study. Details of patient recruitment and exclusion are listed in the flow diagram in [Table/Fig-1].

Subjects were enrolled in the study and written informed consent was obtained. Confidentiality was respected at all times. Data collection sheets did not include personal data. Only relevant demographic data was included. The information gathered was protected by a coded numbering system, which was stored in a password-protected computer that was only accessible to the researchers. Permission to conduct the study was obtained from the Head of Department (HOD) of the CMJAH ED and the hospital management. Clearance was obtained from the Human Research Ethics Committee of the University of the Witwatersrand (certificate no. M110920).

All ultrasound examinations and data collection was conducted by the primary investigator who is emergency ultrasound certified by College of Emergency Medicine of South Africa (official specialist certification body in South Africa). The research was fully supervised by a faculty member of the division of emergency ultrasound of the College of Emergency Medicine of South Africa. Patients were randomly selected from the queue at a time convenient to the researcher. The last patient waiting in the queue was approached first and so on, so as not to increase patient waiting times. Potential participants were given an information leaflet.

Individuals who volunteered to participate in the study were asked to follow the researcher to a private cubicle. Participants were then questioned regarding exclusion criteria. Individuals who were not eligible to participate were thanked and taken back to their place in the queue. Eligible volunteers, who agreed to participate, were requested to sign informed consent. They were then allocated a participant number to maintain anonymity. The investigation was carried out in the supine position. We used a Toshiba diagnostic ultrasound system (model SSA-510A, serial no. P3C06X5875) and a high frequency (8MHz) transducer (PLF.805ST) with the machine set on the "small parts" preset mode. Sonar gel was applied to the ultrasound transducer once the machine was in running mode. The transducer, with the marker pointing to the participant's head (cranially), was gently applied above the inferior border of the mandible and just lateral to the mentum. The mental foramen was identified under ultrasound guidance and its relation to the closest mandibular premolar tooth recorded. The mental foramen is easily identified in this region as a break in the continuity of the bone [Table/Fig-2]. There are no other similar ultrasonographic structures that can be confused with the mental foramen in this vicinity. The above procedure was repeated on the opposite side

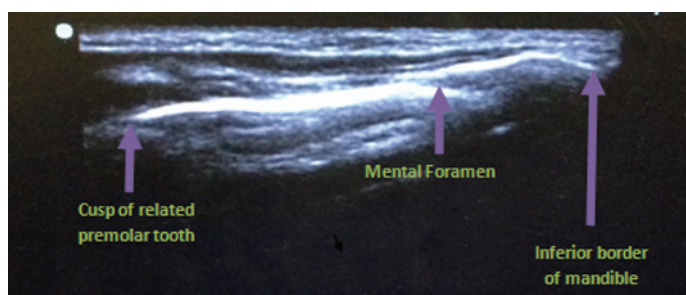
of the face. After documenting relevant data, excess gel was gently cleaned off and the volunteer thanked. All volunteers, as far as possible, maintained their position in the queue waiting to see their clinician. Any difficulties experienced during the investigation were documented.

STATISTICAL ANALYSIS

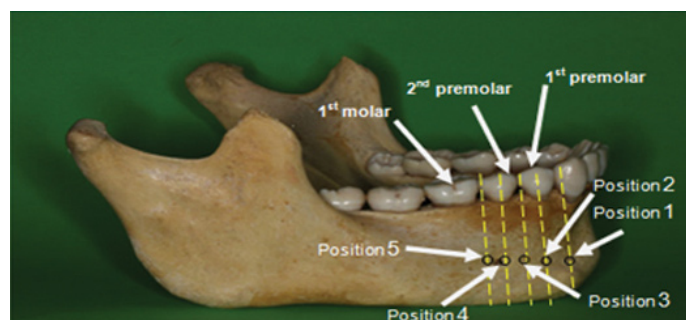
All data was captured from the data collection sheets by the primary investigator and entered into an electronic spreadsheet (Microsoft® Excel®). STATA® version 12.1 software (StataCorp LP) was used to analyze all data. Each volunteer was placed in an age category: a) 18-30 years; b) 31-40 years; c) 41-50 years; d) 51-60 years; e) 61-70 years. A cross table was used to compare race, gender and age with the position of the mental foramen. The Fisher's-exact test was used to assess for relationships between two categorical variables (positions 1 – 5 versus age group, gender, and race). Study reporting conformed to STROBE guidelines [18].

RESULTS

The total sample of 100 subjects consisted of 50 Blacks (27 males and 23 females) and 50 Caucasians (23 males and 27 females). The Caucasians were further subdivided into 25 Asians (13 males and 12 females) and 25 Whites (10 males and 15 females). The overall sex distribution was equal (50 males and 50 females). The overall mean age of the study population was 35.7 years (SD 1.9 years). Sixty nine percent of subjects were under the age of 40 years and only 2% of subjects were older than 60 years. The reason that most of our subjects were under 40 years of age is due to the fact that with advancement in age, the incidences of missing teeth between the right and left mandibular 1st molars are higher. Twenty-two patients older than 60 years were excluded from the study as they had missing teeth between the right and left 1st mandibular molars. All mental foramina (100%) were ultrasonographically identified. The position of the mental foramen was described as: Position 1 - mesial to the 1st premolar; Position 2 - in line with the long axis of the 1st premolar; Position 3 - between 1st and 2nd premolars; Position 4 - in line with the long axis of the 2nd premolar and Position 5 - lateral to 2nd premolar.



[Table/Fig-2]: Ultrasound image of the mental foramen and its hard tissue relations. The mental foramen is easily identified as a break in the continuity of the bone between the corner of the mouth and the inferior border of the mandible.



[Table/Fig-3]: Dry mandible specimen and the various possible positions of the mental foramen (black circles) and its vertical relationship to the long axis of the mandibular teeth (yellow lines).

Position 1- mesial to 1st premolar. Position 2- in line with the long axis of the 1st premolar. Position 3-between 1st and 2nd premolar. Position 4- in line with the long axis of the 2nd premolar. Position 5-lateral to 2nd premolar.

	Position 1	Position 2	Position 3	Position 4	Position 5	Statistical Significance (Fisher's-exact test)
Entire group R	1%	12%	41%	44%	2%	N/A
Entire group L	1%	9%	44%	43%	3%	
Blacks R	0%	8%	36%	52%	4%	p = 0.26
Asians R	4%	12%	40%	44%	0%	
Whites R	0%	20%	52%	28%	0%	
Blacks L	0%	6%	38%	50%	6%	p = 0.12
Asians L	4%	8%	40%	48%	0%	
Whites L	0%	16%	60%	24%	0%	
Males R	2%	8%	42%	46%	2%	p = 0.77
Females R	0%	16%	40%	42%	2%	
Males L	2%	4%	44%	46%	4%	p = 0.39
Females L	0%	14%	44%	40%	2%	
18-30 years R	2.5%	12.5%	47.5%	35%	2.5%	p = 0.52
31-40 years R	0%	6.9%	44.8%	48.3%	0%	
41-50 years R	0%	18.7%	25%	50%	6.3%	
51-60 years R	0%	7.7%	30.8%	61.5%	0%	
61-70 years R	0%	50%	50%	0%	0%	
18-30 years L	2.5%	10%	50%	35%	2.5%	p = 0.14
31-40 years L	0%	3.4%	48.3%	48.3%	0%	
41-50 years L	0%	18.8%	18.8%	50%	12.4%	
51-60 years L	0%	0%	46.1%	53.9%	0%	
61-70 years L	0%	50%	50%	0%	0%	

[Table/Fig-4]: The impact of race, sex and age group on the position of the mental foramen with regard to hard tissue relations.

R - Right mental foramen position, L - Left mental foramen position, VR - Vertical hard tissue relation on the right side, VL - Vertical hard tissue relation on the left side, Position 1 - mesial to 1st premolar, Position 2 - in line with the long axis of the 1st premolar, Position 3 - between 1st and 2nd premolars, Position 4 - in line with the long axis of the 2nd premolar, Position 5 - lateral to 2nd premolar.

[Table/Fig-3] describes the various possible positions of the mental foramen and its vertical relationship to the long axis of the mandibular teeth. [Table/Fig-4] describes the impact of race, sex and age on the position of the mental foramen with regard to the long axis of the mandibular teeth. Fisher's exact test was used to assess for statistical significant for all comparisons.

Overall the most frequent position of the mental foramen in relation to vertical hard tissue landmarks was at position 4 on the right (44%) and position 3 on the left (44%). They were closely followed by position 3 on the right (41%) and position 4 on the left (43%). In 4% or less of subjects, the mental foramen was located at position 1 (mesial to the 1st premolar) and position 5 (lateral to the 2nd premolar).

There were no statistically significant differences ($p > 0.05$) between race groups with regard to the position of the mental foramen in relation to the mandibular premolars on both the right and left sides. In Blacks, the most frequent position of the mental foramen was at position 4 on the right (52%) and left (50%) sides. The second most common position was at position 3 with a frequency of 36% on the right and 38% on the left side. In Asians, the most frequent position of the mental foramen was found to be slightly more frequently at position 4 on the right (44%) and left (48%) sides, then at position 3 with a frequency of 40% on both the right and left sides. In Whites, the most frequent position of the mental foramen was at position 3, on the right (52%) and left (60%) sides. The second most common position was at position 4 with a frequency of 28% on the right and 24% on the left.

There were no statistically significant differences between females and males with regard to the position of the mental foramen and its relation to the mandibular premolars on both the right and left sides ($p=0.766$ and $p=0.387$ respectively). The most frequent

position of the mental foramen in females was at position 4 on the right (42%) and position 3 on the left (44%) side. The second most common position was at position 3 on the right with a frequency of 40% and position 4 on the left with a frequency of 40%. The most frequent position of the mental foramen in males on the right was at position 4 (46%) and then position 3 at 42%. On the left it was most frequently found at position 4 (46%) and then position 3 at 44%.

There were no statistically significant differences ($p > 0.05$) between the various age categories with regard to the position of the mental foramen in relation to the mandibular premolars on both the right and left sides. The most common position of the mental foramen in subjects in the age group category 18-30 years was at position 3 on the right and left sides. In patients aged 31-60 years position 4 was the most common position, with higher frequencies of subjects at position 4 with advancement of age. In 4% or less of patients, the mental foramen was positioned at position 1 or 5 on both the right and left sides.

DISCUSSION

The position of the mental foramen and its relation to the long axis of the mandibular premolars has been well described in the literature [1,2,10,19,20]. To our knowledge, this landmark study is the first to make use of ultrasonography in a study population to determine the position of the mental foramen.

We did not find any statistically significant differences between race groups, gender and age categories with regard to the position of the mental foramen in relation to the mandibular premolars on both the right and left sides ($p > 0.05$ for all categories).

However, in Blacks the most common position was in line with the long axis of the second mandibular premolar (52% on the right and 50% on the left). In Asians, the most frequent position of the mental foramen was found slightly more frequently in line with the long axis of the 2nd mandibular premolar (44% on the right and 48% on the left) followed closely by position 3, which is between the 1st and 2nd mandibular premolars (40% on either side). In Whites, the most frequent position of the mental foramen was between the 1st and 2nd mandibular premolars on the right (52%) and left (60%) sides.

[Table/Fig-5] Summarizes the most common position of the mental foramen in various population groups previously studied [1,2,5,6,19-41].

Overall, in only 3% of cases on the right and 4% of cases on the left, the mental foramen was found to be mesial to the 1st premolar or lateral to the 2nd premolar. When the mental foramen was found mesial to the 1st premolar, frequencies of between 1% and 5% have been reported in the literature [1,5,26,42]. Frequencies of between 4% and 51.5% have been reported for the position lateral to the 2nd premolar [1,10,22,42,43]. Shah and colleagues in their study commented that the mental foramen lies either mesial to the first premolar or lateral to the first molar in only 1-2% of cases [44].

A limitation to our study is that we excluded patients with congenital / acquired facial distortion, patients with a history of mandibular surgery and patients who had mandibular teeth missing between the right and left lower 1st molars. Perhaps the mental foramen may not have been as easily found with ultrasonography in these patients as a result of positional change or distortion of the mental foramen. Chrcanovic et al., reported a change in the position of the mental foramen with age and loss of teeth. With loss of teeth and resultant bone resorption, the alveolar crest shifts downwards and closer to the mental foramen [45]. Another study reported that the mental foramen was situated at an average of 3.8mm lower in edentulous jaws than in dentulous jaws with respect to a superior reference point (the alveolar crest) [46]. A study in Hong Kong

Author	Year	Population group	Race	Study size	Study method	Most common position*
Africa – North to South						
Mbajjorgu E et al., [20]	1998	Zimbabwean	Black	32	Cadaver	B
Igbigbi P et al., [21]	2005	Malawian	Black	70	Cadaver	B
Fabian F [22]	1976	Tanzanian	Black	100	Cadaver	B
Mwaniki D et al., [23]	1992	Kenyan	Black	79	Cadaver	B
Olasoji H et al., [19]	2004	Nigerian	Black	157	PR	A
Asia – East to West						
Kim I et al., [6]	2006	Korean	Asian	112	Intra-op and PR	B
Green R [24]	1987	Chinese	Asian	87	Cadaver	B
Guo J et al., [25]	2009	Chinese	Asian	21	Cadaver	B
Ngeow W et al., [26]	2003	Malaysian	Asian	169	PR	B
Neo J [5]	1989	Singaporean	Asian	158	PR	B
Shankland W [27]	1994	Indian	Asian	69	Cadaver	B
Sankar D et al., [28]	2011	Indian	Asian	90	Cadaver	A
Udhaya K et al., [29]	2013	Indian	Asian	90	Cadaver	B
Gada S et al., [30]	2014	Indian	Asian	300	PR	A
Haghanifar S et al., [2]	2009	Iranian	Asian	400	PR	A
Khojastepour L et al., [31]	2015	Iranian	Asian	156	CBCT	B
Al Jasser N et al., [32]	1998	Saudi Arabian	Asian	414	PR	B
Al-Khateeb T et al., [1]	2007	Jordanian	Asian	860	PR	A
Europe & North America – East to west						
Aktekin M et al., [33]	2003	Turkish	White	58	Cadaver	A
Yesilyurt H et al., [34]	2008	Turkish	White	70	Cadaver	B
Kqiku L et al., [35]	2013	Kosovarian	White	500	PR	A
Smajilagic A et al., [36]	2004	Bosnian	White	20	Cadaver	B
Voljevica A et al., [37]	2015	Bosnian	White	150	Cadaver	B
Phillips J et al., [38]	1992	North American	White	75	PR	B
Moiseiwitsch J [39]	1998	North American	White	105	Cadaver	A
Pria C et al., [40]	2011	North American	White	500	PR	A
South America						
Chu R et al., [41]	2014	Brazilian		191	Cadaver	A

[Table/Fig-5]: Summary of the various population groups reviewed with regard to the position of the mental foramen.

PR – panoramic radiograph, CT – computed tomography, CBCT – cone beam computed tomography

* Most common position in relation to the mandibular premolar teeth: A – between the 1st and 2nd premolars; B – in line with the long axis of the 2nd premolar.

found there to be a significant correlation between tooth wear and position of the mental foramen [4]. Since only two subjects in our study were older than 60 years, we cannot fully comment on the effect of ageing on the position of the mental foramen.

Earlier studies [Table/Fig-5] used various methods such as cadaver specimens, various radiological modalities as well as intraoperative studies to determine the location of the mental foramen. In terms of radiological modalities, panoramic radiographs, periapical radiographs, Magnetic Resonance Imaging (MRI), Cone Beam Computed Tomography (CBCT), Spiral Computed Tomography (SCT) and Multi Slice Computed Tomography (MSCT) have all been studied by clinicians to determine the position of the mental foramina [7-12].

Periapical and panoramic radiographic techniques have their limitations. Linear measurements may need to be corrected for rotation and radiographic distortion [14]. In a study by Bou and colleagues, there was a tendency for panoramic radiographs to

overestimated distances when compared to spiral or computed tomography [7]. Panoramic X-rays also distort the position of the mental foramen as they do not take curvatures and angling of the mandible into account [6,38,47]. Size reduction through compression has also been shown to effect image quality [48]. In contrast, in the study by Phillips et al., on PR's there was a 23% increase in size and a distal shift of the mental foramen [38]. Forni et al., also found that images on panoramic radiographs were magnified by 36.6% compared to computed tomography [49]. Periapical and panoramic radiographs are also limited in their ability to detect the mental foramen. Two studies in this line only detected the mental foramen in 84% and 94% of panoramic radiographs respectively [14,50] and the second of these studies commented that only 49% of mental foraminae were clearly visible [14]. With periapical views, the yield is even lower. A study conducted by Fishel et al., using periapical films reported that the mental foramen was detected in only 46.8% of cases [51]. In contrast our study detected the mental foramen, bilaterally in all enrolled subjects. This suggests that ultrasound may be more sensitive than periapical and panoramic radiographs in detecting the mental foramen. With regard to other radiological modalities, CBCT was superior to MSCT in detecting the mental foramen and also used lower radiation doses [11]. Another study found MRI to be more accurate than CBCT in determining the position of the mental foramen and nerve [9]. The drawback with these modalities is much higher radiation doses, increased cost, the need for a radiology service and extra time taken to transport the patient to the radiology department and to carry out the investigation.

Ultrasound

Ultrasonography is a cost effective, safe, time saving, non-invasive modality with no risk of radiation exposure and can be performed at the bedside. It may be used as a diagnostic as well as an interventional tool in medicine [13,16]. Its use in anaesthesia and the emergency department for regional nerve block anaesthesia has been well described [37]. Another potential benefit is that the mental nerve may be blocked under direct vision, using real time ultrasound guidance as a tool. This would increase first time success rates, decrease failure rates and decrease the chances of neurological injury in trained and experienced hands [17].

Traxler et al., used ultrasound to determine the alveolar ridge width for purposes of dental implants. He also commented that ultrasound provided accurate information about the position of the mental foramen, as a secondary finding [52].

A limitation to the use of ultrasound is the fact that ultrasonography is operator dependent [16]. Therefore all ultrasound examinations and data collection was conducted by the primary investigator who is emergency ultrasound certified by the College of Emergency Medicine of South Africa. The study was fully supervised by a faculty member of the division of emergency ultrasound of the College of Emergency Medicine of South Africa.

CONCLUSION

In conclusion, point of care/hand held ultrasound devices and recent developments in 3D ultrasound have the potential to revolutionize the practice of dento-maxillofacial surgery. Further studies using ultrasound to locate not only the mental foramen, but also other clinically important related anatomy in the vicinity are required.

REFERENCES

- [1] Al-Khateeb T, Al-Hadi Hamasha A, Ababneh KT. Position of the mental foramen in a northern regional Jordanian population. *Surg Radiol Anat.* 2007;29(3):231-37.
- [2] Haghanifar S, Rokouei M. Radiographic evaluation of the mental foramen in a selected Iranian population. *Indian J Dent Res.* 2009;20(2):150-52.
- [3] Song W-C, Kim S-H, Paik D-J, Han S-H, Hu K-S, Kim H-J, et al. Location of the infraorbital and mental foramen with reference to the soft-tissue landmarks. *Plast Reconstr Surg.* 2007;120(5):1343-47.

- [4] Green RM, Darvell BW. Tooth wear and the position of the mental foramen. *Am J Phys Anthropol.* 1988;77(1):69–75.
- [5] Neo J. Position of the mental foramen in Singaporean Malays and Indians. *Anaesth Prog.* 1989;36(6):276–78.
- [6] Kim I-S, Kim S-G, Kim Y-K, Kim J-D. Position of the mental foramen in a Korean population: a clinical and radiographic study. *Implant Dent.* 2006;15(4):404–11.
- [7] Bou Serhal C, Jacobs R, Flygare L, Quirynen M, van Steenberghe D. Perioperative validation of localisation of the mental foramen. *Dentomaxillofac Radiol.* 2002;31(1):39–43.
- [8] Cavalcanti MG, Yang J, Ruprecht A, Vannier MW. Validation of spiral computed tomography for dental implants. *Dentomaxillofac Radiol.* 1998;27(6):329–33.
- [9] Chau A. Comparison between the use of magnetic resonance imaging and conebeam computed tomography for mandibular nerve identification. *Clin Oral Implants Res.* 2012;23(2):253–56.
- [10] Kçikü L, Sivic E, Weiglein A, Städtler P. Position of the mental foramen: an anatomical study. *Wien Med Wochenschr.* 2011;161(9-10):272–73.
- [11] Liang X, Jacobs R, Hassan B, Li L, Pauwels R, Corpas L, et al. A comparative evaluation of Cone Beam Computed Tomography (CBCT) and Multi-Slice CT (MSCT) Part I. On subjective image quality. *Eur J Radiol.* 2010;75(2):265–69.
- [12] Parnia F, Moslehifard E, Hafezeqorani A, Mahboub F, Mojaver-Kahnamouei H. Characteristics of anatomical landmarks in the mandibular interforaminal region: a cone-beam computed tomography study. *Med Oral Patol Oral Cir Bucal.* 2012;17(3):e420–25.
- [13] Claudon M, Guillaume L. Diagnostic imaging and radiation hazards. *Rev Prat.* 2015;65(1):79–81.
- [14] Jacobs R, Mraiwa N, Van Steenberghe D, Sanderink G, Quirynen M. Appearance of the mandibular incisive canal on panoramic radiographs. *Surg Radiol Anat.* 2004;26(4):329–33.
- [15] Laher AE, Wells M, Motara F, Kramer E, Moolla M, Mahomed Z. Finding the mental foramen. *Surg Radiol Anat.* 2016;38(4):469–76.
- [16] Coskun F, Akinci E, Ceyhan MA, Sahin Kavakli H. Our new stethoscope in the emergency department: handheld ultrasound. *Ulus Travma Acil Cerrahi Derg.* 2011;17(6):488–92.
- [17] Wells M. Local and Regional Anaesthesia in the Emergency Department Made Easy - Elsevier. 1st ed. London: Churchill Livingstone Elsevier; 2010.
- [18] von Elm E, Altman DG, Egger M, Pocock SJ, Gøtzsche PC, Vandenbroucke JP. The Strengthening of Reporting of Observational Studies in Epidemiology (STROBE) statement: guidelines for reporting observational studies. *Lancet.* 2007;370(9596):1453–57.
- [19] Olasoji HO, Tahir A, Ekanem AU, Abubakar AA. Radiographic and anatomic locations of mental foramen in northern Nigerian adults. *Niger Postgrad Med J.* 2004;11(3):230–33.
- [20] Mbajjorgu EF, Mawera G, Asala SA, Zivanovic S. Position of the mental foramen in adult black Zimbabwean mandibles: a clinical anatomical study. *Cent Afr J Med.* 1998;44(2):24–30.
- [21] Igbigbi PS, Lebona S. The position and dimensions of the mental foramen in adult Malawian mandibles. *West Afr J Med.* 2005;24(3):184–89.
- [22] Fabian FM. Position, shape and direction of opening of the mental foramen in dry mandibles of Tanzanian adult black males. *Ital J Anat Embryol.* 1976;112(3):169–77.
- [23] Mwaniki DL, Hassanali J. The position of mandibular and mental foramina in Kenyan African mandibles. *East Afr Med J.* 1992;69(4):210–13.
- [24] Green RM. The position of the mental foramen: a comparison between the southern (Hong Kong) Chinese and other ethnic and racial groups. *Oral Surg Oral Med Oral Pathol.* 1987;63(3):287–90.
- [25] Guo JL, Su L, Zhao JL, Yang L, Lv DL, Li YQ, et al. Location of mental foramen based on soft- and hard-tissue landmarks in a Chinese population. *J Craniofac Surg.* 2009;20(6):2235–37.
- [26] Ngeow WC, Yuzawati Y. The location of the mental foramen in a selected Malay population. *J Oral Sci.* 2003;45(3):171–75.
- [27] Shankland WE. The position of the mental foramen in Asian Indians. *J Oral Implantol.* 1994;20(2):118–23.
- [28] Sankar DK, Bhanu SP, Susan PJ. Morphometrical and morphological study of mental foramen in dry dentulous mandibles of South Andhra population of India. *Indian J Dent Res.* 2011;22(4):542–46.
- [29] Udhaya K, Saraladevi KV, Sridhar J. The morphometric analysis of the mental foramen in adult dry human mandibles: a study on the South Indian population. *J Clin Diagn Res.* 2013;7(8):1547–51.
- [30] Gada SK, Nagda SJ. Assessment of position and bilateral symmetry of occurrence of mental foramen in dentate Asian population. *J Clin Diagn Res.* 2014;8(2):203–05.
- [31] Khojastepour L, Mirbeigi S, Mirhadi S, Safaee A. Location of mental foramen in a selected Iranian population: A CBCT assessment. *Iran Endod J.* 2015;10(2):117–21.
- [32] al Jasser NM, Nwoku AL. Radiographic study of the mental foramen in a selected Saudi population. *Dentomaxillofac Radiol.* 1998;27(6):341–43.
- [33] Aktekin M, Celik HM, Celik HH, Aldur MM, Aksit MD. Studies on the location of the mental foramen in Turkish mandibles. *Morphologie.* 2003;87(277):17–19.
- [34] Yesilyurt H, Aydinlioglu A, Kavakli A, Ekinci N, Eroglu C, Hacialiogullari M, et al. Local differences in the position of the mental foramen. *Folia Morphol (Warsz).* 2008;67(1):32–35.
- [35] Kçikü L, Weiglein A, Kamberi B, Hoxha V, Meqa K, Städtler P. Position of the mental foramen in Kosovar population. *Coll Antropol.* 2013;37(2):545–49.
- [36] Smajilagic A, Dilberovic F. Clinical and anatomy study of the human mental foramen. *Bosn J Basic Med Sci.* 2004;4(3):15–23.
- [37] Voljevica A, Talovic E, Hasanovic A. Morphological and morphometric analysis of the shape, position, number and size of mental foramen on human mandibles. *Acta Med Acad.* 2015;44(1):31–38.
- [38] Phillips JL, Weller RN, Kullid JC. The mental foramen: 3. Size and position on panoramic radiographs. *J Endod.* 1992;18(8):383–86.
- [39] Moiseiwitsch JR. Position of the mental foramen in a North American, white population. *Oral Surg Oral Med Oral Pathol Oral Radiol Endod.* 1998;85(4):457–60.
- [40] Pria CM, Masood F, Beckerley JM, Carson RE. Study of the inferior alveolar canal and mental foramen on digital panoramic images. *J Contemp Dent Pract.* 2011;12(4):265–71.
- [41] Chu RA, Nahas FX, Di Martino M, Soares FA, Novo NF, Smith RL, et al. The enigma of the mental foramen as it relates to plastic surgery. *J Craniofac Surg.* 2014;25(1):238–42.
- [42] Santini A, Alayan I. A comparative anthropometric study of the position of the mental foramen in three populations. *Br Dent J.* 2012;212(4):E7.
- [43] Oguz O, Bozkir MG. Evaluation of location of mandibular and mental foramina in dry, young, adult human male, dentulous mandibles. *West Indian Med J.* 2002;51(1):14–16.
- [44] Shah S, Vaze S, Kinhal K. A variation in the position of the mental foramen: a case report. *J Maxillofac Oral Surg.* 2010;9(3):307–09.
- [45] Chrcanovic BR, Abreu MHNG, Custódio ALN. Morphological variation in dentate and edentulous human mandibles. *Surg Radiol Anat.* 2011;33(3):203–13.
- [46] Soikkonen K, Wolf J, Ainamo A, Xie Q. Changes in the position of the mental foramen as a result of alveolar atrophy. *J Oral Rehabil.* 1995;22(11):831–33.
- [47] Phillips JL, Weller RN, Kullid JC. The mental foramen: 1. Size, orientation, and positional relationship to the mandibular second premolar. *J Endod.* 1990;16(5):221–23.
- [48] Yasar F, Yesilova E, Apaydin B. The effects of compression on the image quality of digital panoramic radiographs. *Clin Oral Investig.* 2012;16(3):719–26.
- [49] Forni A, Sánchez-Garcés MA, Gay-Escoda C. Identification of the mental neurovascular bundle: a comparative study of panoramic radiography and computer tomography. *Implant Dent.* 2012;21(6):516–21.
- [50] Jalili MR, Esmaeilinejad M, Bayat M, Aghdasi MM. Appearance of anatomical structures of mandible on panoramic radiographs in Iranian population. *Acta Odontol Scand.* 2012;70(5):384–89.
- [51] Fishel D, Buchner A, Hershkovith A, Kaffe I. Roentgenologic study of the mental foramen. *Oral Surg Oral Med Oral Pathol.* 1976;41(5):682–86.
- [52] Traxler M, Ulm C, Solar P, Lill W. Sonographic measurement versus mapping for determination of residual ridge width. *J Prosthet Dent.* 1992;67(3):358–61.

PARTICULARS OF CONTRIBUTORS:

1. Lecturer and Senior Consultant, University of the Witwatersrand and Charlotte Maxeke Johannesburg Academic Hospital, Johannesburg, South Africa.
2. Head of Academic and Clinical Department, University of the Witwatersrand and Charlotte Maxeke Johannesburg Academic Hospital, Johannesburg, South Africa.
3. Lecturer and Senior Consultant, University of the Witwatersrand and Charlotte Maxeke Johannesburg Academic Hospital, Johannesburg, South Africa.

NAME, ADDRESS, E-MAIL ID OF THE CORRESPONDING AUTHOR:

Dr. Abdullah Ebrahim Laher,
P.O.Box 42529, Fordsburg, Johannesburg, South Africa, 2033.
E-mail: abduallahlaher@msn.com

FINANCIAL OR OTHER COMPETING INTERESTS: None.

Date of Submission: **Jan 11, 2016**

Date of Peer Review: **Feb 05, 2016**

Date of Acceptance: **Mar 03, 2016**

Date of Publishing: **Jun 01, 2016**