

Invasive craniopharyngioma

WARREN D. GROVER¹ AND LUCY BALIAN RORKE²

From the Division of Neurosurgery and Neurology, and the Department of Pathologic Anatomy, The Children's Hospital of Philadelphia, Pennsylvania, U.S.A.

Craniopharyngiomas are relatively uncommon tumours of childhood and, although histologically benign, they produce striking clinical symptoms by compression of the optic pathways, pituitary, and hypothalamus. They may project upward into the cavity of the third ventricle, obstruct the foramina of Monro and produce hydrocephalus. Occasionally they extend posteriorly along the ventral aspect of the pons. Direct invasion of the deep gray nuclei or of the brain-stem parenchyma is extremely rare and only one such case has been reported (Iyer, 1952). It is the purpose of this communication to report a second case in which extensive invasion and destruction of the caudate, thalamus, midbrain, and pons occurred in spite of combined surgical and *x*-ray therapy.

CASE HISTORY

A 5-year-old boy was first admitted to the Children's Hospital of Philadelphia in 1954 because of frontal headaches of six months' duration. No significant physical or neurological findings were noted, and a routine skull radiograph showed only a paranasal sinusitis. A lumbar puncture was normal. He was treated with antibiotics and discharged. He returned to the hospital 10 months later because the headaches had recurred and were associated with vomiting. Neurological examination showed a slight left-sided hyper-reflexia, an equivocal wide-based gait, and bilateral papilloedema. Skull radiography revealed sutural diastasis and suprasellar calcification. A Torkildsen shunt was installed in October 1954. Post-operatively he developed meningitis.

Three months later a craniotomy was performed and approximately 95% of a solid craniopharyngioma was removed. Except for the development of diabetes insipidus he did well and he was able to resume a normal routine, including school attendance.

His third admission took place four years later in 1960 at the age of 10 years. The headache and vomiting had again recurred. Pertinent physical findings at that time included bitemporal hemianopia, decreased visual acuity, left central facial paresis, nystagmus on left lateral gaze, slight but definite dysmetria of the upper

extremities (right more than the left), and mild ataxia. Radiographic examination showed a bone age of six years. The symptoms disappeared following treatment with intravenous fluids and appropriate hormones, but the physical findings remained unchanged.

After discharge he was unable to attend school, but continued to make academic progress at his grade-level with a tutor. He was re-admitted to the hospital several times during the next two years because of recurrent vomiting, fatigability, and lethargy. The previously-noted neurological signs persisted and, in addition, there were optic disc pallor and a decreased left corneal reflex. In the fall of 1961 he was treated with 6100 r via cobalt *x*-radiation over a 46 day period. After this therapy, he did well for two years with only supplemental hormones.

His next hospital admission took place in October, 1963, because of progressive dizziness and lethargy over the previous six month period. Additional neurological findings included moderate dysarthria, deviation of the tongue to the left, bilateral intention tremor, which was more marked in the left upper extremity, and a left Babinski sign. He had mild dysgraphaesthesia and astereognosis of the left hand. Both the ataxia and the left hemiparesis had increased in severity. A radioisotope scan showed a 3 cm density in the suprasellar region and a combined pneumoventriculogram disclosed a third ventricular mass obstructing the foramina of Monro. Surgical removal was attempted, but because of extensive bleeding the procedure was terminated after removal of the bone flap. Treatment following this consisted of anti-convulsants and hormones.

The boy was hospitalized on numerous occasions over the next three years because of recurrent fever, vomiting, and dehydration. He was confined to bed during the last year of life. He became aphasic and tube feedings were necessary because of dysphagia. Before death the pupils became small and fixed. The right reacted only slightly to light and the left not at all. He was unable to adduct either eye past the midline but convergence was intact. There was generalized hyper-reflexia with bilateral Babinski signs and ankle clonus. Flexion contractures of all extremities developed.

On 23 August 1966, almost 12 years after his first operation, the patient died suddenly after a two hour period of marked respiratory distress.

Necropsy showed a well-developed boy who appeared to be much younger than his chronological age of 17 years. The testes were infantile and the body was hirsute.

¹Present address: St. Christopher's Hospital for Children, Philadelphia, Pa. U.S.A.

²Reprint requests to Dr. Rorke, Department of Pathologic Anatomy, Children's Hospital of Philadelphia, Philadelphia 19146, U.S.A.

Except for the presence of bronchopneumonia and pulmonary oedema the general necropsy findings were non-contributory.

The brain weighed 1,290 g. Fragments of rubber tubing extended from the surfaces of both occipital lobes and similar tubing was found within the cisterna magna. Examination of the base of the brain disclosed the presence of a large, dense, partially calcified multinodular mass measuring $8 \times 6 \times 6$ cm. This filled the interpeduncular space and extended deeply into the hemispheres and brain-stem. The optic nerves and chiasm as well as cranial nerve roots III to VI could not be identified. The basilar artery indented the base of the pons and disappeared into the undersurface of the tumour.

Coronal sections of the brain showed dilatation of the anterior horns of the lateral ventricles. Remnants of the rubber catheters were found in the ventricles. At the level of the anterior limb of the internal capsule, the left caudate nucleus was replaced by a cystic cavity filled with golden-brown, thick fluid. This extended posteriorly and completely destroyed the left thalamus. The borders of the cavity consisted of solid, partially calcified tumour (Fig. 1). Most of the midbrain and upper pons had been replaced by the tumour, which left a peripheral rim of tissue only about 1 cm in width (Fig. 2). Only the tegmentum of the lower pons was involved, but the basis was relatively free. Although the fourth ventricle was filled with tumour only the right dorsal horn of the medulla had been invaded. Microscopic examination disclosed almost no normal residual structure of the left caudate, thalamus, midbrain, or pons. These areas of the brain had been replaced by relatively acellular fibro-calcific material. Only a thin, apparently viable, growing edge of squamous epithelium could be seen in a few places. There were several intra-tumour cysts filled with degenerated red cells, haemosiderin-laden macrophages, and cholesterol clefts. The tissue around the thalamic portion of the tumour consisted of an extremely thick cuff of piloid astrocytes, whereas in the brain-stem it was characterized by interstitial haemorrhage and a round cell infiltration. The basal subarachnoid space was also filled with tumour and a sparse round cell infiltration.

DISCUSSION

Direct invasion of brain parenchyma by craniopharyngioma is an exceedingly rare event. The only previous report of such an occurrence was made by Iyer in 1952. His case was that of a 3-month-old baby with a congenital craniopharyngioma, which caused prenatal hydrocephalus. At death the tumour had replaced structures in the hypothalamic region and had not only grown into the third ventricle, but into the midbrain tegmentum as well. This direct invasion of the midbrain parenchyma produced aqueductal obstruction. Clinically there had been progressive cranial enlargement and generalized spasticity but no other focal neurological signs.

Since the clinical manifestations of craniopharyngiomas are fairly characteristic and consist

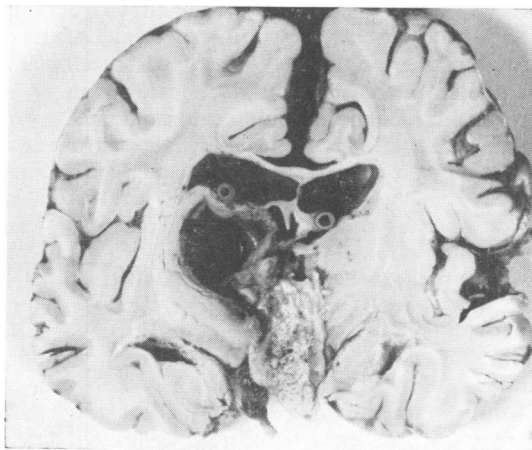


FIG. 1. Coronal section showing cystic replacement of left thalamus. Cyst was filled with granular golden brown liquid. Note multinodular tumour within the third ventricle and at the base of brain.

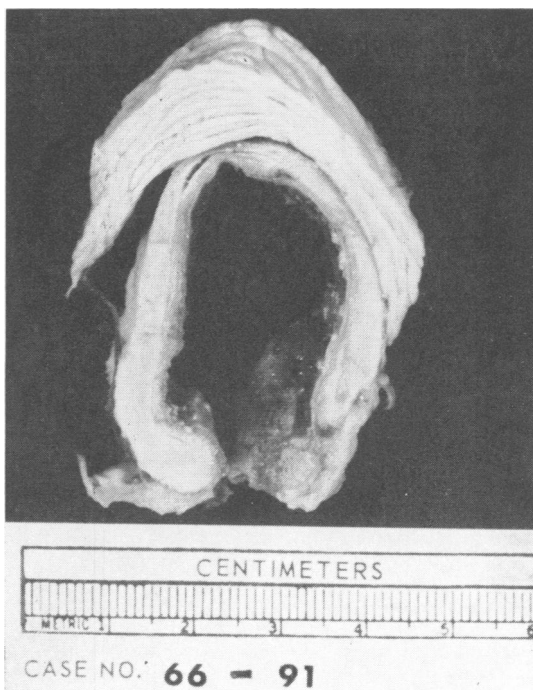


FIG. 2. Transverse section through upper pons and cerebellum. Note replacement of pons by well-demarcated cystic tumour and small peripheral remnant of uninvolved pontine parenchyma. Typical 'motor-oil' fluid from cyst has been removed.

primarily of headache with or without vomiting, visual field defects, optic atrophy and signs of pituitary-hypothalamic dysfunction, development of additional focal neurological signs may be of assistance in delineating the direction and extent of tumour growth. These may include sixth cranial nerve palsy, thalamic syndrome, and Parkinsonian state, hemichorea with or without hemiparesis or hemiataxia (Anderson and Haymaker, 1962). Such suggestive localizing signs in our patient appeared four years after the initial surgery and consisted of left central facial palsy, nystagmus on left lateral gaze, dysmetria of upper limbs, and ataxia. Over the succeeding six years more definite signs of pyramidal, midbrain, and cerebellar dysfunction appeared. These were most severe during the last year of the patient's life and were manifested by his inability to walk, swallow, or speak. Furthermore, involvement of midbrain and pontine structures was apparent by the presence of small fixed pupils, abnormalities of eye movements, poorly responsive state, and ataxia.

Excessive bleeding at the time of his second craniotomy made surgical removal impossible and the tumour was apparently not sensitive to radiation therapy. The capacity of the residual, relatively inconspicuous viable tumour tissue to invade the

brain in spite of the combined surgical and radiation therapy is especially remarkable.

SUMMARY

A boy with a craniopharyngioma who had been treated both by surgery and irradiation therapy died 12 years after initial diagnosis had been made. Examination of the brain at necropsy showed extensive invasion into the deep gray masses and almost total replacement of midbrain and pontine structures by the tumour. Clinical diagnosis of this very rare occurrence may be made if focal neurological signs develop.

This study was supported in part by National Institute of Neurological Diseases and Blindness Special Fellowship 7 F 11 NB-1358-03 (Dr. Grover), and National Institute of Neurological Diseases and Blindness Training Grant 2 TO 1 NB 05260-09.

REFERENCES

- Iyer, C. G. S. (1952). Case report of an adamantinoma present at birth. *J. Neurosurg.*, 9, 221-228.
- Anderson, E., and Haymaker, W. (1962). Disorders of the hypothalamus and pituitary gland. Pp. 1371-1372 in *Clinical Neurology*, Vol. 3 (2nd. ed.). Edited by A. B. Baker. Hoeber-Harper, New York.