

# Perinatal telencephalic leucoencephalopathy

FLOYD H. GILLES AND SEAN F. MURPHY

*From the Department of Pathology (Neuropathology), Children's Hospital Medical Center and the Department of Neurology, Harvard Medical School, Boston, Massachusetts, U.S.A.*

The frequent, though generally unrecognized, occurrence of damage to telencephalic white matter during the perinatal period prompted the present characterization of the pathological changes as well as a consideration of associated clinical and necropsy findings. Symmetrical astrocytosis or acutely damaged glial cells found predominantly in regions undergoing myelination suggest that the latter is associated with enhanced vulnerability. Although a single aetiological factor could not be identified in the clinical and necropsy data of the infants in this study, it may well be that the changes in developing white matter are non-specific morphological responses to a variety of noxious stimuli. The available data indicate an increasing deficit in brain weight with increasing survival age and the speculation is tendered that infants may survive the neonatal period with varying degrees of permanent symmetrical deficit of telencephalic white matter.

## MATERIAL AND METHODS

The material consisted of 271 brains, ranging in age from six gestational months to the end of the third postnatal month, collected consecutively over a three year period, 1965 to 1967 inclusively. Sixty-six brains were set aside because of the presence of the following conditions: malformation or genetic abnormality, intracranial tumour, subdural haematoma, meningitis, hypoglycaemia embolic encephalopathy, phenylketonuria, rubella, hyperbilirubinaemia, and massive matrix haemorrhage with rupture into the telencephalon. Nine brains could not be utilized for technical reasons. The remaining 196 brains were obtained from patients dying from a variety of non-neurological diseases and constitute the basis of this report. Brains were fixed in one of three fixatives: 4% formaldehyde in physiological saline, phosphate buffered 4% formaldehyde, or 4% formaldehyde to which 2% calcium acetate and 2.5% sucrose had been added. The morphological abnormalities in these brains were not fixative dependent as adjacent blocks from both normal and abnormal brains fixed in each solution were comparable. All brains were cut in a standard fashion related to certain landmarks at the base of the brain. Representative blocks were processed and embedded in paraffin. Previous experience indicated that celloidin embedded material was not satisfactory for identifying glial abnormalities in unmyelinated or myelinating white

matter. Sections were cut at 10  $\mu$  and were stained with one or several standard stains or methods, including haematoxylin and eosin, phosphotungstic acid haematoxylin, Bodian for axons, Luxol Fast Blue, Solochrome Cyanin R, cresyl violet, Von Kossa, Gomori for iron, Millon's for protein, periodic acid Schiff, Gomori trichrome, and Holzer.

The following morphological criteria of damage in myelinating white matter were utilized:

**HYPERTROPHIC ASTROCYTES** Cells with pale vesicular nuclei and eosinophilic irregular hyaline cytoplasm (Figs. 1a and b) are not found in normal human myelinating telencephalic white matter (Mickel and Gilles, 1968). With appropriate stains they have the configuration of astrocytes (Fig. 2) and are associated with a delicate fibrillary gliosis. Although the cytoplasm of these cells is less voluminous than that of the usual hypertrophic astrocyte in mature brain, there are sufficient morphological similarities to consider them small hypertrophic astrocytes. They are identical with the small hypertrophic astrocytes found adjacent to puncture wounds of human neonatal telencephalic white matter. For descriptive purposes these are called hypertrophic astrocytes. Furthermore, white matter considered to be undamaged—that is, without these cells—does not contain the delicate fibrillary gliosis.

**ACUTELY DAMAGED GLIAL CELLS** A second abnormality of the glial cell population was encountered. In standard histological screening stains, normal glial cells in human unmyelinated white matter have an unstainable cytoplasm, with either a large pale vesicular nucleus or a small dark nucleus (Fig. 3). In contradistinction, glial cells were considered abnormal when they contained pyknotic, irregular, hyperchromic, or karyorrhectic nuclei and globular amphophilic or darkly eosinophilic hyaline or faintly granular cytoplasm (Fig. 4). For descriptive purposes, these cells are called acutely damaged glial cells and are considered to represent an early stage of subtotal or total damage to the cell. It should be noted that the hyaline or faintly granular eosinophilic or amphophilic cytoplasm of these cells bears little or no resemblance to the vesiculate cytoplasm of the usual macrophage. At times populations of glial cells were encountered in which there were mixtures of both varieties of abnormal glial cells (Fig. 5) or which contained individual cells which exhibited some of the characteristics of each variety—for example, large pale vesicular nucleus in a globular amphophilic cytoplasm.

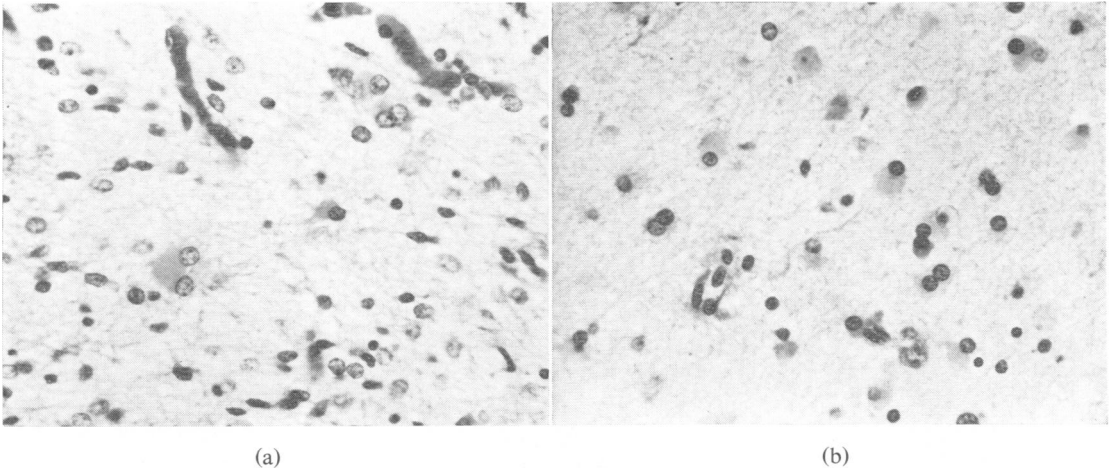


FIG. 1. (a) Hypertrophic astrocyte with hyaline eosinophilic cytoplasm. Similar binucleate forms were frequently encountered, particularly in cerebellum. *H and E*,  $\times 200$ . (b) Hypertrophic astrocytes with indistinct cytoplasmic margins. *H and E*,  $\times 200$ .

The majority of cells in neonatal telencephalic isocortex are small undeveloped neurones with a diminutive cytoplasm containing sparse Nissl substance. The morphological changes characteristic of acute neuronal necrosis in more mature neuronal perikarya are consistently absent in immature cortex. In acutely damaged neonatal brain, karyorrhexis of cortical cells is one of the few reliable signs of necrosis. Larger neurones of striatum, pallidum, thalamus, brain-stem, and cerebellum exhibit the usual sequence of changes when damaged acutely and the standard criteria of acute neuronal necrosis can be utilized. On the other hand, the established cortical lesion, when sufficiently severe, can be recognized by neuronal depletion and gliosis.

Two other criteria of damage in the adult brain must be modified when dealing with the immature brain.

Pleomorphic microgliaocytes (Gilles and Murphy, 1968) or sudanophilic material diffusely scattered within unmyelinated white matter (Rydberg, 1930; Alpers and Haymaker, 1934; Mickel and Gilles, 1968) cannot by themselves be considered abnormal when encountered in the perinatal brain.

#### RESULTS

The slides of the 196 brains of the study group were surveyed for hypertrophic astrocytes, acutely damaged glial cells, focal necroses in white matter, and evidence of neuronal necrosis. No abnormality was found in 92 cases and these will hereafter be referred to as the control group. The morphological

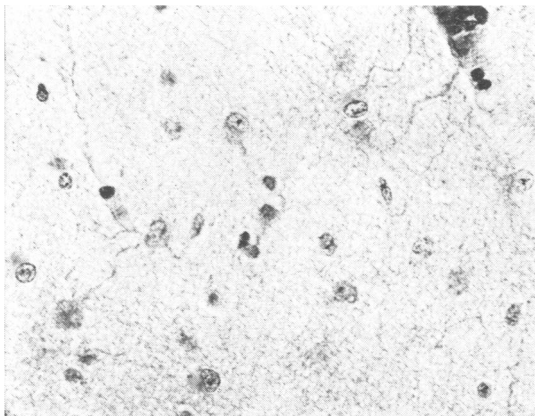


FIG. 2. Hypertrophic astrocytes with long fibrillar processes. *PTAH*,  $\times 320$ .

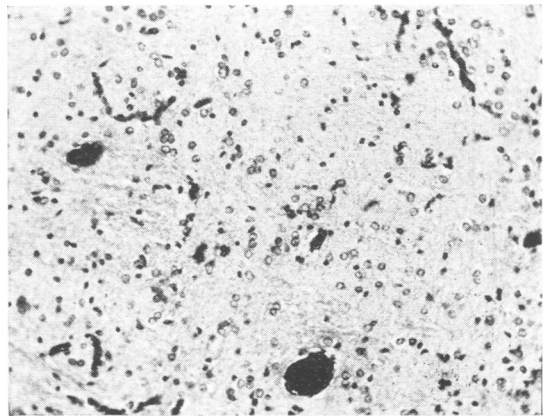


FIG. 3. Glia in normal unmyelinated human telencephalic white matter do not display a cytoplasm in routine stains. *H and E*,  $\times 150$ .

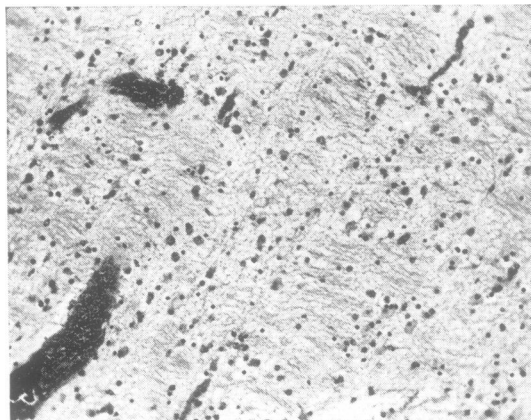


FIG. 4. Acutely damaged glial cells with rounded, amphophilic, or darkly eosinophilic cytoplasm and pyknotic hyperchromic nuclei. *H and E*,  $\times 100$ .

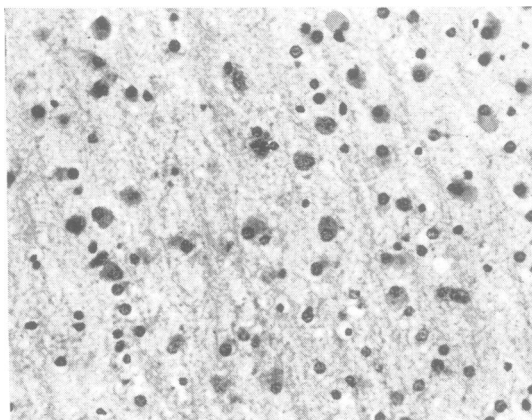


FIG. 5. A population with both varieties of glial cell change. *H and E*,  $\times 200$ .

changes in the remaining 104 cases fell into the following categories: I = brains with hypertrophic astrocytes in white matter (51); II = brains with acutely damaged glial cells in white matter (19); III = brains with both acutely damaged glial cells and hypertrophic astrocytes in white matter (21); IV = brains with focal white matter necroses without hypertrophic astrocytes or acutely damaged glial cells (12); V = brains with grey damage alone (basis pontis) (1).

At the time of gross examination, generalized congestion or faint grey discoloration of telencephalic white matter was irregularly present in both control and abnormal groups. Focal necroses were recognized as limited, small, white, opaque areas in

normally opalescent white matter. Regions of moderately severe diffuse white matter damage were readily recognized under low magnification by their pallor.

**HYPERTROPHIC ASTROCYTES** The intensity and extent of hemispherical white matter astrocytosis varied considerably, ranging from brains in which most of the glial population consisted of hypertrophic astrocytes to brains which contained only a few of these cells. Frequently, a region of severe astrocytosis extended into the layer of subcortical fibres where it ceased abruptly at the border of morphologically normal immature isocortex. The mitoses (Figs. 6a and b) and paired or binucleate (Figs. 1a and b) astrocytes

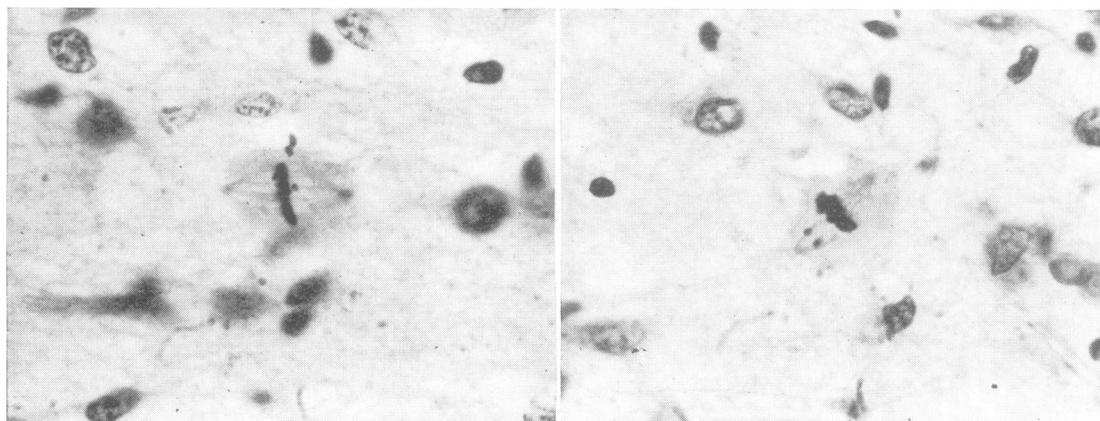


FIG. 6. Two of several mitotic figures encountered in regions of astrocytosis. *H and E*,  $\times 620$ .

found in regions of dense astrocytosis suggested a rapid proliferation of astrocytes, although specific identification of a cell in mitosis is often difficult. In a few cases, a region containing diffuse astrocytosis also contained typical macrophages with pale vesiculate cytoplasm.

Focal or widespread telencephalic white matter astrocytosis of variable intensity was found in 72 cases. Twenty-one of these brains also contained acutely damaged glial cells. Although the usual location of hypertrophic astrocytes was deep frontal or parieto-occipital white matter, they were frequently found in the corpus callosum as well as in gyral white matter cores. They were conspicuously absent in well-myelinated regions. In no instance were they found in the white matter of extreme anterior temporal pole, one of the last regions of telencephalic white matter to myelinate (middle half of the first postnatal year). The other common locus of these cells was in white matter cores of symmetrical cerebellar folia (24/72). In these folia, preservation of neurones in the internal and external granule cell layers, the Purkinje cell layer, and in the roof nuclei was particularly prominent.

The bilateral symmetry of the white matter astrocytosis, whether in the cerebrum, cerebellum, gyral white matter cores, or in corpus callosum, was especially notable. This symmetry was present even when the lesions were relatively restricted or focal.

Hypertrophic astrocytes were found in deep white matter of 10 infants whose death occurred within 24 hours of birth and in an additional 12 infants who died in the first three days of life. Although it is possible that hypertrophic astrocytes may develop more rapidly in the immature brain than in the adult brain, it appears more likely that the insult to developing white matter occurred before the time of birth in these particular cases.

One-third of brains with diffuse hypertrophic astrocytosis contained focal necroses within regions of diffuse astrocytosis, whether the latter were deep in centrum semiovale or peripheral in gyral cores. Acute coagulative and established focal necroses were juxtaposed in several brains.

Hypertrophic astrocytes and acutely damaged glial cells occurred in the same region in 23 brains. With advancing survival age, it became increasingly difficult to detect hypertrophic astrocytes, although the mild fibrillary gliosis was demonstrable by appropriate methods. Moderate numbers of stainable axons were found in the regions containing reactive astrocytes. Reduction in number of axons could not be demonstrated except when the tissue was totally necrotic.

**ACUTELY DAMAGED GLIAL CELLS** These cells were

found in variable density and shared the same topographic distribution as hypertrophic astrocytes. They were rarely encountered in completely myelinated regions. In 36 of the 40 cases containing these cells, limited or extensive karyorrhexis within telencephalic grey or in the basis pontis was also present. This change in glial cell morphology was not associated with a recognizable histiocytic or macrophage response or with any particular vascular change other than mild endothelial swelling. Axons were demonstrable in regions containing these cells.

**FOCAL NECROSSES** Focal necrotic lesions, either coagulative or organized, were found in 18% of the brains under study. In 6% they represented the only abnormality, while in 12% they were associated with diffuse telencephalic white matter damage. They were similar in every respect to those previously described (Schwartz, 1961; Banker and Larroche, 1962), although in the present series the topographic distribution of these lesions was more widespread. Their distribution was far too variable in deep paraventricular or superficial white matter or in gyral white matter cores (for example, inferior frontal convolution) to implicate any specific vascular bed or border zone. It is of importance that focal necroses have the same general distribution as the glial changes mentioned above and were never found in anterior temporal white matter. Elsewhere we have found focal necroses in association with a wide variety of perinatal conditions: prematurity, difficult labour, neonatal meningitis, rubella, posterior fossa haematoma, herpes simplex, kernicterus, phenylketonuria, cystic fibrosis, hyaline membrane disease, congenital heart disease, intraventricular haemorrhage, ganglionic eminence haemorrhage, erythroblastosis foetalis without kernicterus, agranulocytosis, and sagittal sinus thrombosis.

**PARENCHYMAL GLOBULES** The small numbers of parenchymal globules (Fig. 7) frequently encountered in the white matter of abnormal brains were similar to the perivascular globules commonly found in the corpus striatum in this age group. However, this study was concerned only with those globules found in telencephalic white matter. These globules were amphophilic or basophilic, frequently pericapillary (Fig. 7) or perivenular, and sometimes laminated. They were periodic acid Schiff positive, brown-black in Von Kossa, iron negative, red in Gomori trichrome stain, and protein positive by Millon's method. Usually, no cellular reaction to these globules was apparent. Two globules were encountered, however, which were eccentrically or centrally located in a small mass of matrix-like cells.

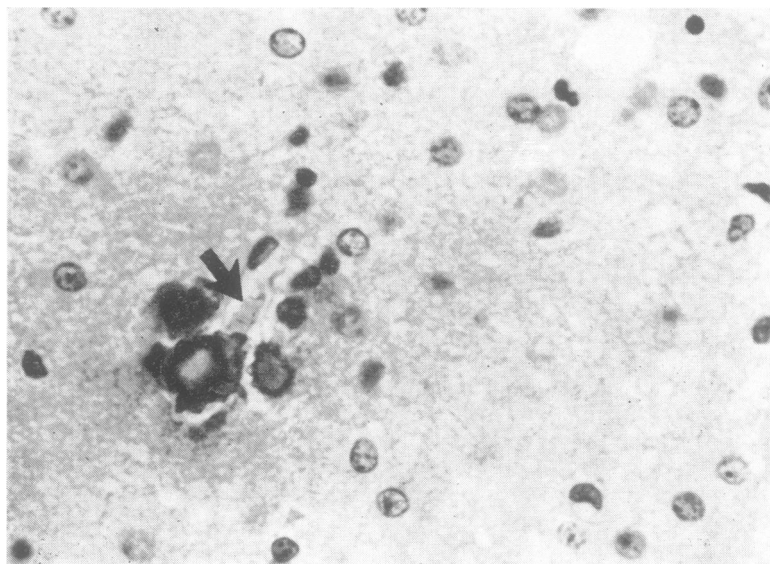


FIG. 7. Perivascular globules. A capillary containing two erythrocytes (arrow) lies adjacent to the largest globule. H and E,  $\times 600$ .

The globules were found in 9.6% of the control brains, and in 66% of the abnormal brains.

Neuronal loss or astrocytosis was not prominent in the grisea of those brains containing hypertrophic astrocytosis in telencephalic white matter and did not appear in isolation. In these cases it was more apparent in basis pontis, thalamus, and basal ganglia (in that order) than in cortex. Karyorrhexis within basis pontis primarily and, to a lesser extent, in thalamus, basal ganglia, or cortex, was far more frequent, particularly in brains containing acutely damaged glial cells in telencephalic white matter, and was present in basis pontis alone in only a single case. Parenthetically, neurones in sectors CA<sub>2</sub>, CA<sub>3</sub> and the hilus of the fascia dentata, although antedating sector CA<sub>1</sub> in maturation, appear no more or less susceptible to damage than isocortex in general at this age. Hippocampal damage was certainly present far less frequently than the 65% of perinatal brains reported elsewhere (Riggs and Rorke, 1966), and acute or established necrosis limited to sector CA<sub>1</sub> (essentially Sommer's Sector) was not encountered in this series.

**CLINICAL CORRELATES** The mean survival ages of infants whose brains contained hypertrophic astrocytes (16.3 days), acutely damaged glial cells (16 days), or focal necroses (17.2 days) were essentially the same. However, the mean survival age of infants whose brains contained white matter perivascular globules was somewhat longer (23.7 days). The mean gestational ages of infants grouped according to each of these four pathological abnormalities were similar (37.5 to 38.2 weeks).

Infants whose white matter contained any of the four pathological abnormalities singly or in combination were grouped collectively and compared with the controls. The control and abnormal groups did not differ significantly in the numbers of infants weighing less than 5 lb. 8 oz. (2.5 kg) (40% and 43% respectively), or in mean gestational age (37.9 and 37.4 weeks), or in mean survival age (26 and 24 days). History of significant perinatal difficulty was present slightly more often in the abnormal group, 20% vs. 14%. Included in this category were maternal diabetes, toxemia, precipitous delivery, multiple pregnancy, Caesarean section, prolonged labour, premature separation of placenta, and foetal distress.

Congenital heart disease or pulmonary disease accounted for the demise of 84 of the 104 abnormal infants and 63 of the 92 control infants. These differences are barely statistically significant ( $P < 0.05$ ). The remaining patients died from a variety of other perinatal conditions which appeared in comparable numbers in the two groups or which occurred in such small numbers that no significant comparison could be made.

Congenital heart disease alone appeared in a higher proportion (56/104) of the patients with leucoencephalopathy than in the normal group (37/92). However, this is not a highly significant difference ( $P < 0.05$ ). A higher proportion of infants with leucoencephalopathy had had cardiac arrest (14/104:10/92), apnoeic spells or respiratory difficulty (57/104:39/92), or congestive heart failure (16/104:10/92), but these differences are not highly significant. Among the other factors considered,

only cyanosis appeared particularly significant. The presence of prolonged cyanosis was a highly important parameter regardless of its aetiology. Patients whose cyanosis was limited to distal extremities or whose cyanosis was agonal were excluded. Cyanosis was present in 72/104 infants with perinatal leucoencephalopathy and in 44/92 controls. The difference between the two groups would appear to be highly significant ( $P < 0.001$ ).

Randomly obtained clinical laboratory data were also compared in both groups (see appendix). No significant differences between the means (maximum or minimum where appropriate) could be found in haematocrit, blood sugar, hydrogen ion concentration, sodium, potassium, or chloride when all infants with any manifestation of the leucoencephalopathy were grouped together. Furthermore, when the infants were subgrouped by the individual criteria of hypertrophic astrocytes, acutely damaged glial cells, and focal necroses, no distinct differences between the means of these values were found.

Blood gases had been obtained on arterial or freely flowing capillary blood in less than one-fourth of the individuals in both groups excluding terminal or agonal determinations. The mean values of oxygen tension and saturation were not significantly different in the two groups. The mean value of the minimum carbon dioxide tension was significantly lower for the abnormal group. Comparable values for both groups for mean oxygen saturation were obtained at cardiac catheterization for left ventricular and femoral arterial blood. The mean systemic flow was statistically comparable in the two groups, but mean pulmonary flow was significantly reduced in the abnormal group. The range of antibiotics used and the number of individuals who had undergone a general anaesthetic were comparable for the two groups.

Mean spinal fluid protein concentration was mildly elevated in the group with leucoencephalo-

pathy but, unfortunately, only a small number of determinations was available for the control group.

**ANATOMICAL CORRELATES** Estimates of the state of nourishment had been recorded by the prosector in 66 of the infants without perinatal leucoencephalopathy and in 86 of the infants with perinatal leucoencephalopathy. Of the control group, 21% were considered to be poorly nourished, 27% fairly well nourished, and 52% were recorded as having good nutritional status. Of the group with the perinatal leucoencephalopathy, 33% were considered poorly nourished, 33% fairly well nourished, and 34% well nourished.

Infants in both groups were subgrouped by 5 cm increments in crown-heel length and by 100 g increments in fresh brain weight. Several anatomical parameters including body weight at death, liver, kidney and thymus weight and thickness of abdominal fat pad were then compared within the individual groups. However, no significant differences were found for the large number of infants in the middle ranges. While differences in organ weights, in extremes of length or brain weight were present, the numbers of individuals were too small for significant comparison.

When infants were grouped by the individual factors hypertrophic astrocytes, acutely damaged glial cells, and organized focal necroses, no outstanding differences appeared between the individual groups and the appropriate control groups in either clinical or necropsy data.

Infants with hypertrophic astrocytes in telencephalic white matter and controls were grouped according to length of survival (Table I). In infants who had survived 0 to 3 days, there were no significant differences between the means of crown-heel length, birth or death weight, fat pad thickness, or brain, thymus, liver, or kidney weight. Nor were there any significant differences in mean gestational and survival ages. For patients who had survived 4 to

TABLE I  
CONTROLS/INFANTS WITH TELENCEPHALIC WHITE MATTER ASTROCYTOSIS GROUPED BY DAYS OF SURVIVAL<sup>1</sup>

Mean	Gestational age (wk)	Birth weight (g)	Death weight (g)	Crown-heel (death) (cm)	Brain weight (g)	Thymus weight (g)	Liver weight (g)	Kidney weight (g)	Fat pad thickness (cm)
				0-3 days					
Control	37 (28)	2450 (30)	2338 (30)	46.5 (31)	312 (30)	7.4 (27)	91 (29)	12.3 (31)	0.32 (23)
Abnormal	38.2 (19)	2770 (22)	2580 (19)	46.4 (21)	326 (17)	8 (18)	100.2 (22)	12.5 (22)	0.45 (16)
				4-7 days					
Control	33.4 (10)	2770 (10)	2450 (7)	48.1 (9)	313 (8)	5.4 (8)	101 (9)	15 (10)	0.44 (7)
Abnormal	38.8 (10)	2540 (11)	2510 (9)	46.0 (11)	299 (9)	3.4 (8)	82.2 (10)	12.6 (10)	0.41 (9)
				8-105 days					
Control	38.8 (28)	2740 (30)	2630 (39)	52.2 (40)	456 ± 142 (36)	10.3 ± 9.4 (35)	145 ± 65.9 (39)	18.6 (41)	0.41 ± 0.24 (30)
Abnormal	37.6 (33)	2510 (34)	2490 (32)	52.7 (37)	354 ± 108 (34)	3.6 ± 2.5 (30)	105 ± 32 (35)	15.3 (33)	0.24 ± 0.16 (27)
					$P < 0.005$	$P < 0.005$	$P < 0.005$	NSD	NSD

<sup>1</sup>Numbers of determinations in parentheses.

7 days, mean weights of liver, thymus, and brain were slightly lower than in controls although these differences were not statistically significant.

A statistically highly significant difference appeared in those infants who had survived between 8 and 105 days. Mean brain, thymus, and liver weights in infants whose telencephalic white matter contained hypertrophic astrocytes were markedly less than in controls. Mean brain weight of the damaged group was about 25 %, mean thymus weight was 65 %, and mean liver weight was about 25 % of controls. These differences are significant ( $P < 0.005$ ). The means of gestational age, birth and death weights, crown-heel length, and kidney weight were comparable with those for the control group, although there was a difference of two weeks in mean survival age. Abdominal fat pads were thinner in the abnormal group but this was not statistically significant.

#### DISCUSSION

The morphological abnormalities used as criteria of pathological change within perinatal telencephalic white matter are not differentially related to gestational or survival age. They reflect cellular response and regional vulnerability to insult and lend considerable support to several hypotheses: (1) developing human telencephalic white matter may be as vulnerable to insult as perinatal isocortex or allocortex; (2) focal necroses may represent regions of maximal focal morphological response to the same processes which give rise to the diffuse glial change described herein; (3) vascular endothelium may partake in this response by allowing transient escape of proteinaceous material which may subsequently mineralize. The clinical events and specific disease processes underlying these morphological abnormalities can be considered to be those leading either to a disparity between tissue demand and systemic supply of appropriate metabolites or to the appearance of an abnormal agent capable of acting as a toxin.

The available clinical and anatomical data do not identify a single specific aetiological factor in all infants with abnormal brains. Among those factors which may contribute to these changes, but which do not appear markedly more frequently in the abnormal group, are congenital heart disease, perinatal difficulties (specified above), and episodes of cardiac or respiratory insufficiency. Infants with cyanosis or decreased mean pulmonary flow appeared in a statistically more significant number in the abnormal group. The significantly low mean of minimum carbon dioxide tension without changes in electrolytes or hydrogen ion concentration suggests

that an excess of organic acids may be present. However, a sizeable number of infants whose brains contained some manifestation of the leucoencephalopathy came to necropsy with none of these factors recognizable in their backgrounds. Abnormalities of haematocrit, blood sugar, hydrogen ion concentration, electrolytes, and kinds of antibiotics or general anaesthetics used did not appear to play a significant role, although many of the samples obviously recorded only very transient phenomena. Chronic hypoxaemia alone does not appear to be directly related to perinatal leucoencephalopathy. If isolated bouts of acute severe hypoxaemia were important it would have been expected that episodes of cardiac or respiratory arrest would have held a more prominent role in the anamnesis of the abnormal group. Furthermore, the lack of correlation of perinatal telencephalic leucoencephalopathy with prematurity would be expected if it were primarily a lesion associated with myelination—the latter process attaining full momentum late in gestation and in early postnatal life for frontal and parieto-occipital lobes (Yakovlev and LeCours, 1967).

The role of hypoxia, *per se*, in the pathogenesis of these morphological changes in white matter, or in the pathogenesis of many lesions in perinatal brain for that matter, is exceedingly difficult to assess. All too frequently the lesions in brains from individuals who had had difficult perinatal periods have been inferred to be 'anoxic' in origin. While it is obvious that neither neonates nor adults can live indefinitely in the absence of oxygen, the neonates of many mammalian species do have a much greater capability of surviving anoxia than adults of the same species (Boyle, 1670; Himwich, Bernstein, Herrlich, Chesler, and Fazekas, 1941-42; Hicks, 1953) and vigorous human neonates with high Apgar scores may have negligible arterial oxygen saturations (James, Weisbrot, Prince, Holaday, and Apgar, 1958). Moreover, it is not logically necessary to infer that lesions in perinatal brain are *ipso facto* anoxic in origin, especially when these lesions lie in arterial or venous beds or in typical border zones (Norman, Urich, and McMenemy, 1957). Furthermore, it has been suggested that neonatal oxygen saturations (Apgar, Girdany, McIntosh, and Taylor, 1955; Graham, Caldwell, Ernhart, Pennoyer, and Hartmann, 1957) and asphyxia neonatorum (Campbell, Cheeseman, and Kilpatrick, 1950) alone have little predictive value for long term intellectual or neurological outcome. The role of hypoxia may lie either in concomitant changes induced in electrolytes or metabolites or in a direct effect upon some other organ. For example, depletion of cardiac carbohydrate reserves during hypoxaemia (Mott, 1961)



may lead to inadequate perfusion of brain. Furthermore, cardiac output for the neonate is not only relatively much greater than that of the adult but a larger proportion is directed to the head, and it may decrease or fail to increase in the face of hypoxaemia. These studies were recently summarized by Young (1966). Blood pressure, normally low in the neonate, may fall profoundly with hypoxaemia (James and Rowe, 1957). As a result of a combination of these factors the newborn may have little reserve between an adequate and a critical cerebral perfusion. The logical speculation is that mild failures of white matter perfusion may fall short of producing frank border zone necroses but may still inadequately supply essential metabolites or remove metabolic by-products. On the other hand, experimental primate neonatal asphyxia, with severe bradycardia, is associated with a constellation of restricted symmetrical focal necroses of brain-stem nuclei (Ranck and Windle, 1959) which were not present in any of the cases included in this study.

The decrease in rate of growth of the foetus at the end of gestation is thought to be related to relative inadequacy in the maternal-foetal supply line (Gruenewald, 1963). Those infants whose leucoencephalopathy was apparent in the first few days of life might indeed be reflecting some unknown maternal nutritional deficit, an unrecognized placental abnormality, or some inability of the foetus itself to transport adequate supplies of appropriate myelin precursors to brain. While there was no excess thymic involution to suggest frank foetal distress in the newborn group, it may be that myelinating brain is more sensitive than thymus to such a relative lack of appropriate metabolites. Certainly after birth, when the neonate was no longer supported maternally, significant deficits in brain, thymus, and liver weight appeared quickly. The relationships between the weight deficits of the three organs is not at all clear. They could reflect loss of a common metabolite necessary for adequate development of all three organs or one organ could be dependent upon adequate function of the others.

The morphological changes in developing white matter could well be due to a generalized insult to foetus or neonate. One such non-specific insult could be an inadequate nutritional supply. Nutritionally deprived neonatal rats (Dobbing and Widdowson, 1965) and pigs (Dickerson, Dobbing, and McCance, 1966), as well as humans malnourished during growth (Brown, 1965), tend to have brains small for their age. Rats, pigs, and humans in these studies tended to have associated delays in body growth but possibly the infants presented in this report did not live long enough for such delays to become manifest.

Morphological evidence of restricted or wide-

spread symmetrical telencephalic leucoencephalopathy was found in the brains of approximately one-half of these infants who died perinatally. The presence of abnormal cells, descriptively labelled hypertrophic astrocytes or acutely damaged glial cells, in developing white matter constitutes the basis for this statement. Even if one discounts focal necroses and acutely damaged glial cells as the result of unrelated processes, telencephalic white matter astrocytosis still appears in more than one-third of perinatal necropsies. Furthermore, approximately one-third of the brains with leucoencephalopathy exhibited a comparable symmetrical astrocytosis in distal cerebellar folial white matter. Clinically, these infants were considered to be intact neurologically, although the widespread changes in myelinating white matter may have been reflected in a moderately elevated cerebrospinal fluid protein in some cases.

Myelin appears in specific tracts after a predetermined sequence of events which includes proliferation of glial cells, accumulation and synthesis of myelin precursors, and the deposition of the spiral lamellae of the myelin sheath itself. The chain of events, which is characterized by intense metabolic activity, is initiated by the presence of axons and is dependent upon the presence of extraneural sources of energy and the availability of appropriate myelin structural units or their precursors (Friede, 1966). Furthermore, the rapid growth exhibited by mammalian brains at the time of myelination may be largely accounted for by the great bulk of material transported to and incorporated into the developing nervous system during this period. A wide variety of stresses or deficits may potentially interfere with the supply of exogenous precursors, the sources of energy needed for myelinating white matter, or directly with the endogenous intracellular events finally leading to the formation of the myelin sheath (Davison and Dobbing, 1966). Thus, it is logical to expect myelinating white matter to be more vulnerable to certain types of insult than white matter in which myelination is complete. However, little emphasis has been placed on morphological evidence of damage in human myelinating telencephalic white matter, with the exception of certain focal necroses (Schwartz, 1961; Banker and Larroche, 1962). The tendency of these necroses to occur in myelinating regions of telencephalon was not recognized.

The lobar symmetry of the astrocytosis constituting perinatal leucoencephalopathy is not unexpected because comparable symmetrical regions of brain undergo myelination at the same time. Distribution of telencephalic white matter damage reflects susceptibility of these regions at the stage in development when the insult occurred. The extent and



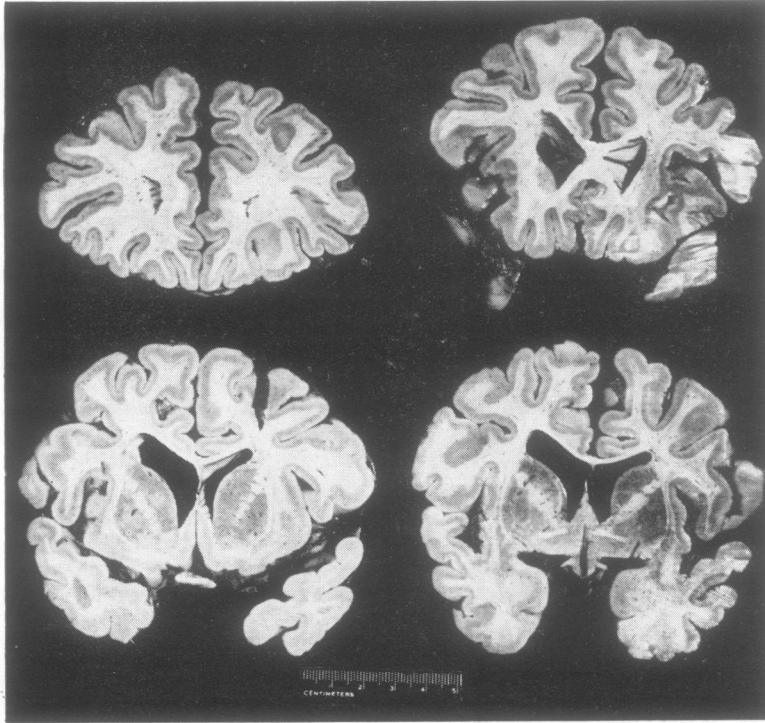


FIG. 8. Slabs of frontal and anterior temporal lobes. The cortical grey band is of ample thickness throughout. There is a paucity of white matter relative to the amount of grey.

intensity of the leucoencephalopathy may reflect severity and duration of insult. Thus, interplay of insult intensity and stage of development of symmetrical myelinating systems at the time of insult may be expected to lead to a considerable spectrum of symmetrical regional damage.

Perinatal telencephalic leucoencephalopathy, if sufficiently intense and widespread, could lead to a widespread paucity of white matter with a global intellectual deficit. Such brains have been described by Malamud (1959) and demonstrated by Lindenberg (1961), and have been seen at this institution (Fig. 8). This leucoencephalopathy is sufficiently common, and is associated with such a wide variety of conditions that it seems reasonable to assume that some infants must survive with varying degrees and distributions of symmetrical damage in hemispherical white matter. Such children would carry a permanent record of their perinatal encounter with a cryptic set of conditions which were less than optimal for adequate development of the hemispherical white matter. If the observations recorded herein are valid, as well as the assumption that the hemispherical white matter deficit is permanent, then these children would be functioning with brains with local or generalized symmetrical deficits in hemispherical white matter. Further, such deficits, while not inter-

fering with cortical function *per se*, could potentially interfere with appropriate intracerebral connections and lead to a wide spectrum of limited intellectual defects.

The data of this study—namely, the presentation of evidence of cellular reaction to white matter insult—strongly support the contention that developing telencephalic white matter is vulnerable to insult. The implication of the glial cells involved in the process of myelination as the vulnerable element is largely on topographical and logical grounds. Thus human telencephalon should be regarded as highly vulnerable to insult during myelination and this period in development should be added to those already recognized as critical in the growth and differentiation of the nervous system—namely, the phases of induction, migration, and neuronal differentiation.

#### SUMMARY

Evidence of damage within symmetrical regions of human telencephalic white matter is frequently encountered in perinatal necropsies. A single aetiological factor has not been identified for this group of infants, although cyanosis or nutritional deficiency may contribute to its development. The

brains of infants with telencephalic white matter astrocytosis are smaller than controls of comparable age. The speculations are presented that telencephalic regions have enhanced vulnerability at the time of myelination and white matter deficits induced in this period may be permanent.

The authors gratefully acknowledge the support given to this study by the Department of Health, Education and Welfare Grants SO1-FR-05482-03, SO1-FR-05482-04, SO1-FR-05482-05, as well as 1 PO1 HD 03773-01. We are grateful to Dr. Gordon F. Vawter for many helpful criticisms and comments. To Mr. John Howard and Mr. Ronald DiStefano who provided technical assistance and Miss Margaret Walsh who prepared the manuscript we are indebted. Mr. Robert F. McEnany provided photographic assistance.

### APPENDIX

Set out below are the mean values of available clinical data of all infants with any manifestation of perinatal telencephalic leucoencephalopathy compared with infants whose brains were considered normal. Agonal values were not used (usually the last four to six hours of life). The number of infants for whom data were available is recorded in parentheses.

	Control	Abnormal
Electrolytes (m-equiv/l.)		
Na max	144 (40)	138 (62)
Na min	137 (40)	135 (62)
K max	6.2 (37)	6.15 (64)
K min	5.17 (37)	5.72 (64)
Cl max	95.4 (37)	97.4 (59)
Cl min	89 (37)	95 (59)
Random arterial or capillary blood gases		
pO <sub>2</sub> max	77.5 (16)	81.7 (18)
pO <sub>2</sub> min	39.4 (16)	38.4 (18)
O <sub>2</sub> sat max	64.5 (13)	79.5 (18)
O <sub>2</sub> sat min	40.5 (13)	49.3 (18)
pCO <sub>2</sub> max	72.4 (18)	58.2 (16) NSD
pCO <sub>2</sub> min	54.1 (18)	32.8 (16) P<0.005
Cardiac catheterization		
Left ventricle O <sub>2</sub> sat	81.07 (10)	82.8 (13)
Femoral artery O <sub>2</sub> sat	70.5 (14)	64.5 (18)
Systemic flow l-/m <sup>2</sup> /min	4.9 (11)	3.84 (14) NSD
Pulmonary flow	13.1 ± 6.1 (8)	7.08 ± 4.3 (9)
		P<0.005
Haematocrit (%)		
Max	53.0 (62)	53.5 (79)
Min	44.3 (62)	48.5 (79)
pH		
Max	7.23 (26)	7.25 (36)
Min	7.08 (26)	7.16 (36)
Blood sugar (mg/100 ml.)	60.3 (11)	59.5 (24)
Cerebrospinal fluid protein (mg/100 ml.)	69.5 ± 49.6 (4)	123.5 ± 94.5 (18)
		P<0.005

### REFERENCES

Alpers, B. J., and Haymaker, W. (1934). The participation of the neuroglia in the formation of myelin in the prenatal infantile brain. *Brain*, 57, 195-205.

- Apgar, V., Girdany, B. R., McIntosh, R., and Taylor, H. C. (1955). Neonatal anoxia. I. A study of the relation of oxygenation at birth to intellectual development. *Pediatrics*, 15, 653-662.
- Banker, B. Q., and Larroche, J. C. (1962). Periventricular leukomalacia of infancy. *Arch. Neurol. (Chic.)*, 7, 386-410.
- Boyle, R. (1970). Pneumata experiments. *Phil. Trans.*, Abridged Ed. (1700), 2, 217-218.
- Brown, R. E. (1965). Decreased brain weight in malnutrition and its implications. *E. Afr. med. J.*, 42, 584-595.
- Campbell, W. A. B., Cheeseman, E. A., and Kilpatrick, A. W. (1950). Effects of neonatal asphyxia on physical and mental development. *Arch. Dis. Childh.*, 25, 351-359.
- Davison, A. N., and Dobbing, J. (1966). Myelination as a vulnerable period in brain development. *Brit. med. Bull.*, 22, 40-44.
- Dickerson, J. W. T., Dobbing, J., and McCance, R. A. (1966). The effect of undernutrition on the postnatal development of the brain and cord in pigs. *Proc. roy. Soc. B.*, 166, 396-407.
- Dobbing, J., and Widdowson, E. M. (1965). The effect of undernutrition and subsequent rehabilitation on myelination of rat brain as measured by its composition. *Brain*, 88, 357-366.
- Friede, R. L. (1966). *Topographic Brain Chemistry*. Academic Press: New York.
- Gilles, F. H., and Murphy, S. F. (1968). Unpublished observation.
- Graham, F. K., Caldwell, B. M., Ernhart, C. B., Pennoyer, M. M., and Hartmann, A. F. (1957). Anoxia as a significant perinatal experience: a critique. *J. Pediat.*, 50, 556-569.
- Gruenewald, P. (1963). Chronic fetal distress and placental insufficiency. *Biologia Neonat.*, 5, 215-265.
- Hicks, S. P. (1953). Developmental brain metabolism. Effects of cortisone, anoxia fluoroacetate, radiation, insulin, and other inhibitors on embryo, newborn, and adult. *Arch. Path.*, 55, 302-327.
- Himwich, H. E., Bernstein, A. O., Herrlich, H., Chesler, A., and Fazekas, J. F. (1941-42). Mechanisms for the maintenance of life in the newborn during anoxia. *Amer. J. Physiol.*, 135, 387-391.
- James, L. S., and Rowe, R. D. (1957). The pattern of response of pulmonary and systemic arterial pressures in newborn and older infants to short periods of hypoxia. *J. Pediat.*, 51, 5-11.
- , Weisbrot, I. M., Prince, C. E., Holaday, D. A., and Apgar, V. (1958). The acid-base status of human infants in relation to birth asphyxia and the onset of respiration. *Ibid.*, 52, 379-394.
- Lindenbergh, R. (1961). Personal communication.
- Malamud, N. (1959). Sequelae of perinatal trauma. *J. Neuropath. exp. Neurol.*, 18, 141-155.
- Mickel, H. S., and Gilles, F. H. (1968). Changes in glial cells during myelinogenesis. *Ibid.*, 27, 146.
- Mott, J. C. (1961). The ability of young mammals to withstand total oxygen lack. *Brit. med. Bull.*, 17, 144-147.
- Norman, R. M., Urich, H., and McMenemey, W. H. (1957). Vascular mechanisms of birth injury. *Brain*, 80, 49-58.
- Ranck, J. B., Jr., and Windle, W. F. (1959). Brain damage in the monkey, *Macaca Mulatta* by asphyxia neonatorum. *Exp. Neurol.*, 1, 130-154.
- Riggs, H. E., and Rorke, L. B. (1966). Studies of neonatal brain pathology, pp. 753-757 in *Proceedings of the Fifth International Congress of Neuropathology, Zurich*. Edited by F. Luthy and A. Bischoff. Excerpta Medica Foundation: Amsterdam. (International Congress Series, no. 100.)
- Rydberg, E. (1930). On the nature and morphology of the 'congenital encephalitis and myelitis' (Virchow). *Acta path. microbiol. scand.*, 7, 309-313.
- Schwartz, P. (1961). *Birth Injuries of the Newborn: Morphology, Pathogenesis, Clinical Pathology and Prevention*. Haffner: New York.
- Yakovlev, P. I., and LeCours, A.-R. (1967). The myelogenetic cycles of regional maturation of the brain, pp. 3-70 in *Regional Development of the Brain in Early Life*. Edited by A. Minkowski. Blackwell: Oxford and Edinburgh.
- Young, M. (1966). Responses of the systemic circulation of the newborn infant. *Brit. med. Bull.*, 22, 70-72.