



REVIEW

An overview of cutaneous T cell lymphomas [version 1; referees: 2 approved]

Nooshin Bagherani¹, Bruce R. Smoller²

¹Taha Physicians' Building, Khoramshahr, Khuzestan Province, Iran

²Department of Dermatology, School of Medicine and Dentistry, University of Rochester, Rochester, New York, USA

v1 **First published:** 28 Jul 2016, 5(F1000 Faculty Rev):1882 (doi: 10.12688/f1000research.8829.1)

Latest published: 28 Jul 2016, 5(F1000 Faculty Rev):1882 (doi: 10.12688/f1000research.8829.1)

Abstract

Cutaneous T cell lymphomas (CTCLs) are a heterogeneous group of extranodal non-Hodgkin's lymphomas that are characterized by a cutaneous infiltration of malignant monoclonal T lymphocytes. They typically afflict adults with a median age of 55 to 60 years, and the annual incidence is about 0.5 per 100,000. Mycosis fungoides, Sézary syndrome, and primary cutaneous peripheral T cell lymphomas not otherwise specified are the most important subtypes of CTCL. CTCL is a complicated concept in terms of etiopathogenesis, diagnosis, therapy, and prognosis. Herein, we summarize advances which have been achieved in these fields.

Open Peer Review

Referee Status:

	Invited Referees	
	1	2
version 1 published 28 Jul 2016		

F1000 Faculty Reviews are commissioned from members of the prestigious F1000 Faculty. In order to make these reviews as comprehensive and accessible as possible, peer review takes place before publication; the referees are listed below, but their reports are not formally published.

- 1 Mary Jo Lechowicz**, Winship Cancer Institute, Emory University USA
- 2 Stefano Pileri**, European Institute of Oncology, Milan/Bologna University School of Medicine Italy

Discuss this article

Comments (0)

Corresponding author: Nooshin Bagherani (nooshinbagherani@yahoo.com)

How to cite this article: Bagherani N and Smoller BR. **An overview of cutaneous T cell lymphomas [version 1; referees: 2 approved]**
F1000Research 2016, 5(F1000 Faculty Rev):1882 (doi: [10.12688/f1000research.8829.1](https://doi.org/10.12688/f1000research.8829.1))

Copyright: © 2016 Bagherani N and Smoller BR. This is an open access article distributed under the terms of the [Creative Commons Attribution Licence](#), which permits unrestricted use, distribution, and reproduction in any medium, provided the original work is properly cited.

Grant information: The author(s) declared that no grants were involved in supporting this work.

Competing interests: The authors declare that they have no competing interests.

First published: 28 Jul 2016, 5(F1000 Faculty Rev):1882 (doi: [10.12688/f1000research.8829.1](https://doi.org/10.12688/f1000research.8829.1))

Introduction

In 1806, Alibert initially described mycosis fungoides (MF) as the infiltration of skin by lymphocytes. In 1974, Edelson used the term “cutaneous T cell lymphomas” (CTCLs) for MF and its leukemic variant, Sézary syndrome (SS), which are the major types of CTCL¹. Nowadays, the CTCLs, which are characterized by infiltration of malignant monoclonal T lymphocytes in the skin, are considered a heterogeneous group of extranodal non-Hodgkin’s lymphomas¹⁻³. Approximately 25% to 40% of non-Hodgkin’s lymphoma cases involve extranodal sites. The skin is the most common site after the gastrointestinal system⁴. The annual incidence of CTCL is about 0.5 per 100,000, and men are more involved than women (1.6:1 to 2.0:1)¹. They typically afflict adults with a median age of 55 to 60 years^{1,5}.

In 1975, for the first time, the North American Mycosis Fungoides Cooperative Study Group classified the CTCLs on the basis of a tumor-node-metastasis (TNM) system. Thereafter, the classification was modified and updated by the CTCL workshop to the one used today, known as the Bunn and Lambert system¹. The International Society for Cutaneous Lymphomas/European Organization for Research and Treatment of Cancer classified MF and SS according to clinical, pathological, biological, and immunological features⁶.

MF, SS, and primary cutaneous peripheral T cell lymphomas not otherwise specified (PCTCL - NOS) are among the most important subtypes of the CTCLs^{7,8}. MF is the commonest type of CTCLs, representing 44% to 62% of cases⁹. MF restricted to the skin has an indolent progression passing from macule and patch stage to infiltrated plaque and tumor stage (Figure 1)^{5,10,11} in sun-protected body sites¹². SS is defined as an aggressive leukemic-phase type of MF¹¹, clinically characterized by erythroderma and generalized

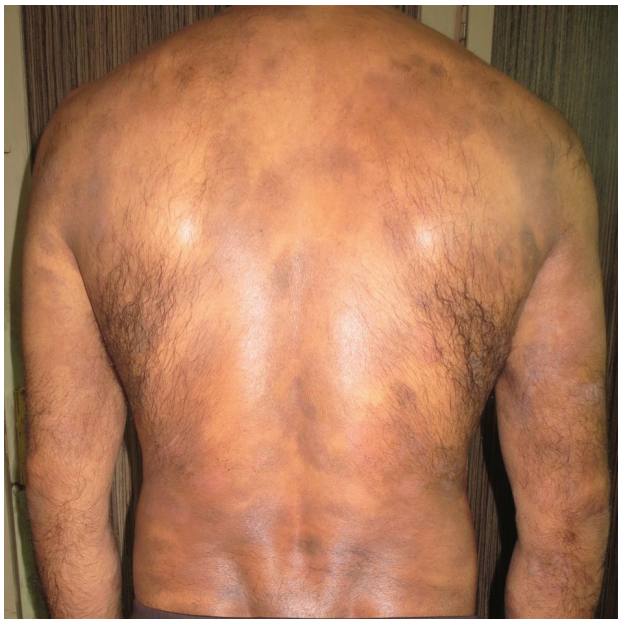

Figure 1. Mycosis fungoides in a 40-year-old man manifested as generalized atrophic patches.

lymphadenopathy¹³. PCTCL-NOS can present with a solitary red-violaceous tumor-like nodule or scattered multifocal or diffuse nodules on any part of the body, which mostly become ulcerated and infected. Rapid cutaneous dissemination and systemic involvement are key features of this class of CTCL⁸.

At the early stages, CTCLs are often misdiagnosed as benign skin conditions^{1,9,13-17}. Their most important differential diagnoses have been listed in Table 1.

In most patients with CTCL, the histologic features are subtle, so that the differentiation of these disorders from benign inflammatory diseases is difficult^{18,19}. Haloed lymphocytes, exocytosis, epidermotropism, Pautrier’s microabscess, large hyperconvoluted, hyperchromatic lymphocytes in the epidermis, and lymphocytes aligned within the basal layer are findings seen in histologic sections of MF (Figure 2)^{16,20}.

CTCL is a complicated concept in terms of etiopathogenesis, diagnosis, therapy, and prognosis. Herein, we have summarized advances which have been achieved in these fields.

Etiopathogenesis

Although different views of CTCL etiopathogenesis have been elucidated in depth over the last few decades, the exact mechanism of initiation and progression of this disorder is not yet known^{4,10,21} (Figure 3). Although dysregulation of some genes and signaling pathways has been reported in the CTCLs (Table 2), their exact role in the pathogenesis of these disorders is unknown^{2,3,13,22-34}. Most of these aberrations are seen in chromosome 10³⁵. Recent studies demonstrate ectopic expression of cancer testis genes in the CTCLs. It appears that this gene works through inhibiting apoptosis, inducing resistance to various forms of therapeutic modalities, and contributing to oncogenesis by targeting tumor suppressor genes such as *p53* and *p21*². Deficient expression or function of negative regulators, including SOCS3 and protein tyrosine phosphatases such as SHP1, have been implicated in dysregulation of the Jak-3/STAT pathway and interleukin (IL)-independent proliferation of malignant T cells. The Jak-3/STAT pathway has

Table 1. The most important differential diagnoses of the cutaneous T cell lymphomas.

All kinds of dermatitis and eczema ^{1,9,13-15}
Adverse drug reactions ¹³
Parapsoriasis ⁹
Psoriasis ^{1,14,15}
Lichen planus ¹⁶
Morphea ¹⁶
Panniculitis ¹⁷
Folliculitis ¹⁴
Pityriasis lichenoides chronica ¹⁴
Pityriasis lichenoides et varioliformis acuta ¹⁴
Pigmented purpuric dermatoses ¹⁴
Vitiligo ¹⁴
Lymphomatoid papulosis ⁹

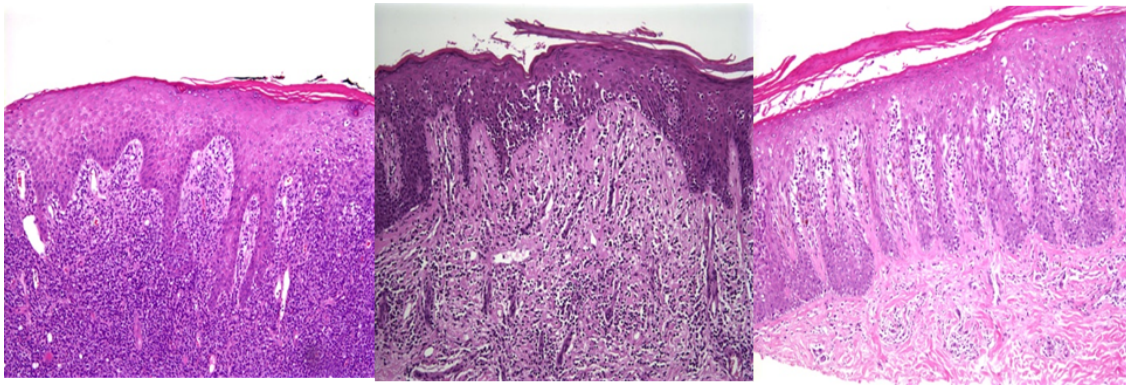


Figure 2. In pathological view, the cutaneous T cell lymphomas are characterized by haloed lymphocytes, exocytosis, epidermotropism, Pautrier's microabscess, large hyperconvoluted, hyperchromatic lymphocytes in the epidermis, and lymphocytes aligned within the basal layer. **Figure 2A** (left) A lymphocytic infiltrate is present in the dermis and extending into the overlying epidermis with minimal overlying spongiosis. **Figure 2B** (center) Lymphocytes with surrounding haloes are present in the epidermis as single cells and small clusters (Pautrier's microabscesses). There is minimal accompanying spongiosis. **Figure 2C** (right) Psoriasiform epidermal hyperplasia with epidermotropism of haloed lymphocytes is seen in this case of patch-stage mycosis fungoides.

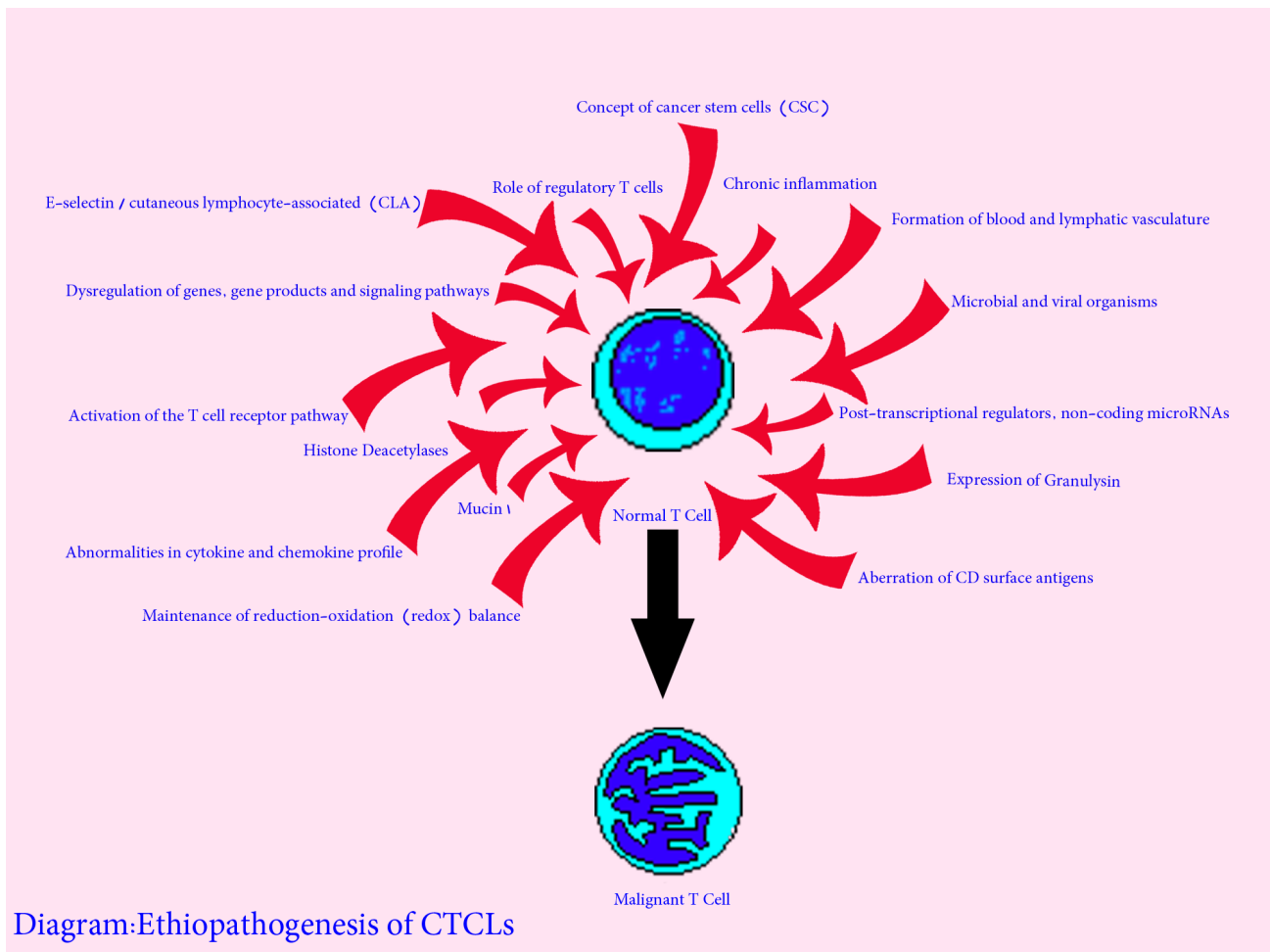


Figure 3. Etiopathogenesis of cutaneous T cell lymphoma. CTCL, cutaneous T cell lymphoma.

Table 2. An alphabetical list of dysregulation of genes and signaling pathways seen in the cutaneous T cell lymphomas.

AT-rich interactive domain-containing protein 1A (ARID1A)²³
 B-Raf proto-oncogene, serine/threonine kinase (BRAF)²⁴
 Bromodomain-9 (BRD-9)²⁴
 Cancer testis (CT)²
 Caspase recruitment domain (CARD11)^{23,24}
 C-C chemokine receptor-4 (CCR-4)²³
 Chromodomain-helicase-DNA-binding protein (CHD)-3²⁴
 CREB-binding protein (CREBBP)²⁴
 Cyclin-dependent kinase-2 (CDKN-2)²³⁻²⁶
 Cyclooxygenase-2 (COX-2)²⁵
 Dynamin-3 (DNM-3)²²
 Embryonic stem cell regulators^{3,25}
 Eph receptor A4 (EPHA4)¹³
 Forkhead box P3 (FOXP3)²⁷
 GATA-binding protein-3 (GATA-3)^{22,25}
 Histone deacetylase-6 (HDAC-6)²⁵
 Histone-lysine N-methyltransferase (KMT)-2D or myeloid/lymphoid or mixed-lineage leukemia protein-2 (MLL-2)²⁴
 Interleukin-2 receptor common gamma chain (IL-2Rgc)^{3,25}
 Janus kinase-3 (Jak-3)/signal transducers and activators of transcription (STAT)^{25,28}
 KIRD3DL2²²
 Lysine (K)-specific methyltransferase (KMT)-2C or myeloid/lymphoid or mixed-lineage leukemia protein-3 (MLL-3)²⁴
 MYC-associated factor X (MAX)²⁵
 Metallothioneins I and II (MTI/II)²⁹
 Methylthioadenosine-phosphorylase (MTAP)³⁰
 Mitogen-activated protein kinase 1 (MAPK1)²⁴
 MYC-binding protein (MYCBP)²⁵
 NOTCH1^{13,31}
 Nuclear factor kappa-light-chain-enhancer of activated B cells (NFκB)^{3,24,25}
 Nuclear factor of activated T cells (NFAT)²⁴
 Phospholipase C gamma 1 (PLCG1)^{23,32}
 P21³³
 P53^{28,32}
 Phosphatase and tensin homolog (PTEN)^{24,25,34}
 Plastin-3 (PLS-3)²²
 Protein kinase, CGMP-dependent (PRKG1)²⁴
 Receptor tyrosine kinase (RTK)¹³
 Retinoblastoma-1 (RB-1)²⁴
 Ribosomal protein S6 kinase-1 (RPS6KA-1)²³
 Runt-related transcription factor-3 (RUNX-3)²²
 Src homology region 2 domain-containing phosphatase-1 (SHP1)²⁵
 Special AT-rich sequence-binding protein 1 (SATB1)²⁹
 SRC proto-oncogene, non-receptor tyrosine kinase (Src kinases)²⁵
 Suppressors of cytokine signaling-3 (SOCS3)²⁵
 SWI/SNF-related, matrix-associated, actin-dependent regulator of chromatin-A4 (SMARC-A4)²⁴
 Tet methylcytosine dioxygenase 2 (TET2)²⁴
 Thymocyte selection-associated high-mobility group box (TOX)^{22,25}
 Tumor protein p53 (TP53)^{23,24}
 Tumor necrosis factor receptor superfamily-1B (TNFRSF-1B)³⁰
 Twist²²
 Zinc finger E-box-binding homeobox 1 (ZEB1)²³

a role in fighting against CTCLs by promoting production of IL-5, IL-10, IL-17A, and IL-17F; regulating angiogenic factors; and interfering with resistance to histone deacetylase inhibitor (HDACI) therapy²⁵. An additional report demonstrates pathogenic involvement of the NOTCH1 signaling pathway in the pathogenesis of SS¹³. NOTCH includes a family of transmembrane receptors, which play roles in cell differentiation, proliferation, and stemness³¹.

The loss of heterozygosity of phosphatase and tensin homolog (PTEN) in MF has been reported, but the significance of the finding remains unclear. In one study, a statistically significant decrease in the percentage of cells retaining PTEN and altered staining intensity were shown in MF from patch to plaque stage, but this attenuation was not significant in tumor stage in comparison with plaque stage³². The mRNA expression of a subfamily of receptor tyrosine kinase (RTK) is high in SS but not in other types of CTCLs¹³.

TOX is a transcription factor with a role in the development of CD4⁺ T cells, including downstream effects on the expression of *RUNX 3*, a well-known tumor suppressor gene. Studies show that the overexpression of TOX and its protein product is associated with thicker lesions of MF, disease progression, and poor prognosis. Furthermore, dysregulation of this gene is reported in lesions and peripheral blood mononuclear cells of cases with SS²².

Patients with CTCL show a distinct microRNA (miRNA) expression profile. Studies have shown that miR-21 and miR-155 are associated with poor prognosis and aggressive behavior by interfering with resistance to apoptosis and promoting malignant proliferation, respectively. On the other hand, the expression of miR-22, a tumor suppressor, is downregulated in SS. It appears that Jak-3/STAT is responsible for the loss of miR-22 expression²⁵. miR-16 is another non-coding microRNA that induces cellular senescence and is downregulated in CTCLs³³. Studies have shown that miRNAs inhibit the expression of many oncogenes such as *MAX*, *MYCBP*, nuclear receptor coactivator-1 (*NCOA-1*), and cyclin-dependent kinase-6 (*CDK-6*)²⁵.

A role for IL-2Rgc-signaling cytokines, including IL-2, IL-4, IL-7, IL-15, and IL-21, has been suggested in the pathogenesis of CTCLs²⁵. IL-12 plays a role as a potent anti-tumor agent. Its expression is decreased during tumoral-stage MF³⁶. On the other hand, in lesional skin of CTCLs, increased expression of IL-9 that is regulated by STAT3/5 and silencing of STAT5 has been reported³⁷. Additionally, upregulation of CC chemokine receptor 6 (CCR6)³⁸ and CCR7³ has been reported in CTCLs and alleged to be responsible for spreading malignant T cells to sentinel lymph nodes, the bloodstream, and internal organs. Chemokine (C-X-C motif) ligand12 (CXCL12) belongs to the superfamily of chemokines that is expressed on endothelial and stromal cells in different organs. Most hematopoietic cells such as CD34⁺ progenitor cells and CD4⁺ T cells express CXCR4, the receptor of this chemokine. This receptor plays a role in chemotaxis, invasion, angiogenesis, and proliferation. The role of the CXCR4/CXCL12 axis has been implicated in the pathogenesis of MF¹⁰.

In CTCLs, malignant T cells display activation of the T cell receptor (TCR) pathway, which leads to TCR-dependent T helper 2

(Th2) cytokines such as IL-4 and IL-13 and resistance to natural mechanisms that prevent uncontrolled proliferation, such as Fas cell surface death receptor (FAS)-mediated apoptosis and transforming growth factor-beta-mediated growth suppression¹². Regulatory T cells with a CD4⁺ CD25⁺ phenotype comprise about 5% to 10% of peripheral T cells and play a role in tumor immunology. The role of these cells in CTCLs is controversial. Most studies have shown that, in CTCLs, a high count of FOXP3⁺ regulatory T cells is correlated with improved prognosis. This finding is completely opposite to that of studies on the role of these cells in solid tumors²⁷.

Studies have shown that CD26 is able to cleave and inactivate CXCL12; hence, its lack of expression in CTCLs results in enhanced CXCL12-dependent chemotaxis¹⁰. On the other hand, CD164 is significantly overexpressed on CD4⁺ lymphocytes in SS. It seems that this factor can be a diagnostic parameter and a potential target for therapeutic approaches in SS³⁹. These are zinc-dependent enzymes implicated in gene regulation and in the modulation of numerous cellular pathways, including proliferation, differentiation, apoptosis, and migration. Aberration in the activity of these enzymes and their mutations has been reported in CTCLs¹.

In MF, the malignant cells migrate to the skin by using the ligand E-selectin on endothelial cells by the expression of a marker for skin homing, cutaneous lymphocyte-associated antigen (CLA). The ability of CLA to mediate leukocyte homing to the skin is dependent on specific chemokine receptor-ligand interactions. One of these interactions occurs through chemokine receptor CCR4; overexpression of this receptor has been reported in CTCL cases with peripheral blood involvement¹.

Granulysin is a cytotoxic, proinflammatory, and anti-microbial agent that is expressed along with granzymes and perforin in granules of cytotoxic T cells and natural killer cells. It plays a role in innate immunity, chemotaxis, and tumor immunology and has been shown to be involved in the progression of MF²⁷. Mucin 1 C-terminal subunit controls important pathways of oncogenesis by governing cell proliferation, self-renewal, tissue invasion, and apoptosis. This heterodimeric protein protects cells against reactive oxygen species-induced death. Overexpression of this protein has been shown in CTCL cell lines⁴⁰. It has been suggested that the maintenance of redox balance plays a critical factor in protecting malignant cells in the CTCLs from apoptosis⁴⁰.

Cancer stem cells have many similarities to normal stem cells, including infrequent division, high self-renewal capacity, resistance to apoptosis, and ability to maintain an undifferentiated state, overcome cellular senescence, and differentiate to all cell types. Because of their rare cell divisions, they are resistant to chemotherapeutic agents. Additionally, these cells are responsible for relapse and metastasis of tumors. The expression of embryonic stem cell genes such as Nanog homeobox (*NANOG*), *SRY* (sex determining region Y)-box (*SOX*)-2, and *OCT4* (*POU* class 5 homeobox [*POU5F1*]-1) and their upstream and downstream signaling members was shown in CTCL lesions².

It was proposed that the formation of blood and lymphatic vasculature is involved in the progression of CTCL. Malignant T cells

produce several angiogenic factors, such as podoplanin (PDPN), lymphatic vessel hyaluronan receptor-1 (LYVE-1), vascular endothelial growth factor-C (VEGF-C), VEGF-R3, and lymphotoxin alpha (LT α), which play roles in neoangiogenesis and neo-lymphoangiogenesis. The interaction of LT α , IL-6, and VEGF has been shown to induce angiogenesis by promoting endothelial cell sprouting and tube formation³.

Some studies have reported an association between chronic cutaneous inflammation and subsequent development of CTCL⁹. Chronic or professional exposure to topical chemical agents, long-lasting psoriasis, and urticaria have been proposed as risk factors²¹. Chronically activated T lymphocytes may eventually result in the creation of an atypical T cell clone⁹. For instance, in granulomatous MF, it appears the granulomatous inflammation may precede the lymphoma, resulting in lymphocyte proliferation through macrophage-produced IL-6⁴¹.

A relationship between microbial colonization/infection and MF has been suggested^{9,42}. It has been shown that bacterial isolates containing staphylococcal enterotoxin-A (SEA) promote disease progression by inducing STAT3 activation and IL-17 expression in malignant T cells⁴². On the other hand, during the evolutionary process of CTCLs, loss of the normal TCR repertoire results in immunosuppression and opportunistic infections leading to death¹².

The role of viral infection in the pathogenesis of the CTCLs remains controversial. Recently, the role of retroviruses such as human T cell leukemia virus type 1 (HTLV-1) and HTLV-2 and human immunodeficiency virus and herpesvirus family members like Epstein-Barr virus, human herpesvirus 8, and cytomegalovirus have been suggested in the pathogenesis of these disorders. Viral infection may promote tumoral infiltration by inducing the production of tumor necrosis factor-alpha (TNF- α), IL-6, and IL-1a in keratinocytes. Additionally, in the skin, these organisms play the role of a stable chronic antigen, which results in a clonal proliferation of T cells, leading to CTCLs⁴.

Diagnosis

The diagnosis of CTCLs is difficult at early stages because of the presence of multiple clinical presentations^{1,43,44} and lack of definitive diagnostic criteria^{1,45}. Hence, in most cases, it takes an average of 6 years from disease onset until confirmation of the diagnosis^{1,44}.

Recently, there have been advances in the accurate diagnosis of CTCLs. To diagnose the CTCLs, guidelines prepared by the National Comprehensive Cancer Network recommend biopsy of suspicious skin sites and subsequent assessment in terms of dermatopathology, immunohistochemistry, and molecular analysis (TCR gene rearrangement)¹⁴. Observation and palpation of the skin are mainstays in suspecting CTCLs. Palpation of lymph nodes remains the traditional approach for staging of these disorders^{14,45,46}. Frequently, many biopsies are required to make the definitive diagnosis, as morphologic and phenotypic manifestations of CTCLs are variable and information derived from a single biopsy can lead to misdiagnosis^{18,19,45,46}. Identifying malignant cells in the peripheral blood of patients with CTCL is invaluable for detecting SS in early stages and determining prognosis^{47,48}.

However, blood analysis is of limited value because there is no precise marker in this analysis to detect the CTCLs in a sensitive way^{9,14}. Lactate dehydrogenase (LDH) is a non-specific marker of tumor burden and is related to poor prognosis of CTCLs^{9,14}. These studies provide a robust technique for assessing aberration of genes in the CTCLs^{3,35}.

Detection of a malignant T cell clone is a critical marker for definite diagnosis of CTCLs. TCR γ polymerase chain reaction (PCR) analysis detects clones of T cells in only a subset of patients, whereas the sensitivity and specificity of high-throughput TCR sequencing to detect T cell clones are higher than in TCR γ PCR. Indeed, the technique of high-throughput TCR sequencing is useful for the accurate diagnosis of all stages of CTCLs, differentiation of these disorders from benign inflammatory disorders, and determination of origin and location of malignant CTCL cells^{14,44}. Detection of malignant cells using flow cytometry in patients with SS is an important marker for diagnosing SS^{14,39,45}. In advanced cases, biopsies from bone marrow and lymph nodes are important factors in diagnosis¹⁴.

The loss of cell surface markers such as CD26, CD27, and CD7 on malignant T cells is of value in diagnosing CTCLs. On the other hand, the overexpression of CD164 has been reported on CD4⁺ T cells of patients with SS. In flow cytometric studies, detection of more than 20% CD164 on CD4⁺ cells in the blood of erythrodermic cases is highly suspicious for SS. However, the sensitivity and specificity of these assays should be interpreted with caution⁴⁸. PCTCL-NOS is characterized by variable loss of almost all T cell antigens, CD56 positivity, and limited or absent CD30 expression⁸. Ki67, CD34, and AgNORs are parameters of cell proliferation and angiogenesis that are well-known markers for progression of CTCLs. They are highly expressed in advanced stages of MF and are associated with shorter survival¹⁰.

T-cell-specific soluble IL-2 receptor (sIL-2r)⁹ is not specific for diagnosing CTCL but is a potential marker for activity, severity, and prognosis of this disorder. The association between increased sIL-2r and either adnexal disease or advanced-stage MF has been reported. This factor has better specificity as a prognostic factor than does LDH⁹.

Recent studies have confirmed the role of the *TOX* gene as a disease marker of CTCLs. Moreover, this gene is a candidate for therapeutic targeting²². Studies have suggested that *EPHA4* can be a diagnostic and prognostic marker for SS¹³. miRNA profiling is a diagnostic marker for CTCLs. Studies have shown that minimal miRNA classifiers can determine malignant dermatoses²⁵.

HTLV serology should be considered in advanced cases¹⁴. Magnetic resonance imaging (MRI) or computed tomography (CT) scan⁹ is used to investigate nodal and systemic involvement^{9,46}. Fluorine-18 fluorodeoxyglucose positron emission tomography-CT (¹⁸F-FDG PET-CT)⁴⁶ can determine cutaneous and extracutaneous lesions in CTCLs, response to therapy, and disease recurrence. In comparison with CT scan, this modality is more sensitive and specific in detecting both cutaneous and extracutaneous involvement, particularly in determining lymph node involvement⁴⁶.

Management

There is no known cure for MF and SS¹¹; hence, therapeutic options are mostly palliative^{1,49}, and the goals of treatment include relieving symptoms, inducing remission, and postponing progression while decreasing significant side effects caused by therapeutic modalities¹². Multi-drug therapeutic approaches are inappropriate for CTCLs because of the high risk of infection in patients with poor skin barrier⁵⁰.

Before choosing the best option for treating this malignant condition, accurate staging is essential^{1,46,51}. Generally, therapeutic options are classified into two groups. Skin-directed therapies^{1,11,45,52,53} are the first choice for treating early stages of disease (IA to IIA) when involving less than 20% of the body surface¹. Systemic therapies^{1,11,45,52,53} are used for refractory cases in the early stages and cases with advanced stages (at least IIB)^{1,6}.

Corticosteroids in topical and systemic forms are effective in treating CTCLs^{9,54,55}. Topical corticosteroids can be employed for treating refractory cases of both early stage disease and more advanced cases. One of the problems with corticosteroid therapy is relapse of disease¹.

Retinoids are effective in treating the CTCLs through anti-proliferative and apoptosis-inducing effects^{56,57}. Retinoic acid receptor β 2 works as a tumor suppressor gene⁵⁶. Among topical retinoids, bexarotene, also known as Targretin, is approved by the US Food and Drug Administration (FDA) for treating stage I MF^{1,58,59} and relapsed refractory CTCLs⁵⁸. Severe mixed hyperlipidemia with a significant decrease in high-density lipoprotein cholesterol level and central hypothyroidism are reversible, dose-dependent adverse effects of bexarotene⁶⁰. Tazarotene is another topical retinoid whose efficacy as a monotherapy has been shown in treating stages I to IIA CTCL⁶¹. Systemic retinoids such as acitretin, isotretinoin, and bexarotene have been used successfully in the treatment of CTCLs⁹.

HDACIs, classified as anti-neoplastic agents, are novel therapeutic options for treating CTCLs^{1,9,62}. Their mechanisms of action are via transcription-dependent and transcription-independent ways¹¹, including (a) promoting the expression of genes that regulate cell differentiation and apoptosis, (b) inducing changes to the structural integrity of chromatin¹, (c) regulating miR-22 expression²⁵, and (d) increasing the production of reactive oxygen species and decreasing mitochondrial membrane⁶³. These agents preferentially destroy transformed cells over normal cells¹¹.

In this therapeutic group, vorinostat^{1,11,50,58} and romidepsin^{1,11,50,58,63} are FDA approved for treating progressive, persistent, or recurrent CTCLs. These agents, when given as single agents, can induce an overall response rate of 30% to 35%, but a complete response rate is seen in only 2% to 6% of cases¹¹. Entinostat, belinostat, panobinostat¹, AN-7¹¹, and quisinostat⁶⁴ are other HDACIs currently under study. Generally, HDACIs are well tolerated. Fatigue, gastrointestinal discomfort, thrombocytopenia, neutropenia, anemia, and dehydration are insignificant side effects which have been reported with these agents¹.

Imiquimod is a Toll-like receptor 7 (TLR7) agonist that is effective in treating MF. It works through inducing the production of interferon-alpha (IFN- α), TNF- α , IL-1 α , IL-6, and IL-8 from plasmacytoid dendritic cells, which are seen in inflamed and malignant skin lesions. The efficacy of topical resiquimod, an imidazoquinoline with TLR7- and TLR8-stimulating activity, was shown in treating early stage CTCLs. Its effectiveness in inducing regression of untreated lesions was reported, probably mediated by enhancing systemic anti-tumor immunity. Resiquimod appears to act by recruiting and expanding benign T cell clones, increasing skin T cell effector and natural killer cell functions⁵⁴.

Danileukin diftotox is a recombinant fusion protein^{9,50}, composed of diphtheria toxin and IL-2, approved by the FDA for treating CTCLs⁵¹.

The efficacy of zanolimumab and alemtuzumab in treating the CTCLs has been reported. Zanolimumab has a lower risk of infection than does alemtuzumab⁵⁰.

Cytokines such as IFN- α are effective in treating cases with MF and SS but can exacerbate PCTCL-NOS⁸. IFN- α 2b is still the best option as first-line systemic therapy for MF⁵¹. Recombinant IL-12 is beneficial in treating CTCLs by inducing cellular immunity and cytotoxic T cell responses in the host⁵⁴.

Chemotherapeutic agents play a role in managing CTCLs, but severe adverse effects are reported¹¹. For the most part, topical chemotherapeutic agents such as mechlorethamine (nitrogen mustard) and carmustine are successful in managing early stage disorders, but their effectiveness in treating advanced cases is doubtful^{1,11}. Mechlorethamine was approved by the FDA for the treatment of stage Ia and Ib MF. It is an alkylating agent, which acts by inhibiting proliferating cells and affecting keratinocyte-Langerhans cell-T cell interactions. Non-melanoma skin cancers have been seen in patients who have received this agent in combination with phototherapy, radiation, and immunosuppressive chemotherapy¹¹.

Other systemic chemotherapeutic agents that have been used to treat CTCLs include methotrexate, chlorambucil, gemcitabine, and pegylated doxorubicin⁹. Pralatrexate is a methotrexate analog approved by the FDA for treating relapsed or refractory CTCLs⁵⁰. Studies have shown variable efficacy for cyclophosphamide, doxorubicin, vincristine, and prednisone (CHOP) in the treatment of advanced cases of CTCLs^{9,50}.

Psoralen plus ultraviolet A (PUVA), ultraviolet B (UVB)⁹, UVA1, and excimer laser⁶⁵ are among the most common treatments used for achieving remission or avoidance of progression in MF. In comparison with PUVA, UVB is less effective at treating infiltrated lesions; additionally, remission duration is shorter with UVB⁹.

Radiotherapy is an effective skin-directed therapy for the treatment of CTCLs^{66,67}. Lymphocytes are sensitive to radiation therapy. In more advanced cases, radiation therapy to local lesions or to the entire skin can control disease. For cases with a single lesion, this modality can be curative⁶⁶.

Electron beam radiation therapy is effective in treating CTCLs^{49,50,68,69} in stages I to III⁵⁰. Whole-body total skin electron beam is an appropriate modality for more advanced cases^{1,50}. Complete response rate is lower in tumor-stage disease in comparison with plaque-stage cases (36% versus 98.3%)⁴⁹.

Conventional photodynamic therapy with aminolevulinic acid (ALA-PDT) is effective in a subset of CTCLs because it acts through apoptosis while the expression of death receptors like FAS in malignant T cells is low. The combination of methotrexate with ALA-PDT enhances the efficacy of photodynamic therapy through upregulating FAS by inhibiting the methylation of its promoter⁷⁰.

Extracorporeal photopheresis is an immunomodulating method resulting in the expansion of the peripheral blood dendritic cell population and enhancement of the TH1 immune response⁷¹. It is an appropriate modality for treating refractory, early stage MF⁷¹ and SS^{50,71}. With this modality, a partial response rate of 30% to 80% and a complete remission rate of 14% to 25% are estimated⁵⁰.

Allogeneic hematopoietic stem cell transplantations are used for treating advanced stages of MF, SS^{7,53,54,72,73}, and PCTCL-NOS⁸. Studies have shown that this therapeutic option is appropriate for young patients^{7,50,72} with relapsing diseases which progress in spite of several lines of chemotherapy⁷.

The efficacy of some agents, including tazarotene, lenalidomide, forodesine (BCX-1777), synthetic oligonucleotides, temozolomide, C-beta kinase inhibitor⁵⁰, mucin 1 C inhibitors⁴⁰, everolimus⁷⁴, PD1/PD-L1 inhibitors⁷⁵, brentuximab vedotin, and mogamulizumab, is under investigation^{62,75}.

As mucin 1 is overexpressed in cells of CTCLs, therapies targeting mucin 1 are effective in treating CTCLs. Theoretically, mucin 1 C inhibitors (such as GO-203), which increase the level of reactive oxygen species and lead to oxidative-stress-induced late apoptosis/necrosis, can be an effective treatment⁴⁰. Everolimus, which targets the mammalian target of rapamycin (mTOR) pathway, appears to be effective in treating T cell lymphoma by inhibiting malignant T cell proliferation⁷⁴.

Prognosis

CTCLs are lifelong disorders that recur after discontinuation of therapy, even in cases that do not progress⁵⁴. In spite of the introduction of several therapeutic options for CTCLs, as they progress and become refractory to treatment, the malignant cells have the propensity to infiltrate lymph nodes and peripheral blood vessels, resulting in debilitating states. Progression to tumor stage where the neoplastic cells spread to the lymph nodes and internal organs has been reported in less than 5% of cases with CTCL¹. In [Table 3](#), prognostic factors for CTCLs are listed^{1,5,8,9,12,14,22,27,39,40,46,51,52,76,77}.

In CTCL cases with visceral involvement, skin lesions are severe and the risk of skin infection is high. On the other hand, autopsy studies have shown that between 70% and 90% of patients with MF die with visceral involvement⁵. Moreover, primary CTCLs have distinctive clinical behavior in comparison with systemic lymphomas with skin involvement⁷⁸.

Table 3. Prognostic factors in cutaneous T cell lymphoma cases.

<p>Clinical factors</p> <p>Age^{5,8,52,77}</p> <p>Sex⁵²</p> <p>Staging^{47,52,53}</p> <p>Extent and type of cutaneous involvement^{1,9,47,53}</p> <p>Presence of extracutaneous involvement^{1,5,46,52} such as blood^{1,5,52,53}, bone marrow⁸, and adnexal⁹ involvement</p> <p>Disease progression¹</p> <p>Old refractoriness to successive treatment protocols⁵</p>
<p>Laboratory factors</p> <p>Proliferation index⁵²</p> <p>Folliculotropism⁵²</p> <p>Presence of Sézary cells^{5,40}</p> <p>Large cell transformation in histology^{14,41,52}</p> <p>White blood cell/lymphocyte count⁵²</p> <p>Loss of T cell receptor repertoire³⁹</p> <p>Increased level of soluble interleukin-2 receptor at initial diagnosis⁹</p> <p>Normal or high levels of lactate dehydrogenase^{8,52,77}</p> <p>CD30 expression of less than 10%^{52,77}</p> <p>Overexpression of TOX²²</p> <p>Expression of proliferation markers Ki-67, MCM-3, and MCM-7⁷⁸</p> <p>MicroRNA profiling²⁵</p> <p>Granulysin expression²⁷</p> <p>Presence of FOXP3⁺ regulatory T cells²⁷</p> <p>EPHA4 expression¹³</p>

At early stages, there is no significant difference between the life expectancy of patients with CTCL and that of healthy people^{1,5}, whereas in more progressed cases, life expectancy decreases to 3.2 to 9.9 years¹.

Patients with MF have a chronic course lasting from years to decades; many of them die from unrelated disorders, whereas about 25% of them die of lymphoma⁹. Immunosuppression and opportunistic infections are the most common causes of disease-related death¹¹. The prognosis of SS is poor. Its median survival rate is from 2 to 4 years¹, and its 5-year survival rate is approximately 18% to 20%⁷. In PCTCL-NOSs, the 5-year survival rate is less than 20%⁸.

Conclusion

Although there are many studies regarding the pathogenesis and management of the CTCLs, many questions about this complicated group of diseases remain unanswered.

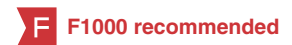Competing interests

The authors declare that they have no competing interests.

Grant information

The author(s) declared that no grants were involved in supporting this work.

References



1. Rodd AL, Verweris K, Karagiannis TC: **Current and Emerging Therapeutics for Cutaneous T-Cell Lymphoma: Histone Deacetylase Inhibitors.** *Lymphoma.* 2012; 2012: 1–10, 290685. [PubMed Abstract](#) | [Publisher Full Text](#)
2. Litvinov IV, Netchiporouk E, Cordeiro B, *et al.*: **Ectopic expression of embryonic stem cell and other developmental genes in cutaneous T-cell lymphoma.** *Oncoimmunology.* 2014; 3(11): e970025. [PubMed Abstract](#) | [Publisher Full Text](#) | [Free Full Text](#) | [F1000 Recommendation](#)
3. Lauenborg B, Christensen L, Ralfkiaer U, *et al.*: **Malignant T cells express lymphotoxin α and drive endothelial activation in cutaneous T cell lymphoma.** *Oncotarget.* 2015; 6(17): 15235–49. [PubMed Abstract](#) | [Publisher Full Text](#) | [Free Full Text](#) | [F1000 Recommendation](#)
4. Nahidi Y, Meibodi NT, Ghazvini K, *et al.*: **Evaluation of the Association Between Epstein-Barr Virus and Mycosis Fungoides.** *Indian J Dermatol.* 2015; 60(3): 321. [PubMed Abstract](#) | [Publisher Full Text](#) | [Free Full Text](#) | [F1000 Recommendation](#)
5. Gómez Venegas ÁA, Vargas Rubio RD: **Unusual involvement in mycosis fungoides: Duodenal papilla.** *Rev Esp Enferm Dig.* 2015. [PubMed Abstract](#) | [Publisher Full Text](#)
6. Devata S, Wilcox RA: **Cutaneous T-Cell Lymphoma: A Review with a Focus on Targeted Agents.** *Am J Clin Dermatol.* 2016; 17(3): 225–37. [PubMed Abstract](#) | [Publisher Full Text](#)
7. Väkevä L, Niittyvuopio R, Leppä S, *et al.*: **Allogeneic Haematopoietic Stem Cell Transplantation for Patients with Cutaneous T-cell Lymphoma.** *Acta Derm Venereol.* 2016. [PubMed Abstract](#) | [Publisher Full Text](#)
8. Aderhold K, Carpenter L, Brown K, *et al.*: **Primary Cutaneous Peripheral T-Cell Lymphoma Not Otherwise Specified: A Rapidly Progressive Variant of Cutaneous T-Cell Lymphoma.** *Case Rep Oncol Med.* 2015; 2015: 429068. [PubMed Abstract](#) | [Publisher Full Text](#) | [Free Full Text](#)
9. Eklund Y, Aronsson A, Schmidtchen A, *et al.*: **Mycosis Fungoides: A Retrospective Study of 44 Swedish Cases.** *Acta Derm Venereol.* 2016; 96(5): 669–73. [PubMed Abstract](#) | [Publisher Full Text](#)
10. Maj J, Jankowska-Konsur AM, Haloń A, *et al.*: **Expression of CXCR4 and CXCL12 and their correlations to the cell proliferation and angiogenesis in mycosis fungoides.** *Postepy Dermatol Alergol.* 2015; 32(6): 437–42. [PubMed Abstract](#) | [Publisher Full Text](#) | [Free Full Text](#)
11. Moyal L, Feldbaum N, Goldfeiz N, *et al.*: **The Therapeutic Potential of AN-7, a Novel Histone Deacetylase Inhibitor, for Treatment of Mycosis Fungoides/Sézary Syndrome Alone or with Doxorubicin.** *PLoS One.* 2016; 11(1): e0146115. [PubMed Abstract](#) | [Publisher Full Text](#) | [Free Full Text](#)
12. Choi J, Goh G, Walradt T, *et al.*: **Genomic landscape of cutaneous T cell lymphoma.** *Nat Genet.* 2015; 47(9): 1011–9. [PubMed Abstract](#) | [Publisher Full Text](#) | [Free Full Text](#) | [F1000 Recommendation](#)
13. Hameetman L, van der Fits L, Zoutman WH, *et al.*: **EPHA4 is overexpressed but not functionally active in Sézary syndrome.** *Oncotarget.* 2015; 6(31): 31868–76. [PubMed Abstract](#) | [Publisher Full Text](#) | [Free Full Text](#)
14. Benjamin Chase A, Markel K, Tawa MC: **Optimizing Care and Compliance for the Treatment of Mycosis Fungoides Cutaneous T-Cell Lymphoma With Mechlorethamine Gel.** *Clin J Oncol Nurs.* 2015; 19(6): E131–9. [PubMed Abstract](#) | [Publisher Full Text](#)
15. Foo SH, Shah F, Chaganti S, *et al.*: **Unmasking mycosis fungoides/Sézary syndrome from preceding or co-existing benign inflammatory dermatoses requiring systemic therapies: patients frequently present with advanced disease and have an aggressive clinical course.** *Br J Dermatol.* 2016; 174(4): 901–4. [PubMed Abstract](#) | [Publisher Full Text](#)
16. Pankratov O, Gradova S, Tarasevich S, *et al.*: **Poikilodermatous mycosis fungoides: clinical and histopathological analysis of a case and literature review.** *Acta Dermatovenerol Alp Pannonica Adriat.* 2015; 24(2): 37–41. [PubMed Abstract](#) | [Publisher Full Text](#)
17. LeBlanc RE, Tavallaee M, Kim YH, *et al.*: **Useful Parameters for Distinguishing Subcutaneous Panniculitis-like T-Cell Lymphoma From Lupus Erythematosus Panniculitis.** *Am J Surg Pathol.* 2016; 40(6): 745–54. [PubMed Abstract](#) | [Publisher Full Text](#)
18. Smoller BR, Bishop K, Glusac E, *et al.*: **Reassessment of histologic parameters in the diagnosis of mycosis fungoides.** *Am J Surg Pathol.* 1995; 19(12): 1423–30. [PubMed Abstract](#)
19. Kash N, Massone C, Fink-Puches R, *et al.*: **Phenotypic Variation in Different Lesions of Mycosis Fungoides Biopsied Within a Short Period of Time From the Same Patient.** *Am J Dermatopathol.* 2016; 38(7): 541–5. [PubMed Abstract](#) | [Publisher Full Text](#)
20. Smoller BR: **Mycosis fungoides: what do/do not we know?** *J Cutan Pathol.* 2008; 35(Suppl 2): 35–9. [PubMed Abstract](#) | [Publisher Full Text](#)
21. Lebas E, Libon F, Nikkels AF: **Koebner Phenomenon and Mycosis Fungoides.** *Case Rep Dermatol.* 2015; 7(3): 287–91. [PubMed Abstract](#) | [Publisher Full Text](#) | [Free Full Text](#)
22. Dulmage BO, Akilov O, Vu JR, *et al.*: **Dysregulation of the TOX-RUNX3 pathway in cutaneous T-cell lymphoma.** *Oncotarget.* 2015. [PubMed Abstract](#) | [Publisher Full Text](#) | [F1000 Recommendation](#)
23. Wang L, Ni X, Covington KR, *et al.*: **Genomic profiling of Sézary syndrome identifies alterations of key T cell signaling and differentiation genes.** *Nat Genet.* 2015; 47(12): 1426–34. [PubMed Abstract](#) | [Publisher Full Text](#) | [Free Full Text](#)
24. da Silva Almeida AC, Abate F, Khiabani H, *et al.*: **The mutational landscape of cutaneous T cell lymphoma and Sézary syndrome.** *Nat Genet.* 2015; 47(12): 1465–70. [PubMed Abstract](#) | [Publisher Full Text](#) | [Free Full Text](#)
25. Sibbesen NA, Kopp KL, Litvinov IV, *et al.*: **Jak3, STAT3, and STAT5 inhibit expression of miR-22, a novel tumor suppressor microRNA, in cutaneous T-Cell lymphoma.** *Oncotarget.* 2015; 6(24): 20555–69. [PubMed Abstract](#) | [Publisher Full Text](#) | [Free Full Text](#) | [F1000 Recommendation](#)
26. Woollard WJ, Kalaivani NP, Jones CL, *et al.*: **Independent Loss of Methylthioadenosine Phosphorylase (MTAP) in Primary Cutaneous T-Cell Lymphoma.** *J Invest Dermatol.* 2016; 136(6): 1238–46. [PubMed Abstract](#) | [Publisher Full Text](#)
27. Shareef MM, Elgarhy LH, Wasfy Rel-S: **Expression of Granulysin and FOXP3 in Cutaneous T Cell Lymphoma and Sézary Syndrome.** *Asian Pac J Cancer Prev.* 2015; 16(13): 5359–64. [PubMed Abstract](#) | [Publisher Full Text](#) | [F1000 Recommendation](#)
28. McGirt LY, Jia P, Baerenwald DA, *et al.*: **Whole-genome sequencing reveals oncogenic mutations in mycosis fungoides.** *Blood.* 2015; 126(4): 508–19. [PubMed Abstract](#) | [Publisher Full Text](#) | [Free Full Text](#)
29. Jankowska-Konsur A, Kobierzycki C, Reich A, *et al.*: **Expression of SATB1, MT1/II and Ki-67 in Mycosis Fungoides.** *Anticancer Res.* 2016; 36(1): 189–97. [PubMed Abstract](#)
30. Ungewickell A, Bhaduri A, Rios E, *et al.*: **Genomic analysis of mycosis fungoides and Sézary syndrome identifies recurrent alterations in TNFR2.** *Nat Genet.* 2015; 47(8): 1056–60. [PubMed Abstract](#) | [Publisher Full Text](#) | [F1000 Recommendation](#)
31. Gallardo F, Sandoval J, Díaz-Lagares A, *et al.*: **Notch1 Pathway Activation Results from the Epigenetic Abrogation of Notch-Related MicroRNAs in Mycosis Fungoides.** *J Invest Dermatol.* 2015; 135(12): 3144–52. [PubMed Abstract](#) | [Publisher Full Text](#)
32. Tensen CP: **PLCG1 Gene Mutations in Cutaneous T-Cell Lymphomas Revisited.** *J Invest Dermatol.* 2015; 135(9): 2153–4. [PubMed Abstract](#) | [Publisher Full Text](#)
33. Kitadate A, Ikeda S, Teshima K, *et al.*: **MicroRNA-16 mediates the regulation of a senescence-apoptosis switch in cutaneous T-cell and other non-Hodgkin lymphomas.** *Oncogene.* 2016; 35(28): 3692–704. [PubMed Abstract](#) | [Publisher Full Text](#)
34. Katona TM, Smoller BR, Webb AL, *et al.*: **Expression of PTEN in mycosis fungoides and correlation with loss of heterozygosity.** *Am J Dermatopathol.* 2013; 35(5): 555–60. [PubMed Abstract](#) | [Publisher Full Text](#)
35. Katona TM, O'Malley DP, Cheng L, *et al.*: **Loss of heterozygosity analysis identifies genetic abnormalities in mycosis fungoides and specific loci associated with disease progression.** *Am J Surg Pathol.* 2007; 31(10): 1552–6. [PubMed Abstract](#) | [Publisher Full Text](#)
36. Kabasawa M, Sugaya M, Oka T, *et al.*: **Decreased interleukin-21 expression in skin and blood in advanced mycosis fungoides.** *J Dermatol.* 2016; 43(7): 819–22. [PubMed Abstract](#) | [Publisher Full Text](#)
37. Vieyra-Garcia PA, Wei T, Naym DG, *et al.*: **STAT3/5-Dependent IL9 Overexpression Contributes to Neoplastic Cell Survival in Mycosis Fungoides.** *Clin Cancer Res.* 2016; 22(13): 3328–39. [PubMed Abstract](#) | [Publisher Full Text](#)
38. Ikeda S, Kitadate A, Ito M, *et al.*: **Disruption of CCL20-CCR6 interaction inhibits metastasis of advanced cutaneous T-cell lymphoma.** *Oncotarget.* 2016; 7(12): 13563–74. [PubMed Abstract](#) | [Publisher Full Text](#) | [Free Full Text](#) | [F1000 Recommendation](#)
39. Guenova E, Ignatova D, Chang YT, *et al.*: **Expression of CD164 on Malignant T cells in Sézary Syndrome.** *Acta Derm Venereol.* 2016; 96(4): 464–7. [PubMed Abstract](#) | [Publisher Full Text](#) | [F1000 Recommendation](#)
40. Jain S, Stroopinsky D, Yin L, *et al.*: **Mucin 1 is a potential therapeutic target in cutaneous T-cell lymphoma.** *Blood.* 2015; 126(3): 354–62. [PubMed Abstract](#) | [Publisher Full Text](#) | [Free Full Text](#) | [F1000 Recommendation](#)
41. Pousa CM, Nery NS, Mann D, *et al.*: **Granulomatous mycosis fungoides—a diagnostic challenge.** *An Bras Dermatol.* 2015; 90(4): 554–6. [PubMed Abstract](#) | [Publisher Full Text](#) | [Free Full Text](#)

42. **F** Willerslev-Olsen A, Krejsgaard T, Lindahl LM, *et al.*: **Staphylococcal enterotoxin A (SEA) stimulates STAT3 activation and IL-17 expression in cutaneous T-cell lymphoma.** *Blood*. 2016; **127**(10): 1287–96.
[PubMed Abstract](#) | [Publisher Full Text](#) | [Free Full Text](#) | [F1000 Recommendation](#)
43. Sidiropoulos KG, Martinez-Escala ME, Yelamos O, *et al.*: **Primary cutaneous T-cell lymphomas: a review.** *J Clin Pathol*. 2015; **68**(12): 1003–10.
[PubMed Abstract](#) | [Publisher Full Text](#)
44. **F** Kirsch IR, Watanabe R, O'Malley JT, *et al.*: **TCR sequencing facilitates diagnosis and identifies mature T cells as the cell of origin in CTCL.** *Sci Transl Med*. 2015; **7**(308): 308ra158.
[PubMed Abstract](#) | [Publisher Full Text](#) | [Free Full Text](#) | [F1000 Recommendation](#)
45. Hughes CF, Newland K, McCormack C, *et al.*: **Mycosis fungoides and Sézary syndrome: Current challenges in assessment, management and prognostic markers.** *Australas J Dermatol*. 2015.
[PubMed Abstract](#) | [Publisher Full Text](#)
46. **F** Alanteri E, Usmani S, Marafi F, *et al.*: **The role of fluorine-18 fluorodeoxyglucose positron emission tomography in patients with mycosis fungoides.** *Indian J Nucl Med*. 2015; **30**(3): 199–203.
[PubMed Abstract](#) | [Publisher Full Text](#) | [Free Full Text](#) | [F1000 Recommendation](#)
47. Gibson JF, Huang J, Liu KJ, *et al.*: **Cutaneous T-cell lymphoma (CTCL): Current practices in blood assessment and the utility of T-cell receptor (TCR)-V β chain restriction.** *J Am Acad Dermatol*. 2016; **74**(5): 870–7.
[PubMed Abstract](#) | [Publisher Full Text](#) | [Free Full Text](#)
48. Aggarwal S, Topaloglu H, Kumar S: **Systematic Review Of Burden Of Cutaneous T-Cell Lymphoma.** *Value Health*. 2015; **18**(7): A438.
[PubMed Abstract](#) | [Publisher Full Text](#)
49. Ahmed SK, Grams MP, Locher SE, *et al.*: **Adaptation of the Stanford technique for treatment of bulky cutaneous T-cell lymphoma of the head.** *Pract Radiat Oncol*. 2016; **6**(3): 183–6.
[PubMed Abstract](#) | [Publisher Full Text](#)
50. Chmielowska E, Studziński M, Giebel S, *et al.*: **Follow-up of patients with mycosis fungoides after interferon α 2b treatment failure.** *Postepy Dermatol Alergol*. 2015; **32**(2): 67–72.
[PubMed Abstract](#) | [Publisher Full Text](#) | [Free Full Text](#)
51. Scarisbrick JJ, Prince HM, Vermeer MH, *et al.*: **Cutaneous Lymphoma International Consortium Study of Outcome in Advanced Stages of Mycosis Fungoides and Sézary Syndrome: Effect of Specific Prognostic Markers on Survival and Development of a Prognostic Model.** *J Clin Oncol*. 2015; **33**(32): 3766–73.
[PubMed Abstract](#) | [Publisher Full Text](#)
52. Wilcox RA: **Cutaneous T-cell lymphoma: 2016 update on diagnosis, risk-stratification, and management.** *Am J Hematol*. 2016; **91**(1): 151–65.
[PubMed Abstract](#) | [Publisher Full Text](#) | [Free Full Text](#)
53. Virmani P, Zain J, Rosen ST, *et al.*: **Hematopoietic Stem Cell Transplant for Mycosis Fungoides and Sézary Syndrome.** *Dermatol Clin*. 2015; **33**(4): 807–18.
[PubMed Abstract](#) | [Publisher Full Text](#)
54. **F** Rook AH, Gelfand JM, Wysocka M, *et al.*: **Topical resiquimod can induce disease regression and enhance T-cell effector functions in cutaneous T-cell lymphoma.** *Blood*. 2015; **126**(12): 1452–61.
[PubMed Abstract](#) | [Publisher Full Text](#) | [Free Full Text](#) | [F1000 Recommendation](#)
55. Nguyen CV, Bohjanen KA: **Skin-Directed Therapies in Cutaneous T-Cell Lymphoma.** *Dermatol Clin*. 2015; **33**(4): 683–96.
[PubMed Abstract](#) | [Publisher Full Text](#)
56. Kato Y, Egusa C, Maeda T, *et al.*: **Combination of retinoid and histone deacetylase inhibitor produced an anti-tumor effect in cutaneous T-cell lymphoma by restoring tumor suppressor gene, retinoic acid receptor β 2, via histone acetylation.** *J Dermatol Sci*. 2016; **81**(1): 17–25.
[PubMed Abstract](#) | [Publisher Full Text](#)
57. Huen AO, Kim EJ: **The Role of Systemic Retinoids in the Treatment of Cutaneous T-Cell Lymphoma.** *Dermatol Clin*. 2015; **33**(4): 715–29.
[PubMed Abstract](#) | [Publisher Full Text](#)
58. Zinzani PL, Bonthapally V, Huebner D, *et al.*: **Panoptic clinical review of the current and future treatment of relapsed/refractory T-cell lymphomas: Cutaneous T-cell lymphomas.** *Crit Rev Oncol Hematol*. 2016; **99**: 228–40.
[PubMed Abstract](#) | [Publisher Full Text](#)
59. Marciano DP, Kuruvilla DS, Pascal BD, *et al.*: **Identification of Bexarotene as a PPAR γ Antagonist with HDX.** *PPAR Res*. 2015; **2015**: 254560.
[PubMed Abstract](#) | [Publisher Full Text](#) | [Free Full Text](#)
60. Rodriguez Suarez S, Parnies Andreu E, Muñoz Grijalvo O, *et al.*: **[Thyroid and lipidic dysfunction associated with bexarotene in cutaneous T-cell lymphoma].** *Med Clin (Barc)*. 2016; **146**(3): 117–20.
[PubMed Abstract](#) | [Publisher Full Text](#)
61. **F** Besner Morin C, Roberge D, Turchin I, *et al.*: **Tazarotene 0.1% Cream as Monotherapy for Early-Stage Cutaneous T-Cell Lymphoma.** *J Cutan Med Surg*. 2016; **20**(3): 244–8.
[PubMed Abstract](#) | [Publisher Full Text](#) | [F1000 Recommendation](#)
62. Chung CG, Poligone B: **Cutaneous T cell Lymphoma: an Update on Pathogenesis and Systemic Therapy.** *Curr Hematol Malig Rep*. 2015; **10**(4): 468–76.
[PubMed Abstract](#) | [Publisher Full Text](#)
63. Valdez BC, Brammer JE, Li Y, *et al.*: **Romidepsin targets multiple survival signaling pathways in malignant T cells.** *Blood Cancer J*. 2015; **5**: e357.
[PubMed Abstract](#) | [Publisher Full Text](#) | [Free Full Text](#)
64. Child F, Ortiz-Romero PL, Alvarez R, *et al.*: **Phase II Multicenter Trial of Oral Quisinstat, a Histone Deacetylase Inhibitor, in Patients with Previously Treated Stage IB-IVA Mycosis Fungoides/Sézary Syndrome.** *Br J Dermatol*. 2016.
[PubMed Abstract](#) | [Publisher Full Text](#)
65. Olsen EA, Hodak E, Anderson T, *et al.*: **Guidelines for phototherapy of mycosis fungoides and Sézary syndrome: A consensus statement of the United States Cutaneous Lymphoma Consortium.** *J Am Acad Dermatol*. 2016; **74**(1): 27–58.
[PubMed Abstract](#) | [Publisher Full Text](#)
66. **F** Tandberg DJ, Craciunescu O, Kelsey CR: **Radiation Therapy for Cutaneous T-Cell Lymphomas.** *Dermatol Clin*. 2015; **33**(4): 703–13.
[PubMed Abstract](#) | [Publisher Full Text](#) | [F1000 Recommendation](#)
67. **F** Goddard AL, Vleugels RA, LeBoeuf NR, *et al.*: **Palliative Therapy for Recalcitrant Cutaneous T-Cell Lymphoma of the Hands and Feet With Low-Dose, High Dose-Rate Brachytherapy.** *JAMA Dermatol*. 2015; **151**(12): 1354–7.
[PubMed Abstract](#) | [Publisher Full Text](#) | [F1000 Recommendation](#)
68. Elsayad K, Kriz J, Moustakis C, *et al.*: **Total Skin Electron Beam for Primary Cutaneous T-cell Lymphoma.** *Int J Radiat Oncol Biol Phys*. 2015; **93**(5): 1077–86.
[PubMed Abstract](#) | [Publisher Full Text](#)
69. Gamsiz H, Beyzadeoglu M, Sager O, *et al.*: **Evaluation of mycosis fungoides management by total skin electron beam therapy with "translational technique".** *J BUON*. 2015; **20**(4): 1124–31.
[PubMed Abstract](#)
70. **F** Salva KA, Wood GS: **Epigenetically Enhanced Photodynamic Therapy (ePDT) is Superior to Conventional Photodynamic Therapy for Inducing Apoptosis in Cutaneous T-Cell Lymphoma.** *Photochem Photobiol*. 2015; **91**(6): 1444–51.
[PubMed Abstract](#) | [Publisher Full Text](#) | [Free Full Text](#) | [F1000 Recommendation](#)
71. Zic JA: **Extracorporeal Photopheresis in the Treatment of Mycosis Fungoides and Sézary Syndrome.** *Dermatol Clin*. 2015; **33**(4): 765–76.
[PubMed Abstract](#) | [Publisher Full Text](#)
72. Oka T, Sugaya M, Cury-Martins J, *et al.*: **Hematopoietic stem cell transplantation for cutaneous T-cell lymphoma: Summary of 11 cases from two facilities in Japan and Brazil.** *J Dermatol*. 2016; **43**(6): 638–42.
[PubMed Abstract](#) | [Publisher Full Text](#)
73. Hosing C, Bassett R, Dabaja B, *et al.*: **Allogeneic stem-cell transplantation in patients with cutaneous lymphoma: updated results from a single institution.** *Ann Oncol*. 2015; **26**(12): 2490–5.
[PubMed Abstract](#) | [Publisher Full Text](#) | [Free Full Text](#)
74. **F** Witzig TE, Reeder C, Han JJ, *et al.*: **The mTORC1 inhibitor everolimus has antitumor activity *in vitro* and produces tumor responses in patients with relapsed T-cell lymphoma.** *Blood*. 2015; **126**(3): 328–35.
[PubMed Abstract](#) | [Publisher Full Text](#) | [Free Full Text](#) | [F1000 Recommendation](#)
75. Rozati S, Kim YH: **Experimental treatment strategies in primary cutaneous T-cell lymphomas.** *Curr Opin Oncol*. 2016; **28**(2): 166–71.
[PubMed Abstract](#) | [Publisher Full Text](#)
76. Talpur R, Sui D, Gangar P, *et al.*: **Retrospective Analysis of Prognostic Factors in 187 Cases of Transformed Mycosis Fungoides.** *Clin Lymphoma Myeloma Leuk*. 2016; **16**(1): 49–56.
[PubMed Abstract](#) | [Publisher Full Text](#)
77. Jankowska-Konsur A, Kobierzycki C, Reich A, *et al.*: **Expression of MCM-3 and MCM-7 in Primary Cutaneous T-cell Lymphomas.** *Anticancer Res*. 2015; **35**(11): 6017–26.
[PubMed Abstract](#)
78. Lee HS, Suh KS, Lee DY, *et al.*: **Cutaneous Lymphoma in Korea: A Nationwide Retrospective Study.** *Acta Derm Venereol*. 2016; **96**(4): 535–9.
[PubMed Abstract](#) | [Publisher Full Text](#)

Open Peer Review

Current Referee Status:



Editorial Note on the Review Process

F1000 Faculty Reviews are commissioned from members of the prestigious **F1000 Faculty** and are edited as a service to readers. In order to make these reviews as comprehensive and accessible as possible, the referees provide input before publication and only the final, revised version is published. The referees who approved the final version are listed with their names and affiliations but without their reports on earlier versions (any comments will already have been addressed in the published version).

The referees who approved this article are:

Version 1

- 1 **Stefano Pileri**, Unit of Haematopathology, European Institute of Oncology, Milan/Bologna University School of Medicine, Bologna, Italy
Competing Interests: No competing interests were disclosed.
- 2 **Mary Jo Lechowicz**, Department of Hematology Oncology, Winship Cancer Institute, Emory University, Atlanta, Georgia, USA
Competing Interests: No competing interests were disclosed.