

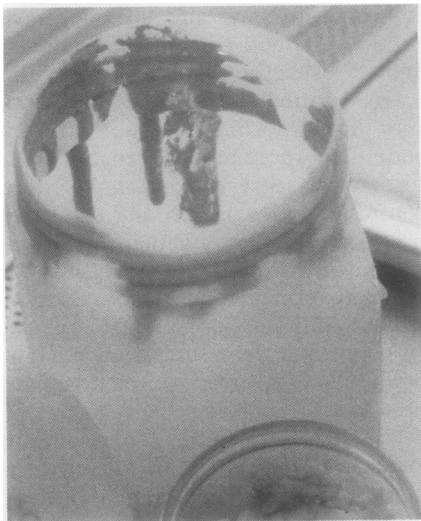
## CORRESPONDENCE

### Chronochemistry, rubber, and formalin

Histopathologists, with their obsessional penchant for prolonged storage of fixed or stained tissues and associated mountants, should take more interest in slow chemical reactions (*chronochemistry*; a possible neologism for which we offer no apology).

A recent foray to rescue 4000 specimens of breast tissue, stored in 10% aqueous formaldehyde for the past 20 years in a notoriously cool mortuary, showed many examples of a dramatic internal candlewax-like ooze of the rubber rings of storage jars (figure). Despite extensive domestic experience from similar commendable patience in storing bottles and demijohns of jellies and home-made wines, also sealed by rubber sealers, this is a new phenomenon to us.

Rubber is an organic polymer of isoprene and its homologues. Formaldehyde is a polymerising agent for proteins. How has this accidental collision of agents led to the dribble which we illustrate? A chemical explanation is needed to prevent future loss of the aesthetic appeal or the forensic value of tissue stored over a long period. Are proper chronochemists out there ready with advice and explanation?



The rubber ring on the neck of an opalescent plastic specimen storage jar containing formalin has oozed downwards after seven years of storage, thus simulating molten candlewax.

J D DAVIES  
J S ARMSTRONG  
Regional Breast Pathology and  
Quality Assurance Unit,  
Southmead Hospital,  
Westbury-on-Trym,  
Bristol BS10 5NB

### Declining necropsy rate

We read with interest the recent paper by Benbow on medical students' views on necropsies.<sup>1</sup> In common with many other hospitals around the world<sup>2,3</sup> our own district

### Replies of consultant and junior clinical staff to necropsy questionnaire

	Consultant (%)	Junior staff (%)
Are you worried by the declining hospital necropsy rate?		
Yes	79	33
No	16	52
Don't know	5	15
For patients dying in hospital, necropsy is desirable in:		
All cases	19	7
Most cases	51	29
A few cases	30	64
No cases	0	0

general hospital has suffered a steady decline in the hospital necropsy rate from over 50% in 1960 to 10% in 1990 (excluding coroners' necropsies). In an attempt to find out why, we sent a questionnaire to 120 clinical colleagues.

Replies were received from 37 consultants and 43 junior clinical staff. It is interesting to compare the responses of consultants and junior staff. When asked if the falling necropsy rate worried them, 79% of consultants, but only 37% of junior clinical staff, stated that they were concerned by it (table). Furthermore, most consultants (51%) felt that for patients dying in hospital a necropsy was desirable in most cases, while most junior staff (64%) considered necropsy desirable in only a few cases.

When asked about reasons for the declining necropsy rate, decreased emphasis on necropsy in medical education was considered important by the highest percentage of all respondents (64%). Predictably, despite continuing evidence to the contrary,<sup>4,5</sup> advances in antemortem diagnostic techniques which offset the need for necropsy, were considered important by 54% of all respondents. Failure of junior doctors to ask for a relative's consent and an increased reluctance on the part of relatives to give consent were considered important by 53% and 52%, respectively. Failure of pathologists to communicate their findings, and increased aesthetic, or emotional objections of clinicians to necropsy, were considered important by only 18% and 16% of respondents, respectively.

The somewhat negative attitude to the necropsy expressed by junior clinical staff in our survey, and the acknowledgement that medical education is lacking in this area are important, as it is frequently the most junior of doctors who are called on to ask a relative's consent for necropsy.

We agree with the conclusions of Benbow that more care, effort, and sensitivity must be shown in the training of future doctors, with regard to the necropsy.<sup>1</sup> Only then, perhaps, may the current unacceptable decline in the hospital necropsy rate be halted.

AP GILES  
R DOSHI  
GG MENON  
MK KHAN

Departments of Histopathology and Neuropathology,  
Brook General Hospital,  
Shooters Hill,  
London SE18 4LW.

- 1 Benbow EW. Medical students' views on necropsies. *J Clin Pathol* 1990;43:969-76.
- 2 Cameron HM. Future of the hospital autopsy. *Br J Hosp Med* 1988;40:335.
- 3 Frederici HHR. Reflections on the postmortem audit. *JAMA* 1988;260:3461-5.
- 4 Goldman L, Sayson R, Robbins S, Conn LH, Bettmann M, Weisberg M. The value of the autopsy in three medical eras. *N Engl J Med* 1983;308:1000-5.
- 5 Stevanovic G, Tucakovic G, Dotlic R, Kanjuh V. Correlation of clinical diagnoses with autopsy findings. *Hum Pathol* 1986;17:1225-30.

### Dr Benbow comments:

I'd like to thank Dr Giles and his colleagues for their interest in my paper, and to congratulate them on their own contribution to the debate. They are certainly right when they conclude that changes are necessary in the way future doctors are introduced to necropsy, though I remain unsure exactly what those changes should be. My own studies, so far, have done more to define the problem than to provide any solutions.<sup>1-3</sup> I remain puzzled that, although most of our students feel that they have been well taught in the necropsy room,<sup>1</sup> many remain reluctant to attend again, even to follow up their own patients.<sup>1,2</sup> I suspect that progress will be difficult until medical students get more help with understanding and coming to terms with the emotional issues surrounding death and dying.<sup>3</sup>

I was particularly interested that 54% of respondents in Giles's study felt that current diagnostic techniques have reduced the need for necropsy. Some of my own results show that 75% of second year medical students, and 81% of third year students, disagreed with the contention that modern investigative techniques have superseded necropsy.<sup>4</sup> A total of 72% agreed that necropsy can assess the accuracy of new radiological techniques (with 25% offering no opinion), and 89% agreed that necropsy can assess the efficacy of antemortem treatment. Clearly, seduction by technology occurs at some stage after the third year of the medical course.

The finding of Dr Giles and his colleagues that consultants are more concerned than juniors about the dropping necropsy rate is an important one. It echoes views expressed by senior academic pathologists in the USA, who feel that one of the most important causes of the decline of the necropsy is a failure to educate medical students and junior clinicians about its value.<sup>5</sup> It follows that there is a cohort of recently (and not so recently) qualified doctors who have little experience of the necropsy, and who may therefore know little of its benefits. As members of this cohort become the leaders of their profession over the next decade or two, their lack of interest in the necropsy may prove even more detrimental than it does now.

Not only do we need to educate undergraduates, but we need to re-educate postgraduates. We should lose no opportunity to emphasise discrepancies between clinical and necropsy diagnoses in clinical meetings, clinicopathological conferences, and casual discussions: there is plenty of published ammunition to bolster personal anecdote.<sup>6</sup> Our comments, of course, should be carefully tempered with an understanding of "necessary fallibility".<sup>7</sup>

- 1 Benbow EW. Autopsy demonstrations to medical students: audit by questionnaire. *J Pathol* 1990;162:177-9.

- 2 Benbow EW. Medical students' views on necropsies. *J Clin Pathol* 1990;43:969-76.
- 3 Benbow EW. Why show autopsies to medical students? *J Pathol* 1990;162:187-8.
- 4 Benbow EW. The attitudes of second- and third-year medical students to the autopsy. A survey by postal questionnaire. *Arch Pathol Lab Med* (in press).
- 5 Anderson RE, Hill RB. Epitome. The current status of the autopsy in academic medical centers in the United States. *Am J Clin Pathol* 1989;92:s31-s7.
- 6 Hill RB, Anderson RE. *The Autopsy: medical practice and public policy*. Stoneham, Massachusetts: Butterworths, 1988:67-90.
- 7 Anderson RE, Hill RB, Key CR. The sensitivity and specificity of clinical diagnostics during five decades: toward an understanding of necessary fallibility. *JAMA* 1989;261:1610-7.

WN PATTON  
 Department of Haematology, The Medical School  
 University of Birmingham B15 2TT  
 CM BUNCE  
 G BROWN  
 Department of Immunology, The Medical School  
 University of Birmingham B15 2TT  
 SLARKIN  
 Department of Cytogenetics, Birmingham Maternity  
 Hospital, Birmingham B15 2TH

- 1 Williamson PJ, Oscier DG, Bell AJ, Hamblin TJ. Red cell aplasia in myelodysplastic syndrome. *J Clin Pathol* 1991;44:431-2.
- 2 Patton WN, Bunce CM, Larkin S, Brown G. Defective erythropoiesis in primary myelofibrosis associated with a chromosome 11 abnormality. *Br J Cancer* 1991;64:128-31.

#### Drs Williamson et al comment:

The case cited above is certainly of interest in investigating the pathogenesis of red cell aplasia in myelodysplasia (MDS). The overlap of morphological features between MDS and myelofibrosis is increasingly being recognised,<sup>1</sup> and it would be intriguing to know the consequences at the gene level in this case of 11q- with break point at 11q13.

Our cases all had attempted cytogenetic analysis of marrow aspirate. Four gave a normal karyotype and two failed to yield metaphases. Several of our cases date from the early 1980s and the cytogenetic technique has undoubtedly improved since then. Our rate of clonal cytogenetic abnormality in MDS in the Wessex region is about 35-40% which accords with the national average. A few published series quote clonal abnormality rates of 75% plus, but these may be the result of repeated analysis of large numbers of cells and may be influenced by case selection. In the Wessex region we have never encountered the 11q13 region as being involved in a case of MDS. The 1988 Catalogue of Chromosomal Aberrations in Cancer<sup>2</sup> lists only five reported cases where the 11q13 region has been involved in myelodysplastic/proliferative disorders, often as part of a complex karyotype. A review of the other published cases of MDS and red cell aplasia referenced in our paper shows that all five in which cytogenetics are reported yielded a normal karyotype. Thus although of some interest, it remains to be seen if the 11q13 region has a role in the regulation of erythropoiesis.

- 1 Lambertenghi-Deliliers G, Orazi A, Luksch R, Annaloro C, Soligo D. Myelodysplastic syndrome with increased marrow fibrosis: a distinct clinico-pathological entity. *Br J Haematol* 1991;78:161-6.
- 2 Mittleman F. *Catalogue of chromosomal aberrations in cancer*. 3rd edn. New York: Alan R Liss, 1988.

#### Visceral leishmaniasis in human immunodeficiency virus disease

I read the very interesting article by Curry, Turner, and Lucas.<sup>1</sup> It is important to include visceral leishmaniasis (VL) as an opportunistic protozoan infection in patients infected with HIV, as it is common in endemic areas.<sup>2</sup> Although the authors comment on some of the salient diagnostic and therapeutic features of VL in patients with HIV, the description is perhaps incomplete as it is based on only a few cases. Over the past few years, most cases of VL in HIV infection have been reported from Spain, probably due to a high incidence of

both VL and HIV infection and a greater awareness about this association once the first few cases had been described. In 1990 two independent studies described the features of VL in many cases of HIV.<sup>2,3</sup> More recently, our cooperative multicentre study of 40 patients, including most cases that had appeared in Spain up to the beginning of 1990, has updated that experience.<sup>4</sup>

Although in some patients VL can be the consequence of reactivated disease, the finding that 92.5% of the patients were intravenous drug misusers suggested that the disease could be transmitted intravenously (which is an occasional route of transmission in immunocompetents). VL can occur at all stages of HIV infection, but 77% of patients were classified as stage IV with CD4 counts below  $4 \times 10^9/l$ , suggesting that it is commoner in the later stages of HIV infection. Most patients present with a clinical picture of "classic" Kala-azar with fever, hepatosplenomegaly, and pancytopenia, but some are asymptomatic and are diagnosed incidentally. In all patients *Leishmania amastigotes* were demonstrated in the bone marrow smear, and in the liver of 94.5% of the patients who had a biopsy. In four cases *L. amastigotes* were found in normal skin, and were also present in skin lesions of a Kaposi's sarcoma in one case. This is not a surprising finding, as *L. amastigotes* are found in normal skin in immunocompetent patients with VL. The two most remarkable findings were the absence of leishmanial antibodies, present in only 35.2% of cases, and the chronic relapsing course of the disease. Although 75% of patients had a good initial response to antimony drugs, 42.5% followed a chronic or relapsing course; 40% of patients died due to HIV related causes, and death was only inadvertently related to the relapsing course of the disease.

These findings suggest that VL behaves like other infections in HIV seropositive patients, such as tuberculosis or *Pneumocystis carinii*, showing a good response to initial treatment but persisting as latent chronic disease. Conventional treatment with antimony is not effective in half the patients and other therapeutic approaches are needed. Production of  $\alpha$ -interferon ( $\alpha$ -INF) and other lymphokines are essential to activate macrophages, but these are defective in both VL and HIV infections. Adjuvant treatment with  $\gamma$ -INF has been effective in animals, in experimental models of human macrophages, and in refractory VL in immunocompetent patients.<sup>5</sup> These results suggest that  $\gamma$ -INF could also be effective in VL in HIV seropositive patients and a therapeutic trial is currently being conducted in Spain.

VL is an opportunistic infection in HIV seropositive patients that is found increasingly often. It must be suspected and precluded in patients presenting with fever, hepatosplenomegaly, and pancytopenia, and even in less ill patients living in or travelling to endemic areas.

C MONTALBAN  
 Ministerio de Sanidad y Consumo,  
 Instituto Nacional de la Salud,  
 Hospital Ramon y Cajal,  
 Carretera de Colmenar,  
 Madrid 28034  
 Spain

- 1 Curry A, Turner AJ, Lucas S. Opportunistic protozoan infections in human immunodeficiency virus disease: Review highlighting diagnostic and therapeutic aspects. *J Clin Pathol* 1991;44:182-93.

#### Defective erythropoiesis in myelodysplastic syndromes

We read with interest the report of Williamson et al describing uncommon cases of red cell aplasia (RCA) in patients with myelodysplastic syndromes (MDS).<sup>1</sup> The mechanism of RCA in their first three cases was attributed to an intrinsic defect of maturation and proliferation of erythroid precursors occurring as part of the myelodysplastic disorder, whereas in the second three cases a different, and possibly autoimmune aetiology, was suggested. We believe that cytogenetic and molecular study of such unusual cases is important. Most cases of MDS and other malignant haematological disorders are associated with structural chromosomal abnormalities. Cytogenetic study of unusual cases with common features, such as these cases of RCA, might indicate a common chromosomal abnormality which would point to the existence of genes which encode key regulators of erythroid lineage development at or near the junction of the chromosomal aberration. The key regulators of lineage commitment and differentiation in haemopoiesis remain unknown, and an investigative approach through the study of nature's genetic errors might lead to their discovery.

Using such an approach we have recently described a possible association between defective erythropoiesis and an abnormality of chromosome 11.<sup>2</sup> A case of primary myelofibrosis was identified which showed morphological erythroid aplasia and absent circulating erythroid progenitors. The patient had greatly increased numbers of circulating granulocyte-monocyte progenitor cells (CFU-GM). Co-culture of peripheral blood mononuclear cells with irradiated allogeneic normal bone marrow stroma generated increased numbers of CFU-GM compared with controls but failed to generate erythroid progenitors, providing further evidence for an intrinsic defect in erythropoiesis. Our patient exhibited a previously unreported complex karyotype. Only once previously has the absence of erythroid progenitors in primary myelofibrosis been studied in relation to cytogenetic abnormalities, and this case also indicated a complex karyotype which shared with our case a defect on chromosome 11. The abnormality in our case was 11q- with the break point at 11q13. A literature review showed that the proto-oncogene SEA (S13 avian erythroblastosis oncogene homolog) maps to the 11q13 region and we intend to study the possible role of this gene at the molecular level.