

# Disseminated *Pneumocystis carinii* infection in AIDS

R J Coker, D Clark, E L Claydon, M Gompels, J G Ainsworth, S B Lucas, R Miller, R D F Goldin, A J Pinching, J R W Harris

## Abstract

**Eight patients with AIDS and *Pneumocystis carinii* infection were studied. Protean manifestations were a feature not untypical of disseminated pneumocystosis. Aerosolised pentamidine as prophylaxis against *P carinii* pneumonia was ineffective at suppressing dissemination. The knowledge that extrapulmonary infection can occur has implications for the detection and treatment of, and prophylaxis against, *P carinii* infection. The survival of patients with disseminated pneumocystosis is particularly poor, and may be due to a lack of clinical awareness and consequent delay in diagnosis.**

*Pneumocystis carinii* causes opportunistic infection, most commonly a potentially fatal pneumonia in up to 85% of patients with AIDS in Europe and North America.<sup>1</sup> Disease in other organs is reported surprisingly infrequently in view of the multisystem spread of many other organisms in such patients. We describe eight cases of disseminated *P carinii* infection in patients with AIDS, and highlight the different modes of presentation, the predisposing factors, and the histological features found.

## Case reports

### CASE 1

A 36 year old homosexual man presented with a three week history of perianal pain. He had been reported as HIV-1 antibody positive two years previously (July 1987) when he was diagnosed as having *P carinii* pneumonia. *P carinii* pneumonia recurred in November 1988 in conjunction with pulmonary tuberculosis. Details of the treatment he received in the USA for these episodes are not available, but he subsequently received aerosolised pentamidine (300 mg fortnightly) as secondary prophylaxis. He had had recurrent perianal herpes and developed cryptosporidial diarrhoea in July 1989. Examination showed that he was emaciated, feverish (39°C), and had oral candidosis and hairy oral leucoplakia. He had a right sided pneumothorax, evidence of cytomegalovirus infection (CMV), retinitis and a 2 cm ulcerated necrotic perianal mass, which was excised. He developed a left pneumothorax and despite treatment deteriorated and died shortly afterwards.

### CASE 2

A 26 year old homosexual man presented with severe abdominal pain. A chest x ray picture on admission showed bilateral pulmonary infiltrates suggestive of *P carinii* pneumonia. He had been found to be HIV antigen and antibody positive two years previously (November 1988). *Mycobacterium malmoense* had been isolated from sputum samples in June 1990 and at that time he had started quadruple anti-tuberculous treatment. He had developed an enlarged non-tender thyroid six weeks before admission and was found to be hypothyroid for which he was being treated with thyroxine. Auto-antibodies were not detected. He had received aerosolised pentamidine (300 mg fortnightly) as prophylaxis against *P carinii* pneumonia for six months. At laparotomy a perforation of the small bowel was found and repaired, but he died seven days later.

### CASE 3<sup>2</sup>

A 33 year old homosexual man presented with a history of weight loss, anorexia, dry cough, fever and night sweats. He had been found to be HIV-1 antibody positive three years previously and had developed *P carinii* pneumonia two years and again 10 months before admission. Since his first episode of *P carinii* pneumonia he had been maintained on aerosolised pentamidine (300 mg fortnightly). He was feverish (39.4°C) and cachectic. His chest and abdomen were clinically normal, as were chest x ray picture and arterial blood gas analysis. Bronchoscopy and examination of alveolar lavage specimens yielded normal results. Laboratory data showed raised aspartate transaminase (AST) (247 IU/l) and alkaline phosphatase (413 IU) activities. Serum bilirubin was normal. The patient subsequently developed liver failure and thrombocytopenia, from which he died one month after admission.

### CASE 4

A 26 year old homosexual man was admitted with a history of dyspnoea for one day and fever for five days. He had been diagnosed as HIV-1 antibody positive 18 months earlier when he presented with cutaneous Kaposi's sarcoma. This subsequently became disseminated and was treated with vincristine and bleomycin. He was not taking prophylaxis for *P carinii* pneumonia. On examination, he was feverish (39.8°C), tachypnoeic, and had oral hairy leucoplakia and oral candidosis. No abnormalities were detected on examination of the chest. A chest x ray picture showed widespread

Department of  
Genitourinary  
Medicine, St Mary's  
Hospital and Medical  
School, London  
W2 1NF

R J Coker  
E L Claydon  
J G Ainsworth  
J R W Harris

Department of  
Histopathology  
D Clark  
R D F Goldin

Department of  
Clinical Immunology  
M Gompels  
A J Pinching

Department of  
Histopathology,  
University College and  
Middlesex School of  
Medicine, London  
S B Lucas

Department of  
Medicine  
R Miller

Correspondence to:  
Dr R J Coker

Accepted for publication  
9 May 1991

interstitial lung shadowing suggestive of *P carinii* pneumonia. Arterial blood gas analysis confirmed hypoxia. Liver function tests were only mildly abnormal (AST: 51 IU/l). Despite treatment he died two days after admission.

#### CASE 5

A 34 year old homosexual man presented with a two week history of fever, malaise, and gradually increasing dyspnoea. He was HIV-1 antibody positive. He had had three previous episodes of *P carinii* pneumonia over an 18 month period and had developed a rash, when treated with co-trimoxazole during his first attack of pneumonia, and nausea when he was treated with trimethoprim and dapsone during a second. He had responded well to aerosolised pentamidine during a third episode but had not tolerated pentamidine prophylaxis after this. He had a right tension pneumothorax and a moderate left pleural effusion. Pneumocysts were identified in the pleural aspirate. No other cause for the effusion was identified and he responded to treatment with trimethoprim and dapsone. He died one year later.

#### CASE 6

A 44 year old homosexual man presented with a one month history of anorexia, weight loss, and fullness after eating. He had no respiratory symptoms. He had been HIV-1 antibody positive for two years during which time he had received aerosolised pentamidine as primary prophylaxis. He had developed cutaneous Kaposi's sarcoma four months before admission. His liver function tests had been abnor-

mal for one month (AST 189 IU/l initially, and 97 IU/l on admission). His *P carinii* pneumonia prophylaxis had been changed to dapsone (100 mg/week) and pyrimethamine (25 mg/week) six weeks before this admission. On examination, he was cachectic, had widespread cutaneous Kaposi's sarcoma, and ascites. A chest x ray picture showed bilateral interstitial shadowing similar to that noted one month earlier. Gastroscopy showed a small pigmented lesion in the stomach. Despite systemic treatment he died six weeks later.

#### CASE 7

A 42 year old homosexual man had been found to be HIV-1 antibody positive in August 1987 when he presented with a left lower lobe pneumonia and pleural effusion. He began primary prophylaxis with oral co-trimoxazole but because of intolerance this was changed to aerosolised pentamidine (150 mg fortnightly). He had only received one dose of this before he was admitted in December 1988 with *P carinii* pneumonia. He was treated with aerosolised pentamidine at a dose of 8 mg/kg for 21 days and made a full recovery. Secondary prophylaxis with aerosolised pentamidine was subsequently given. In May 1990 he presented with B-cell non-Hodgkin's lymphoma affecting the lower lobe of the left lung. He had periventricular changes on a computed tomography scan that were suggestive of intracerebral disease. He developed bilateral interstitial infiltrates thought to be *P carinii* pneumonia and died despite treatment with intravenous pentamidine (4 mg/kg daily).

#### CASE 8

A 31 year old homosexual man was found to be HIV-1 antibody positive in January 1989. In May 1989 he had an episode of *P carinii* pneumonia which was treated successfully with aerosolised pentamidine (8 mg/kg for 21 days), and he subsequently began secondary *P carinii* pneumonia prophylaxis with aerosolised pentamidine (150 mg fortnightly). In January 1990 he developed a left pneumothorax which resolved spontaneously. He developed a further pneumothorax, on the right, later the same month which required a chest drain. On reinflation of the lung, a chest x ray picture showed bilateral perihilar shadowing, suggestive of *P carinii* pneumonia. He developed a left pneumothorax two days later that required an intercostal drain. Despite treatment with intravenous high dose co-trimoxazole he continued to have bilateral air leaks, complicating bilateral pneumonia and he died.

#### Biopsy findings

An antemortem diagnosis of extrapulmonary pneumocystosis was made on biopsy specimens of perianal skin, small bowel, and gastric body in cases 1, 2, and 6, respectively. In cases 3 and 4 the diagnosis was made on a postmortem needle necropsy specimen of the liver. In cases 1, 2, 3, and 6 the histological diagnosis was initially suspected because of the presence of frothy pink exudate similar to that seen in

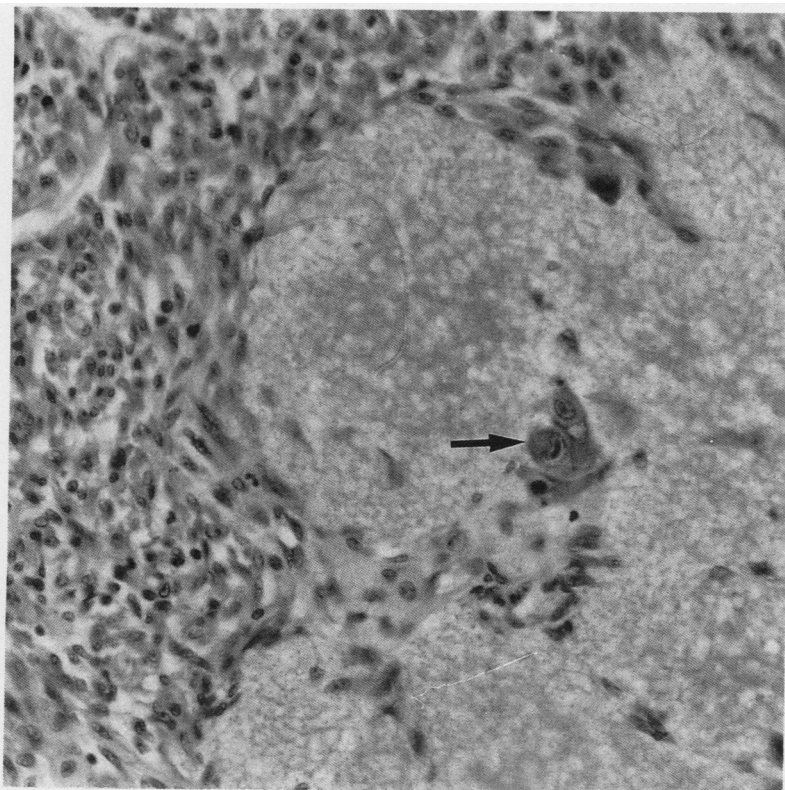


Figure 1 Case 6: small bowel; Kaposi's sarcoma on the left, foamy eosinophilic exudate, characteristic of pneumocystis infection, on the right side of the field. Also note cytomegalovirus infected cells (arrowed) (haematoxylin and eosin).

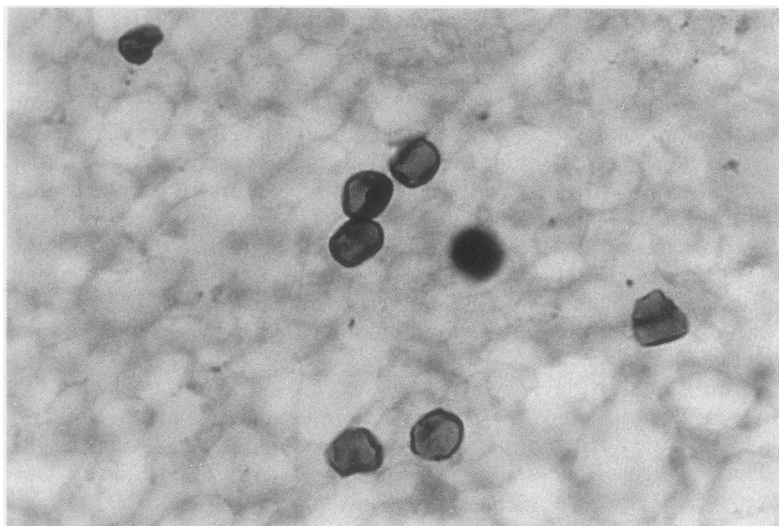


Figure 2 Case 6: cyst forms of *Pneumocystis carinii* (Grocott's methenamine silver stain).

alveoli in *P carinii* pneumonia in haematoxylin and eosin stained sections. In cases 1, 3, and 6 the exudate was very scanty and only visible in some of the levels which were cut completely through the specimens. Microscopically, case 2 had a necrotic tumour (2.5 cm in diameter) protruding into the lumen of the small bowel, with a perforation (0.3 cm in diameter) close to its base. This was Kaposi's sarcoma, but much of the tumour had been replaced by the foamy exudate described above, particularly in the region of the perforation (fig 1). Numerous cells infected with CMV were also present within the tumour. The combination of *P carinii*, CMV, and Kaposi's sarcoma was also seen in case 1. In all cases the diagnosis was confirmed by demonstrating the cyst forms of *P carinii* using Grocott's methenamine silver stain (fig 2). In case 4 the only evidence of *P carinii* infection was the presence of cyst forms in hepatic sinusoids on Grocott's methenamine silver stain.

### Post mortem findings

#### CASE 2

The lungs (left weighing 700 g, right weighing 650 g; normal values, left 570 g, right 620 g) were consolidated and contained a yellow nodule, 2 cm in diameter. Similar yellow tissue infiltrated the chest, mesenteric lymph nodes, and the thyroid, which was completely replaced. Small yellow nodules were present in the liver, spleen, and kidneys. Histologically, the yellow infiltrates represented *P carinii* infection with calcification. The intestine showed no residual *P carinii* lesions. The pneumonic consolidation represented shock lung (adult hyaline membrane disease). CMV infection was found only in the adrenal glands.

#### CASE 7

Lymphoma was found in the brain and left lung (right and left weighing 600 g). There was widespread *P carinii* pneumonia with cavitation, and the *P carinii* was intermingled with the lymphoma. The sinuses of the hilar lymph nodes were infiltrated by *P carinii*, but not by lymphoma. Histologically, there was much

calcification within the pneumocystosis. CMV infection was widespread in the lungs, gut, spleen, nodes and adrenal glands.

#### CASE 8

Both lungs showed yellow cavitating consolidation (left weighing 800 g, right weighing 1050 g), and the hilar nodes showed yellow infiltration. The remaining organs were macroscopically normal. Histologically, the lung and nodes showed calcifying *P carinii* infection. *P carinii* and a focal granulomatous reaction had infiltrated and occluded the arteries of the lungs. CMV infection was present only in the adrenal glands.

### Discussion

Dissemination of *P carinii* infection is rare, but is increasingly being reported in patients with AIDS. This series includes: the first patients to be reported with perianal infection; the first patient to develop hypothyroidism secondary to *P carinii* thyroiditis; the first patient to develop bowel perforation; and the first reported cytological documentation of *P carinii* in pleural fluid in the absence of concurrent ipsilateral pneumothorax.

Of the 585 episodes of *P carinii* infection (397 patients) treated at St Mary's and the Middlesex Hospitals up to November 1990, only these eight (0.5%) patients had evidence of extrapulmonary spread. The incidence of disseminated *P carinii* infection documented here is lower than that reported previously, but the incidence of clinical disease is similar. In a review of 161 necropsies of patients with AIDS, 55 had *P carinii* pneumonia; four (2.5%) had extrapulmonary *P carinii* infection, but only one had clinical evidence of this.<sup>3</sup> Extrapulmonary sites in which *P carinii* infection has been documented include the spleen,<sup>4</sup> liver,<sup>3-5</sup> kidney,<sup>3,4</sup> bone marrow,<sup>3</sup> auditory canal,<sup>6</sup> thyroid,<sup>4,7</sup> lymph nodes,<sup>4,5</sup> gastrointestinal tract,<sup>4,8</sup> eye<sup>9</sup> and brain.<sup>10</sup>

Disseminated *P carinii* infection was first reported in 1960.<sup>11</sup> LeGolvan and Heidelberger reviewed seven cases in 1973 but could not identify any predisposing underlying factors to determine which patients would develop disseminated disease.<sup>12</sup> Lymphatic and haematogenous spread occurs, but risk factors predisposing to dissemination have still not been elucidated. As in most previously reported studies,<sup>3-10</sup> most of the patients reported here had had either a previous episode of *P carinii* pneumonia or had *P carinii* pneumonia at the time of presentation with extrapulmonary disease. This may have been due to more aggressive disease being present, and lung destruction might have been more extensive, because of variations in the invasiveness of the organisms, or unknown systemic factors. The mortality from disseminated disease is high, as shown by the poor survivals seen in these and previous cases. The pneumocystosis in cases 1, 2, 3, 4, and 6 probably contributed to death, and earlier diagnosis might have influenced outcome.

The true incidence of disseminated disease is

probably underestimated for various reasons. The disease may respond to systemic treatment; post mortem examinations are not always performed; the organism is often not specifically sought in extrapulmonary sites.

Perianal disease as a result of *P. carinii* infection has not previously been reported, although associated disease of the oesophagus, duodenum, appendix, jejunum and thyroid have.<sup>4,7,8</sup> The hypothyroidism noted in case 2 several weeks before his final admission was probably caused by infection in this organ. This patient also had a perforation of his small bowel. This has not previously been associated with pneumocystosis, but, histologically, the extensive pneumocystis infection seemed to be the cause of the perforation, although the coexistent CMV infection may also have played a part.<sup>13,14</sup> There are no reports of Kaposi's sarcoma with perforation in cases of AIDS without CMV infection,<sup>2</sup> implying that Kaposi's sarcoma is not destructive enough to cause perforation of the gastrointestinal tract.

Colonisation of the liver by *P. carinii* (cases 2, 3, and 4) is commonly seen when dissemination occurs. Six of the 10 cases reviewed by Northfelt<sup>15</sup> had some hepatic disease although none developed hepatic failure. Jenkins *et al.*,<sup>16</sup> reporting on case 3, have discussed the occurrence of unrecognised *P. carinii* hepatitis and resultant hepatic failure.

In case 5 pneumocysts were isolated from the pleural effusion on the contralateral side to the pneumothorax. Though pleural effusions in *P. carinii* pneumonia<sup>17</sup> and isolation of *P. carinii* from the pleura have been reported,<sup>18</sup> we are unaware of pneumocysts being isolated from this site unless there is concurrent ipsilateral pneumothorax.<sup>19</sup>

There has recently been concern over the use of pentamidine possibly being responsible for the increased incidence of pneumothoraces.<sup>20</sup> This was noted in cases 1, 5, and 8, all of whom were receiving aerosolised pentamidine.

Six of the eight patients presented here had received aerosolised pentamidine (through Respigard II nebulisers) as either primary (cases 2 and 6) or secondary (cases 1, 3, 7, and 8) prophylaxis for *P. carinii* pneumonia. The usual portal of entry of *P. carinii* is the lung, and aerosolised pentamidine is attractive because high concentrations can be attained in the lungs, it is well tolerated, and has not resulted in clinically important toxicity. It may be, however, that aerosolised pentamidine is an effective prophylactic agent against pneumonia but ineffective in preventing dissemination of the infection. Moreover, the absence of pneumonia may cause the diagnosis of extrapulmonary pneumocystosis to be overlooked. Dissemination could occur during the initial infection but the occurrence in two cases receiving primary prophylaxis means that the extrapulmonary spread does not only occur during the first clinical episode of *P. carinii* pneumonia in AIDS, and that the use of

aerosolised pentamidine, though an effective agent for prophylaxis for pneumonia, is ineffective at suppressing extrapulmonary pneumocystosis.<sup>16,21</sup> This may be relevant when choosing prophylaxis in the future.

In summary, the cases reported here show the protean manifestations of disseminated pneumocystosis. Physicians must be aware of the unusual sites of infection, especially in patients not receiving any prophylaxis or receiving prophylaxis in the form of aerosolised pentamidine. Pathologists should be alerted to look specifically for pneumocysts in biopsy samples from HIV antibody positive patients whatever the tissue, because earlier diagnosis and systemic treatment may improve survival.

- Murray JF, Garay SM, Hopewell PC, Mills J, Snider GL, Stover DE. Pulmonary complications of the acquired immune deficiency syndrome. An update. *Am Rev Respir Dis* 1987;135:504-9.
- Friedman SL, Wright TL, Altman DF. Gastrointestinal Kaposi's sarcoma in patients with acquired immunodeficiency syndrome: endoscopic and autopsy findings. *Gastroenterology* 1985;89:102-8.
- Telzak EE, Cote RJ, Gold JWM, Campbell SW, Armstrong D. Extrapulmonary *Pneumocystis carinii* infections. *Rev Infect Dis* 1990;12:380-6.
- Macher AM, Bardenstein DS, Zimmerman LE, Steigman CK, Pastore L, Poretz DM, Eron LJ. *Pneumocystis carinii* choroiditis in a male homosexual with AIDS and disseminated pulmonary and extrapulmonary *P. carinii* infection. *N Engl J Med* 1987;316:1092.
- Afessa B, Green WR, Williams WA, Hagler NG, Gumbs RV, Hackney RL, Frederick WR. *Pneumocystis carinii* pneumonia complicated by lymphadenopathy and pneumothorax. *Arch Intern Med* 1988;148:2651-4.
- Breda SD, Gigliotti F, Hammerschlag PE, Schinella R. *Pneumocystis carinii* in the temporal bone as a primary manifestation of the acquired immunodeficiency syndrome. *Ann Otol Rhinol Laryngol* 1988;97:427-31.
- Gallant JE, Enriquez RE, Cohen KL, Hammers LW. *Pneumocystis carinii* thyroiditis. *Am J Med* 1988;84:303-6.
- Grimes MM, LaPook JD, Bar MH, Wasserman HS, Dwork A. Disseminated *Pneumocystis carinii* infection in a patient with acquired immunodeficiency syndrome. *Hum Pathol* 1987;18:307-8.
- Sneed SR, Blodi CF, Berger BB, Speights JW, Folx JC, Weingeist TA. *Pneumocystis carinii* choroiditis in patients receiving inhaled pentamidine. *N Engl J Med* 1990;322:936-7.
- Mayayo E, Vidal F, Alvira R, Gonzalez J, Richart C. Cerebral *Pneumocystis carinii* infection in AIDS. *Lancet* 1990;336:1592.
- Anderson CD, Barrie HJ. Fatal *Pneumocystis* pneumonia in an adult. *Am J Clin Pathol* 1960;34:365-70.
- LeGolvan, Heidelberger KP. Disseminated, granulomatous *Pneumocystis carinii* pneumonia. *Arch Pathol* 1973;95:344-8.
- Jacobson MA, Mills J. Serious cytomegalovirus disease in the acquired immunodeficiency syndrome (AIDS). *Ann Intern Med* 1988;108:585-94.
- Frank D, Ratent RF. Intestinal perforation associated with cytomegalovirus infection in patients with acquired immunodeficiency syndrome. *Am J Gastroenterol* 1984;79:201-5.
- Northfelt DW. Extrapulmonary pneumocystosis in patients taking aerosolised pentamidine. *Lancet* 1989;ii:1454.
- Jenkins RE, Goldin RD, Lindley RP, Pinching AJ. Aerosolised pentamidine. *Lancet* 1990;i:113.
- Naidich DP, Garay SM, Lutman BS, McCauley DI. Radiographic manifestations of pulmonary disease in the acquired immunodeficiency syndrome (AIDS). *Semin Roentgenol* 1987;22:14-30.
- Dyner TS, Lang W, Busch DF, Gordon PR. Intravascular and pleural involvement by *Pneumocystis carinii* in a patient with the acquired immunodeficiency syndrome (AIDS). *Ann Intern Med* 1989;111:94-5.
- Balachandran I, Jones DB, Humphrey DM. A case of *Pneumocystis carinii* in pleural fluid with cytologic, histologic and ultrastructural documentation. *Acta Cytol* 1990;34:486-90.
- Martinez CM, Romanelli A, Mullen MP, Lee M. Spontaneous pneumothoraces in AIDS patients receiving aerosolised pentamidine. *Chest* 1988;94:1317.
- Armstrong D, Bernard E. Aerosol pentamidine. *Ann Intern Med* 1988;109:852-4.