

Mallory Weiss tears have been reported in association with many conditions, including vomiting caused by raised intracranial pressure, pregnancy, cytotoxic drugs, and ipecac. Other recognised precipitating events include straining at passing stools, hiccupping, protracted coughing, snoring and blunt abdominal trauma. Medical and surgical procedures have also been implicated, including gastroscopy, transtracheal aspiration, and external cardiac massage, but we can find no previous description of Mallory Weiss tears, in the absence of preceding vomiting, occurring as a postoperative complication.

Patients with coexistent upper gastrointestinal disease, such as hiatus hernia, peptic ulceration, and oesophagitis or gastritis, seem to be at increased risk, and an association with non-steroidal inflammatory agents has been described. Dipyridamole is associated with a high incidence of upper gastrointestinal disturbance⁷ and may have been an aggravating factor in our patient.

Hulewicz's recent description of gastric mucosal tears following cardiopulmonary resuscitation⁸ suggested that they were caused by inadvertent gastric inflation during mouth-to-mouth resuscitation of patients who collapsed in public. Although our patient was subjected to cardiopulmonary resuscitation, her haematemesis had occurred before this and cannot be accounted for by any lesion other than the gastric tears.

The diagnosis of Mallory Weiss lesions on

clinical grounds alone is difficult because of the wide range of predisposing factors and variations in presentation, correct pre-endoscopy diagnosis being made in only 36% of cases.⁹ These lesions are the third commonest cause of upper gastrointestinal haemorrhage after duodenal ulceration and gastric ulceration,¹⁰ and the fact that they can cause fatal haematemesis without any warning should be emphasised.

We thank Mr R W G Johnson, consultant surgeon, for permission to report the clinical details, Mr L M Gorodkin, HM Coroner for Greater Manchester (Central), for permission to report the pathological aspects, and Mrs J Crossley for taking the photograph.

- 1 Quincke H. Ulcus oesophagi ex digestion. *Dtsch Arch Klin Med* 1879;24:72.
- 2 Mallory GK, Weiss S. Hemorrhage from laceration of the cardiac orifice due to vomiting. *Am J Med Sci* 1929; 178:506.
- 3 Watts HD, Admirand WH. Mallory Weiss syndrome. A reappraisal. *JAMA* 1974;230:1674-5.
- 4 Graham DY, Schwartz JT. The spectrum of Mallory Weiss. *Medicine* 1977;57:307-18.
- 5 Graham DY, Davis RE. Acute upper GI hemorrhage. New observations of an old problem. *Am J Dig Dis* 1978;23:876.
- 6 Knauer CM. Mallory Weiss syndrome: characteristics of 75 Mallory Weiss lacerations in 528 patients with upper gastrointestinal haemorrhage. *Gastroenterology* 1976; 71:5-8.
- 7 Browse NL, Hall JN. Effect of dipyridimole on the incidence of clinically detectable deep vein thrombosis. *Lancet* 1969;ii:718-20.
- 8 Hulewicz B. Gastric trauma following cardiopulmonary resuscitation. *Med Sci Law* 1990;30:149-53.
- 9 Hastings PR, Peters KW, Cohn I. Mallory Weiss syndrome: review of 64 cases. *Am J Surg* 1981;142:560-2.
- 10 Sugawa C, Benishek D, Walt AJ. Mallory Weiss syndrome. A study of 224 patients. *Am J Surg* 1985;145:30-3.

J Clin Pathol 1991;44:788-789

Platelet satellitism and α granule proteins

C Christopoulos, C Mattock

Abstract

Blood smears from a patient with severe generalised arteriopathy and an occluded synthetic femoropopliteal graft showed the phenomenon of EDTA dependent adherence of platelets to neutrophils (platelet satellitism). Immunoenzymatic staining with a monoclonal antibody to thrombospondin showed that adherence to neutrophils exclusively involved platelets that stained strongly positive for thrombospondin, while negative or weakly positive platelets showed no tendency to adhere. There was no increase in platelet surface immunoglobulins. This suggests a possible role for thrombospondin or some other cytoadhesive platelet α granule protein in mediating the adherence of platelets to neutrophils in cases of satellitism.

Adherence of platelets to neutrophils in a rosette formation, known as platelet satellitism, is a rare in vitro phenomenon typically

seen in EDTA anticoagulated blood. It is not consistently related to any clinical entity but can be the cause of spurious thrombocytopenia. The exact mechanism of this phenomenon is unknown but its transferability, at least in some cases, to normal blood by patients' serum^{1,2} and a report of increased surface IgG in the adhering platelets³ suggest that immunoglobulins have a central role. Our findings in the following case of satellitism point toward an alternative link that might be mediating the adherence of platelets to neutrophils in this setting.

Case report

A 69 year old woman was admitted for replacement of an occluded synthetic femoropopliteal arterial graft. Apart from severe peripheral arteriopathy she also had ischaemic heart disease, having had a triple by-pass graft two years previously. Aspirin had been discontinued three days before admission. A routine preoperative blood count (EDTA anticoagulant) showed a normal platelet count but the white cell differential

Department of
Haematology,
University College and
Middlesex School of
Medicine, London
WC1E 6AU
C Christopoulos
C Mattock

Correspondence to:
Dr C Christopoulos

Accepted for publication
20 February 1991

was rejected by the Coulter analyzer. A blood film showed extensive rosetting of platelets around most neutrophils without platelet clumping. Eosinophils, monocytes, and lymphocytes were not involved. Examination of a citrated blood sample showed many platelet clumps but no satellitism.

Measurement of surface immunoglobulin concentrations of platelets isolated from the EDTA sample was performed using a modification of the flow cytometric method described by Rosenfeld *et al.*⁴: thoroughly washed platelets from the EDTA sample were incubated with a fluorescein-labelled polyvalent (anti-IgG, IgM, IgA) goat-anti-human antibody. After further washing, analysis on a Coulter EPICS-Profile flow cytometer showed the mean platelet fluorescence to be within our pre-established normal range.

As part of a study assessing platelet thrombospondin (TSP) content in patients with conditions associated with increased *in vivo* platelet activation, peripheral blood smears from this patient were stained with a novel murine monoclonal anti-thrombospondin antibody (FT7) produced by one of us.⁵ We used a modification of the three layer peroxidase-antiperoxidase (PAP) immunoenzymatic labelling technique described by Mason *et al.*⁶ Briefly, freshly made blood smears fixed in 0.3% H₂O₂ in methanol for 10 minutes were incubated with FT7 or a non-platelet bindable control monoclonal followed by an excess of polyclonal rabbit-anti-mouse "bridging" antibody and then monoclonal PAP. All the incubations were of one hour's duration with intervening washes. Finally, the smears were treated for 10 minutes with diaminobenzidine/H₂O₂ substrate for colour development and were counterstained in Mayer's haematoxylin. Intracellular as well as surface antigens are detected with this method, and, when stained with FT7, most platelets from normal controls gave a uniformly strong positive reaction, as expected from a protein which is found at high concentrations in the α granules; in a case of α granule deficiency (grey platelet syndrome) most platelets were negative or only weakly positive.

Surprisingly, in the case of our patient with

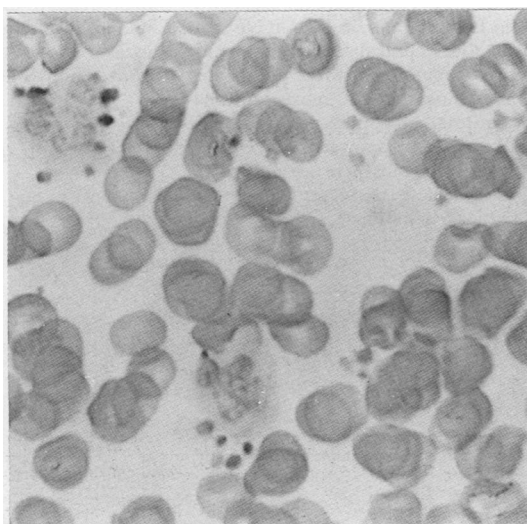
platelet satellitism we observed that only platelets that stained strongly positive for TSP had formed rosettes around neutrophils (figure). Non-rosetting platelets were either weakly positive or negative—that is, these platelets were deficient in α granule TSP which, in normal controls, accounts for the bulk of platelet TSP positivity.

Discussion

The primary event in the phenomenon of platelet satellitism seems to be a change induced by EDTA in the plasma membrane of platelets or neutrophils. This probably results in the formation of molecular bridges that cross-link platelets with neutrophils. Jungi *et al.*⁷ have shown that stimulation of platelets with low dose thrombin induces the expression of surface determinants interacting strongly with monocytes and neutrophils. TSP is a multifunctional α granule protein involved in cell to cell and cell to matrix interactions, and it has been shown that the adhesion of activated platelets to monocytes is mediated by TSP via an interaction with glycoprotein IV on the surface of both cells.⁸ Other workers have shown that PADGEM (platelet activation dependent granule-external membrane protein), another α granule adhesive protein, mediates binding of activated platelets to neutrophils and monocytes.⁹

Boughton *et al.* have presented evidence suggesting that *in vivo* platelet activation with aggregation or release of granule contents can be followed by disaggregation and recirculation of "exhausted" platelets.¹⁰ It is tempting to speculate that this could account for the presence of platelets deficient in α granule TSP in our case of platelet satellitism, in view of the clinical history suggestive of *in vivo* platelet activation. These "exhausted" (TSP deficient) platelets showed no tendency to adhere to neutrophils, which suggests that either TSP itself or some other α granule cytoadhesive protein was essential for satellitism to occur in this patient.

Peroxidase-antiperoxidase stain of a smear of EDTA anticoagulated blood with a murine monoclonal anti-thrombospondin (FT7) antibody. All platelets adhering to neutrophils are strongly positive, whereas negative or weakly positive non-adhering platelets can be seen in the same field.



- 1 Greipp PR, Gralnick HR. Platelet to leukocyte adherence phenomena associated with thrombocytopenia. *Blood* 1976;47:13-21.
- 2 Yoo D, Weems H, Lessin LS. Platelet to leukocyte adherence phenomena (platelet satellitism) and phagocytosis by neutrophils associated with *in vitro* platelet dysfunction. *Acta Haematol* 1982;68:142-8.
- 3 Bodensteiner D, Talley R, Rosenfeld C. Platelet satellitism: a possible mechanism. *South Med J* 1987;80:459-61.
- 4 Rosenfeld CS, Nichols G, Bodensteiner DC. Flow cytometric measurement of antiplatelet antibodies. *Am J Clin Pathol* 1987;87:518-22.
- 5 Mattock C, Treasure T, Crawford N, Machin SJ. Failure to detect excess platelet surface thrombospondin following cardio-pulmonary bypass is not due to heparin. *Br J Haematol* 1990;74(suppl 1):48.
- 6 Mason DY, Cordell JL, Abdulaziz Z, Naiem M, Bordenave G. Preparation of peroxidase:antiperoxidase (PAP) complexes for immunohistological labelling of monoclonal antibodies. *J Histochem Cytochem* 1982; 30:1114-22.
- 7 Jungi TW, Spycher MO, Nydegger UE, Barandun S. Platelet-leukocyte interaction: selective binding of thrombin-stimulated platelets to human monocytes, polymorphonuclear leukocytes, and related cell lines. *Blood* 1986; 67:629-36.
- 8 Silverstein RL, Asch AS, Nachman RL. Glycoprotein IV mediates thrombospondin-dependent platelet-monocyte and platelet-U937 cell adhesion. *J Clin Invest* 1989; 84:546-52.
- 9 Larsen E, Celi A, Gilbert GE, *et al.* PADGEM protein: a receptor that mediates the interaction of activated platelets with neutrophils and monocytes. *Cell* 1989;59:305-12.
- 10 Boughton BJ, Corbett WE, Ginsburg AD. Myeloproliferative disorders: A paradox of *in-vivo* and *in-vitro* platelet function. *J Clin Pathol* 1977;30:228-34.