



Published in final edited form as:

JAMA Neurol. 2013 February ; 70(2): 258–261. doi:10.1001/jamaneurol.2013.595.

Mitochondrial Cardioencephalomyopathy Due to a Novel *SCO2* Mutation in a Brazilian Patient

Juliana Gurgel-Giannetti, MD, PhD, Guilherme Oliveira, PhD, Geraldo Brasileiro Filho, MD, PhD, Poliana Martins, PhD, Mariz Vainzof, PhD, and Michio Hirano, MD, PhD

Pediatric Neurology Service, Department of Pediatrics (Dr Gurgel-Giannetti) and Department of Anatomic Pathology and Forensic Medicine (Dr Brasileiro Filho), Medical School, Universidade Federal de Minas Gerais, and FioCruz (Dr Oliveira), Belo Horizonte, and Centro de Estudos do Genoma Humano, Universidade de São Paulo, São Paulo (Drs Martins and Vainzof), Brazil; and Department of Neurology, Columbia University Medical Center, New York, New York (Dr Hirano)

Abstract

Objectives—To review all patients with *SCO2* mutations and to describe a Brazilian patient with cardioencephalomyopathy carrying compound heterozygous mutations in *SCO2*, one being the known pathogenic p.E140K mutation and the other a novel 12–base pair (bp) deletion at nucleotides 1519 through 1530 (c.1519_1530del).

Design—Case report and literature review.

Setting—University hospital

Patient—Infant girl presenting with an encephalomyopathy, inspiratory stridor, ventilator failure, progressive hypotonia, and weakness, leading to death.

Main Outcome Measures—Clinical features, neuro-imaging findings, muscle biopsy with histochemical analysis, and genetic studies.

Results—This infant girl was the first child of healthy, nonconsanguineous parents. She developed progressive muscular hypotonia and ventilatory failure. At the end of the first month of life, she developed cardiomegaly and signs of cardiac failure. Routine blood tests showed lactic acidosis and mild elevation of the creatine kinase level. Brain magnetic resonance imaging showed increased T2 and fluid-attenuated inversion recovery signals in the putamen bilaterally. Nerve conduction studies showed severe axonal sensorimotor neuropathy. Muscle biopsy revealed a neurogenic pattern with mitochondrial proliferation and total absence of cytochrome-*c* oxidase histochemical stain. Sequencing of *SCO2* showed that the patient had compound heterozygote

Correspondence: Juliana Gurgel-Giannetti, MD, PhD, Pediatric Neurology Service, Department of Pediatrics, Universidade Federal de Minas Gerais, Rua Rio Grande do Norte, 57/606 Belo Horizonte, Minas Gerais 30.130-130, Brazil (gurgelju@yahoo.com.br).

Author Contributions: *Study concept and design:* Gurgel-Giannetti. *Acquisition of data:* Gurgel-Giannetti, Oliveira, and Martins. *Analysis and interpretation of data:* Gurgel-Giannetti, Oliveira, Brasileiro Filho, Vainzof, and Hirano. *Drafting of the manuscript:* Gurgel-Giannetti, Martins, and Hirano. *Critical revision of the manuscript for important intellectual content:* Gurgel-Giannetti, Oliveira, Brasileiro Filho, Vainzof, and Hirano. *Obtained funding:* Oliveira. *Administrative, technical, and material support:* Oliveira, Brasileiro Filho, Martins, and Hirano. *Study supervision:* Gurgel-Giannetti and Vainzof.

Conflict of Interest Disclosures: None reported.

SCO2 mutations: the previously described c.1541G A (p.E140K) mutation and a novel 12-bp deletion at nucleotides 1519 through 1530 (c.1519_1530del). The patient died at age 45 days.

Conclusions—Our findings and the literature review indicate that it is important to consider the diagnosis of mitochondrial disease in newborns with hypotonia and cardiomyopathy. In our case, the accurate diagnosis of *SCO2* mutations is particularly important for genetic counseling.

HUMAN *SCO2* PROTEIN IS essential for assembly of the catalytic core of cytochrome-*c* oxidase (COX), complex IV of the mitochondrial respiratory chain. Mutations in *SCO2* (GenBank AF177385) cause an infantile cardioencephalomyopathy with severe deficiency of COX in heart, brain, and muscle.^{1,2}

The main clinical manifestations are progressive muscular hypotonia, hypertrophic cardiomyopathy, and encephalopathy. The disease typically presents during the neonatal period, and the majority of the patients die in the first year of life. Cardiopulmonary failure is the most common cause of death.²

Almost all reported patients have had the p.E140K missense mutation, which can be homozygous or compound heterozygous. Patients with a homozygous p.E140K mutation show milder clinical phenotypes than those with a compound heterozygous mutation.² Only about 50 cases have been described worldwide.¹⁻¹⁵ Herein, we describe a Brazilian patient with a fatal cardioencephalomyopathy due to compound heterozygous *SCO2* mutations, one being p.E140K and the other a 12–base pair (bp) deletion (c.1519_1530del).

REPORT OF A CASE

This infant girl is the first child of healthy, nonconsanguineous parents. After an uneventful pregnancy, she was born at 39 weeks' gestation by vaginal delivery with fetal extraction difficulties. At birth, her weight was 2600 g, her length was 49.5 cm, and Apgar scores were 9 at 1 minute and 10 at 5 minutes; however, the newborn had inspiratory stridor, hypotonic lower limbs, and hypertonic upper limbs. She developed progressive muscular hypotonia and ventilatory failure, prompting transfer to the neonatal intensive care unit. At the end of the first month of life, she developed cardiomegaly (as shown on chest radiography) and signs of cardiac failure. Routine blood tests showed lactic acidosis and mild elevation of the creatine kinase level. Brain magnetic resonance imaging showed increased T2 and fluid-attenuated inversion recovery signals in the putamen bilaterally, and proton magnetic resonance spectroscopy showed an increased lactic acid doublet peak in the ventricular system and cerebral parenchyma (**Figure 1**). Nerve conduction studies and electromyography showed severe axonal sensorimotor neuropathy. Muscle biopsy revealed a neurogenic pattern with mitochondrial proliferation and total absence of COX histochemical stain (**Figure 2**). There was mild lipid and glycogen accumulation in muscle fibers. Sequencing of *SCO2* showed that the patient had compound heterozygous *SCO2* mutations, one being the previously described c.1541G A (p.E140K) mutation and the other a novel 12-bp deletion at nucleotides 1519 through 1530 (c.1519_1530del). Segregation analysis revealed that the father was a heterozygous carrier of the p.E140K mutation and the mother showed the deletion in heterozygosity (**Figure 3**). Both parents were clinically asymptomatic. The patient died at age 45 days.

COMMENT

The SCO2 protein is a metallochaperone that is essential for assembly of the catalytic core of COX.¹ Numerous additional proteins are required for efficient COX assembly and maintenance. Mutations in different nuclear genes encoding these proteins have been described, including *SURF1*, *SCO1*, *SCO2*, *COX10*, and *COX15*. The phenotypes associated with these genetic defects are typically severe and fatal.⁶

To date, about 50 patients with mutations in *SCO2* have been described.¹⁻¹⁵ The p.E140K mutation was found in all patients either in heterozygosity or in association with a second mutation (compound heterozygosity), except one patient described in 2009 by Mobley et al¹³ who had a homozygous p.G193S mutation (**Table**). Patients harboring a homozygous p.E140K mutation have shown late onset and longer survival compared with patients with compound heterozygous *SCO2* mutations.^{2,6,12,14,15} Our patient showed the common p.E140K mutation and a novel 12-bp deletion at nucleotides 1519 through 1530. The SCO proteins contain a conserved pair of cysteines separated by 3 residues, a motif that has been proposed to bind copper. Both genetic defects in our patient are adjacent to the SCO2 CXXXC copper-binding motif between Cys133 and Cys137, which is a critical region of SCO2.¹ The clinical consequence of this compound heterozygous mutation was a severe phenotype and early death.

In the initial description of *SCO2* mutations, patients were noted to have abnormalities in the nervous system, heart, and skeletal muscle (cardioencephalomyopathy).¹ Since then, other manifestations of *SCO2* mutations have included Leigh syndrome, hypertrophic cardiomyopathy, lactic acidosis, stridor with ventilator insufficiency, and a spinal muscular atrophy–like phenotype.²⁻¹⁵ Our patient showed a complex phenotype characterized by encephalopathy, cardiomyopathy, peripheral neuropathy, stridor, ventilator insufficiency, and lactic acidosis. Brain magnetic resonance imaging showed increased T2 and fluid-attenuated inversion recovery signals in the putamen bilaterally, indicating Leigh syndrome. Proton magnetic resonance spectroscopy showed a lactic acid peak in the ventricular system and cerebral parenchyma as commonly observed in other mitochondrial diseases. The patient developed cardiomyopathy, which was ultimately fatal.

Nerve conduction studies and electromyography in our patient revealed a severe axonal sensorimotor neuropathy. In 1999, Papadopoulou et al¹ described 3 patients with *SCO2* mutations, but among them just 1 showed peripheral neuropathy. The electrophysiological findings have rarely been reported. This fact could be related to the difficulty of performing this examination in very young infants as well as the severity and early fatal outcome of the disease.

Among patients described with *SCO2* mutations, muscle histopathological analysis has revealed varying abnormalities. In 2010, Pronicki et al¹⁴ described the pathological changes in muscles of 18 affected infants and noted 4 different patterns: type A, the spinal muscular atrophy pattern characterized by the presence of distinct atrophic and hypertrophic muscle fibers arranged in groups; type B, the spinal muscular atrophy–like pattern with a mixture of fibers of varying diameters generally not grouped; type C, dispersed and grouped neurogenic

atrophy with small angulated fibers strongly reactive for oxidative enzymes; and type D, a nonspecific pattern with variability of muscle fiber size. Among the 18 patients, those with homozygous or compound heterozygous *SCO2* mutations showed the type A or B pattern in muscle biopsy, while patients with uncertain or unconfirmed molecular background of the disease had the type C or D pattern. Our patient with the p.E140K and c.1519_1530del mutations showed fascicles with groups of atrophic or hypertrophic fibers compatible with the type A histopathological pattern (spinal muscular atrophy pattern).

The frequencies of causes of COX deficiency are unknown, but among children with COX deficiency, *SCO2* mutations appear to be frequent genetic causes. In 2006, Böhm et al¹⁶ published a retrospective multicenter study of 180 children with COX deficiency. They identified pathogenic mutations in 75 patients and showed a striking prevalence of 2 nuclear gene mutations: c.845_846del_CT in *SURF1* and a c.1541G A (p.E140K) transition in *SCO2* in the Slavic population. In addition, Vesela et al¹⁰ studied 26 children with COX deficiency and found *SCO2* mutations in 6 patients, leading them to conclude that *SCO2* mutations are not rare in their population.

More recently, Honzik et al¹⁷ published a retrospective study that evaluated 461 patients with confirmed mitochondrial disease. The neonatal onset was reported in 28% of the patients, and a high incidence of neonatal cardiomyopathy was observed among them (40%). They proposed a diagnostic flowchart applicable to ill neonates suspicious for mitochondrial disorders. In this approach, the sequencing analysis of *SCO1* and *SCO2* was suggested if the neonate presented with a cardiomyopathy.

Our findings and the literature review indicate that it is important to consider the diagnosis of mitochondrial disease in newborns with hypotonia and cardiomyopathy. In our case, the accurate diagnosis of *SCO2* mutations was important as it allows genetic counseling and enables pregestation or prenatal diagnosis in subsequent pregnancies of the parents.

REFERENCES

1. Papadopoulou LC, Sue CM, Davidson MM, et al. Fatal infantile cardioencephalomyopathy with COX deficiency and mutations in *SCO2*, a COX assembly gene. *Nat Genet.* 1999; 23(3):333–337. [PubMed: 10545952]
2. Verdijk RM, de Krijger R, Schoonderwoerd K, et al. Phenotypic consequences of a novel *SCO2* gene mutation. *Am J Med Genet A.* 2008; 146A(21):2822–2827. [PubMed: 18924171]
3. Jaksch M, Ogilvie I, Yao J, et al. Mutations in *SCO2* are associated with a distinct form of hypertrophic cardiomyopathy and cytochrome c oxidase deficiency. *Hum Mol Genet.* 2000; 9(5): 795–801. [PubMed: 10749987]
4. Sue CM, Karadimas C, Checcarelli N, et al. Differential features of patients with mutations in two COX assembly genes, *SURF-1* and *SCO2*. *Ann Neurol.* 2000; 47(5):589–595. [PubMed: 10805329]
5. Salviati L, Sacconi S, Rasalan MM, et al. Cytochrome c oxidase deficiency due to a novel *SCO2* mutation mimics Werdnig-Hoffmann disease. *Arch Neurol.* 2002; 59(5):862–865. [PubMed: 12020273]
6. Sacconi S, Salviati L, Sue CM, et al. Mutation screening in patients with isolated cytochrome c oxidase deficiency. *Pediatr Res.* 2003; 53(2):224–230. [PubMed: 12538779]
7. Foltopoulou PF, Zachariadis GA, Politou AS, Tsiftoglou AS, Papadopoulou LC. Human recombinant mutated forms of the mitochondrial COX assembly Sco2 protein differ from wild-type

- in physical state and copper binding capacity. *Mol Genet Metab.* 2004; 81(3):225–236. [PubMed: 14972329]
8. Tarnopolsky MA, Bourgeois JM, Fu MH, et al. Novel *SCO2* mutation (G1521A) presenting as a spinal muscular atrophy type I phenotype. *Am J Med Genet A.* 2004; 125A(3):310–314. [PubMed: 14994243]
 9. Tay SK, Shanske S, Kaplan P, DiMauro S. Association of mutations in *SCO2*, a cytochrome c oxidase assembly gene, with early fetal lethality. *Arch Neurol.* 2004; 61(6):950–952. [PubMed: 15210538]
 10. Vesela K, Hansikova H, Tesarova M, et al. Clinical, biochemical and molecular analyses of six patients with isolated cytochrome c oxidase deficiency due to mutations in the *SCO2* gene. *Acta Paediatr.* 2004; 93(10):1312–1317. [PubMed: 15499950]
 11. Leary SC, Mattman A, Wai T, et al. A hemizygous *SCO2* mutation in an early on-set rapidly progressive, fatal cardiomyopathy. *Mol Genet Metab.* 2006; 89(1-2):129–133. [PubMed: 16765077]
 12. Knuf M, Faber J, Huth RG, Freisinger P, Zepp F, Kampmann C. Identification of a novel compound heterozygote *SCO2* mutation in cytochrome c oxidase deficient fatal infantile cardioencephalomyopathy. *Acta Paediatr.* 2007; 96(1):130–132. [PubMed: 17187620]
 13. Mobley BC, Enns GM, Wong LJ, Vogel H. A novel homozygous *SCO2* mutation, p.G193S, causing fatal infantile cardioencephalomyopathy. *Clin Neuropathol.* 2009; 28(2):143–149. [PubMed: 19353847]
 14. Pronicki M, Kowalski P, Piekutowska-Abramczuk D, et al. A homozygous mutation in the *SCO2* gene causes a spinal muscular atrophy like presentation with stridor and respiratory insufficiency. *Eur J Paediatr Neurol.* 2010; 14(3):253–260. [PubMed: 19879173]
 15. Joost K, Rodenburg R, Piirsoo A, van den Heuvel B, Zordania R, Ounap K. A novel mutation in the *SCO2* gene in a neonate with early-onset cardioencephalomyopathy. *Pediatr Neurol.* 2010; 42(3):227–230. [PubMed: 20159436]
 16. Böhm M, Pronicka E, Karczmarewicz E, et al. Retrospective, multicentric study of 180 children with cytochrome C oxidase deficiency. *Pediatr Res.* 2006; 59(1):21–26. [PubMed: 16326995]
 17. Honzik T, Tesarova M, Magner M, et al. Neonatal onset of mitochondrial disorders in 129 patients: clinical and laboratory characteristics and a new approach to diagnosis. *J Inher Metab Dis.* 2012; 35(5):749–759. [PubMed: 22231385]

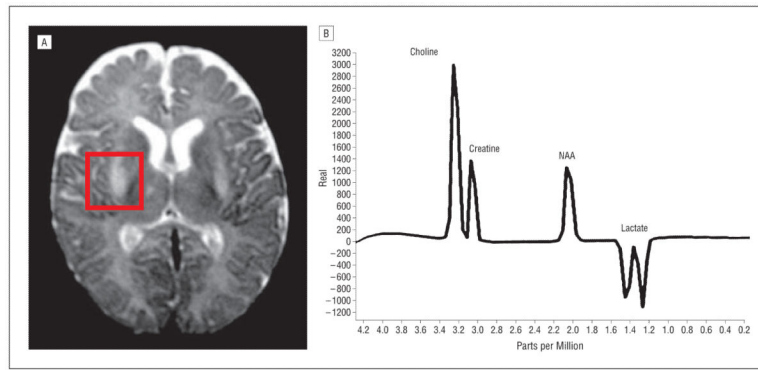


Figure 1. Brain magnetic resonance imaging (A) and proton magnetic resonance spectroscopy (B) showing a Leigh syndrome–like pattern with a lactate doublet peak in the brain tissue and ventricular system. NAA indicates *N*-acetylaspartate.

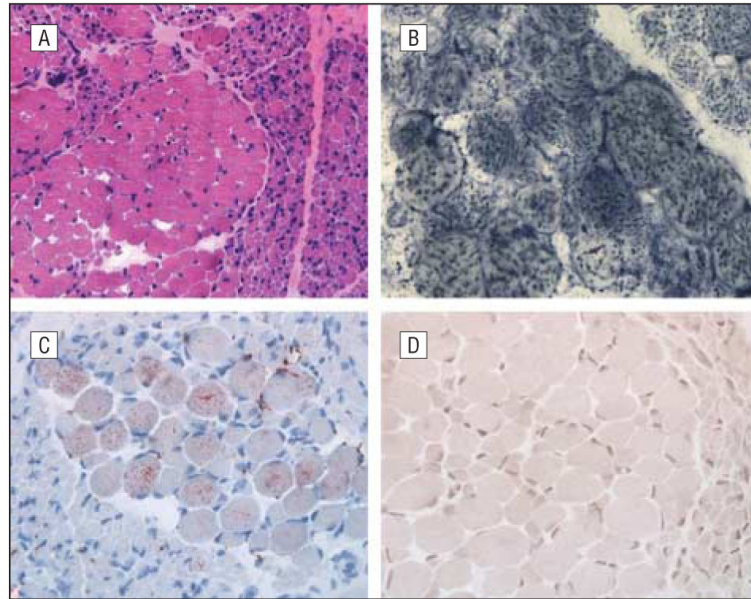


Figure 2. Muscle biopsy. A, Neurogenic pattern evident in hematoxylin-eosin staining (original magnification $\times 10$). B, Mitochondrial proliferation revealed by succinate dehydrogenase histochemistry (original magnification $\times 40$). C, Some hypertrophic fibers with mild lipid excess demonstrated by oil red O staining (original magnification $\times 20$). D, Cytochrome-*c* oxidase histochemistry showing absence of detectable activity in all fibers (original magnification $\times 20$).

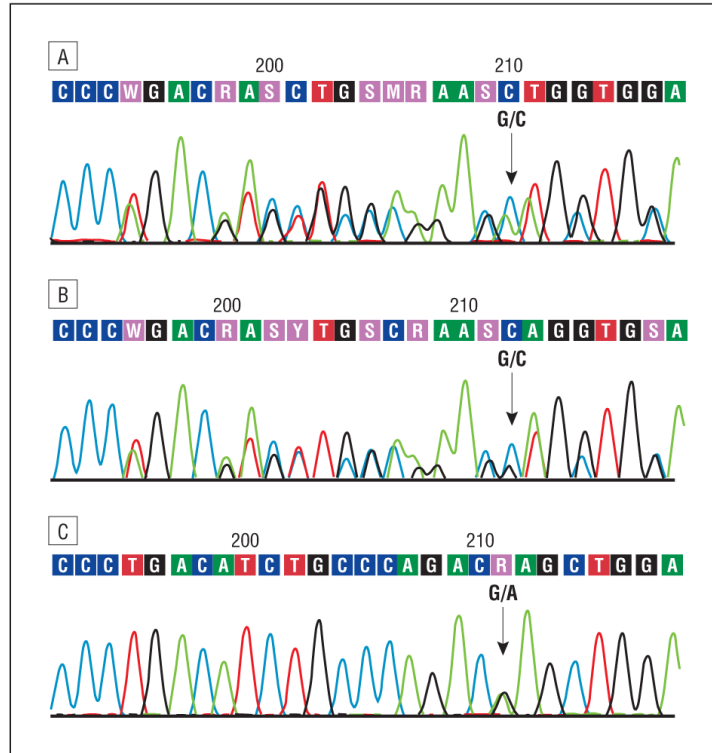


Figure 3. Sequencing analysis of *SCO2*. A, Representative electropherogram of the DNA (sense strand) from the patient showing the compound heterozygous mutations c.1541G A (p.E140K) and a 12–base pair (bp) deletion at c.1519-1530. B, Representative electropherogram of the DNA (sense strand) from the patient’s mother showing the deletion (12 bp at c.1519-1530) in heterozygosity, without the p.E140K mutation. C, Representative electropherogram of the DNA (sense strand) from the patient’s father showing the heterozygous p.E140K mutation.

TableClinical and Genetic Data of Published Cases With *SCO2* Mutations

Source	Phenotype	Muscle	Genotype
Papadopoulou et al, ¹ 1999	Cardioencephalomyopathy, 3 patients	Absence of COX activity	p.Q53X/E140K in 2 patients, p.E140K/S225F in 1 patient
Jaksch et al, ³ 2000	Cardioencephalomyopathy, 3 patients	Absence of COX activity	E140K/R171W in 1 patient, E140K/R90X in 2 patients (siblings)
Sue et al, ⁴ 2000	Encephalopathy and hypertrophic cardiomyopathy, 3 patients	Absence of COX activity	Compound heterozygosity, p.E140K/Q53X in 2 patients, p.E140K/S222F in 1 patient
Salviati et al, ⁵ 2002	Cardioencephalomyopathy and SMA phenotype, 1 patient	Absence of COX activity, neurogenic pattern	Compound heterozygosity, p.E140K and 10-bp duplication of nucleotides 1302-1311
Sacconi et al, ⁶ 2003	Leigh syndrome, 1 patient	Absence of COX activity	Compound heterozygosity, p.E140K/L151P
Foltopoulou et al, ⁷ 2004	Cardioencephalomyopathy, 3 patients	Absence of COX activity	E140K, S225F
Tarnopolsky et al, ⁸ 2004	Cardiomyopathy and SMA, 1 patient	Absence of COX activity, neurogenic pattern	Compound heterozygosity, p.E140K and p.C133Y
Tay et al, ⁹ 2004	Cardioencephalomyopathy, 1 patient	Absence of COX activity, neurogenic pattern	Compound heterozygosity, p.E140K and p.Q53X
Vesela et al, ¹⁰ 2004	Cardioencephalomyopathy, 6 patients	Absence of COX activity	p.E140K homozygosity in 5 patients, p.E140K/Q53X compound heterozygosity in 1 patient
Leary et al, ¹¹ 2006	Cardiomyopathy, 1 patient	Absence of COX activity	Homozygous p.E140K, hemizygous 16-bp intron deletion
Knuf et al, ¹² 2007	Fatal cardioencephalomyopathy, 1 patient	Absence of COX activity	Compound heterozygosity, E140K/V160G
Verdijk et al, ² 2008	Fatal cardioencephalomyopathy, 1 patient	Absence of COX activity	Compound heterozygosity, p.E140K/W36X
Mobley et al, ¹³ 2009	Fatal infantile cardioencephalomyopathy, 1 patient		Homozygous p.G193S
Pronicki et al, ¹⁴ 2010	Floppy infant with stridor and respiratory insufficiency, hypertrophic cardiomyopathy, 18 patients	Neurogenic and other patterns, absence of COX activity	p.E140K in all patients, p.Q53X in 1 patient, p.M177T in 1 patient
Joost et al, ¹⁵ 2010	Leigh syndrome and cardioencephalomyopathy, 1 patient (mother with mental retardation)	Total absence of COX activity	Compound heterozygosity, c.418G>A (father), 19-bp insertion at position 17 (mother)
Present case	Cardioencephalomyopathy, stridor, neuropathy, 1 patient	Total absence of COX activity	Compound heterozygosity, p.E140K and 12-bp deletion (c.1519_1530del)

Abbreviations: bp, base pair; COX, cytochrome-*c* oxidase; SMA, spinal muscular atrophy.