

Rapid identification of Ebola virus and related filoviruses in fluid specimens using indirect immunoelectron microscopy

T W Geisbert, J B Rhoderick, P B Jahrling

Abstract

Recent filoviral outbreaks in animal primates have raised public awareness of the potential for filoviruses to become a public health concern; methods that efficiently identify these viruses are therefore of high priority. An indirect immunoelectron microscopy method, which uses homologous guinea pig polyclonal antiserum, successfully identified Ebola-related (Reston) virus particles in serum and tissue culture fluid specimens with infectivity titres of 300 plaque forming units (pfu) per ml or more. The sensitivity of this procedure is sufficient to show virus in most acute phase sera, and is equal to that of the antigen capture enzyme linked immunosorbent assay (ELISA). The immunoelectron microscopy fluid technique can differentiate among antigenically distinct filoviruses in less than three hours. It should be valuable in the rapid diagnosis of potential filoviral infections.

We recently showed that "post-embedment" immunoelectron microscopy of MA-104 cells, inoculated with serum from sick animal primates, is useful in diagnosing filoviral (Marburg, Ebola, or Reston) infections.¹ Since the recent importation of Ebola-related Reston virus into the United States,² development of rapid diagnostic procedures for these viruses is now of special concern. In a refinement of the immunoelectron microscopy

procedure, we adapted the method of Lin³ to show the presence of Ebola-related virus (Reston virus) in fluid specimens. This adaptation is more rapid and simpler to perform than thin section examination of inoculated cell cultures.

Methods

Our immunoelectron microscopy procedure critically depends on the use of guinea pig antisera, collected and pooled 99 days after subcutaneous inoculation of guinea pigs with 500 plaque forming units (pfu) of Reston virus. The immunofluorescent antibody titre of this pool was 1/160 against Reston virus.

About 1.5 cc of fluid, such as serum, plasma, and tissue culture supernatant, was centrifuged in a conical Eppendorf microfuge tube at 12 000 × g for 15 minutes. The supernatant was removed, and the virus pellet resuspended in 5–10 μl of phosphate buffered saline (PBS), and transferred to a 300-mesh, nickel electron microscopy grid pre-coated with Formvar and carbon. After blotting excess fluid the grid was completely immersed for 45 minutes at 23°C in a dilution (1 in 150) of guinea pig antiserum against Reston virus in TRIS-buffer containing 0.1% bovine serum albumin and 0.05% Tween-20 (pH = 8.1). The grid was washed with TRIS-bovine serum albumin-Tween buffer (pH = 7.2) for five minutes and transferred for 45 minutes at 23°C to anti-guinea pig IgG labelled with 10 nm gold spheres (Janssen Life Sciences), diluted 1 in 10 in the TRIS-buffer (pH = 8.1). The grid was washed by successive immersion in three drops of TRIS-bovine serum albumin-Tween buffer (pH = 7.2), two drops of PBS, and fixed in a drop of 2% glutaraldehyde in PBS for five minutes. After fixation, the grid was rinsed in drops of distilled water and negatively stained with 1% phosphotungstic acid (pH = 6.6).

Results

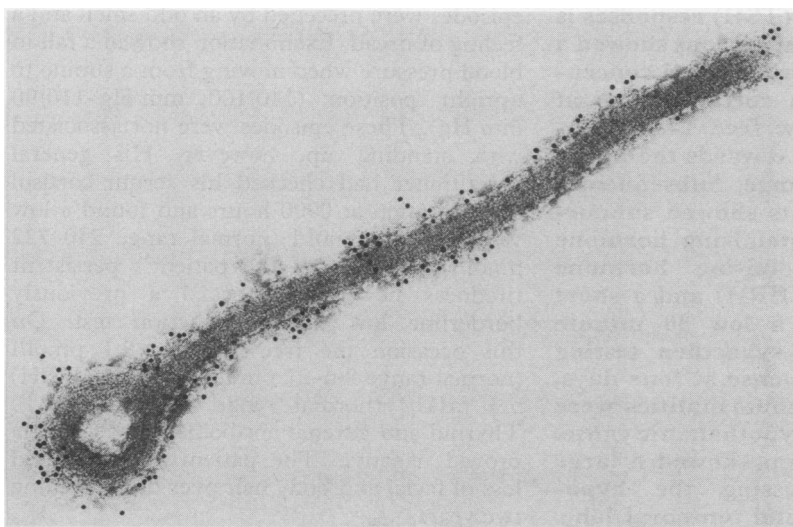
Positive immunogold staining was observed when Reston guinea pig antiserum was diluted 1 in 150 (figure). Dilutions of antiserum exceeding 1 in 250 diminished positive labelling. Reston virions did not label when incubated with normal guinea pig serum diluted 1 in 150. Non-specific background staining of the support film, reported by Hopley and Doane,⁴ was negligible at 1 in 150, but evident when higher concentrations of

The views of the authors do not purport to reflect the position of the Department of the Army or the Department of Defense.

Disease Assessment
Division, US Army
Medical Research
Institute of Infectious
Diseases, Fort Detrick,
Frederick, Maryland
21702-5011, USA
T W Geisbert
J B Rhoderick
P B Jahrling

Correspondence to:
Dr T W Geisbert

Accepted for publication
6 December 1990



Positive gold sphere staining of a Reston virion was observed with immunoelectron microscopy performed as described. Preparation was stained by negative contrast with 1% phosphotungstic acid (pH = 6.6).

antiserum (dilutions of ≤ 1 in 50) were used. Even when antiserum was diluted 1 in 50, however, stained virions were clearly discernible over background staining. Staining was equally intense and background manageable with both serum and tissue culture supernatants. Our technique successfully detected virus in samples with infectivity titres of 300 pfu/ml or more.

Discussion

Although filoviruses are morphologically distinct, they may be difficult to detect in fluid preparations poorly preserved or improperly contrast stained. Use of colloidal gold markers assisted in identifying virions in crude specimens. Sensitivity of our procedure is sufficient for most samples, certainly tissue culture fluids, and most acute phase sera. Immunoelectron microscopy sensitivity is similar to that of the antigen capture enzyme

linked immunosorbent assay (ELISA).² Tissue culture is more sensitive, but requires more time (three to 10 days). A major advantage of the immunoelectron microscopy fluid technique is that it gives a specific immunological identification of filoviral particles in less than three hours. It therefore has the potential to become a valuable tool for the rapid diagnosis of filoviral infections.

- 1 Geisbert TW, Jahrling PB. Use of immunoelectron microscopy to show Ebola virus during the 1989 United States epizootic. *J Clin Pathol* 1990;43:813-16.
- 2 Jahrling PB, Geisbert TW, Dalgard DW, et al. Preliminary report: isolation of Ebola virus from monkeys imported to USA. *Lancet* 1990;335:502-5.
- 3 Lin N. Gold-IgG complexes improve the detection and identification of viruses in leaf dip preparations. *J Virol Methods* 1984;8:181-90.
- 4 Hopley JFA, Doane FW. Development of a sensitive protein A-gold immunoelectron microscopy method for detecting viral antigens in fluid specimens. *J Virol Methods* 1985; 12:135-47.

Exaggerated and prolonged thyrotrophin releasing hormone (TRH) test responses in tertiary hypothyroidism

G H Mills, R D Ellis, P R Beck

Abstract

A 60 year old man with panhypopituitarism due to a large meningioma and prolonged and exaggerated thyroid stimulating hormone (TSH) responses is described. Initial investigations showed a subnormal urinary free cortisol concentration, a low serum cortisol taken at 0900 hours, and a low free T4 concentration. The TSH was towards the upper end of the normal range. Subsequently pituitary function tests showed subnormal production of luteinising hormone in response to luteinising hormone releasing hormone (LHRH) and a short synacthen test with a low 30 minute cortisol value. Long synacthen testing showed a normal response at four days, confirming that the abnormalities were due to a pituitary or hypothalamic cause. A computed tomogram showed a large meningioma compressing the hypothalamus, pituitary, and temporal lobe. TRH testing showed a prolonged and exaggerated response, consistent with tertiary hypothyroidism.

Case report

A 60 year old man presented with an 18 month history of episodes of feeling faint. He also complained of weight gain. These episodes were preceded by an odd smell and a feeling of dread. Examination showed a fall in blood pressure when moving from a supine to upright position (140/100 mm Hg-110/90 mm Hg). These episodes were not associated with standing up, however. His general practitioner had checked his serum cortisol concentration at 0900 hours and found a low value of 163 nmol/l (normal range 240-722 nmol/l). In view of the patient's persistent tiredness he had rechecked a previously borderline low thyroid function test. On this occasion the free T4 was 8.1 pmol/l (normal range 8.6-27 pmol/l), and the (TSH) 5.3 mIU/l (normal range 0.5-6.5 mIU/l). Thyroid and adrenal antibodies subsequently proved negative. The patient also admitted loss of facial and body hair over the preceding two years.

Overall, the differential diagnosis was felt to be between hypopituitarism or hypoadrenalism, with possible temporal lobe epilepsy.

Department of
Medicine,
Rotherham District
General Hospital,
Rotherham S60 2UD
G H Mills

Department of
Clinical Biochemistry
R D Ellis
P R Beck

Correspondence to:
Dr G H Mills

Accepted for publication
6 December 1990