



The Result of *In Situ* Pinning for Valgus Impacted Femoral Neck Fractures of Patients over 70 Years Old

Yoon-Chung Kim, MD, Joo-Yup Lee, MD, PhD, Joo-Hyoun Song, MD, PhD, Seungbae Oh, MD

Department of Orthopedic Surgery, The Catholic University of Korea, St. Vincent's Hospital, Suwon, Korea

Purpose: We aimed to evaluate the outcome of fixation with cannulated screws for valgus impacted femoral neck fractures in patients over 70 years of age.

Materials and Methods: We reviewed the outcome in 33 patients older than 70 years with valgus impacted femoral neck fractures who were treated with cannulated screws fixation from May 2007 to December 2010. These patients were followed for at least a year. We assessed the fixation failure rate, body mass index (BMI), bone mineral density (BMD) of proximal femur, distance between screw tip and joint, number of screws and time from fracture to operation.

Results: We identified six patients (18.2%) with failure. Two patients with subtrochanteric fractures through the screw insertion site and another patient with osteonecrosis were excluded from the fixation failure group. No difference was found in age, BMI, BMD of proximal femur, distance between screw tip and joint, number of screws and time from fracture to operation between failure and non-failure groups.

Conclusion: The failure rate of cannulated screw fixation for valgus impacted femoral neck fractures in the elderly patients was not low. Risk of failure should be considered in the management of these patients and accurate assessment for fracture type should be performed using computed tomogram and clinical evaluation.

Key Words: Valgus, Impacted, Femoral neck fracture, Internal fixation, Elderly patient

Submitted: August 1, 2014 1st revision: August 18, 2014
2nd revision: October 7, 2014 Final acceptance: October 10, 2014

Address reprint request to

Joo-Hyoun Song, MD, PhD

Department of Orthopedic Surgery, The Catholic University of Korea, St. Vincent's Hospital, 93 Jungbudaero, Paldal-gu, Suwon 442-723, Korea

TEL: +82-31-249-8172 FAX: +82-31-254-7186

E-mail: delmarsong@naver.com

This is an Open Access article distributed under the terms of the Creative Commons Attribution Non-Commercial License (<http://creativecommons.org/licenses/by-nc/3.0>) which permits unrestricted non-commercial use, distribution, and reproduction in any medium, provided the original work is properly cited.

INTRODUCTION

Femoral neck fractures with marked displacement in the elderly patients are primarily treated with arthroplasty as opposed to internal fixation, for its comparatively better improvement in pain, functional recovery of hip, reoperation, satisfaction of patients, quality of life and economical burdens¹⁻⁷. In contrast, the valgus impacted Garden type I femoral neck fracture is often treated with internal fixation using screws^{8,9}. Recently, there is an increase in the rate of femoral neck fractures thanks to the increased life expectancy. Internal

fixation has been widely used to treat valgus impacted femoral neck fractures. Although the prognosis of these fractures are favorable, the complication rate in elderly patients is not low¹⁰⁾ and frequency of reoperation is higher than arthroplasty^{11,12)}. In this study, we investigated clinical outcomes of fixation with cannulated screws for valgus impacted femoral neck fractures in the elderly patients.

MATERIALS AND METHODS

We studied 33 patients with valgus impacted femoral neck fractures who were over 70 years of age and were treated with cannulated screw fixation from May 2007 to December 2010. These patients were followed at least for one year. Twelve male and 21 female patients were included with an average age of 77 years old (70-100 years). Valgus impacted fracture was diagnosed only with plain films. The fracture was not managed with reduction. A guide wire for cannulated screws was non-invasively inserted with the aid of image intensifier. Upon acquisition of an acceptable position for the guide wire, limited incision was made for introduction of screws and the internal fixation was completed with 3-4 cannulated screws. Six patients received three screws for internal fixation, half of whom failed to achieve internal fixation. Use of three screws was limited to patients

under 75 years old and older patients had all received four screws. Patients were allowed to put body weight on the repaired fracture at the earliest feasible time, which was 3.5 days on average. Postoperative radiographic examinations were done at 2, 4, 8, and 12 weeks after surgery. Failure of internal fixation was defined by the fulfillment of one these conditions³⁾: dislocation (>1 cm) of the fracture site, penetration of cannulated screws into the joint via the femoral head, more than 2 cm backward displacement of the cannulated screws and change in the angle (>5%) between screws that necessitates total hip replacement. We identified the patients with internal fixation failure (defined as the internal fixation failure group) and compared their age, bone mineral density (BMD) of proximal femur, numbers of cannulated screws, distance between screw tip and joint, time from fracture to operation (i.e., internal fixation) and body mass index (BMI) with patients achieving successful bone union (defined as the bone union group). Independent *t*-test and logistic regression were used for statistical analysis and a *P*-values less than 0.05 were considered statistically significant (Fig. 1).

RESULTS

Failure of internal fixation was identified in six patients

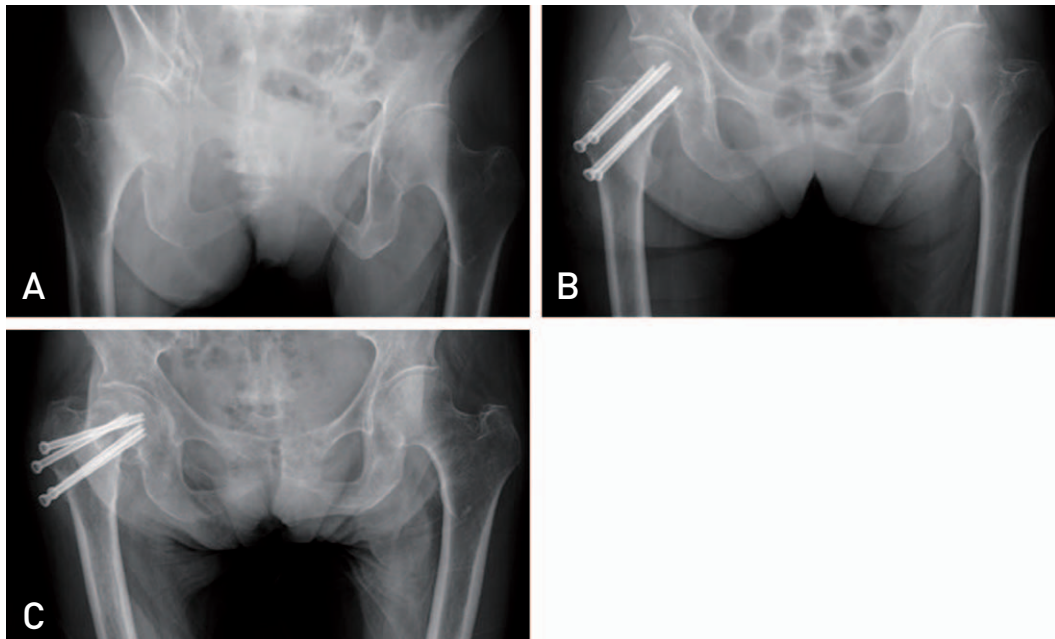


Fig. 1. Eighty two year-old female patient with valgus impacted right femoral neck fracture. (A) Preoperative plain film shows valgus impacted neck fracture in the right femur. (B) *In situ* internal fixation with 4 cannulated screws. (C) Six weeks after the operation, fixation failure occurred.

(18.2%) out of the 33 studied patients. Two other patients had subtrochanteric fractures through the screw insertion site and another patient had post-traumatic femoral head necrosis, who were not included in the internal fixation failure group. The failure of internal fixation could be identified as early as three weeks after the surgery and in all cases within eight weeks (average: 4 weeks). Secondary falling accidents after surgery was the cause of subtrochanteric fractures through the screw insertion site in the two identified patients (Fig. 2).

There was no difference between the age of the patients in the internal fixation failure group (average: 78 years, range: 70-92 years) and bone union group (78 years, 70-100 years). The numbers of cannulated screws were also not different (3.8 screws in both groups). No difference was seen in the distance between the screw tip and the joint (7.3 mm and 8.1 mm for internal

fixation failure group and bone union group, respectively; $P=0.43$) and the elapsed time from fracture to operation (3.3 days and 3.9 days for internal fixation failure group and bone union group, respectively; $P=0.357$). Lastly, there was no statistically significant difference between the BMI and BMD of proximal femur of the two groups (BMI of 19.5 and 20.3 for internal fixation failure group and bone union group, respectively; Table 1).

DISCUSSION

Valgus impacted femoral neck fractures are characterized by no additional displacement and a relatively stable impaction; hence, internal fixation with screws is considered as the primary treatment option^{8,9}. Due to the paucity of earlier studies on valgus impacted

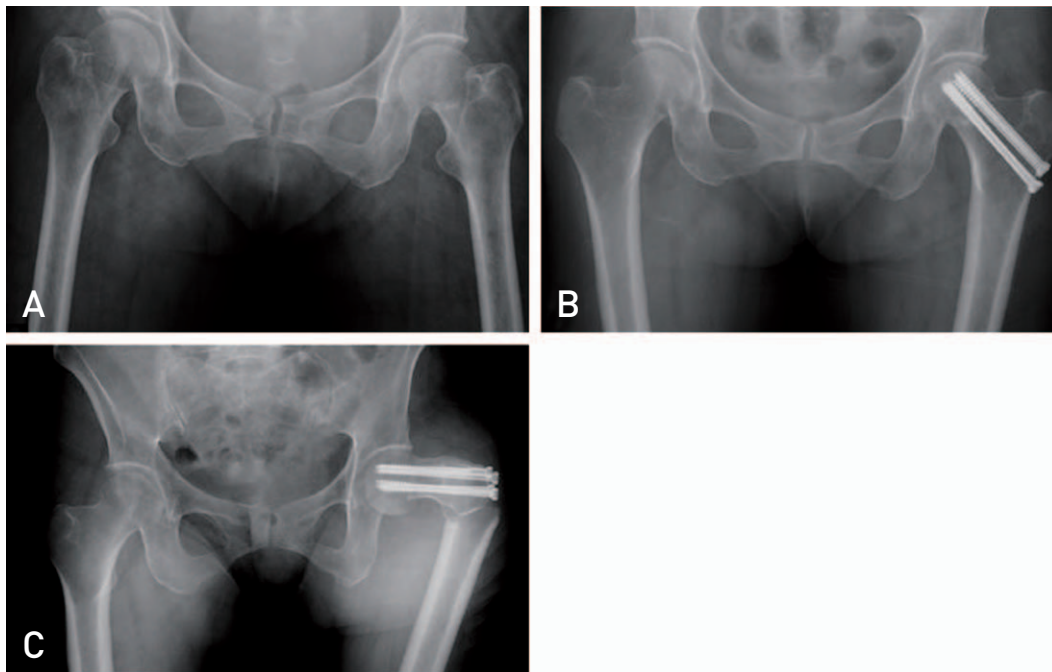


Fig. 2. Seventy two-year-old female patient with valgus impacted right femoral neck fracture. (A) Preoperative plain film shows valgus impacted neck fracture in the left femur. (B) *In situ* internal fixation with 4 cannulated screws. (C) Four weeks after the operation, subtrochanteric fracture through the pin insertion site occurred after slip down.

Table 1. Average Bone Mineral Densities of Proximal Femur

	Internal fixation failure group	Bone union group	P-value
Total	-3.2	-3.1	0.684
Neck	-3.6	-3.5	0.378
Intertrochanteric	-2.7	-2.8	0.730
Trochanteric	-3.1	-3.0	0.968

femoral neck fractures and their clinical outcomes, we reviewed reports on cases of femoral neck fractures without displacement. Gjertsen et al.¹²⁾ compared therapeutic results of arthroplasty, internal fixation for displaced femoral neck fractures and internal fixation of femoral neck fractures without displacement. The frequency of reoperation was found to be lowest in the arthroplasty, followed by the internal fixation of femoral neck fractures without displacement and displaced femoral neck fractures, showing that the clinical outcomes of internal fixation for femoral neck fractures without displacement are not favorable compared to those of arthroplasty. Similarly, Parker et al.¹³⁾ reported that arthroplasty for displaced femoral neck fractures had longer operation time and hospitalization days and higher complication rates, while re-hospitalization and reoperation rates were significantly lower compared to the internal fixation. Furthermore, Sikand et al.¹¹⁾ questioned internal fixation as the first treatment option of femoral neck fractures without displacement because no significant difference in prognosis was found between arthroplasty and internal fixation.

In a previous study on the failure rate of fixation in femoral neck fractures without displacement, Chiu and Lo¹⁴⁾ enrolled a total of 250 patients over 59 years of age and found 6%, 3.6%, and 7.2% of non-union, failure of fixation and femoral head necrosis, respectively. In another study on 375 patients, Conn and Parker¹⁵⁾ reported 7.7% of reoperation due to femoral head necrosis and non-union. Lee et al.¹⁶⁾ enrolled 182 patients with an average age of 67 year and found 10.4% of poor outcomes after 102 months of follow-up. Rogmark et al.¹⁷⁾ followed 224 patients for up to 32 months and reported 15% reoperation and 11% fixation failure. In the study conducted by Clement et al.¹⁰⁾ 162 patients older than 65 years were followed for at least a year and the fixation failure was shown to be 17.3%. Taken together, it seems reasonable to consider that based on previous studies, femoral neck fractures without displacement tend to result in poorer clinical outcomes in comparison to internal fixation. When it comes to the timing for weight bearing, Lee et al.¹⁶⁾ and Clement et al.¹⁰⁾ had the policy of allowance as soon as patients were able to do so, while the internal fixation failure was found between 4 weeks and 3 months postoperatively with an average of 5 weeks.

Our patients were older than those described in above investigations. Six patients in our study had failed fixation

(18%) and two others had subtrochanteric fractures through the screw insertion site, which makes a 24% reoperation rate. It has been shown that age^{14,15)}, degree of osteoporosis¹⁶⁾, posterior tilt on lateral radiographs^{10,15)} and walking ability of the patient before surgery¹⁵⁾ are significant prognostic factors of internal fixation failure, but we did not find a significant difference in age and BMD of proximal femur between the internal fixation failure and bone union groups. The degree of posterior tilt, however, was not investigated in our study. It warrants further analysis of preoperative computed tomography in valgus impacted femoral neck fractures to determine properties of fractures and prognosis of retro-displacement after internal fixation, which is also previously addressed by Melvin et al.¹⁸⁾

Although age and osteoporosis are reportedly key factors of failure, no significant difference was found between our patient groups. BMI of patients was not a significant predictor in our study. Karaeminogullari et al.¹⁹⁾ suggested that favorable prognosis might be expected in surgical treatments within 12 hours from injury, yet we did not find a significant effect of time elapsed from injury to surgery. It has been shown that²⁰⁾ changes at cellular levels begin within 6 hours after injury but necrosis of bone cells progresses slowly over a period of 2 to 3 days; therefore, magnitude of external force and fracture conditions might be more influential in prognosis than time-to-operation.

Given the speculations that the degree of osteoporosis in the elderly patients might significantly affect fixation with screws, we compared the number of cannulated screws and the distance between screws and joint. Unexpectedly, no significant difference between the two groups was found. A number of previous studies have shown that internal fixation with sliding hip screw and plate results in excellent outcomes despite a number of disadvantages such as larger incision, longer hospitalization and blood loss²¹⁻²³⁾. In a similar context, arthroplasty is argued as the primary therapeutic option given the frequency of reoperation, patients' satisfaction and treatment outcomes despite of risk of deteriorated general condition²⁴⁻²⁸⁾. Our study was not designed to compare arthroplasty over internal fixation (with known advantageous such as minimal incision in patients) primarily for the general condition of the elderly patients. It is important to understand the fracture conditions and possible complications to address both merits and demerits of a therapeutic approach for

patients and their caregivers.

Secondary falling accidents were the cause of subtrochanteric fractures through the screw insertion site in two patients. Both patients had four cannulated screws. In order to prevent subtrochanteric fractures through the screw insertion site, relevant principles for insertion of cannulated screws should be followed. More specifically, the three cannulated screws should be inserted in form of an inverted triangle in patients with displacement and the distance between screws should be kept at least 4 mm. The lowest screw should not be inserted below the lesser trochanter and the angle between screws are recommended to be kept less than 10° ²⁰⁾.

Clinically, patients with typical valgus impacted femoral neck fractures may not have pain, could walk with limping and have limited joint movability²⁰⁾. In our study, patients were retrospectively analyzed with simple anterior-posterior projected images without including all presenting clinical symptoms at the time of injury. We could have included patients with serious displacement in sagittal plane, at least in part, which is one of limitations of our study.

CONCLUSION

The failure rate of internal fixation with cannulated screws for valgus impacted femoral neck fractures was not low in the elderly patients. Therefore, it is important to address any potential inherent risk of a respective therapeutic approach for patients and their caregivers. It is also important to accurately assess the fracture through computed tomogram and clinical evaluation.

REFERENCES

1. Waaler Bjørnelv GM, Frihagen F, Madsen JE, Nordsletten L, Aas E. *Hemiarthroplasty compared to internal fixation with percutaneous cannulated screws as treatment of displaced femoral neck fractures in the elderly: cost-utility analysis performed alongside a randomized, controlled trial. Osteoporos Int.* 2012;23:1711-9.
2. Støen RØ, Lofthus CM, Nordsletten L, Madsen JE, Frihagen F. *Randomized trial of hemiarthroplasty versus internal fixation for femoral neck fractures: no differences at 6 years. Clin Orthop Relat Res.* 2014;472:360-7.
3. Gjertsen JE, Vinje T, Engesaeter LB, et al. *Internal screw fixation compared with bipolar hemiarthroplasty for treatment of displaced femoral neck fractures in elderly patients. J Bone Joint Surg Am.* 2010;92:619-28.
4. Leighton RK, Schmidt AH, Collier P, Trask K. *Advances in the treatment of intracapsular hip fractures in the elderly. Injury.* 2007;38 Suppl 3:S24-34.
5. Bhandari M, Devereaux PJ, Tornetta P 3rd, et al. *Operative management of displaced femoral neck fractures in elderly patients. An international survey. J Bone Joint Surg Am.* 2005;87:2122-30.
6. Gjertsen JE, Vinje T, Lie SA, et al. *Patient satisfaction, pain, and quality of life 4 months after displaced femoral neck fractures: a comparison of 663 fractures treated with internal fixation and 906 with bipolar hemiarthroplasty reported to the Norwegian Hip Fracture Register. Acta Orthop.* 2008;79:594-601.
7. Tidermark J, Zethraeus N, Svensson O, Törnkvist H, Ponzer S. *Quality of life related to fracture displacement among elderly patients with femoral neck fractures treated with internal fixation. J Orthop Trauma.* 2002;16:34-8.
8. Chen WC, Yu SW, Tseng IC, Su JY, Tu YK, Chen WJ. *Treatment of undisplaced femoral neck fractures in the elderly. J Trauma.* 2005;58:1035-9.
9. Bjørgul K, Reikerås O. *Outcome of undisplaced and moderately displaced femoral neck fractures. Acta Orthop.* 2007;78:498-504.
10. Clement ND, Green K, Murray N, Duckworth AD, McQueen MM, Court-Brown CM. *Undisplaced intracapsular hip fractures in the elderly: predicting fixation failure and mortality. A prospective study of 162 patients. J Orthop Sci.* 2013;18:578-85.
11. Sikand M, Wenn R, Moran CG. *Mortality following surgery for undisplaced intracapsular hip fractures. Injury.* 2004;35:1015-9.
12. Gjertsen JE, Fevang JM, Matre K, Vinje T, Engesaeter LB. *Clinical outcome after undisplaced femoral neck fractures. Acta Orthop.* 2011;82:268-74.
13. Parker MJ, White A, Boyle A. *Fixation versus hemiarthroplasty for undisplaced intracapsular hip fractures. Injury.* 2008;39:791-5.
14. Chiu FY, Lo WH. *Undisplaced femoral neck fracture in the elderly. Arch Orthop Trauma Surg.* 1996;115:90-3.
15. Conn KS, Parker MJ. *Undisplaced intracapsular hip fractures: results of internal fixation in 375 patients. Clin Orthop Relat Res.* 2004;421:249-54.
16. Lee YH, Chiu FY, Lo WH. *Complications in surgical treatment of undisplaced femoral neck fracture. Zhonghua Yi Xue Za Zhi (Taipei).* 1996;58:24-8.
17. Rogmark C, Flensburg L, Fredin H. *Undisplaced femoral neck fractures--no problems? A consecutive study of 224 patients treated with internal fixation. Injury.* 2009;40:274-6.
18. Melvin JS, Matuszewski PE, Scolaro J, Baldwin K, Mehta S. *The role of computed tomography in the diagnosis and management of femoral neck fractures in the geriatric patient. Orthopedics.* 2011;34:87.
19. Karaeminogullari O, Demirors H, Atabek M, Tuncay C, Tandogan R, Ozalay M. *Avascular necrosis and nonunion after osteosynthesis of femoral neck fractures: effect of fracture displacement and time to surgery. Adv Ther.* 2004;21:335-42.
20. Keating J. Femoral neck fractures. In: *Bucholz BW, Heckman JD, Court-Brown CM, Tornetta P 3rd, ed. Rockwood and Green's Fractures in adults. 7th ed. Philadelphia, PA:*

- Lippincott Williams & Wilkins; 2010. 1562-92.*
21. Wu CC, Chen WJ. *Minimally displaced intra-capsular femoral neck fractures in the elderly--comparison of multiple threaded pins and sliding compression screws surgical techniques. J Orthop Surg (Hong Kong). 2003;11:129-36.*
 22. Lee YS, Chen SH, Tsuang YH, Huang HL, Lo TY, Huang CR. *Internal fixation of undisplaced femoral neck fractures in the elderly: a retrospective comparison of fixation methods. J Trauma. 2008;64:155-62.*
 23. Yih-Shiunn L, Chien-Rae H, Wen-Yun L. *Surgical treatment of undisplaced femoral neck fractures in the elderly. Int Orthop. 2007;31:677-82.*
 24. Gao H, Liu Z, Xing D, Gong M. *Which is the best alternative for displaced femoral neck fractures in the elderly?: A meta-analysis. Clin Orthop Relat Res. 2012;470:1782-91.*
 25. Bhandari M, Devereaux PJ, Swiontkowski MF, et al. *Internal fixation compared with arthroplasty for displaced fractures of the femoral neck. A meta-analysis. J Bone Joint Surg Am. 2003;85-A:1673-81.*
 26. Fisher MA, Matthei JD, Obirieze A, et al. *Open reduction internal fixation versus hemiarthroplasty versus total hip arthroplasty in the elderly: a review of the National Surgical Quality Improvement Program database. J Surg Res. 2013;181:193-8.*
 27. Ravikumar KJ, Marsh G. *Internal fixation versus hemiarthroplasty versus total hip arthroplasty for displaced subcapital fractures of femur--13 year results of a prospective randomised study. Injury. 2000;31:793-7.*
 28. Bjørgul K, Reikerås O. *Hemiarthroplasty in worst cases is better than internal fixation in best cases of displaced femoral neck fractures: a prospective study of 683 patients treated with hemiarthroplasty or internal fixation. Acta Orthop. 2006;77:368-74.*