

## BENIGN INTRACRANIAL HYPERTENSION

BY

PETER BRADSHAW

*From the Department of Neurological Surgery, the Radcliffe Infirmary, Oxford*

A common problem in neurological practice is that of the patient with papilloedema who, on investigation, is found to have neither a brain tumour nor other space-occupying lesion, nor indeed any very well defined cause to explain it. These cases have hitherto been described under the several titles of "benign serous meningitis", "otitic hydrocephalus", and, in the American and Continental literature, as "pseudotumour".

This paper is concerned with an analysis of 42 such cases, admitted to the Nuffield Department of Surgery at the Radcliffe Infirmary, between the years 1938 and 1954 inclusive. Its purpose is to present information about the diagnosis, prognosis, and treatment which may be of value.

The term "otitic hydrocephalus" was introduced by Symonds (1931, 1932) owing to the frequent concurrence of aural suppuration. In such cases the distinction from brain abscess is of the greatest importance, and he stressed certain features which favoured a diagnosis of otitic hydrocephalus: namely, the absence of constitutional symptoms and focal signs, and the presence of a normal cerebrospinal fluid (C.S.F.) under increased pressure. He considered that the condition was related to accretion of blood clot in the lateral sinus and, more recently (1952), has discussed the pathogenesis with regard to possible increased C.S.F. formation, cerebral oedema, and defective absorption of C.S.F.

Both an increase of C.S.F. formation and cerebral oedema might ensue if there were obstruction to the intracranial venous outflow. Indeed, Sugarbaker and Wiley (1951) have shown that, following bilateral jugular ligation in man, a transient intracranial hypertension develops. But, as Symonds pointed out, unless the opposite lateral sinus is rudimentary, a thrombosis upon one side would have to extend to the torcula in order to effect complete obstruction. In such cases compression of the jugular veins would fail to provoke a rise of the spinal C.S.F. pressure, and in most patients with otitic hydrocephalus the manometric observations are normal. However, Nielsen and Courville

(1934) have shown that this mechanism may occasionally be incriminated. In their study of 42 patients who died with a lateral sinus thrombosis they found an extension of the thrombus into the posterior portion of the sagittal sinus in six. A similar observation was made by Bailey and Hass (1937) in a patient who died with otitic hydrocephalus. In addition, Symonds (1952) described a young woman with otitic hydrocephalus who expired after a lumbar puncture. At necropsy she was found to have a thrombosis of a lateral sinus which extended upwards into the posterior end of the superior longitudinal sinus and downwards into the jugular vein as far as its junction with the common facial vein.

The presence of cerebral oedema has at times been suggested by ventriculography. Davidoff and Dyke (1936) attempted a ventriculogram on each of 12 patients with "benign serous meningitis"; in six the ventricles were difficult to locate with the brain needle and failed to fill with air, in the remainder the ventricles were smaller than normal. Dott (quoted by Symonds, 1952) has also remarked on the small size of the cerebral ventricles in the acute stage of the condition.

The experimental observations of Weed (1914) have shown that when the arachnoid villi in animals are blocked with lamp black hydrocephalus ensues. This led Symonds (1932) to suggest that a mural thrombosis of the sagittal sinus, arising from the lateral sinus, might interfere with C.S.F. absorption by the arachnoid villi. This mechanism would explain the syndrome of otitic hydrocephalus, and some support for this theory is gained by the results of sinography. By this means, Frenckner (1937) and Ellis (1937) were able to demonstrate occlusion of the sagittal sinus during life.

McKenzie (1948) and others have criticized the label "otitic" since infections of the second branchial cleft are not exclusive in the production of the syndrome. McAlpine (1937) reported the association with non-suppurative inflammations of the nasopharynx, Symonds (1937) with puerperal thrombosis of the leg veins, peritonsillar abscess,

thrombophlebitis migrans, and (1940) with frontal sinusitis. Garcin and Pestel (1949), in a detailed review of the literature, have incriminated trauma, cachexia, and anaemia.

Symonds (1937) has reminded us that the pterygoid venous plexus, which drains the upper respiratory tract, including the tonsillar bed, is a tributary of the jugular vein. Garcin and Pestel (1949) have shown that this plexus also communicates with the cavernous sinus. Symonds suggested that a thrombosis of veins in the locality of the tonsils might extend to involve first the internal jugular vein and from thence into the intracranial venous sinuses and thereby explain the development of papilloedema in patients with tonsillitis. A somewhat similar accretion of clot may follow thrombosis of the jugular vein related either to trauma or to cervical lymphadenitis (Garcin and Pestel, 1949). Pennybacker (1943) described a patient with a thymic tumour who developed papilloedema. At necropsy the tumour was found to have compressed the left innominate vein and, from this site, a thrombosis extended up the jugular vein into the major intracranial venous sinuses.

The syndrome of cortical thrombophlebitis was first described by Martin and Sheehan (1941) in women during the puerperium and patients with gastro-intestinal infections. Unlike otitic hydrocephalus, the condition is characterized by constitutional symptoms, focal signs referable to one or both cerebral hemispheres, and fits. In addition, Martin and Sheehan found in many that the C.S.F. was bloodstained or contained an excess of cells or protein. They considered that the condition arose as the result of embolic spread, via the spinal venous plexus, from a local thrombosis of pelvic veins. In support of this theory they quoted the observations of Baston who injected radio-opaque material into the pelvic veins. After compression of the abdomen he was able to demonstrate the contrast medium within the cranium.

The prognosis is less favourable than in otitic hydrocephalus and a number of cases came to necropsy. Martin and Sheehan reported the presence of thrombosis of cortical veins, cerebral softening and oedema, and the finding of punctate haemorrhages within the brain and meninges. An interesting but unusual cause of death, noted by Garcin and Pestel (1949), was thrombosis of the great vein of Galen with resulting softening and infarction of the basal ganglia. These authors were loth to accept the theory of venous embolism. They have remarked that though a few of the puerperal cases gave a history of complications, such as "white leg" or haemorrhages, the majority had

normal pregnancies. Kendall (1948) has suggested that the increased blood fibrinogen or number of circulating platelets, known to occur in late pregnancy, or the presence of new and "sticky" red cells recently withdrawn from the bone marrow in response to haemorrhage, were factors which accounted for the puerperal incidence.

The close relationship between otitic hydrocephalus and cortical thrombophlebitis is emphasized by Symonds (1937) and Garcin and Pestel (1949) who have described the concurrence of both conditions. Indeed this is not remarkable, since in the first there is a high incidence of thrombosis of venous sinuses whilst in the second the veins are involved. Barnett and Hyland (1953) have shown that factors which predispose to extracranial venous thrombosis are also associated with thrombosis of veins within the skull. These include cardiac disease, cachexia, post-operative and post-traumatic states, hyperpyrexia, haemorrhage, and certain rare blood dyscrasias.

In the treatment of otitic hydrocephalus, with or without involvement of cortical veins, most authorities, including Symonds, Garland and Seed (1933), and McKenzie (1948), have recommended repeated spinal puncture to avert the development of consecutive optic atrophy. Others, including Davidoff and Dyke (1936), have employed yet more energetic methods and supplement this régime with dehydration therapy and operative decompression.

**Clinical Material and Presentation of Cases**

It was found that the 42 patients fell into five clinical groups by reason of an associated pathology as follows: (1) Infections of the second branchial cleft and respiratory tract (26 cases, 61%); (2) extracranial venous thrombosis (four cases); (3) obesity (six cases); (4) post-traumatic (two cases); (5) undetermined (four cases).

The age and sex distribution of the several groups is shown in Table I.

TABLE I  
AGE AND SEX DISTRIBUTION

Age Group (years)	Group 1		Group 2		Group 3		Group 4		Group 5	
	M	F	M	F	M	F	M	F	M	F
2½-10	6	7	0	0	0	0	1	0	0	0
11-20	4	3	0	0	1	0	0	0	1	0
21-30	0	4	0	1	0	2	0	0	0	1
31-40	0	2	0	1	0	2	1	0	1	1
41-52	0	0	1	1	0	1	0	0	0	0
Totals	10	16	1	3	1	5	2	0	2	2

**Infections of Second Branchial Cleft and Respiratory Tract.**—The majority of the patients (61%) had conditions clearly associated with infections of

the second branchial cleft or respiratory tract. Twenty-one patients (50%) had aural suppuration and these were classical examples of otitic hydrocephalus; they provided much of the information which was applied later to the other groups. In brief, it is generally the story of a child who has had a recent aural infection, develops a squint due to paralysis of one or both external rectus muscles, and complains of headache. This leads to examination of the optic fundi and to the discovery of papilloedema. In many cases there is no headache.

*Case 1 (No. 79323/47).*—Ten weeks before admission to this hospital this child, a boy aged 5, had a left Schwartz mastoidectomy for an acute mastoiditis. After a fortnight the wound was healed and he returned home. At this time his parents noticed that he had a squint, though he did not complain of headache or any other symptoms. He was admitted to the Radcliffe Infirmary because his doctor had detected papilloedema and rightly suspected that he might have a brain abscess.

On examination he was an alert and intelligent boy with a head circumference of 21 in. (normal 19.8 in.), which gave a cracked-pot note to percussion. There was bilateral papilloedema of 2 dioptres, and the visual acuities were preserved. The left external rectus muscle was paralysed, but there were no other abnormal physical signs; in particular, there was no hemianopia.

Radiographs of the skull showed increased convolutional markings and moderate suture diastasis. The lumbar C.S.F. pressure was 220 mm. of water, the spinal manometric observations were normal, and the fluid contained 1 lymphocyte per c. mm. and 15 mg. of protein per 100 ml. A ventriculogram showed very slight dilatation of otherwise normal ventricles.

All the evidence pointed to this being otitic hydrocephalus and he was discharged from hospital without treatment after eight days. He remained in good health; the squint cleared up in two months and the appearances of the optic fundi were normal within eight months.

This case illustrates the remarkably symptomless course of the malady which was detected only because the child developed a squint.

Table II shows the nature of the infection giving rise to intracranial hypertension. Of the nine

TABLE II  
PREDISPOSING INFECTION

Nature of Infection	No. of Cases
Post-mastoidectomy .. .. .	9
Acute otitis media .. .. .	11
Chronic otitis media .. .. .	1
Acute follicular tonsillitis .. .. .	2
Frontal sinusitis .. .. .	2
Pulmonary abscess .. .. .	1

patients who had a mastoidectomy, the lateral sinus was reported to be thrombosed in two and normal in seven. The time interval between

operation and the detection of papilloedema was from one to 49 days, with an average of 19 days. Three of the patients who had otitis media had sustained a mild head injury which was followed by an exacerbation of the pre-existing aural disease. All the evidence suggested that the raised intracranial pressure which developed arose in connexion with otitis rather than with the injury, though the two cases in Group 4 seemed to be purely traumatic in origin.

The following remarkable case shows that very occasionally the pathological process giving rise to otitic hydrocephalus is not confined to intracranial structures.

*Case 2 (No. 118074/50).*—Since the age of 5 this girl, now aged 15, had suffered from a recurrent left-sided otorrhoea and, at the age of 8, the tonsils and adenoids were removed. Five weeks before admission to this hospital she developed an acute left mastoiditis for which an endaural mastoidectomy was done. At operation the left lateral sinus was reported to have been normal. Post-operative recovery was uneventful until the fourth day when she vomited and was found to have a stiff neck, papilloedema, and a pyrexia of 101° F. She was transferred to the Radcliffe Infirmary on February 22, 1950.

On examination she was a thin, pale, and ill-looking girl with a fever of 100° F. There was marked neck stiffness and Kernig's sign was positive. The blind spots measured some 30 in. in diameter at 2 m. and the visual acuity was J2, 6/18 on the right and J2, 6/9 on the left. There was bilateral papilloedema of 5 to 6 dioptres and punctate retinal haemorrhages. Ocular movements were full and, apart from the deep tendon reflexes which were difficult to obtain, there were no other abnormal physical signs.

Radiographs of the chest and skull were normal. The lumbar C.S.F. pressure was 310 mm. of water, the spinal manometric observations were normal, and the fluid contained 0 cells and 16 mg. of protein per 100 ml. A ventriculogram was normal.

For the next four months she continued to run an intermittent pyrexia of up to 101° F. This was at first attributed to persistence of the mastoiditis and accordingly the left mastoid cavity was re-explored but no abnormality was found. The erythrocyte sedimentation rate (E.S.R.) was above 100 mm. per hour, a white cell count was 13,000 per c. mm., with 73% neutrophils, 14% lymphocytes, 7% eosinophils, and 6% monocytes. The Wassermann reaction and Paul Bunnell test were negative in the blood and C.S.F., agglutinations for *Brucella* were negative, and three blood cultures sterile.

On March 12 she complained of transient attacks of amblyopia. The papilloedema now measured 6 dioptres, the diameters of the blind spots had increased to 40 in. at 2 m., and the visual acuity was J4, 6/18 on the right and J1, 6/9 on the left. The lumbar C.S.F. pressure was 240 mm. of water and the fluid contained 2 polymorphs

per c. mm. and 30 mg. of protein per 100 ml. The haemoglobin was found to be only 43% but this was raised to 85% by transfusion of packed red cells.

In view of the appearances of the optic fundi and the state of vision, it was thought best to do a posterior fossa decompression. On March 18 this was carried out and at operation the dura was tense but there were no other abnormal findings and recovery was uneventful until the second day.

On March 20 she was found to have a moderately severe flaccid weakness of both upper limbs most marked upon the right side. The deep tendon reflexes were absent in the upper limbs, brisk and equal in the lower limbs, and the plantar responses were extensor. No sensory loss was detected at this time, but during the course of the day she developed an almost complete flaccid quadriplegia with total areflexia, loss of vibration and postural sensibility in the fingers and toes, and cutaneous impairment for all modalities of sensation below the level of the third dorsal segment upon both sides. She was incontinent of urine and faeces. A lumbar puncture revealed xanthochromic fluid under a pressure of 150 mm. of water, containing 28 cells per c. mm. (10 polymorphs and 18 lymphocytes), 85 mg. of protein per 100 ml., and a normal sugar. Culture of the C.S.F. was sterile.

By March 22 there was some improvement in power and the sensory level had receded to the level of the tenth dorsal segment. In view of the bizarre clinical picture it was thought that the likely diagnoses included bacterial endocarditis and polyarteritis nodosa, but analysis of the urine was negative and three blood cultures were sterile. The improvement was maintained and on June 22 she was able to move all the limbs against resistance though power was still less than normal. During the two months that had elapsed she had developed global wasting of both hands, but the tendon reflexes had returned and the plantar reflexes were flexor. No cutaneous sensory loss was demonstrable, though the threshold for joint position sense was greater than normal in the fingers and toes upon the right side. Partial sphincter control was effected and, for the first time, the temperature was normal.

By August 20 the papilloedema had subsided, though there was slight pallor of the right optic disc. The visual acuity was J2, 6/12 on the right, and J1, 6/6 on the left. There were no other abnormal physical signs. She was sent to a convalescent home where she gained 2 stones in weight. Since that time she has remained well and the visual acuities have not altered over the last three years.

This patient was considered to have had otitic hydrocephalus. She was given a posterior fossa decompression to preserve vision and, two days later developed a flaccid quadriplegia. It was thought that this complication was due to an extension of intracranial thrombophlebitis to involve veins of the spinal cord.

In five patients there was no evidence of aural suppuration, though there was infection of the

respiratory tract. Two patients gave a history of a recent frontal sinusitis which was confirmed by radiological examination. In one of these the sinus infection was a complication of measles and in the other of whooping cough. A further two patients had suffered from a recent attack of acute follicular tonsillitis without abscess formation.

Another unusual case arose in connexion with a lung abscess.

*Case 3 (No. 19394/41).*—Three months before admission to this hospital this patient, a woman aged 33, complained of a generalized headache, coughed up a large quantity of offensive green sputum, and vomited. She was admitted to another hospital where she was found to have a pulmonary abscess with a fluid level in the dorsal segment of the left lower lobe. This was treated with postural drainage and sulphonamides and her symptoms resolved within 14 days. Two months after the onset her headache returned, she complained of diplopia, and began to vomit. She was found to have bilateral papilloedema and, because of the known recent chest infection, the question of a metastatic brain abscess arose.

On examination she was a healthy looking woman of average development and intelligence. The margins of the optic discs were blurred, though there was no measurable swelling. Ocular movements were full and there were no other abnormal signs.

Radiographs of the chest and skull were normal. The lumbar C.S.F. pressure was 180 mm. of water and the fluid contained 0 cells and 35 mg. of protein per 100 ml. A cisternal air encephalogram was normal.

It was considered that her condition arose from thrombosis of an intracranial venous sinus. She received no treatment and the appearances of the optic fundi were normal within six weeks.

**Extracranial Venous Thrombosis.**—Four patients were known to have had thrombosis of extracranial veins before the onset of intracranial hypertension. In the first two the site of the thrombosis was remote from the jugular system.

*Case 4 (No. 146716/51).*—Nine months before admission, during the fifth month of her second pregnancy, this woman, aged 20, developed swelling of both lower limbs which subsided within three months. Seven months after the onset, three months after parturition, she complained of a slight headache and retired to bed. She vomited twice but, a day later, returned to her household duties. She remained in good health, though a few days afterwards noticed double vision.

On examination she was an obese woman of 5 ft. 3½ in. in height, weighing 12 stones 1 lb. There was bilateral papilloedema of 4 dioptries with a few small retinal haemorrhages. Both external rectus muscles were paralysed and there was a fine nystagmus on lateral gaze to the left. There were no other abnormal physical findings.

Radiographs of the chest and skull were normal. The lumbar C.S.F. pressure was 450 mm. of water, the spinal manometric observations were normal, and the fluid contained 0 cells and 35 mg. of protein per 100 ml. A ventriculogram was normal.

After a further three lumbar punctures she returned home; the squint cleared up within two months and the appearances of the optic fundi were normal at the end of eight months.

It was considered that this patient had developed papilloedema as the result of a venous sinus thrombosis during the puerperium. The association with thrombophlebitis of the lower limbs was presumed from the history. In the following patient there was more definite evidence of extracranial thrombophlebitis.

*Case 5 (No. 112772/50).*—Fourteen months before admission to this hospital this patient, a man aged 41, had a laparotomy on account of swelling of both lower limbs and was found to have a thrombosis of both internal iliac and common femoral veins. Ten months after the operation he developed a moderately severe bifrontal headache. This subsided during the subsequent seven days but, after an interval of a week, headache returned and he began to vomit.

On examination he was an alert man of average development and intelligence, with massive oedema of both lower limbs. There was bilateral papilloedema of 3 to 4 dioptries and punctate retinal haemorrhages. No other abnormal physical signs were detected.

Radiographs of the chest and skull were normal. The lumbar C.S.F. pressure was 300 mm. of water, the spinal manometric observations were normal, and the fluid contained 1 lymphocyte per c. mm. and 80 mg. of protein per 100 ml. A ventriculogram was normal.

A second lumbar puncture was done a week later and the C.S.F. protein was still elevated. He returned home without treatment and remained in good health. The appearances of the optic fundi were normal within one year.

The following two patients are examples of a different kind in whom the internal jugular system was presumed to have been occluded.

*Case 6 (No. 131941/50).*—This woman, aged 30, had had three months previously an operation for the removal of some tuberculous lymphatic glands from behind the angle of the jaw upon the left side. The following day she complained of headache and double vision and was found to have tenderness on palpation over the line of the left internal jugular vein, and local swelling of the neck. Thereafter her vision deteriorated and she was found to have papilloedema.

On examination she was a listless woman, of modest intelligence, who feared that she had incurable tuberculosis. A systolic bruit was heard over the whole cranium and there was bilateral papilloedema of 4 dioptries with punctate retinal haemorrhages. The visual acuities were recorded as J16 on the right, and J14 on the left, but the

hysterical left-sided weakness and hemianaesthesia. A left lower facial weakness was attributed to the operation upon her neck. There were no other abnormal physical signs.

Radiographs of the chest and skull were normal. The lumbar C.S.F. pressure was 300 mm. of water, the spinal manometric observations were normal, and the fluid contained 0 cells and 45 mg. of protein per 100 ml. To exclude a post-operative arteriovenous communication, bilateral carotid arteriograms were done and these were normal.

After a second lumbar puncture she returned home and, though the visual acuities improved to J4 on either side during the next five months, the papilloedema did not subside. She was readmitted and at five lumbar punctures on successive days the C.S.F. pressure was found to be above 300 mm. of water. To avert possible consecutive optic atrophy a subtemporal decompression was done. At operation the dura was so tense that a ventricular tap was contemplated before opening it, but on incising the dura the arachnoid was accidentally nicked and C.S.F. gushed out. The tension on the dura was immediately relieved and it was opened widely. The sub-arachnoid space was abnormally capacious over the whole field; the cerebral convolutions and cortical veins appeared to be normal. Post-operative recovery was uneventful. Vision was normal within four months, though it was two years before the appearances of the optic fundi were normal. Throughout this period the decompression was not "used", i.e., it never bulged or became tense.

This patient was presumed to have had thrombosis of the left internal jugular vein following an operation upon the neck. The intracranial hypertension was thought to arise as the result of retrograde extension of the clot into the sagittal sinus. An operative decompression was done to preserve vision.

The second patient in whom occlusion of the internal jugular system seemed to have occurred follows.

*Case 7 (No. 66223/46).*—For the past nine months this woman, aged 32, had been subject to morning headaches which lasted for several hours and were accompanied by vomiting and transient attacks of amblyopia of one or two minutes' duration. During this time her vision deteriorated, and she experienced vertigo, without tinnitus or deafness, which came on at night while she lay in bed. One month previously she had been admitted to another hospital where a ventriculogram was done. It was reported that the findings suggested a left frontal tumour, but after the air studies all her symptoms resolved and she returned home. She was admitted to the Radcliffe Infirmary on September 19, 1939.

On examination she was a healthy looking woman with very markedly distended veins over the chest wall and root of the neck upon both sides (Fig. 1). There was bilateral anosmia\* and bilateral papilloedema of 5 to 6

\*See footnote on page 33

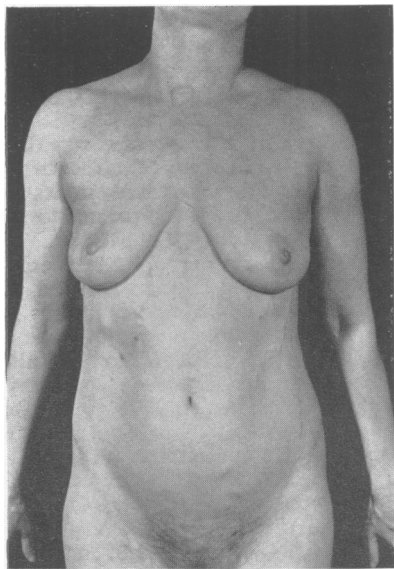


FIG. 1.—Dilated trunk veins in Case 7, resulting from superior vena cava thrombosis.

dioptries, with punctate retinal haemorrhages. The visual acuity was J6, 6/9 on the right, and J1, 6/9 on the left. No other abnormal physical signs were detected.

The findings suggested the possibility of an olfactory groove meningioma, but radiographs of the skull were normal. The lumbar C.S.F. pressure was 460 mm. of water and there was no rise when either or both internal jugular veins were compressed. The C.S.F. contained 0 cells and 20 mg. of protein per 100 ml. A ventriculogram was normal.

She returned home, but the papilloedema did not subside, and she was readmitted on April 19, 1940. The following day a subtemporal decompression was done. At operation the dura was very tense and, when this was incised, the membrane of a small chronic subdural haematoma was revealed. The membrane was no more than 2 to 3 mm. in thickness; it was considered that this bore little relation to her present condition and probably arose as a complication of the first ventriculogram. After operation there was a temporary improvement of vision, but this was not sustained. Radiographs of the chest failed to show any evidence of a mediastinal neoplasm, and it was felt that her condition was due to thrombosis of the superior vena cava.

During the following three months she developed bilateral pleural effusions, ascites, hepatic enlargement, oedema of the lower extremities, and enormous distension of the decompression. These were treated by repeated aspirations and lumbar puncture, with some effect. In 1946 her visual acuity was J14, 6/18 on the left, and perception of light only on the right. She started to have

\* A similar case is under observation at present: a healthy young man, with bilateral anosmia, intense papilloedema, slight mental changes, all suggesting the possibility of an olfactory groove meningioma. Bilateral carotid angiograms and a ventriculogram are quite normal and are presumed to exclude the presence of a tumour.

major convulsions, but these were partially controlled with anticonvulsants. She was last seen in 1951, when she was technically blind.

**Cases Associated with Obesity.**—It is not uncommon to find a moderate elevation of the lumbar C.S.F. pressure in an obese but otherwise healthy person. This is due to the pressure exerted by the thighs and abdominal fat upon the lumbar veins when the patient is in the lateral position usually employed for spinal puncture. The presence of papilloedema, however, cannot be so lightly dismissed and, in this series, six patients gave a history of a rapid increase in weight and were found to be obese. In four of these there was no other cause to account for the intracranial hypertension, though of the other two, one had mitral stenosis and one gave a history of a miscarriage eight months before admission to hospital. It will also be remembered that Case 4 (see p. 31) was obese, although her clinical state seemed more probably due to postpartum venous thrombosis.

*Case 8 (No. 44996/45).*—This woman, aged 36, had gained 3½ stones in weight in the past two years. Eighteen months before admission her menses became irregular, lasting for five days and following a cycle of from two to eight weeks. One year before admission she started to have mild morning headaches and six months later noticed progressive failure of vision.

On examination she was an obese woman of 5 ft. 4 in. in height weighing 13 stones 10 lb. There was bilateral papilloedema of 2 dioptries. The visual acuities were preserved and, apart from a fine horizontal nystagmus on lateral gaze, there were no other abnormal findings.

Radiographs of the chest and skull were normal. The lumbar C.S.F. pressure was 280 mm. of water, the spinal manometric observations were normal, and the fluid contained 0 cells and 20 mg. of protein per 100 ml. A ventriculogram was normal.

She received no treatment and became symptom free after one week; the appearances of the optic fundi were normal within one month.

Two similar patients included B. W. (No. 72041/47), a woman aged 25 who was 5 ft. 6 in. in height and weighed 14 stones; and V. D. (No. 6442/41), a woman aged 42, who was 5 ft. 6½ in. in height and weighed 15 stones 7 lb. Both of them gave a history of a recent rapid gain in weight in the two years before admission and were found to have three dioptries of papilloedema. There were no other abnormal findings and analysis of the lumbar C.S.F., radiographs of the chest and skull, and a ventriculogram were normal.

There was only one male in this group, a boy who appeared to be suffering from a mild hypothalamic disorder.

*Case 9 (No. 134418/52).*—This boy, aged 12, had been normal up to the age of 11 when he gained 2 stones 5 lb. in weight within nine months and became apathetic. He slept late if not awakened, but there was no diurnal

sleep and his fluid balance was normal. One year before admission he began to complain of throbbing headaches which were at times sufficiently severe to keep him from school. For the past three months he had been subject to episodes of vertigo, without deafness or tinnitus, which lasted for up to two hours at a time.

On examination he was an apathetic fat boy of 5 ft. 4 in. in height who weighed 11 stones 5 lb. The external genitalia were of average development for his age, the pubic hair was sparse, and the fingers tapering. There was bilateral papilloedema of 1 to 2 dioptres and the ankle jerks were absent. No other abnormalities were detected.

Radiographs of the chest and skull were normal. The lumbar C.S.F. pressure was 290 mm. of water, the spinal manometric observations were normal, and the fluid contained 0 cells and 25 mg. of protein per 100 ml. A lumbar air encephalogram was normal; in particular, the regions of the sella and the third ventricle were clearly visualized and were not remarkable.

After a second spinal puncture he returned home and when seen three months later seemed much brighter and the appearances of the optic fundi were normal. Three years later he was head boy of his school, played active games and was in every respect normal. He weighed 14 stones 2 lb. We have no explanation for the spontaneous recovery from both an endocrine condition and intracranial hypertension.

Of the two patients that remain in this group, one gave a history of a miscarriage, the other had hypertension and mitral stenosis. Barnett and Hyland (1953) have shown that each of these conditions may be associated with cortical thrombophlebitis, so that it is not possible to relate the intracranial hypertension to obesity alone. However, the clinical picture most closely resembled that of sinus thrombosis as distinct from cortical thrombophlebitis.

*Case 10 (No. 152302/52).*—After the birth of her first child, two and a half years previously, this woman, aged 22, had gained 3 stones in weight. Eight months before admission she had a miscarriage during the tenth month of pregnancy. A week later she complained of headache, vomited, and developed diplopia. While awaiting admission her symptoms subsided spontaneously.

On examination she was an obese woman of 5 ft. 6 in. in height who weighed 13 stones. There was bilateral papilloedema of 3 dioptres on the left and 5 dioptres on the right. No other abnormality was detected.

Radiographs of the skull showed slight decalcification of the posterior clinoid processes and of the dorsum sellae. The lumbar C.S.F. pressure was 400 mm. of water, the spinal manometric observations were normal, and the fluid contained 0 cells and 35 mg. of protein per 100 ml. A ventriculogram was normal.

She was given no treatment and the appearances of the optic fundi were normal within 16 months.

*Case 11 (No. 66066/46).*—This patient, a woman aged 39, had had rheumatic fever at the ages of 20 and

23, and 11 weeks before admission had a third attack characterized by a pyrexia of up to 100° F., flitting large joint pains, and profuse perspiration. After eight weeks in bed she complained of a sensation of pressure behind the eyes and deterioration of vision.

On examination she was an obese woman of 5 ft. 2 in. in height who weighed 13 stones 3 lb. There was bilateral papilloedema of 5 to 6 dioptres with retinal exudates and haemorrhages. Visual acuity was reduced to perception of light on the right and J14, 6/12 on the left. The blood pressure was 160/110 mm. Hg and at the cardiac apex there was a mitral diastolic murmur. The pulse was regular and there were no other abnormal physical signs.

A radiograph of the chest showed evidence of mitral stenosis. Radiographs of the skull revealed slight decalcification of the dorsum sellae and of the posterior clinoid processes. The lumbar C.S.F. pressure was 400 mm. of water, the spinal manometric observations were normal, and the fluid contained 0 cells and 40 mg. of protein per 100 ml. A ventriculogram was normal.

Four lumbar punctures were done and after four months the papilloedema measured 2 dioptres. The visual acuity was J6, 6/12 on the right and perception of light on the left. Two years later the swelling had subsided and the vision was unaltered.

**Post-traumatic Cases.**—Two patients developed papilloedema after a closed head injury.

*Case 12 (No. 156126/52).*—Ten days before admission this boy, aged 6, sustained a mild closed head injury with a post-traumatic amnesia of 10 minutes. The following morning he complained of severe headache and vomited.

On examination he was a quiet little boy with a bony depression over the left parietal region of the vault. There was bilateral papilloedema of 2 to 3 dioptres with a few small retinal haemorrhages. No other abnormality was detected.

Radiographs of the skull showed a depressed fracture, 3 cm. in diameter and 2 cm. in depth, in the left parietal region bordering on the midline. This was elevated at operation and the dura was found to be intact. Within two weeks the appearances of the optic fundi were normal and he was well. The site of the depressed fracture suggested that the sagittal sinus had been damaged.

In the second case a mural thrombosis of the superior longitudinal sinus was inferred from the results of sinography.

*Case 13 (No. 134418/50).*—A man, aged 38, eight months before admission sustained a closed head injury without loss of consciousness. Seven months later he complained of occasional left-sided headaches and double vision.

On examination there was a large vitreous haemorrhage in the left eye and bilateral papilloedema of 1 to 2 dioptres. The visual acuity was J4, 6/18 on the left, and J4, 6/9 on the right. Both external rectus muscles were paralysed. No other abnormal physical signs were detected.

Radiographs of the skull showed slight decalcification of the dorsum sellae. The lumbar C.S.F. pressure was 180 mm. of water and the fluid contained 0 cells and 20 mg. of protein per 100 ml. A lumbar air encephalogram was normal. Through a frontal burr-hole, 10 ml. of "thorotrast" was injected into the sagittal sinus. The lumen of the sagittal sinus seemed to be attenuated and the walls irregular: the lateral sinus was normal.

He returned home without treatment. The appearances of the optic fundi and the left vitreous were normal within one year when the visual acuity was J1, 6/6 on either side.

**Cases of Undetermined Origin.**—There remain four patients in whom no obvious cause was found to account for their papilloedema. Two of these were women aged 18 and 20 and the clinical features closely resembled those which have been described. The third, Case 15, is reported later (q.v.), whilst the fourth follows.

*Case 14 (No. 16904/43).*—This patient, a woman aged 20, was a dwarf who was mentally backward. A year before admission she had been investigated for anaemia. In short, this was microcytic and hypochromic in type and had proved refractory to treatment with oral iron and intramuscular liver. Both a glucose tolerance test and a fat balance suggested impairment of intestinal absorption and it was considered likely that absorption of haematinic factors was also defective. Two months before admission she complained of headache and double vision.

On examination she was a well proportioned dwarf of 4 ft. 9½ in. in height who weighed 5 stones 5½ lb. and was mentally backward. The face was pigmented, the genitalia infantile, and pubic hair sparse. Veins over the forehead were prominent and there was bilateral papilloedema of 5 to 6 dioptres. Both external rectus muscles were paralysed and the deep tendon reflexes difficult to obtain. The blood pressure was 100/70 mm. Hg and no other abnormal physical signs were detected.

Radiographs of the skull revealed a very small pituitary fossa. The lumbar C.S.F. pressure was 210 mm. of water and the fluid contained 2 lymphocytes per c. mm. and 10 mg. of protein per 100 ml. A ventriculogram showed slight dilatation of otherwise normal ventricles.

She received no treatment for the intracranial hypertension and the appearances of the optic fundi were normal after two weeks. It was considered that the papilloedema arose from a sinus thrombosis and that this may have been associated with the anaemia.

**Symptoms and Physical Signs**

The incidence of the symptoms and physical signs is shown in Tables III and IV.

A striking feature was the rarity of constitutional symptoms. Only five patients complained of malaise, and this was related more to the predisposing infection than to the raised intracranial pressure. Only one patient (Case 3) was really ill and this was a most unusual case.

TABLE III  
SYMPTOMS

Symptom	Total	Group 1	Groups 2-5
Constitutional .. .. .	5	4	1
Headache .. .. .	30	16	14
Vomiting .. .. .	17	11	6
Visual deterioration .. .. .	11	3	8
Squint and/or diplopia .. .. .	26	21	5
Fits .. .. .	5	3	2
Total number of cases .. .. .	42	26	16

TABLE IV  
PHYSICAL SIGNS

Physical Sign	Total	Group 1	Groups 2-5
Enlargement of head circumference .. .. .	11	10	1
Papilloedema of > 3 dioptres .. .. .	13	7	6
Papilloedema of < 3 dioptres .. .. .	29	18	11
Visual acuity of J2, 6/9-J6, 6/12 .. .. .	9	4	5
Vision worse than J6, 6/12 .. .. .	6	2	4
External rectus weakness Total .. .. .	26	22	4
Unilateral .. .. .	8	8	0
Bilateral .. .. .	18	14	4
Sluggish or absent tendon jerks .. .. .	11	6	5
Nystagmus .. .. .	9	5	4
Slight facial weakness .. .. .	4	3	1
Monoplegia .. .. .	1	1	0
Hemiplegia .. .. .	1	1	0
Bruit audible over the cranium .. .. .	2	1	1

**Headache.**—Headache was seldom a troublesome symptom and this was especially true of the otitic group. It was particularly uncommon in children and, of the 15 patients under the age of 12, only five admitted to a mild headache.

Though headache is so slight in these patients there is usually abundant evidence of raised intracranial pressure. There is papilloedema, elevation of the spinal fluid pressure, and separation of the cranial sutures sometimes evident on clinical examination by a cracked-pot note to percussion or by an increase in the head circumference. Radiologically there may be suture diastasis or convolutional thinning of the vault. Eleven of the 15 children showed these changes in the skull radiographs. Admittedly children are loth to complain, but when the same clinical and radiological findings are due to, say, a cerebellar tumour, headache is a common symptom and may be the predominant one. Nor is the absence of headache to be explained on the basis of a time relationship, because the increase in pressure may develop as slowly or as quickly in cases of brain abscess or tumour. In these 11 children the duration of symptoms before examination was from 10 days to six months, with an average of 12 weeks.

Possible factors which may be relevant are that there is rarely any great ventricular dilatation (as in obstructive hydrocephalus due to a cerebellar



tumour) nor is there any lateral shift or distortion of the cranial contents.

In the whole series only one patient described his headache as violent.

*Case 15 (No. 189205/54).*—A man, aged 33, two years previously began to complain of mild bifrontal headaches of a few minutes' duration. Five weeks before admission he started to have attacks of sudden and very severe headache associated with rotatory vertigo and amblyopia. These episodes lasted for up to five minutes and recurred five or six times a day. Between the attacks he enjoyed good health.

On examination he was a healthy looking man without evidence of psychoneurosis. There was bilateral papilloedema of 5 to 6 dioptres and the visual acuities were J4, 6/12. Apart from a slight left lower facial weakness, no other abnormal signs were detected.

Radiographs of the skull showed slight thinning of the posterior clinoid processes and decalcification of the dorsum sellae. A right carotid arteriogram was normal. It was considered that the history and absence of focal signs suggested intermittent ventricular obstruction, as from a colloid cyst of the third ventricle, and a ventriculogram was done. The intraventricular pressure was 650 mm. of water and the fluid contained 90 red cells per c. mm., 0 white cells, and 35 mg. of protein per 100 ml. Air studies were normal.

In the light of these findings it was thought that his condition was closely related to otitic hydrocephalus and, because of the attacks of amblyopia, he was given a subtemporal decompression. At operation there were no abnormal findings. During the next few weeks he became symptom free and visual acuity improved to J2, 6/6 on either side. Eight months later there were still 2 dioptres of papilloedema though he remained well.

**Vomiting.**—This was a fairly frequent occurrence, especially in children, but it was rarely so insistent as in patients with intracranial hypertension from brain tumour. When present it was usually a feature of the associated acute infection. None of these patients exhibited lethargy or sleepiness so commonly seen in raised intracranial pressure from other causes. Indeed, their alacrity and general well being in the presence of marked papilloedema was often characteristic and came to be recognized as being of diagnostic importance.

**State of Vision.**—As papilloedema was the essential feature of all these cases, and the one which led to admission to hospital, our interest has been centered on the state of vision. In most instances the patient had no symptom referable to the papilloedema, although a few with high degrees of swelling experienced transient attacks of amblyopia. Gross impairment of vision in the acute stage or later as the result of consecutive optic atrophy was rare (Table IV), and of the whole series only two patients became blind. One of these (Case 7) has been described; the other follows.

*Case 16 (No. 182095/53).*—A boy, aged 5, four weeks before admission developed a squint and, after one week, was taken to see an ophthalmologist who reported that the visual acuities and appearances of the optic fundi were normal. After a few days he was found to have a non-suppurative left otitis media but this cleared up within three days. A week before admission he began to walk into the furniture and, for the first time, it was suspected that his vision was defective. He remained otherwise in excellent health.

On examination the head circumference was  $22\frac{1}{2}$  in. and there was a cracked-pot note to percussion. Veins over the forehead were prominent and a systolic bruit was heard over the whole cranium. There was bilateral papilloedema of 5 to 6 dioptres with retinal haemorrhages and macular fans of exudate. The left eye was blind and acuity on the right was reduced to perception of light. Both pupils were inactive to light and there were bilateral sixth nerve palsies. The deep tendon reflexes were all difficult to obtain but there were no other abnormal physical signs.

Radiographs of the skull showed moderate suture diastasis and increased convolutional markings. The lumbar C.S.F. pressure was 470 mm. of water, the manometric observations were normal, and the fluid contained 0 cells and 40 mg. of protein per 100 ml. A ventriculogram was attempted, but the ventricles were difficult to locate and failed to fill with air. In order to try to save vision a subtemporal decompression was done. At operation, the scalp veins were distended and black. The dura was tense and, when the arachnoid was incised, C.S.F. gushed out from a capacious subarachnoid space. The cerebral convolutions appeared to be normal but the cortical veins were widened, tortuous, and filled with dark blood. Serial lumbar punctures showed that the pressure was normal within one week. A lumbar air encephalogram four weeks later showed slight dilatation of otherwise normal ventricles. He returned home blind but in good health. He did not "use" the decompression and four months later had bilateral consecutive optic atrophy.

The rapid development of papilloedema and visual failure suggested obstruction to the venous return from the eyes.

**Diplopia.**—Diplopia was another common symptom and was due in every instance to paralysis of one or both external rectus muscles. Twenty-one of the 26 patients with sixth nerve palsies fell into Group 1 (19 otitic), and, of these, 12 were bilateral and nine unilateral. In eight of the latter the localization was upon the same side as the aural suppuration. The frequency with which the sixth nerve is singled out is remarkable and may have aetiological significance. Symonds (1952) has suggested that the sixth nerve is compressed by an accretion of clot in the inferior petrosal sinus. In all patients the sixth nerve palsy cleared up long before the papilloedema resolved and both the transient duration and lateralization lend support to the theory of a compressive lesion.

**Convulsions.**—Five patients had one or more convulsions. Of these, one was a known epileptic and another had a fit at the height of an acute mastoid infection. Two of the remainder had, in addition, focal signs: one a weakness of the left upper limb, the other a mild right hemiplegia. Since fits and focal signs are common in cortical thrombophlebitis, it is probable that the occurrence of convulsions bespoke an extension of the thrombotic process into the cerebral veins as opposed to the sinuses.

#### The Cerebrospinal Fluid

With the exception of one patient (Case 12), all had one or more lumbar punctures. Generally speaking, great elevation of the spinal pressure was not common, and usually it was considerably less than the appearances of the optic fundi would have led one to expect. The initial pressures, measured in mm. of water, were 60 to 180 (three cases), 181 to 300 (24 cases), and greater than 300 mm. (14 cases).

Separate compression of the left and right internal jugular veins was done in 33 patients and the manometric observations were normal in 26. In six patients there was evidence of obstruction to the internal jugular vein or transverse sinus upon one side, whilst in one (Case 7) bilateral jugular compression failed to effect a rise of the spinal C.S.F. pressure.

The protein content of the lumbar C.S.F., measured in mg. per 100 ml., was 10 to 25 (29 cases), 26 to 50 (10 cases), and greater than 50 (two cases). Six patients had a cell count of more than 3 lymphocytes per c. mm. Thus the lumbar C.S.F. was abnormal in seven patients, but, of these, two had had a ventriculogram before analysis of the fluid. Table V shows the nature of the abnormalities found in the remaining five patients.

TABLE V  
PRE-OPERATIVE ABNORMALITIES OF THE C.S.F. IN FIVE CASES

Cells (per c.mm.)	Protein (mg. per 100 ml.)
1 lymphocyte	80 (Case 5)
38 "	90
12 "	20
11 "	25
0 "	52

Three of the patients were lumbar punctured within a few days of an acute mastoid infection, and one within five days of acute follicular tonsillitis. Each patient was submitted to a second lumbar puncture after five to seven days when, in every instance, the fluid was normal. Case 5, which has been described, had been immobilized in bed for several months and this may possibly have accounted for the elevation of the C.S.F. protein.

Thus it appears that during the acute stage of infection the presence of a moderate pleocytosis or elevation of the protein of the lumbar C.S.F. does not exclude a diagnosis of otitic hydrocephalus. In general summary, analysis showed the following:

(1) The pressure, though elevated, is not so high as the degree of papilloedema would suggest.

(2) Evidence of a major sinus occlusion by jugular compression is often absent.

(3) The fluid usually has a normal, or lower than normal, protein content.

(4) There is usually no cellular reaction.

This information is of great value in the differentiation between otitic hydrocephalus and brain abscess. Since well over 90% of patients with brain abscess show an increase in the cellular or protein content (or both), the finding of a normal C.S.F. considerably weighs the evidence in favour of otitic hydrocephalus.

#### Ventricular Air Studies

Air studies were attempted by the ventricular, cisternal, or lumbar routes upon 32 patients. In 31 the ventricles were symmetrical with free inter-communication; in one they seemed to be small and could not be filled. In 18 the findings were entirely normal. In four the ventricles were small and looked "pinched" (Fig. 2), and in all of these

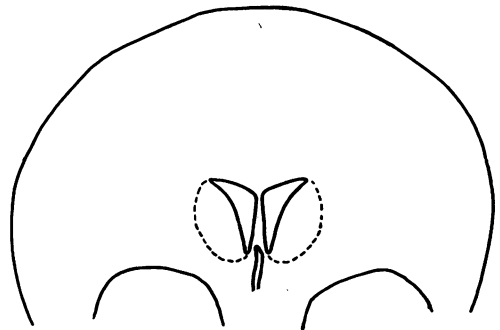


FIG. 2.—"Pinched" ventricles in acute stage of otitic hydrocephalus.

patients there was a history of less than five weeks. The appearances of the ventricles suggested that they were subjected to an evenly dispersed pressure, as from distension of the subarachnoid space in the region of the vertex.

In nine patients there was a slight uniform dilatation of the ventricles (Fig. 3), and this also occurred after operation in Case 16. All of these patients had air studies more than six weeks after the onset of symptoms, the average time interval being 15 weeks.

From these findings it appears that the size of the ventricles is related to the duration of symptoms

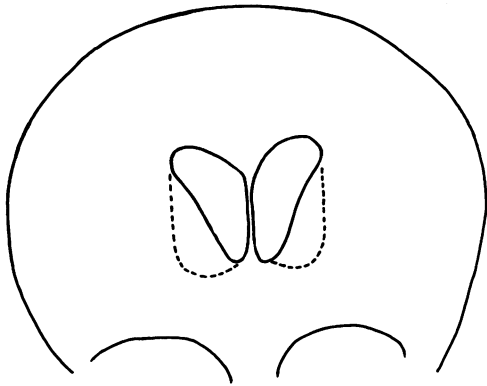


FIG. 3.—Dilated ventricles in late stage of otitic hydrocephalus.

before air encephalography and this may explain the diverse reports of others. In any case the ventriculogram is usually sufficient to exclude a space-occupying lesion.

#### Other Investigations

Sinograms were done on four patients; in two, attempts to fill the sagittal sinus failed although the needle was demonstrated within the sinus by radiography. In the other two the findings suggested a mural thrombosis of the sagittal sinus. This method of investigation proved disappointing, and it must be emphasized that none of the results was unequivocal.

Unilateral carotid arteriography was done on four patients, and bilateral on two. This served to exclude a space-occupying lesion in three patients who did not have air studies. Apart from "bowing" of the anterior cerebral arteries, presumably due to slight ventricular dilatation, no abnormality was detected either in the arterial or venous phase.

#### Management

The immediate problem in the management of these patients is the exclusion of a space-occupying lesion and, as stated above, analysis of the C.S.F. may provide valuable information. Almost always, however, a ventriculogram or an arteriogram is necessary to confirm the diagnosis.

When this has been done the question of treatment arises. The alternatives which have been suggested are to reduce the C.S.F. pressure by repeated spinal puncture, or to proceed straight away to an operative decompression. We have found the first ineffective and the second rarely necessary and, in the majority of our patients, no treatment was given. A few patients were submitted to repeated spinal puncture for interest, and it was found that the pressures fluctuated widely

from day to day. An example is shown in Fig. 4. In other cases the removal of 10 to 15 ml. of C.S.F. twice daily failed to effect a sustained fall of pressure.

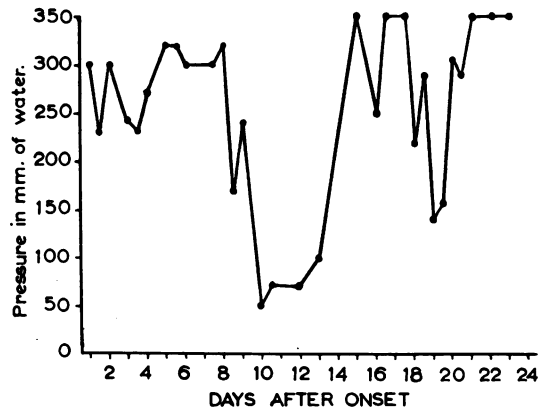


FIG. 4.—Chart showing variations in C.S.F. pressure at daily lumbar punctures.

In short, 15 patients had three or more lumbar punctures, but we found no evidence that they influenced the recession of the papilloedema in any way. Whether or not repeated spinal punctures were employed, there was an average period of seven months before the appearances of the optic fundi returned to normal. It would also appear that frequent spinal puncture will not prevent consecutive optic atrophy, for one patient, who had had over 20, was left with perception of light only in one eye and a visual acuity of J6, 6/9 in the other.

The indications for operative decompression were significant reduction of vision, severe and persistent papilloedema and, in one patient (Case 15), paroxysmal headache which was thereby relieved. But it was by no means always successful in preserving vision and, of the six patients who had an operative decompression to avert blindness, two became blind (Cases 7 and 16), one had good vision in one eye preserved, and three recovered normal visual acuity; they might, of course, have done so without a decompression.

One patient came to operation for a different reason; she was thought to have a posterior fossa tumour.

*Case 17 (No. 28130/52).*—A girl, aged 4, five months previously was treated with penicillin for a left otitis media. This resolved after 10 days when she developed a squint. She was admitted to another hospital where she was found to have papilloedema and subsequently transferred to the Radcliffe Infirmary with a diagnosis of a posterior fossa tumour.

On examination she was a healthy looking child with bilateral papilloedema of 3 to 4 dioptres. No other abnormality was detected.

Radiographs of the skull showed gross suture diastasis. A right occipital burr-hole was made and a needle inserted into the lateral ventricle. The pressure was 500 mm. of water and the ventricle appeared to be capacious. It was decided to proceed to a posterior fossa exploration without preliminary air studies. When the dura was incised, the occipital sinus was found to measure 2 cm. in width and to be distended with dark blood. No other abnormality was detected. The child remained well and the appearances of the optic fundi were normal within six months.

All the evidence, in retrospect, pointed to an otitic hydrocephalus which was probably due to thrombosis of the right transverse sinus.

In one patient a parieto-occipital decompression was done to provide an opportunity for studying the intracranial venous sinuses.

*Case 18 (No. 38685/45).*—A boy, aged 5, three months before admission had a myringotomy for an acute left-sided suppurative otitis media. Nine weeks later he developed a streptococcal arthritis of the left hip and a squint. The arthritis subsided after penicillin treatment and he was transferred to the Radcliffe Infirmary.

On examination there was bilateral papilloedema of 5 dioptres with retinal haemorrhages and exudates. The right external rectus muscle was paralysed but there were no other abnormal physical signs; in particular the left hip was clinically and radiologically normal.

Radiographs of the skull showed slight suture diastasis. The lumbar C.S.F. pressure was 260 mm. of water and the fluid contained 1 lymphocyte per c. mm. and 20 mg. of protein per 100 ml. There was no rise of this pressure when the left jugular vein was compressed; on the right side the spinal manometric observations were normal. Since he was having amblyopic attacks a decompression was done.

A left-sided osteoplastic flap was turned to expose the posterior part of the sagittal sinus, the torcula, the left transverse sinus, and the genu. The posterior 2 cm. of the sagittal sinus and the beginning of the right lateral sinus appeared normal. From thence forwards, for about 4 cm., the sagittal sinus was quite flat, on the same plane as the dura, and the surface was reddened. Anterior to this the normal convexity of the sinus reappeared, although the surface was granular and pink. The left transverse sinus was also flat, reddened, and granular as far as the genu. A hollow needle was inserted into the flattened portions of the sinuses and, in all positions, there was a free flow of blood through it, showing that the lumen was patent. When the dura was opened it was apparent that there was an excess of C.S.F. around the Pacchionian granulations and, after the arachnoid had been pricked, C.S.F. gushed out under increased pressure from a capacious subarachnoid space. The cerebral convolutions and cortical veins appeared to be normal.

He was discharged from hospital after two weeks and remained well. The decompression neither bulged nor became tense and the appearances of the optic fundi were normal after seven months.

These observations suggested a mural thrombosis of the left transverse and sagittal sinuses which did not amount to complete occlusion.

Of the patients who came to operation, only two seemed to "use" the decompression. In none of the frankly otitic cases did it seem to serve any useful function.

### Discussion and Conclusions

The label "otitic hydrocephalus" for these cases is clearly unsuitable, since infections of the second branchial cleft are not exclusive in the production of the syndrome. In the present series, for instance, 21 of the 42 cases were in no way "otitic". Moreover, most clinicians in speaking of hydrocephalus imply dilatation of the cerebral ventricles and, as has been shown, this is not a feature of otitic hydrocephalus. In the absence of a fuller understanding of the pathogenesis it is best to avoid a designation which carries aetiological implications, and it is proposed to employ the term "benign intracranial hypertension".

In 10 patients there was reason to infer obstruction to the venous outflow from the cranium, as low down as the superior vena cava (Case 7), or as high up as a major intracranial venous sinus. Thus, in six patients, compression of the jugular vein upon one side, and in one upon both sides, failed to effect a rise of the spinal C.S.F. pressure. In addition, the lateral sinus was reported to have been thrombosed in two patients who had had a mastoidectomy, and in another (Case 17) the occipital sinus was dilated suggesting occlusion of the transverse sinus.

Obstruction to the jugular system might, as Symonds (1952) has suggested, give rise to oedema of the brain or to increased secretion of C.S.F. Indeed, either of these mechanisms would explain the presence of small ventricles in the acute stage of the condition. However, cerebral oedema is most often associated with marked constitutional symptoms and focal signs (as in hypertensive encephalopathy and brain abscess) which are not found in benign intracranial hypertension. It will also be remembered that in three patients who had a decompression the subarachnoid space was capacious, a finding incompatible with cerebral oedema. For these reasons we believe that the clinical picture and size of the ventricles are caused by an

excess of C.S.F. over the convexity of the hemispheres.

If there is no evidence of occlusion to the jugular system, it is still possible, as Symonds pointed out, that a mural thrombus which does not impair the lumen may exist in relation to the arachnoid villi and thereby impede the reabsorption of C.S.F. We have seen patients with small ventricles and papilloedema consequent on subarachnoid haemorrhage and it is possible that debris of red blood cells may act in a similar way. Without necropsy material it has rarely been practicable to prove or refute this theory. However, in six patients in this series it was possible to invoke thrombosis of the sagittal sinus. Four patients had sinograms and the findings suggested total occlusion in two and a mural thrombosis in two. The operative observations in Case 16 of dilated scalp and cortical veins led us to infer obstruction to the sagittal sinus, whilst in Case 20 the posterior portions of the sagittal and transverse sinuses were flat, reddened, and granular.

The benign nature of the process is also compatible with a thrombosis. The discovery of papilloedema often causes alarm and in the acute phase of the illness there may be some headache, but this is usually short-lived. In the chronic stage during which the papilloedema is resolving the patient may seem to be perfectly well. The onset presumably bespeaks the actual incidence of thrombosis, and later the absorption of C.S.F. is probably re-established either by the original channels or by new ones.

This condition is closely related to cortical thrombophlebitis, which, however, calls attention to itself by gross evidence of hemisphere dysfunction, e.g., fits, hemiplegia, aphasia, hemianopia, etc. Usually there is no papilloedema, but we have seen cases in which, during or after resolution of the focal signs, papilloedema developed, presumably due to a spread of the thrombotic process to the sinuses from the cerebral veins. Similarly, we have observed patients with benign intracranial hypertension develop focal signs, which suggests an extension of the thrombosis from the sinuses to involve cortical veins. In both groups, spontaneous recovery usually occurs.

In 26 patients there was no direct evidence of thrombosis of intracranial sinuses or veins, although two sustained a head injury in the region of the sagittal sinus and a post-traumatic thrombosis of this structure was suspected. A further patient (Case 6) gave a history strongly suggestive of a thrombosis of the left internal jugular vein which followed an operation upon the neck. Indirect

evidence was provided in 35 of the 42 patients by the history or detection of conditions known to be associated with intracranial venous thrombosis. These included infections of the second branchial cleft (21), acute follicular tonsillitis (two), frontal sinusitis (two), trauma (two), mitral stenosis (one), and anaemia (one). In addition, two cases arose in connexion with pregnancy and, including one of these, four patients had evidence of extracranial venous thrombosis. A particularly unusual case has been described in which papilloedema developed in association with a lung abscess. In seven patients there was no well recognized cause to explain the syndrome.

The six patients who were obese formed an interesting group, as the gain in weight seemed closely related to the onset of raised intracranial pressure. With one exception, a boy who appeared to have a mild hypothalamic disorder, all these patients were women. It will also be remembered that two of the three patients with no associated pathology who were included in Group 5 were women. This suggests that endocrine factors may be concerned in the balance between the secretion and reabsorption of the C.S.F., but in what fashion remains obscure. That endocrine disorders can influence the composition of the C.S.F. has been shown by Thompson, Thompson, Silveus, and Dailey (1929) who found an increase in the protein content of the C.S.F. in 13 of 17 patients with myxoedema, whilst Jefferson (1956) noted the appearance of papilloedema in patients with Addison's disease.

Since this paper was started a notable contribution has been made by Foley (1955) who has reviewed 166 patients, including 60 personal cases, with intracranial hypertension. Fifty-nine of these were associated with aural suppuration and the clinical findings are similar to those of the "otitic" group herein described. In a further number of Foley's patients it was possible to incriminate a pre-existing extracranial infection or a head injury. However, in 31 of his personal cases no obvious cause was found. The ratio of females to males in this group was 2 : 1 and it is of particular interest that 22 of the women were obese. Thus, in two independent series, analysis has revealed a group of undetermined aetiology, possibly related to endocrine dysfunction, which is worthy of further study.

Most authorities, including Symonds (1931), Garland and Seed (1933), and Garcin and Pestel (1949), have recommended repeated spinal puncture to avert the development of consecutive optic atrophy. Others have preferred to do an operative decompression. Evidence has been presented to

show that the first is ineffective and the second usually unnecessary, and most of our patients received no treatment. The duration of the papilloedema is often a matter of months, though it may persist for as long as two years; in either instance, the eventual outcome is almost always satisfactory. For the occasional patient with a high degree of papilloedema which does not subside under observation, who has significant visual failure or attacks of amblyopia, it is probably best to do a decompression. By this means everything has been done to preserve vision, though it must be admitted that these patients do not often "use" the decompression.

### Summary

Forty-two patients with papilloedema, unrelated to brain tumour or other well defined cause, are reviewed.

Five clinical groups were distinguishable by reason of an associated pathology: (1) Infections of the second branchial cleft and respiratory tract (26 cases); (2) extracranial venous thrombosis (four cases); (3) obesity (six cases); (4) post-trauma (two cases); (5) undetermined (four cases).

Headaches and other symptoms of increased intracranial pressure were usually slight in proportion to the papilloedema.

Strabismus and diplopia were common and were always due to paralysis of one or both external rectus muscles.

Visual failure was rare, despite the persistence of papilloedema for many months.

Fits and focal signs were rare, and their occurrence is thought to indicate thrombosis of cortical veins.

The lumbar spinal fluid pressure, although usually elevated, was not as high as the degree of papilloedema would lead one to expect.

The spinal fluid was usually normal, although the protein content was frequently lower than normal.

Confirmation of the diagnosis is essential, and this usually entails ventriculography. In the acute stage the ventricles may be slightly smaller than normal, but later may be slightly dilated.

Treatment by repeated lumbar puncture was ineffective. In cases of impending visual failure, decompression operations may be called for.

I wish to thank Mr. J. Pennybacker for his valuable advice and encouragement in the preparation of this paper, and for allowing me to examine the case records and patients admitted under his care.

### REFERENCES

- Bailey, O. T., and Hass, G. M. (1937). *Brain*, 60, 293.  
 Barnett, H. J. M., and Hyland, H. H. (1953). *Ibid.*, 76, 36.  
 Davidoff, L. M., and Dyke, C. G. (1936). *J. nerv. ment. Dis.*, 83, 700.  
 Ellis, R. W. B. (1937). *Proc. roy. Soc. Med.*, 30, 768.  
 Foley, J. (1955). *Brain*, 78, 1.  
 Frenckner, P. (1937). *J. Laryng.*, 52, 350.  
 Garcin, R., and Pestel, M. (1949). *Thrombo-phlébites cérébrales*. Masson, Paris.  
 Garland, H. G., and Sead, G. S. (1933). *Lancet*, 2, 751.  
 Jefferson, A. (1956). *Journal of Neurology, Neurosurgery and Psychiatry*, 19, 21.  
 Kendall, D. (1948). *Brain*, 71, 386.  
 Martin, J. P., and Sheehan, H. L. (1941). *Brit. med. J.*, 1, 349.  
 McKenzie, W. (1948). *J. Laryng.*, 62, 391.  
 McAlpine, D. (1937). *Brain*, 60, 180.  
 Nielsen, J. M., and Courville, C. B. (1934). *Ann. Otol. (St. Louis)*, 43, 972.  
 Pennybacker, J. (1943). *Trans. ophthalm. Soc. U.K.*, 63, 333.  
 Sugarbaker, E. D., and Wiley, H. M. (1951). *Cancer*, 4, 242.  
 Symonds, C. P. (1931). *Brain*, 54, 55.  
 — (1932). *Brit. med. J.*, 1, 53.  
 — (1937). *Brain*, 60, 531.  
 — (1940). *Brit. med. J.*, 2, 348.  
 — (1952). *Ann. roy. Coll. Surg. Engl.*, 10, 347.  
 Thompson, W. O., Thompson, P. K., Silveus, E., and Dailey, M. F. (1929). *Arch. intern. Med.*, 44, 368.  
 Weed, L. H. (1914). *J. med. Res.*, 31, 51.