

THE CLINICAL SIGNIFICANCE OF THE SINU-VERTEBRAL NERVE OF THE CERVICAL SPINE IN RELATION TO THE CERVICAL DISK SYNDROME

BY

RALPH B. CLOWARD

Honolulu, Hawaii

The increasing frequency of injuries to the neck has focused attention on the nature of pain resulting from trauma to the cervical spine. The origin and mechanism of pain in the neck, shoulder, and upper extremities resulting from such injury are not well understood. It is assumed that these pains have their origin in the ligaments and joints of the cervical spine including the intervertebral disks. The sensory nerve which supplies these anatomical structures is the sinu-vertebral nerve. Recently, investigations have been made in patients with painful neck injuries to determine the source of the pain (Cloward, 1959). From the results of these studies it has been possible to ascertain the course and distribution of the sensory nerve which supplies these structures, and the referred pain resulting from its stimulation.

The importance of the sinu-vertebral nerve in cases of rupture of lumbar intervertebral disk has been described by Falconer, McGeorge, and Berg, (1948) and Wiberg (1949). These investigators have determined that reflex rigidity and scoliosis resulting from rupture of the lumbar intervertebral disks are probably produced by irritation of the nerve endings of the sinu-vertebral nerve. Wiberg investigated the anatomical structures about the lower lumbar spinal canal in conscious patients under local anaesthesia. Pressure applied to the ligamentum flavum caused no pain except when the pressure was too great and was transmitted to the adjacent disk. Pressure on the posterior surface of the disk and longitudinal ligament resulted in a pain in the lumbosacral area in all cases. The patients complained of a deep pain within the back lateralized to the side stimulated. Direct pressure to the nerve root caused severe root pain over a dermatome distribution. After anaesthetizing the nerve root the lumbosacral pain could still be produced when pressure was applied to the disk. These experiments have all been carried out by the writer and the findings of Wiberg verified.

One may conclude from these investigations that low back pain with radiation into the sacro-iliac region, hip joint, and upper thigh is not due to compression of the spinal nerve root by the ruptured lumbar disk but is the result of irritation of the sinu-vertebral nerve which supplies the peripheral fibres of the disk and ligaments which surround it. This has been called a diskogenic pain in contradistinction to neurogenic or sciatic pain which results from impingement of the prolapsed disk upon the spinal nerve root. Valuable objective diagnostic information as to the origin of the diskogenic pains has been obtained from the procedure of lumbar diskography. By inserting a fine needle into a ruptured disk (posterior midline) and injecting an opaque fluid into it, pressure is applied to the periphery of the disk through its torn recesses, producing pain. The patient will recognize the character and location of this induced pain as being the same as his clinical symptom if it is caused by the ruptured disk. Lumbar diskography has been used for nearly a decade to determine the cause of low back pain (Cloward and Buzaid, 1952).

All reported anatomical studies of the sinu-vertebral nerve have been made on the lumbar spine where the nerve is larger and more easily followed. The procedure of cervical diskography was developed in the hope that diagnostic information could be obtained to determine the origin and cause of pain from cervical disk pathology (Cloward, 1958a).

In 1956, the method was worked out by inserting a needle into the antero-lateral surface of the disk, injecting an opaque solution, and obtaining a radiograph. As had been found with lumbar diskography (Cloward and Buzaid, 1952), the injection of a fluid medium into the interior of the cervical disk proved to be a painful procedure when the disk was ruptured, and the pain as a rule was described by the patient as being identical with his clinical symptoms. It was also found that the antero-lateral

surface of the disk, either normal or pathological, when stimulated by inserting a needle into it, invariably produced pain. This presented an opportunity to study the sensory nerve supply of the cervical disk. Accordingly, various methods were employed to stimulate the disk, each of which will be described. The referred pains resulting from stimulation of cervical disks were carefully documented according to the disk stimulated and to the exact location of referred pain which resulted. This information has been reported elsewhere (Cloward, 1959).

The anatomical regions to which pain was referred were obtained from the patient when the anterior and posterior surfaces of the intervertebral disk and the corresponding longitudinal ligaments were stimulated. Several methods of stimulation were used including three blind procedures: (1) Needling the anterior surface of the disk for diskography; (2) injection of the disk with a fluid medium for diskography; (3) insertion of fine insulated wires into the disk through the diskogram needle for electrical stimulation. At operation under local anaesthesia, using the anterior approach (Cloward, 1958b), the anterior and posterior surfaces of the disk were also stimulated under direct vision.

Blind Stimulation

(1) The first patient subjected to a cervical diskogram complained of pain when the diskogram needle made contact with the anterior surface of the disk. When asked to localize the pain, she stated, "In my right shoulder blade." Repeated jabs with the needle into the bone (anterior surface of the vertebral body), above and below the disk, caused no pain. But when the disk was touched, the patient reported a rather sharp, aching type of pain located along the vertebral border of the ipsilateral scapula. The pain referred from the upper cervical disks was localized more cephalad on the scapula and from the lower disks more caudad. In over 120 patients, upon whom a cervical diskogram of one or more disks has been performed, this has been a constant finding. This, together with other stimulation experiments, has verified the fact that the anterior outer fibres of the annulus fibrosis of the cervical intervertebral disk are richly supplied with sensory nerves. When these nerves are stimulated or irritated on one side of the disk, pain is referred to the region of the vertebral border of the scapula on the same side.

The second method of investigation was analysis of pain which resulted when the disk was injected

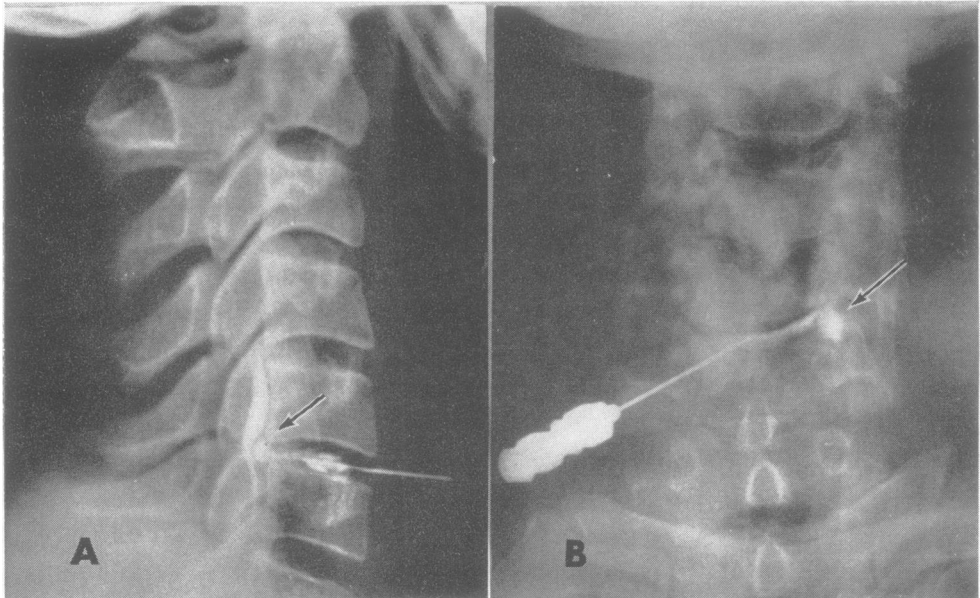


FIG. 1.—Cervical diskogram.

A. Lateral radiographs: opaque solution ("hypaque" 50%) injected in the centre of the disk has passed into the spinal canal through a defect (rupture) in the posterior annulus, outlined the protruding disk fragment (arrow).

B. Antero-posterior projection: needles inserted into the centre of the nucleus pulposus from the antero-lateral surface of the disk. Injected "hypaque" has collected postero-laterally visualizing the herniated disk (arrow).

for diskography (Fig. 1). In the case of a normal disk, that is, one in which fibres of the annulus are not ruptured and the nucleus pulposus is intact, injection of 0.2 to 0.3 ml. of radio-opaque liquid causes no pain. If the fibres of the annulus are torn, permitting the opaque solution, injected under pressure, to reach the periphery of the disk, pain results. The location, character, and intensity of the pain will depend upon the location and extent of the rupture or fissure tract in the disk. Anterior or antero-lateral ruptures cause pain similar to that produced by insertion of the diskogram needle, *i.e.*, along the medial border of the scapula.

If the disk is ruptured in a posterior or posterolateral direction, pains which result from disk injection are of three types: (a) diskogenic, (b) neurogenic, and (c) myelogenic.

The first is by far the most common. If the rupture in the annulus extends to, but not through its peripheral fibres, the pain caused by the injection is described by the patient as beginning in the "shoulder blade" (medial scapular border), spreading over the back of the shoulder or on top of the shoulder in a broad area and then down the posterior surface of the upper arm as far as the elbow. This pain also is described as a "deep, dull, aching sensation" which may be quite severe. It subsides about five to 10 minutes after the injection. This is the "diskogenic" pain.

When the peripheral fibres of the posterior annulus are lacerated, with or without herniation of disk fragments into the spinal canal, as demonstrated by the diskogram, the injected solution can pass through the defect, transmitting the pressure to the spinal nerve root and/or the spinal cord. This "neurogenic" pain resulting from nerve root irritation has a sharper, more intense quality often described by the patient as an electric shock or a hot, burning sensation. It shoots into the arm, forearm, and hand along a dermatome distribution.

In midline disk protrusions, with spinal cord compression, a "myelogenic" pain results from disk injection. This pain, originally described by L'Hermitte, is a shock-like sensation down the middle of the spine and may spread into one or all extremities. It is of only momentary duration.

The third stimulation method consisted of implanting insulated wires into the anterior surface of the disk through the diskogram needle. Electrical stimulus applied to the implanted wire resulted in pain similar to that obtained by needling the disk for diskography, that is, it was referred to the vertebral border of the scapula. Weddell, Feinstein, and Pattle (1943) investigated the scapula pain, which is present in almost every patient with

cervical disk disease, by doing electromyograms on the scapula muscles. They demonstrated abnormal action potentials suggesting that this pain is a motor phenomenon which originates in the muscles of the scapula as a myalgia. Accordingly, electromyogram studies were made on the scapular muscles by stimulating the wire implanted in the anterior surface of the C5-6 disk. These demonstrated a consistently increased irritability of these muscles. Continuous involuntary muscle spasm could be initiated by anterior cervical disk stimulation. Novocaine injected into the area of the implanted stimulating wires abolished the action potentials in the scapula muscles.

If the pain located in the muscles of the vertebral border of the scapula is a motor phenomenon, the nerve impulse must pass from the spinal cord by way of the anterior motor nerve root and the peripheral motor nerve. Stimulation of the ventral cervical nerve root has been shown to produce a deep, boring, myalgic type of pain in the muscles of the shoulder girdle, similar in quality and distribution to that resulting from stimulation of the intervertebral disk. Frykholm (1947) applied mechanical stimuli intradurally to the lower cervical nerve roots under local anaesthesia. He demonstrated conclusively that nerve root pain could be elicited by stimulating the ventral or anterior root as well as the sensory root.

Direct Stimulation

The recent development of a new anterior surgical approach (Cloward, 1958b) for removal of ruptured cervical disks offered an opportunity to stimulate the disk under direct vision. The operation is performed under local anaesthesia with the patient conscious and alert. A 3 cm. transverse skin incision is made on the antero-lateral surface of the neck, and by blunt dissection of the cervical muscles and careful retraction, nearly the entire half of the disk is easily exposed. Pressure with a blunt instrument, a sharp needle, and stimulation by electric current has been applied to each of the cervical disks from C3 to C7 in a large series of patients. The referred pain to the scapular region found by the other methods of stimulation was verified. A drill hole 14 mm. in diameter is made completely through the vertebral bodies at the interspace, exposing the posterior surface of the disk and the posterior longitudinal ligament overlying the dura mater of the spinal cord and nerve roots. The information accumulated on the distribution of pain produced when the posterior disk ruptures were injected for diskography was generally verified by direct stimulation of these elements at the bottom of the drill "hole".

Discussion

From the results of our stimulation studies on the cervical disks, together with those of Frykholm (1947) on the motor roots, a theory may be formulated as to the location and distribution of the sinu-vertebral nerve in the cervical spine. While the nerve in this area is so small as to defy ordinary anatomical methods, the formulation is consistent with the known anatomy of the sinu-vertebral nerve in the lumbar region.

The original anatomical description of the nerve supply to the vertebral column and its ligaments was made by Luschka in 1850. The nerve, called the sinu-vertebral nerve of Luschka, has been studied since that time, though as has been noted, anatomical studies of it have been limited to the lumbar spine. While there is some disagreement as to its actual course, the origin and distribution of its terminal branches have been well established.

The most accurate description of the origin of the sinu-vertebral nerve was made by Hovelacque (1925) and recently studied by Kinney (quoted by Herlihy 1949). According to Kinney, the nerve is formed by a junction of two roots, spinal and sympathetic. The spinal root takes origin from the ventral surface of the "spinal nerve" within the spinal canal. The anterior and posterior spinal nerve roots meet, decussate, and divide into the anterior and posterior primary rami, the short area of decussation being the "spinal nerve". The spinal root of the sinu-vertebral nerve is immediately joined by a sympathetic fibre which passes medially from the sympathetic chain. Both groups of fibres constitute the sinu-vertebral nerve. The main trunk of the nerve then passes medially behind the vertebral body and after a short course divides into its terminal branches.

The distribution of the terminal branches of the sinu-vertebral nerve has been described by Lazorthes, Poulhes, and Espagno (1948) who disagree with an earlier description by Van Buskirk (1941) as to their course. Van Buskirk refers to the origin of the nerve as the "recurrent nerve" which, on gaining the intervertebral canal, divides into an ascending and descending branch, and forms a longitudinal strand of nerve fibres which he calls the sinu-vertebral nerve. The longitudinal strand, he states, extends the length of the vertebral canal anastomosing with its fellow above and below from the opposite side. Lazorthes *et al.*, on the other hand, insist "that the distribution of the branches is purely segmental; that the branches may be short or long and all are ascendent with one exception; that the nerve never divides into ascending or descending branches; and that the nerve anastomoses; the branches may pass anterior or posterior to the anterior longitudinal ligaments and venous sinuses."

According to Lazorthes *et al.*, the branches of the sinu-vertebral nerve are distributed as follows:—

- (1) To the vertebral body from the posterior surface by a few twigs which pass medially anterior to the posterior common ligament and enter the bone along with the basi-vertebral veins;
- (2) to the neuro-laminae from their anterior surface;
- (3) to the intervertebral disk above this vertebral body by more numerous twigs;
- (4) to the intervertebral disk below this vertebral body by fine inconstant filaments which are the only descending elements;
- (5) to the posterior common ligament;
- (6) to the internal vertebral plexus;
- (7) to the epidural tissue;
- (8) to the dura mater by one or two twigs.

The terminal nerve endings of the sinu-vertebral nerve have been studied by Jung and Brunschwig (1932) who described nerve fibres in the anterior spinal ligament, in the posterior longitudinal ligament, and between the annulus fibrosus and the spinal ligaments. They found no nerve endings within the intervertebral disk, but more recently Roofe (1940) observed numerous nerve endings in the posterior annulus fibrosus and posterior longitudinal ligament.

The sinu-vertebral nerve supplies the vertebral column, the intervertebral disks, "the longitudinal venous sinuses", the ligaments within the vertebral canal, the epidural tissue of the vertebral canal, and the dura mater. The nerve is largely sensory and according to Roofe it subserves the function of pain. Van Buskirk indicates that the nerve contains both myelinated and non-myelinated fibres, the majority being the latter. The sympathetic fibres have an arterio-vasomotor function since the longitudinal veins of the internal vertebral plexus do not contain muscle tissue.

From our stimulation experiments and the known anatomical distribution of the sinu-vertebral nerve in the lumbar region, the nerve supply to the cervical intervertebral disks, its course and distribution, may be postulated (Fig. 2). The receptors of this sensory nerve are located throughout the peripheral fibres of the annulus fibrosus of the intervertebral disk, including the attachment of these fibres to the margins of the adjacent vertebral bodies (Sharpey's fibres). The findings suggest that the nerve from each side passes around the disk, supplying one-half of it. The terminal fibres must extend a short distance across the midline and decussate with those from the opposite side, since anterior stimulation of the centre of the disk produces bilateral shoulder pain. The terminal branches probably enter the anterior longitudinal ligament. It is questionable whether the entire length of the long ligament is supplied by filaments from the nerve or just the area of the ligament which passes over the disk. As

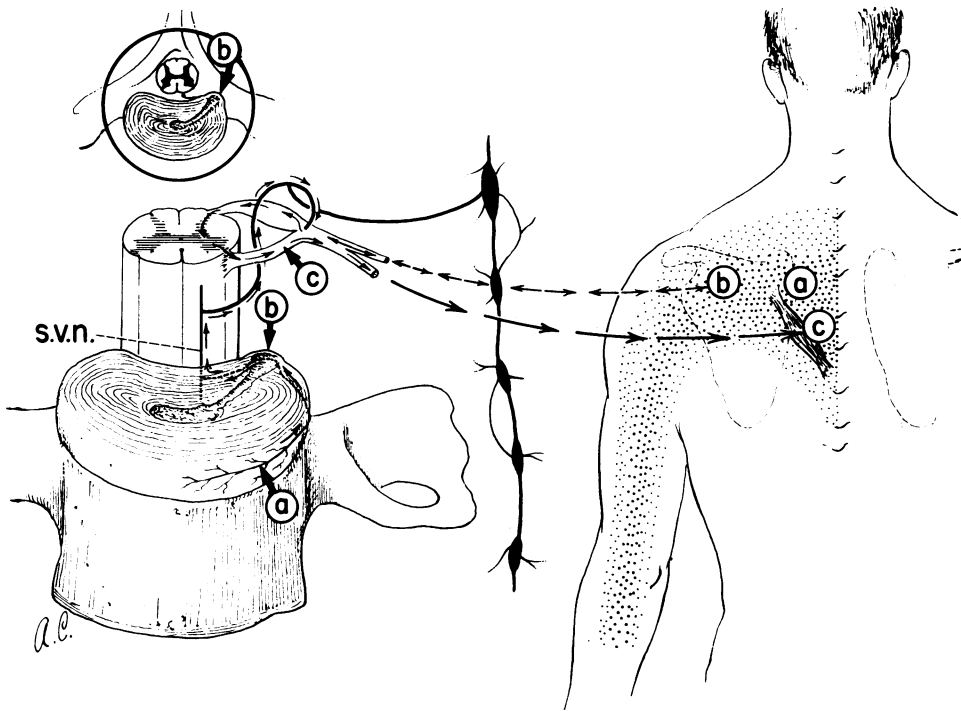


FIG. 2.—Drawing to demonstrate the proposed anatomy of the sinu-vertebral nerve in the cervical region and the pathway over which pain impulses originating in the periphery of the intervertebral disk are referred to the region of the scapula, shoulder, and upper arm.

Mechanical or electrical stimulation of:

- (a) Anterior surface of cervical disk refers pain to vertebral border of scapula.
- (b) Postero-lateral surface of the disk, pain referred to the scapula, shoulder, and radiation into upper arm.
- (c) Motor nerve root intradural; deep myalgic type of pain referred to muscles of vertebral border of the scapula. Pathway of sinu-vertebral from periphery of cervical disk indicated by arrows. Pain impulse enters posterior nerve root and/or to muscle of scapula as reflex arc through spinal cord, anterior root, and motor nerve. Branch from sympathetic chain has insignificant role in pain syndrome.

described above, the referred scapular pain is not produced by stimulating this ligament over the body of the vertebra, but only as it crosses over the disk. It may be that inasmuch as the ligament is so closely associated with and often adherent to the anterior surface of the disk, the stimulus is transmitted through the ligament to the disk surface. This may indicate that the anterior longitudinal ligament has only an insignificant nerve supply compared with that of the disk itself, and therefore contributes very little to the overall pain syndrome.

The nerve evidently courses around the disk to the posterior surface where its fine branches and sensory receptors give evidence of being more numerous. The flood of pain resulting from stimulation of these areas is more diffuse, that is, it spreads over a wider area. It has been possible to map out by stimulation under direct vision the posterior area of the disk and posterior longitudinal ligament, but the information obtained is not so accurate as that

derived from the anterior surface. These posterior structures along with the overlying anterior dura mater are so closely associated that a great many more nerve endings of the sinu-vertebral nerve which supply them are stimulated when the disk is injected for diskography or at open operation. This would account for the pain which is more severe and extends over a wider area. Because of the extensive overlapping of the painful areas resulting from stimulation of the posterior surface of the various cervical disks, it is suggested that one sinu-vertebral nerve may contribute to the nerve supply of the posterior surface of more than one cervical disk, and that through its descending branches it may also supply the posterior surface of the intervertebral disk below as suggested by Lazorthes *et al.* (1948).

In the lumbar region, according to anatomists, the various branches of the sinu-vertebral nerve converge on the posterior surface of the spine to form the main trunk or "recurrent nerve" (Van

Buskirk) which passes through the intervertebral foramen and enters the "spinal nerve" slightly distal to the spinal root ganglion. The pathway over which the sensory impulse travels after gaining entrance to the spinal cord by way of the posterior horn is unknown. It is likely that the sensory impulses pass through a segmental reflex arc to the shoulder muscles by way of the anterior horn cells and motor root at the same or an adjacent level of the spinal cord. Many of the muscles of the pectoral girdle are supplied by cervical motor nerve roots. Pain caused by pressure on the ventral root has been ascribed to changes produced in the muscle fibres with resultant activation of local sensory endings in the muscle, after which the afferent impulse travels centripetally by way of sensory pathways, dorsal root ganglia, and dorsal roots to enter the spinal cord. The impulse is then transmitted via neurons of higher order to cerebral centres for pain.

It is understandable that pain from stimulation of the anterior surface of the disk would be selectively referred to muscles along the vertebral border of the scapula. These muscles, *i.e.*, the levatores scapulae, the rhomboidus minor and major, receive their nerve supply from the anterior rami of the third, fourth, and fifth cervical nerves. The explanation for a painful stimulus on the anterior surface of the spine being perceived in the middle of the back is to be found in the developmental origin of the posterior muscles of the body wall. Embryologically the "ventrolateral" sheath of musculature of the lower cervical region undergoes subsequent migration to obtain a secondary skeletal attachment to the vertebral column at a considerable distance from its origin. Such "muscle migration" is most clearly seen in the diaphragm and latissimus dorsi muscles.

A few patients were selected because they were good witnesses to sensory stimuli. When the cervical disk were stimulated and the scapular pain produced, superficial sensation over the area was tested with light touch and pin prick. Although the findings were often equivocal, one occasionally encountered a patient who insisted that the skin over the painful scapular area was hypersensitive to superficial stimuli. This was observed immediately following injection of the disk for diskography. This finding suggested a sensory as well as a motor origin for the scapular pain and may represent a retrograde impulse through the posterior spinal root and sensory nerve as suggested by Kahr and Sheehan (1933).

In performing the cervical diskogram, inquiry is always made to determine if the flood of pain which follows disk injection could be interpreted as having a sympathetic character or distribution. There are

numerous reports in the literature in which symptoms such as headache, facial pain, vertigo, pseudo-angina, etc., have been attributed to and described as a part of the cervical disk syndrome (Neuwirth and Gayral, 1958). It has been our general impression clinically that ruptured cervical disks are not directly responsible for these vague, unexplainable symptoms. Furthermore, experimentally induced pain, resulting from disk injection, in our experience has not been referred to the head, face, ear, eye, or precordium. This suggests that pain impulses having their origin in the disk do not spread through the sympathetic chain to these remote areas. The function of the sympathetic branch of the sinu-vertebral nerve is to supply, via visceral motor fibres, the blood vessels of the spinal canal and the spinal dura mater, as described by French anatomists. If pain of a sympathetic character results from irritation of these structures by a ruptured disk, it remains localized as part of the neck, shoulder, and arm pain and does not spread to other regions.

Summary and Conclusions

In the investigation of the cause of neck, shoulder, and arm pain in patients with lesions of cervical intervertebral disks, the anatomical structure responsible for the major portion of these pains was found to be the intervertebral disk itself and its surrounding ligaments. Various methods were used to stimulate the disks in conscious subjects, and the exact location and distribution of the referred pains were determined. Objective information was also obtained by electromyographic studies of the shoulder and arm muscles resulting from stimulation of the lower cervical disks. From the information thus accumulated, together with known anatomical knowledge of the sinu-vertebral nerve in the lumbar region, the course of this nerve in the cervical spine has been proposed. Two possible routes for the pain impulse carried by this nerve after it enters the spinal cord are also suggested.

REFERENCES

- Cloward, R. B. (1958a). *Amer. J. Roentgenol.*, 79, 563.
 — (1958b). *J. Neurosurg.*, 15, 602.
 — (1959). *Ann. Surg.*, 150, 1052.
 —, and Buzaid, L. L. (1952). *Amer. J. Roentgenol.*, 68, 552.
 Falconer, M. A., McGeorge, M., and Berg, A. C. (1948). *J. Neurosurg. Psychiat.*, 11, 13.
 Frykholm, R. (1947). *J. Neurosurg.*, 4, 403.
 Herlihy, W. F. (1949). *N.Z. med. J.*, 48, 214.
 Hovelacque, A. (1925). *Ann. Anat. path.*, 2, 435.
 Jung, A., and Brunschwig, A. (1932). *Presse med.*, 40, 316.
 Kahr, S., and Sheehan, D. (1933). *Brain*, 56, 265.
 Lazorthes, G., Poulhes, J., and Espagno, J. (1948). *C. R. Ass. Anat.* 34th Reunion, p. 317.
 Luschka, H. (1850). *Die Nerven des menschlichen Wirbelkanals.* Laupp, Tubingen.
 Neuwirth, E., and Gayral, L. (1958). *J. Lancet*, 78, 197.
 Roope, P. G. (1940). *Arch. Neurol. Psychiat. (Chicago)*, 44, 100.
 Van Buskirk, C. (1941). *Arch. Surg. (Chicago)*, 43, 427.
 Weddell, G., Feinstein, B., and Pattle, R. E. (1943). *Lancet*, 1, 236.
 Wiberg, G. (1949). *Acta orthop. scand.*, 19, 211.